Please visit us at www.Groupinsiders.com

Pathology

USMLE STEP 1

Volume 2: Systemic Pathology

Chapters 10–28

BECKER
PROFESSIONAL EDUCATION®

Please visit us at www.Groupinsiders.com

USMLE Step 1

Pathology

Volume 1: Basic Pathology
Chapters 1–9

Volume 2: Systemic Pathology
Chapters 10–28

Kartik "Carlo" Rangaraj, MD

National Instructor

V 1.1

Please visit us at www.Groupinsiders.com

Please visit us at www.Groupinsiders.com

Kartik "Carlo" Rangaraj, MD
National Instructor, Pathology

Steven R. Daugherty, PhD
Director, Faculty and Curriculum at Becker Professional Education
Chicago, IL

The United States Medical Licensing Examination® (USMLE®) is a joint program of the Federation of State Medical Boards (FSMB) and National Board of Medical Examiners® (NBME®). United States Medical Licensing Examination, USMLE, National Board of Medical Examiners, and NBME are registered trademarks of the National Board of Medical Examiners. The National Board of Medical Examiners does not sponsor, endorse, or support Becker Professional Education in any manner.

© 2013 by DeVry/Becker Educational Development Corp. All rights reserved.

No part of this work may be reproduced, translated, distributed, published or transmitted without the prior written permission of the copyright owner. Request for permission or further information should be addressed to the Permissions Department, DeVry/Becker Educational Development Corp.

1 2 3 4 5 6 7 8 9 18 17 16 15 14 13

Table of Contents

Pathology

Volume 1: Basic Pathology

Unit 1 General Principles of Pathology

Chapter 1 Cellular Pathophysiology 1-1
1 Overview of Cellular Pathophysiology 1-1
2 Tissue Hypoxia 1-2
3 Free Radical Cell Injury 1-20
4 Cellular Accumulations and Reversible Changes 1-23
5 Cellular Responses to Stress 1-26
6 Cell Death (Necrosis) 1-30
7 Apoptosis 1-34

Chapter 2 The Inflammatory Reaction 2-1
1 Overview of Inflammation 2-1
2 The Process of Acute Inflammation 2-4
3 Chronic Inflammation 2-14

Chapter 3 Tissue Repair and Wound Healing 3-1
1 Overview of Regeneration and Repair 3-1
2 Repair by Regeneration 3-1
3 Types of Wound Healing 3-4
4 Extracellular Matrix 3-6

Chapter 4 Hemodynamics 4-1
1 Normal Vascular Hemostasis 4-1
2 Hemodynamic Dysfunction 4-3
3 Diseases of Hypercoagulability 4-10
4 Thrombosis 4-12
5 Embolism 4-13
6 Infarction 4-14
7 Hyperemia, Congestion, and Edema 4-15
8 Shock 4-17

Chapter 5 Neoplasia 5-1
1 Types of Neoplasms 5-1
2 Mechanisms of Carcinogenesis 5-4
3 Cancer Epidemiology 5-15

Please visit us at www.Groupinsiders.com

© DeVry/Becker Educational Development Corp. All rights reserved.

Table of Contents

Pathology

4 Diagnosis of Cancer 5-16
5 Paraneoplastic Syndromes 5-17
6 Cancer Prevention 5-18

Unit 2 Hematology

Chapter 6 Red Blood Cell Pathology 6-1
1 Red Blood Cells 6-1
2 Anemia 6-4
3 Microcytic Anemias 6-6
4 Macrocytic Anemias 6-15
5 Normocytic Anemia 6-19
6 Myelofibrosis 6-30
7 Polycythemia 6-31

Chapter 7 White Blood Cell Pathology 7-1
1 Blood Cell Differentiation 7-1
2 Review of Morphology 7-2
3 Quantitative Disorders 7-3
4 Leukemias 7-6

Chapter 8 Lymphoid Pathology 8-1
1 Lymphoid Pathology Overview 8-1
2 Lymph Nodes 8-1
3 Spleen 8-9
4 Thymus 8-10
5 Plasma Cell Neoplasms 8-11

Chapter 9 Immunohematology 9-1
1 ABO Blood Group Antigens 9-1
2 Determining the ABO Group 9-2
3 Rh Antigen and Non-Rh Antigen Systems 9-3
4 Patient Crossmatch 9-5
5 Transfusion Reactions 9-6
6 Hemolytic Disease of the Newborn (HDN) 9-7

Please visit us at www.Groupinsiders.com

© DeVry/Becker Educational Development Corp. All rights reserved.

Table of Contents

Pathology

Volume 2: Systemic Pathology

Unit 3 Cardiovascular Pathology

Chapter 10 Cardiovascular Disorders 10-1

1 Heart Failure 10-1
2 Ischemic Heart Disease 10-8
3 Cardiomyopathy 10-15
4 Valvular Heart Disease 10-17
5 Endocarditis 10-21
6 Congenital Heart Disease 10-25
7 Myocardial and Pericardial Disease 10-33

Chapter 11 Cardiovascular Pathology 11-1

1 Hypertension 11-1
2 Arteriosclerosis 11-3
3 Hyperlipoproteinemia 11-6
4 Aneurysms 11-9
5 Benign Vascular Tumors 11-11
6 Malignant Vascular Tumors 11-13
7 Vasculitis 11-14

Unit 4 Respiratory Pathology

Chapter 12 Pulmonary Pathology 12-1

1 Basics of the Pulmonary System 12-1
2 Pulmonary Function Tests 12-2
3 Atelectasis 12-3
4 Chronic Obstructive Lung Disease (COPD) 12-5
5 Restrictive Lung Disease 12-9
6 Pulmonary Vascular Disease 12-13
7 Lung Cancer 12-19

Please visit us at www.Groupinsiders.com

© DeVry/Becker Educational Development Corp. All rights reserved.

Table of Contents

Pathology

Unit 5 Renal Pathology

Chapter 13 Renal Pathology 13-1

1 Overview of the Renal System 13-1
2 Renal Functional Anatomy 13-3
3 Renal Pathology 13-11
4 Glomerular Disease 13-14
5 Diseases Affecting Tubules and Interstitium 13-25
6 Infection 13-28
7 Vascular Disease 13-29
8 Urinary Tract Obstruction 13-31
9 Renal Failure 13-33
10 Tumors of the Kidney 13-34
11 Lower Urinary Tract Pathology 13-35

Unit 6 Gastrointestinal Pathology

Chapter 14 Gastrointestinal (GI) Pathology 14-1

1 Gastrointestinal (GI) Pathology Overview 14-1
2 Oral Cavity 14-1
3 Esophagus 14-2
4 Gastric Diseases 14-6
5 Acute Erosive (Hemorrhagic) Gastritis 14-8
6 Diarrhea 14-16
7 Malabsorption Syndromes 14-22
8 Appendicitis 14-23
9 Inflammatory Bowel Disease 14-24
10 Hemorrhoids—Two Types 14-25
11 Small and Large Bowel Polyps 14-26
12 Intestinal Neoplasia 14-27

Unit 7 Hepatobiliary Pathology/Pancreas

Chapter 15 Hepatobiliary Pathology 15-1

1 Hepatic and Biliary Pathology 15-1
2 Cirrhosis 15-5
3 Cholestatic Diseases 15-9

Please visit us at www.Groupinsiders.com

© DeVry/Becker Educational Development Corp. All rights reserved.

Table of Contents

Pathology

4 Hepatic Inflammatory Diseases 15-12
5 Metabolic Liver Diseases 15-16
6 Hepatic Vascular Diseases 15-18
7 Hepatic Neoplastic Diseases 15-19

Chapter 16 Pancreatic Pathology 16-1
1 Congenital Disorders 16-1
2 Inflammation 16-2
3 Neoplastic Disorders 16-5

Unit 8 Reproductive Pathology

Chapter 17 Male Reproductive Pathology 17-1
1 Congenital Abnormalities 17-1
2 Penile Pathology 17-2
3 Abnormalities of the Testes, Epididymis, and Scrotal Sac 17-4
4 Testicular Tumors—Major Categories 17-6
5 Prostate 17-8
6 Common Male Chromosomal Abnormalities 17-11

Chapter 18 Female Reproductive Pathology 18-1
1 Vulva Disorders 18-1
2 Vaginal Disorders 18-2
3 Cervical Disorders 18-3
4 Reproductive Physiology 18-5
5 Effects of Pregnancy 18-11
6 Menopause 18-11
7 Hirsutism and Virilization 18-12
8 Menstrual Dysfunction 18-14
9 Uterine Disorders 18-17
10 Fallopian Tube Disorders 18-20
11 Ovarian Disorders 18-21
12 Gestational Disorders 18-23
13 Sexually Transmitted Diseases and Genital Infections 18-27
14 Breast Anatomy 18-31
15 Nipple Discharge 18-32

Please visit us at www.Groupinsiders.com

© DeVry/Becker Educational Development Corp. All rights reserved.

Table of Contents

Pathology

16 Fibrocystic Change 18-33
17 Benign Breast Tumors 18-34
18 Types of Breast Cancer 18-35

Unit 9 Endocrine Pathology

Chapter 19 Endocrine Pathology 19-1
1 Overview of Pathology 19-1
2 The Hypothalamus and Pituitary 19-3
3 The Hypothalamus and Pituitary: Anterior Pituitary 19-5
4 The Hypothalamus and Pituitary: Thyroid Hormone 19-10
5 The Hypothalamus and Pituitary: Adrenals 19-21
6 Endocrine Pancreas 19-33
7 Calcium Metabolism and Bone 19-47

Unit 10 Nervous Pathology

Chapter 20 Central Nervous System Pathology 20-1
1 Basic Neuroanatomy 20-1
2 Central Nervous System Developmental Diseases 20-3
3 Cerebral Herniation 20-9
4 Cranial Pressure Abnormalities 20-10
5 Head Trauma 20-12
6 Spinal Cord Lesions 20-15
7 Cerebrovascular Disease 20-21
8 Infectious Diseases 20-31
9 Degenerative Diseases 20-39
10 Central Nervous Tumors 20-43

Chapter 21 Peripheral Nervous System Pathology 21-1
1 Inflammatory Neuropathy 21-1
2 Hereditary Neuropathy 21-2

Please visit us at www.Groupinsiders.com

© DeVry/Becker Educational Development Corp. All rights reserved.

Table of Contents

Pathology

Chapter 22 Optic Pathology 22-1

1 Anatomy of the Eye 22-1
2 Congenital Abnormalities 22-2
3 Eyelid Disorders 22-3
4 Conjunctival Disorders 22-4
5 Disorders of the Uvea 22-6
6 Retinal Disorders 22-7
7 Macular Degeneration 22-10
8 Ocular Melanoma 22-11
9 Glaucoma 22-12

Unit 11 Musculoskeleton and Connective Tissue Disorders

Chapter 23 Connective Tissue Disorders 23-1

1 Types of Connective Tissue Disorders 23-1

Chapter 24 Joint Pathology 24-1

1 Classification of Joint Pathologies 24-1
2 Noninflammatory Arthritis 24-2
3 Inflammatory Arthritis 24-5
4 Arthritis of Metabolic Origin 24-12
5 Septic Arthritis 24-15
6 Joint Tumors 24-16

Chapter 25 Bone Pathology 25-1

1 The Skeleton 25-1
2 Congenital Bone Disease 25-4
3 Metabolic and Acquired Bone Disease 25-6
4 Trauma 25-13
5 Infection 25-16
6 Bone-Forming Tumors 25-18
7 Cartilage-Forming Tumors 25-20
8 Fibrous and Other Tumors 25-21
9 Metastatic Diseases 25-22

Please visit us at www.Groupinsiders.com

© DeVry/Becker Educational Development Corp. All rights reserved.

Table of Contents

Pathology

Chapter 26 Muscle Pathology 26-1

1 Classification of Muscle Fiber Type and Innervation 26-1

2 Muscular Dystrophies 26-3

3 Diseases of the Neuromuscular Junction 26-7

Chapter 27 Soft Tissue Pathology 27-1

1 Overview of Connective Tissue Tumors 27-1

2 Tumors of Fat Tissue 27-1

3 Tumors of Fibroblasts 27-2

4 Tumors of Muscle 27-3

Unit 12 Dermatology

Chapter 28 Dermatopathology 28-1

1 Overview and Terminology 28-1

2 Infectious Diseases 28-3

3 Inflammatory Dermatopathology 28-10

4 Neoplastic Diseases 28-14

Please visit us at www.Groupinsiders.com

© DeVry/Becker Educational Development Corp. All rights reserved.

Table of Contents

Pathology Figures

Chapter 1 Cellular Pathophysiology

Figure 1-1.1 . . . . Cellular Response to Stress and Injury 1-1
Figure 1-2.0A . . . Oxidative Phosphorylation. 1-2
Figure 1-2.0B . . . Cyanosis in Patient With Tetralogy of Fallot 1-3
Figure 1-2.1A . . . Ischemia. 1-4
Figure 1-2.1B . . . Hypoxemia 1-5
Figure 1-2.1C . . . Airway Obstruction. 1-6
Figure 1-2.1D . . . Respiratory Distress Syndrome 1-6
Figure 1-2.1E . . . Pulmonary Embolus 1-6
Figure 1-2.1F . . . Pulmonary Infarction 1-6
Figure 1-2.1G . . . Diffusion Defect. 1-7
Figure 1-2.1H . . . Anemia. 1-7
Figure 1-2.1I . . . Methemoglobinemia 1-8
Figure 1-2.1J . . . Carbon Monoxide Poisoning. 1-8
Figure 1-2.1K . . . O_2-Binding Curve (OBC) 1-9
Figure 1-2.2 . . . . Hepatic Portal System 1-11
Figure 1-2.3A . . . Anaerobic Glycolysis: Diffusion of Na^+ and H_2O Into Cell. 1-12
Figure 1-2.3B . . . Re-entry of CA^{2+} Into Mitochondria 1-13
Figure 1-2.3C . . . Ubiquitination 1-14
Figure 1-2.3D . . . Mallory Body 1-15
Figure 1-2.3E . . . Electron Transport Chain: BCL_2 Gene and Cytochrome *c* 1-16
Figure 1-2.3F . . . NADH 1-17
Figure 1-2.3G . . . Heterophagy and Autophagy 1-18
Figure 1-2.3H . . . Megagranule Formation in CHS 1-19
Figure 1-3.0 . . . . Role of Free Radicals in Cell Death 1-20
Figure 1-3.3 . . . . Neutralization of Free Radicals. 1-21
Figure 1-4.1 . . . . Lipofuscin 1-23
Figure 1-4.2A . . . Fat Accumulation in Liver Cells 1-23
Figure 1-4.2B . . . Role of CCI_4 in Fat Accumulation 1-24
Figure 1-4.3 . . . . Bilirubin Accumulation in Liver Tissue. 1-24
Figure 1-4.4 . . . . Hemosiderin Deposits: Prussian Blue Stain 1-25
Figure 1-4.5 . . . . Dystrophic Calcification 1-25
Figure 1-5.1A . . . Prostate Hyperplasia 1-26
Figure 1-5.1B . . . Hyperplasia: Graves Disease Goiter 1-26

Please visit us at www.Groupinsiders.com

© DeVry/Becker Educational Development Corp. All rights reserved.

Table of Contents

Pathology Figures

Figure 1-5.2 . . . . Hypertrophy 1-27
Figure 1-5.3 . . . . Cerebral Atrophy 1-28
Figure 1-5.4 . . . . Glandular Metaplasia in Barrett Esophagus 1-29
Figure 1-6.1A . . . Coagulative Necrosis: Dry Gangrene Caused by Diabetes 1-30
Figure 1-6.1B . . . Coagulative Necrosis 1-30
Figure 1-6.1C . . . Myocardial Infarction 1-31
Figure 1-6.2 . . . . Liquefactive Necrosis: Cystic Cavity in the Brain 1-31
Figure 1-6.3A . . . Caseous Necrosis: Macroscopic Morphology 1-32
Figure 1-6.3B . . . Caseous Necrosis: Microscopic Morphology 1-32
Figure 1-6.5 . . . . Enzymatic Fat Necrosis of Pancreas With Saponification 1-33
Figure 1-7.3A . . . Pathways of Apoptosis 1-35
Figure 1-7.3B . . . Apoptotic Body 1-36

Chapter 2 The Inflammatory Reaction

Figure 2-1.2A . . . Mast Cell. 2-2
Figure 2-1.2B . . . Basophil 2-2
Figure 2-1.2C . . . Neutrophil. 2-2
Figure 2-1.2D . . . Monocyte 2-2
Figure 2-1.2E . . . Macrophage 2-2
Figure 2-1.2F . . . Lymphocyte 2-3
Figure 2-1.2G . . . Plasma Cell 2-3
Figure 2-1.2H . . . Eosinophil 2-3
Figure 2-2.1 . . . . Steps of Leukocyte Extravasation 2-6
Figure 2-2.2 . . . . Mechanisms of Intracellular Killing 2-7
Figure 2-2.3A . . . Arachidonic Acid Cascade 2-8
Figure 2-2.3B . . . Complement Split Products 2-10
Figure 2-2.3C . . . Clotting Cascade 2-11
Figure 2-2.4A . . . Intracellular Killing in CGD 2-13
Figure 2-2.4B . . . Phagocyte in CHS 2-13

Chapter 3 Tissue Repair and Wound Healing

Figure 3-2.1 . . . . Cell Cycle 3-1
Figure 3-2.2 . . . . Growth and Regeneration Signals 3-2
Figure 3-3.1 . . . . Healing by Primary Intention. 3-4
Figure 3-3.2 . . . . Healing by Secondary Intention. 3-5
Figure 3-4.0 . . . . Extracellular Matrix: Collagen 3-6

Please visit us at www.Groupinsiders.com

© DeVry/Becker Educational Development Corp. All rights reserved.

Table of Contents

Pathology Figures

Chapter 4 Hemodynamics

Figure 4-1.1 . . . . Thrombotic Hemostasis 4-1
Figure 4-1.2 . . . . Antithrombotic Activities of Endothelial Cells 4-2
Figure 4-2.1A . . . Thrombogenesis 4-3
Figure 4-2.1B . . . Platelet Adhesion 4-4
Figure 4-2.1C . . . Primary Hemostasis 4-5
Figure 4-2.1D . . . Aggregation 4-5
Figure 4-2.1E . . . Primary Hemostasis 4-6
Figure 4-2.1F . . . Coagulation Cascade 4-6
Figure 4-2.1G . . . Extrinsic and Intrinsic Pathways. 4-7
Figure 4-4.2 . . . . Arterial Thrombus 4-12
Figure 4-5.1 . . . . Saddle Embolus. 4-13
Figure 4-6.1 . . . . Red Infarction 4-14
Figure 4-7.1 . . . . Hyperemia 4-15
Figure 4-7.2A . . . Congestion 4-15
Figure 4-7.2B . . . Centrilobular Necrosis Resulting From Congestive Heart Failure . . 4-16
Figure 4-8.1 . . . . Fick Equation 4-17
Figure 4-8.3 . . . . Septic Shock 4-18

Chapter 5 Neoplasia

Figure 5-1.3A . . . Tubular Adenoma. 5-2
Figure 5-1.3B . . . Teratoma 5-2
Figure 5-1.3C . . . Hamartoma. 5-3
Figure 5-2.0 . . . . Carcinogenesis 5-4
Figure 5-2.2A . . . Chromosomal Translocation 5-6
Figure 5-2.2B . . . Mechanism of RAS Carcinogenesis 5-7
Figure 5-2.2C . . . Oncogenesis 5-9
Figure 5-2.3A . . . Pathogenesis of Retinoblastoma 5-10
Figure 5-2.3B . . . Pathogenesis of Familial Adenomatous Polyposis 5-11
Figure 5-2.8A . . . Metastasis. 5-13
Figure 5-2.8B . . . Radiograph of Metastasis 5-14
Figure 5-4.4 . . . . Clinical Basis for Staging Cancer 5-16

Please visit us at www.Groupinsiders.com

© DeVry/Becker Educational Development Corp. All rights reserved.

Table of Contents

Pathology Figures

Chapter 6 Red Blood Cell Pathology

Figure 6-1.3A . . . Reticulocyte 6-2
Figure 6-1.3B . . . Inaccurate Estimate of Reticulocytosis 6-2
Figure 6-1.3C . . . Erythropoiesis: Hair-on-End Appearance. 6-3
Figure 6-2.1A . . . Types of Anemia 6-4
Figure 6-2.1B . . . Normal Iron Labs. 6-5
Figure 6-3.1A . . . Iron Deficiency 6-6
Figure 6-3.1B . . . Koilonychia 6-6
Figure 6-3.1C . . . Red Blood Cell Distribution Width (RDW) 6-6
Figure 6-3.1D . . . Glossitis Seen With Iron-Deficiency Anemia 6-7
Figure 6-3.1E . . . Anemia of Chronic Disease: Laboratory Findings 6-7
Figure 6-3.1F . . . Porphyria Pathway 6-8
Figure 6-3.1G . . . Heme Synthesis, Porphyrias, and Lead Poisoning. 6-9
Figure 6-3.1H . . . Ringed Sideroblasts 6-10
Figure 6-3.1I . . . Basophilic Stippling 6-10
Figure 6-3.1J . . . Iron Overload: Sideroblastic Anemia 6-10
Figure 6-3.2A . . . Hydrops Fetalis 6-11
Figure 6-3.2B . . . α-Thalassemia Trait 6-12
Figure 6-3.2C . . . Splicing Patterns 6-12
Figure 6-3.2D . . . Peripheral Blood Smear 6-13
Figure 6-3.2E . . . Normal HbE. 6-13
Figure 6-3.2F . . . α-Thalassemia Trait 6-13
Figure 6-3.2G . . . HbE of β-Thalassemia Minor 6-14
Figure 6-4.2 . . . . Biochemical Pathways of Folate and Vitamin B12. 6-16
Figure 6-4.3 . . . . Megaloblast. 6-17
Figure 6-4.4 . . . . Schilling Test. 6-18
Figure 6-5.1 . . . . Normocytic Anemias 6-19
Figure 6-5.2A . . . Corrected Reticulocyte Count 6-20
Figure 6-5.2B . . . Normal Bone Marrow 6-21
Figure 6-5.2C . . . Fibrosed Bone Marrow Secondary to Breast Cancer Metastasis . 6-21
Figure 6-5.3A . . . Extravascular Hemolysis 6-21
Figure 6-5.3B . . . Reticuloctye Count of >3% 6-22
Figure 6-5.3C . . . Spherocytes 6-22

Please visit us at www.Groupinsiders.com

© DeVry/Becker Educational Development Corp. All rights reserved.

Table of Contents

Pathology Figures

Figure 6-5.3D . . . Sickling of Red Blood Cell 6-23
Figure 6-5.3E . . . Howell-Jolly Bodies 6-24
Figure 6-5.3F . . . Sickle Cell Trait vs. Sickle Cell Disease 6-25
Figure 6-5.3G . . . Heinz Bodies 6-26
Figure 6-5.3H . . . Role of Pyruvate Kinase in Glycolysis 6-26
Figure 6-5.3I . . . Aortic Stenosis 6-27
Figure 6-5.3J . . . WAIHA: Role of Penicillin and α-Methyldopa 6-27
Figure 6-5.3K . . . CAIHA: Role of Quinidine 6-28
Figure 6-7.4 . . . . Polycythemia. 6-31
Figure 6-7.5 . . . . Polycythemia Vera Bone Marrow 6-32

Chapter 7 White Blood Cell Pathology

Figure 7-1.0 . . . . Blood Cell Differentiation 7-1
Figure 7-2.1A . . . White Blood Cells. 7-2
Figure 7-3.1A . . . Leukoerythroblastic 7-3
Figure 7-3.1B . . . Atypical Lymphocytes. 7-4
Figure 7-4.0 . . . . Classification of Leukemias 7-6
Figure 7-4.1A . . . Acute Lymphocytic Leukemia (ALL) 7-7
Figure 7-4.1B . . . Acute Myeloid Leukemia (AML) 7-9
Figure 7-4.2A . . . Chronic Lymphoid Leukemia 7-10
Figure 7-4.2B . . . The Philadelphia Chromosome. 7-11
Figure 7-4.2C . . . Chronic Myelogenous Leukemia 7-12
Figure 7-4.2D . . . Hairy Cell Leukemia 7-13

Chapter 8 Lymphoid Pathology

Figure 8-2.1A . . . Normal Lymph Node. 8-1
Figure 8-2.1B . . . Birbeck Granules 8-1
Figure 8-2.4 . . . . Hodgkin Lymphoma 8-4
Figure 8-2.5A . . . Non-Hodgkin Lymphoma/Follicular Lymphoma. 8-6
Figure 8-2.5B . . . Non-Hodgkin Lymphoma/Diffuse Large B Cell Lymphoma 8-6
Figure 8-2.5C . . . Non-Hodgkin Lymphoma/Burkitt Lymphoma 8-7
Figure 8-2.5D . . . Non-Hodgkin Lymphoma/Burkitt Lymphoma 8-7
Figure 8-5.1A . . . Multiple Myeloma. 8-11
Figure 8-5.1B . . . Special Staining of CD138. 8-12

Please visit us at www.Groupinsiders.com

© DeVry/Becker Educational Development Corp. All rights reserved.

Table of Contents

Pathology Figures

Chapter 9 Immunohematology

Figure 9-1.5 . . . . Parents' Blood Types 9-1
Figure 9-2.2 . . . . Determining ABO Group 9-2
Figure 9-3.1 . . . . C, D, E Antigens 9-3
Figure 9-6.1 . . . . ABO HDN 9-7
Figure 9-6.2 . . . . Kernicterus 9-8

Chapter 10 Cardiovascular Disorders

Figure 10-1.1A. . . Left-Sided Heart Failure, Microscopic 10-2
Figure 10-1.1B. . . Left-Sided Heart Failure Forward Failure 10-3
Figure 10-1.1C. . . Left-Sided Heart Failure 10-3
Figure 10-1.1D . . Pulmonary Capillary Wedge Pressure (PCWP) 10-4
Figure 10-1.1E. . . Cardiovascular Function Curves: CHF 10-5
Figure 10-1.2A. . . Jugular Vein Pulse 10-6
Figure 10-1.2B. . . Right-Sided Heart Failure 10-7
Figure 10-1.2C. . . Right Atrial Tracing. 10-7
Figure 10-2.2A . . Ischemic Heart Disease: Stable Angina 10-8
Figure 10-2.2B . . Ischemic Heart Disease: Variant (Prinzmetal) Angina 10-9
Figure 10-2.2C . . Ischemic Heart Disease: Myocardial Infarction 10-10
Figure 10-2.2D . . Ischemic Heart Disease: Myocardial Infarction 10-10
Figure 10-2.2E. . . Ischemic Heart Disease: Myocardial Infarction 10-11
Figure 10-2.2F. . . Coronary Arteries 10-11
Figure 10-2.2G . . Ischemic Heart Disease: Myocardial Infarction Morphology—Day 1 10-12
Figure 10-2.2H . . Ischemic Heart Disease: Myocardial Infarction Morphology—Day 7 10-12
Figure 10-2.2I . . CK-MB Required to Dx Reinfarction Because Troponins Are Increased Over a Week. 10-13
Figure 10-2.2J . . Ischemic Heart Disease: Myocardial Infarction 10-13
Figure 10-2.2K . . Fibrinous Pericarditis Ventricular Aneurysm. 10-14
Figure 10-3.1 . . . Dilated Cardiomyopathy 10-15
Figure 10-3.2 . . . Hypertrophic Cardiomyopathy 10-16
Figure 10-4.1A . . Aortic Stenosis 10-17

Please visit us at www.Groupinsiders.com

© DeVry/Becker Educational Development Corp. All rights reserved.

Table of Contents

Pathology Figures

Figure 10-4.1B . . Aortic Regurgitation 10-18
Figure 10-4.1C . . Mitral Stenosis. 10-19
Figure 10-4.1D . . Mitral Regurgitation 10-19
Figure 10-4.1E . . Mitral Valve Prolapse 10-20
Figure 10-5.0A . . Review: Layers of Cardiac Wall 10-21
Figure 10-5.0B . . Endocarditis 10-21
Figure 10-5.1 . . . Janeway Lesion 10-22
Figure 10-5.3A . . Rheumatic Fever 10-23
Figure 10-5.3B . . Rheumatic Fever (Histology) 10-24
Figure 10-6.0 . . . Fetal Circulation. 10-25
Figure 10-6.2A . . Tetralogy of Fallot 10-27
Figure 10-6.2B . . Transposition of the Great Arteries. 10-28
Figure 10-6.2C . . Truncus Arteriosus 10-28
Figure 10-6.2D . . Tricuspid Atresia 10-29
Figure 10-6.2E . . Total Anomalous Pulmonary Venous Return (TAPVR) 10-29
Figure 10-6.2F. . . Atrial Septal Defect 10-30
Figure 10-6.2G . . Ventricular Septal Defect (VSD). 10-31
Figure 10-6.2H . . Patent Ductus Arteriosus (PDA) 10-31
Figure 10-6.3A . . Coarctation of the Aorta 10-32
Figure 10-6.3B . . Collateral Circulation in Coarctation of the Aorta 10-32
Figure 10-7.1 . . . Myocarditis 10-33
Figure 10-7.2A . . Acute Pericarditis: EKG. 10-34
Figure 10-7.2B . . Pericardial Tamponage 10-35

Chapter 11 Cardiovascular Pathology

Figure 11-1.2 . . . Malignant Nephrosclerosis. 11-2
Figure 11-2.1A . . Hyaline Arteriolosclerosis 11-3
Figure 11-2.1B . . Hyperplastic Arteriolosclerosis 11-3
Figure 11-2.2A. . . Atherosclerosis 11-4
Figure 11-2.2B. . . Atherosclerosis 11-5
Figure 11-2.2C. . . Atherosclerosis (Histology) 11-5
Figure 11-3.0 . . . Lipid Metabolism and Hyperlipoproteinemias 11-6

Please visit us at www.Groupinsiders.com

© DeVry/Becker Educational Development Corp. All rights reserved.

Pathology Figures

Figure 11-3.1 . . . Hyperlipoproteinemia 11-7
Figure 11-3.2 . . . Xanthelasma 11-7
Figure 11-3.3 . . . Type III Hyperlipoproteinemia 11-8
Figure 11-3.4 . . . Types III and IV Hyperlipoproteinemia 11-8
Figure 11-4.1 . . . Aneurysms 11-9
Figure 11-4.2 . . . Cystic Medial Necrosis 11-10
Figure 11-5.1A . . Spider Telangiectasia 11-11
Figure 11-5.1B . . Hereditary Telangiectasia 11-11
Figure 11-5.2 . . . Capillary Hemangioma 11-12
Figure 11-5.3 . . . Sturge-Weber Syndrome 11-12
Figure 11-6.1 . . . Kaposi Sarcoma. 11-13
Figure 11-7.2 . . . Takayasu Arteritis 11-16
Figure 11-7.3A . . Kawasaki Disease 11-17
Figure 11-7.3B . . Polyarteritis Nodosa 11-17
Figure 11-7.4 . . . Wegener Granulomatosis 11-18
Figure 11-7.5A . . Henoch-Schönlein Purpura 11-19
Figure 11-7.5B . . Behçet Disease 11-19
Figure 11-7.6A . . Buerger Disease 11-20
Figure 11-7.6B . . Raynaud Phenomenon 11-20

Chapter 12 Pulmonary Pathology

Figure 12-1.0A . . Lower Airways 12-1
Figure 12-1.0B . . Conducting Zone and Respiratory Zone 12-1
Figure 12-2.2 . . . Spirometry 12-2
Figure 12-3.1 . . . Alveolar Damage 12-4
Figure 12-4.1A . . Centrilobular Emphysema 12-5
Figure 12-4.1B . . Panacinar Emphysema 12-6
Figure 12-4.1C . . Chest X-Ray of Emphysema 12-6
Figure 12-4.2 . . . Chronic Bronchitis vs. Emphysema. 12-7
Figure 12-4.4 . . . Dilated Bronchi and Bronchioles in Bronchiectasis 12-8
Figure 12-5.1A . . Anthrocotic Depositions 12-9
Figure 12-5.1B . . Silicotic Nodule 12-10

Please visit us at www.Groupinsiders.com

© DeVry/Becker Educational Development Corp. All rights reserved.

Table of Contents

Pathology Figures

Figure 12-5.1C. . . Ferruginous Bodies 12-10
Figure 12-5.1D . . Mesothelioma 12-10
Figure 12-5.2 . . . Interstitial Granuloma 12-11
Figure 12-6.0 . . . Hemosiderin-Laden Alveolar Macrophage 12-13
Figure 12-6.2A . . Sites of Aspiration of Foreign Particles 12-14
Figure 12-6.2B . . Lobar Pneumonia With Consolidation 12-14
Figure 12-6.2C . . Bronchopneumonia With Patchy Consolidation. 12-14
Figure 12-6.2D . . Typical Pneumonia 12-15
Figure 12-6.3A . . Primary Ghon Complex. 12-18
Figure 12-6.3B . . Caseous ("Cheese-Like") Necrosi 12-18
Figure 12-7.0 . . . Chest X-Ray With Multiple Lung Nodules. 12-19
Figure 12-7.1A . . Bronchogenic Carcinoma 12-19
Figure 12-7.1B . . Chest X-Ray With Small or Squamous Bronchogenic Carcinoma 12-20
Figure 12-7.1C. . . Adenocarcinoma Located Peripherally. 12-20
Figure 12-7.4 . . . Tension Pneumothorax and Tracheal Deviation 12-21
Figure 12-7.5 . . . Mesothelioma 12-22

Chapter 13 Renal Pathology

Figure 13-1.2 . . . Renal Anatomy 13-1
Figure 13-1.3 . . . Renal Arteries and Veins 13-2
Figure 13-2.1 . . . Renal Functional Anatomy. 13-3
Figure 13-2.3A . . Basic Renal Processes. 13-5
Figure 13-2.3B . . Bowman Capsule and Glomerular Anatomy. 13-5
Figure 13-2.4A . . Fenestrated Capillary Tufts 13-6
Figure 13-2.4B . . Renal Filtration Barriers 13-7
Figure 13-2.5A . . Renal Handling of BUN/Cr 13-8
Figure 13-2.5B . . Prerenal Azotemia 13-9
Figure 13-2.5C . . Renal Azotemia 13-9
Figure 13-2.5D . . Postrenal Azotemia 13-10
Figure 13-3.1 . . . Developmental Landmarks of the Renal System 13-11
Figure 13-3.4A . . Polycystic Kidney Disease 13-13

Please visit us at www.Groupinsiders.com

© DeVry/Becker Educational Development Corp. All rights reserved.

Table of Contents

Pathology Figures

Figure 13-4.1A. . . Immune-Glomerulopathy Patterns 13-14
Figure 13-4.1B. . . Glomerular Diseases 13-15
Figure 13-4.3A. . . Fatty Casts 13-16
Figure 13-4.3B. . . Normal Glomerulus Light Microscopy 13-16
Figure 13-4.3C. . . Normal Glomerulus Electron Microscopy 13-16
Figure 13-4.3D . . Minimal Change Disease 13-17
Figure 13-4.3E. . . Light Microscopy of Membranous Glomerulonephritis 13-18
Figure 13-4.3F. . . Electron Microscopy of Membranous Glomerulonephritis 13-18
Figure 13-4.3G . . Membranous-Granular Pattern. 13-18
Figure 13-4.3H . . Diabetic Nephropathy. 13-20
Figure 13-4.3I . . Renal Amyloid 13-20
Figure 13-4.4A . . Subepithelial Hump of Post-Streptococcal Glomerulonephritis . . 13-21
Figure 13-4.4B . . IgA in Mesangium 13-22
Figure 13-4.5A . . Rapidly Progressive Glomerulonephritis 13-23
Figure 13-4.5B . . Henoch-Schönlein Purpura 13-24
Figure 13-5.4 . . . Acute Tubular Necrosis 13-25
Figure 13-5.5 . . . Renal Papillary Necrosis with Ring-Sign Necrosis 13-26
Figure 13-6.2A . . White Blood Cell Casts 13-28
Figure 13-6.2B . . Blunted Calyx 13-28
Figure 13-7.1 . . . Fibromuscular Dysplasia of the Renal Artery 13-29
Figure 13-8.1 . . . Hydronephrosis of the Renal Parenchyma 13-31
Figure 13-9.1 . . . Urinalysis Waxy Broadcasts. 13-33
Figure 13-10.1. . . Renal Cell Carcinoma 13-34
Figure 13-10.2 . . Wilms Tumor. 13-34

Chapter 14 Gastrointestinal (GI) Pathology

Figure 14-2.2 . . . Peutz-Jeghers Syndrome 14-1
Figure 14-3.1A . . Tracheoesophageal Fistula (Pattern C) 14-2
Figure 14-3.1B . . Hiatal Hernia 14-3
Figure 14-3.2 . . . Esophagus: Normal GEJ and Mucosa 14-4
Figure 14-3.4 . . . Esophageal Varices 14-5
Figure 14-3.5 . . . Esophageal Adenocarcinoma 14-5
Figure 14-4.3 . . . Structural/Functional Stomach Diseases 14-7

Please visit us at www.Groupinsiders.com

© DeVry/Becker Educational Development Corp. All rights reserved.

Table of Contents

Pathology Figures

Figure 14-5.0 . . . Hemorrhagic Gastritis. 14-8
Figure 14-5.1 . . . Anatomy of Gastric Blood Supply 14-10
Figure 14-5.2A . . Signet Ring-Type Gastric Adenocarcinoma. 14-10
Figure 14-5.2B. . . Linitis Plastica 14-10
Figure 14-5.3A. . . Duodenal Artesia 14-12
Figure 14-5.3B. . . Intussusception 14-12
Figure 14-5.3C. . . Volvulus 14-13
Figure 14-5.3D . . Meckel Diverticulum 14-13
Figure 14-5.3E . . Diverticulosis. 14-14
Figure 14-5.3F . . Hirschsprung Disease 14-15
Figure 14-7.0 . . Celiac Disease 14-22
Figure 14-9.0 . . Crohn Disease 14-24
Figure 14-10.1 . . Hemorrhoids 14-25
Figure 14-11.2 . . Examples of Neoplastic Polyps. 14-26
Figure 14-12.1A. . Duke Stages 14-28
Figure 14-12.1B. . Colorectal Cancer. 14-29
Figure 14-12.2 . . Carcinoid Tumors 14-30

Chapter 15 Hepatobiliary Pathology

Figure 15-1.0A . . The Liver 15-1
Figure 15-1.0B . . Bilirubin Metabolism. 15-1
Figure 15-1.0C . . Hepatic Handling of Bilirubin 15-2
Figure 15-1.1A . . Prehepatic Jaundice 15-3
Figure 15-1.1B . . Hepatic Jaundice 15-3
Figure 15-1.1C . . Obstructive Liver Disease 15-4
Figure 15-2.1A . . Portal Hypertension 15-5
Figure 15-2.1B . . Ascites 15-6
Figure 15-2.3A . . Manifestations of Cirrhosis 15-7
Figure 15-2.3B . . Cirrhosis 15-8
Figure 15-2.3C . . Histology of Cirrhosis 15-8
Figure 15-3.3A . . Extrahepatic Cholestatic Diseases/
Primary Sclerosing Cholangitis 15-10
Figure 15-3.3B . . Extrahepatic Cholestatic Diseases 15-10

Please visit us at www.Groupinsiders.com

© DeVry/Becker Educational Development Corp. All rights reserved.

Table of Contents

Pathology Figures

Figure 15-3.4 . . . Cholestatic Diseases/Dubin-Johnson Syndrome 15-11
Figure 15-4.1A . . "Councilman Bodies" in Viral Hepatitis 15-12
Figure 15-4.1B . . Hepatitis B Virus Markers 15-13
Figure 15-4.3A . . Hepatic Steatosis 15-14
Figure 15-4.3B . . Hypoglycemia 15-14
Figure 15-4.3C . . Alcoholic Liver Disease 15-15
Figure 15-5.1 . . . Wilson Disease 15-16
Figure 15-5.2 . . . Hemochromatosis 15-16
Figure 15-7.2 . . . Hepatocellular Carcinoma 15-19
Figure 15-7.3A . . Gallstones 15-20
Figure 15-7.3B . . Cholecystitis 15-21

Chapter 16 Pancreatic Pathology

Figure 16-1.4 . . . Congenital Disorders 16-1
Figure 16-2.1A . . Acute Pancreatitis 16-2
Figure 16-2.1B . . Pancreatic Pseudocyst 16-3
Figure 16-3.2 . . . Grey Turner and Cullen Signs 16-5

Chapter 17 Male Reproductive Pathology

Figure 17-2.1 . . . Peyronie Disease 17-2
Figure 17-3.2 . . . Testicular Torsion 17-4
Figure 17-3.3 . . . Varicocele 17-5
Figure 17-5.2 . . . Benign Prostatic Hyperplasia (BPH) 17-9
Figure 17-5.3A . . Prostate Cancer 17-10
Figure 17-5.3B . . Prostate Cancer: Osteoblastic Metastasis to the Vertebrae . . . 17-10
Figure 17-6.1 . . . Klinefelter Syndrome 17-11
Figure 17-6.2 . . . Androgen Insensitivity Syndrome (AIS) 17-12

Chapter 18 Female Reproductive Pathology

Figure 18-1.1 . . . Lichen Sclerosis 18-1
Figure 18-1.2 . . . Paget Disease 18-1
Figure 18-2.2A . . Embryonal Rhabdomyosarcoma 18-2
Figure 18-3.1 . . . Koilocytosis in CIN 18-3
Figure 18-3.2 . . . Cervical Cancer 18-4

Please visit us at www.Groupinsiders.com

© DeVry/Becker Educational Development Corp. All rights reserved.

Table of Contents

Pathology Figures

Figure 18-4.0A. . . Ovarian-Uterine System 18-5
Figure 18-4.0B. . . Hormone Secretions of the Follicular Phase 18-6
Figure 18-4.0C. . . Hormone Secretions and Ovulation 18-7
Figure 18-4.0D . . Hormone Secretions of the Luteal Phase 18-8
Figure 18-4.0E. . . Hormonal Maintenance of Pregnancy 18-9
Figure 18-4.0F. . . Theca Interna Around Developing Follicle 18-10
Figure 18-7.0A. . . Hirsutism 18-12
Figure 18-7.0B . . Polycystic Ovarian Syndrome 18-13
Figure 18-8.4 . . . Amenorrhea 18-16
Figure 18-9.1 . . . Adenomyosis 18-17
Figure 18-9.2 . . . Intestinal Obstruction Found With Endometriosis 18-18
Figure 18-9.5 . . . Leiomyoma 18-19
Figure 18-10.1 . . Ectopic Pregnancy 18-20
Figure 18-11.2 . . Classification of Ovarian Tumors 18-21
Figure 18-12.2A. . Placenta Previa 18-23
Figure 18-12.2B . . Abruptio Placentae 18-24
Figure 18-12.2C. . Complete Mole 18-26
Figure 18-12.2D . Normal Chorionic Villi 18-26
Figure 18-14.0 . . Breast Nirvana 18-31
Figure 18-16.1 . . Fibrocystic Change 18-33
Figure 18-17.1 . . Fibroadenoma 18-34

Chapter 19 Endocrine Pathology

Figure 19-1.0 . . . Hormones Regulate and Maintain the "Milieu Interior" 19-1
Figure 19-2.1 . . . Osmality Inbalance 19-3
Figure 19-3.1A . . Hypothalamic-Anterior Pituitary System 19-5
Figure 19-3.1B . . Rathke Pouch 19-5
Figure 19-3.1C . . Pink Acidophils and Dark Purple Basophils 19-6
Figure 19-3.2 . . . Proteolytic Cleavage of the POMC Gene 19-7
Figure 19-3.3A . . Hypopituitarism 19-7
Figure 19-3.3B . . Sellar Mass 19-8
Figure 19-3.4 . . . Pituitary Adenoma 19-8
Figure 19-4.1 . . . Three Forms of Monodeiodonases 19-10

Please visit us at www.Groupinsiders.com

© DeVry/Becker Educational Development Corp. All rights reserved.

Table of Contents

Pathology Figures

Figure 19-4.2 . . . Congenital Thyroid Disease 19-11
Figure 19-4.3A . . Graves Disease 19-12
Figure 19-4.3B . . Pretibial Myxedema 19-12
Figure 19-4.3C . . Graves Exopthalmos. 19-12
Figure 19-4.3D . . Hashimoto Thyroiditis: Hurthle Cells 19-13
Figure 19-4.3E . . Work-up for Hyperthyroidism 19-14
Figure 19-4.4A . . Adult Hyperthyroidism 19-15
Figure 19-4.4B . . Hypothyroidism: Childhood Cretinism. 19-16
Figure 19-4.5A . . Benign "Hot" Nodule 19-18
Figure 19-4.5B . . "Cold" Nodules 19-18
Figure 19-4.5C . . Approach to Thyroid Nodule 19-19
Figure 19-4.5D . . Psammoma Bodies. 19-20
Figure 19-4.5E . . Follicular Carcinoma 19-20
Figure 19-4.5F . . Anaplastic Carcinoma 19-20
Figure 19-5.1A . . Pathways of Steroid Hormones Synthesis 19-21
Figure 19-5.2A . . Synthesis in Zona Fasciculata and Zona Reticularis 19-23
Figure 19-5.2B. . . Metabolic Actions of Cortisol 19-24
Figure 19-5.2C . . Control of Cortisol Secretion 19-24
Figure 19-5.2D . . Cortisol Secretion and Action. 19-25
Figure 19-5.3A . . Addison Disease 19-25
Figure 19-5.3B . . Waterhouse-Friderichsen Syndrome 19-26
Figure 19-5.3C . . Adrenal Insufficiency: Hyperpigmentation. 19-26
Figure 19-5.3D . . Metyrapone Test 19-26
Figure 19-5.3E . . Cushing Syndrome. 19-27
Figure 19-5.3F. . . Cushing Symptoms 19-27
Figure 19-5.3G . . 21β-Hydroxylase Deficiency—Zona Glomerulosa 19-29
Figure 19-5.3H . . 21β-Hydroxylase Deficiency—Zona Fasciculata, Zona Reticularis. 19-29
Figure 19-5.3I . . 11β-Hydroxylase Deficiency—Zona Fasciculata, Zona Reticularis. 19-30
Figure 19-5.3J . . 17α-Hydroxylase Deficiency—Zona Fasciculata, Zona Reticularis. 19-30
Figure 19-5.3K. . . Adrenal Medulla. 19-31

Please visit us at www.Groupinsiders.com

© DeVry/Becker Educational Development Corp. All rights reserved.

Pathology Figures

Figure 19-5.3L. . . Metabolic Actions of Epinephrine and Norepinephrine 19-32
Figure 19-6.1A . . Pancreatic Islets 19-33
Figure 19-6.1B . . Pancreatic Islet Cell 19-33
Figure 19-6.1C . . Preproinsulin, Proinsulin, and Insulin 19-34
Figure 19-6.1D . . Control of Insulin Secretion 19-34
Figure 19-6.1E . . β Cell Insulin Release 19-35
Figure 19-6.1F. . . Peripheral Actions of Insulin 19-35
Figure 19-6.2A . . Insulinoma Histology 19-36
Figure 19-6.2B . . Necrolytic Migratory Erythema 19-37
Figure 19-6.3A . . Diabetes Mellitus: Muscle Wasting and Hyperglycemia 19-39
Figure 19-6.3B . . Diabetes Mellitus: Ketoacidosis and Hypertriglyceridemia 19-39
Figure 19-6.3C . . Insulitis in Type I Diabetes 19-40
Figure 19-6.3D . . Hyalinization of Pancreatic β Cells in Type II Diabetes 19-41
Figure 19-6.3E . . Diabetic Ocular Complication: Cataracts 19-45
Figure 19-6.3F. . . Diabetic Ocular Complication: Retinal Detachment 19-45
Figure 19-6.3G . . Kimmelstiel-Wilson Nodule 19-45
Figure 19-6.3H . . Neuropathic Pressure Ulcers 19-46
Figure 19-6.3I . . Acanthosis Nigricans 19-46
Figure 19-6.3J . . Necrobiosis Lipoidica 19-46
Figure 19-7.1A . . Compartmentalization of Ca^{++} and Free PO_4^- 19-47
Figure 19-7.1B . . Compartmentalization of Ca^{++} in the Body 19-47
Figure 19-7.2 . . . Regulation of ECF Calcium and Phosphate 19-48

Chapter 20 Central Nervous System Pathology

Figure 20-1.1A . . Layers of the Skull 20-1
Figure 20-1.1B . . MRI Sagittal Section of the Brain 20-2
Figure 20-1.1C . . Pyramidal Neurons 20-2
Figure 20-2.0A . . "Bleeding" of the Nucleus Pulposes 20-3
Figure 20-2.0B . . Developmental Diseases 20-3
Figure 20-2.0C . . Developmental Diseases of the Central Nervous System 20-4
Figure 20-2.1A . . Anencephaly 20-4
Figure 20-2.1B . . Encephalocele 20-4
Figure 20-2.1C . . Spina Bifida 20-5

Please visit us at www.Groupinsiders.com

© DeVry/Becker Educational Development Corp. All rights reserved.

Table of Contents

Pathology Figures

Figure 20-2.2A . . Arnold-Chiari Type I 20-6
Figure 20-2.2B . . Dandy-Walker Malformation 20-7
Figure 20-2.3 . . . Periventricular Leukomalacia 20-7
Figure 20-2.4 . . . Fetal Alcohol Syndrome 20-8
Figure 20-2.5 . . . Holoprosencephaly 20-8
Figure 20-3.3A . . Cerebral Herniation 20-9
Figure 20-3.3B . . Effects of Uncal and Subfalcine Herniations of the CN III and PCA 20-9
Figure 20-3.4A . . Holoprosencephaly 20-10
Figure 20-3.4B . . Hydrocephalus 20-10
Figure 20-5.1A . . Head Trauma 20-12
Figure 20-5.1B . . Diffuse Axonal Injury 20-12
Figure 20-5.2A . . Epidural Hematoma: Biconvex Bleed 20-13
Figure 20-5.2B . . Subdural Hematoma 20-14
Figure 20-6.0 . . . Spinal Cord and Associated Tracts 20-15
Figure 20-6.2A . . Poliomyelitis: Lesion of Anterior Horns 20-16
Figure 20-6.2B . . Multiple Sclerosis: Lesion of Anterior Horns 20-16
Figure 20-6.4A . . Amyotrophic Lateral Sclerosis 20-17
Figure 20-6.4B . . ASA Occlusion Lesions 20-17
Figure 20-6.4C . . Artery of Adamkiewicz 20-17
Figure 20-6.5 . . . Tabes Dorsalis 20-18
Figure 20-6.6 . . . Subacute Combined Degeneration 20-18
Figure 20-6.7 . . . Syringomyelia 20-19
Figure 20-6.8 . . . Syringomyelia Lesion 20-20
Figure 20-7.1 . . . Cerebral Edema 20-21
Figure 20-7.4 . . . 12 to 48 Hours "Dead Reds" 20-22
Figure 20-7.5A . . Acute Watershed Infarcts 20-23
Figure 20-7.5B . . Atherosclerotic Stroke 20-24
Figure 20-7.5C . . Chronic Right MCA Infarct 20-24
Figure 20-7.5D . . Focal Ischemia 20-24
Figure 20-7.5E . . Lacunar Infarct 20-25
Figure 20-7.5F. . . H.I.E. Stroke Imaging 20-25
Figure 20-7.6A . . Cerebral Distribution 20-26

Please visit us at www.Groupinsiders.com

© DeVry/Becker Educational Development Corp. All rights reserved.

Table of Contents

Pathology Figures

Figure 20-7.6B . . Subacute Infarction 20-28
Figure 20-7.6C . . Transient Ischemic Attacks 20-28
Figure 20-7.7A . . Hemorrhagic Infarcts: Causes 20-29
Figure 20-7.7B . . Berry Aneurysms 20-30
Figure 20-7.7C . . Subarachnoid Hemorrhage 20-30
Figure 20-8.1A . . Bacterial Meningitis 20-31
Figure 20-8.1B . . Fungal Meningitis. 20-32
Figure 20-8.1C . . Cryptococci in a Mucinous Background 20-32
Figure 20-8.3A . . Cytomegalovirus 20-33
Figure 20-8.3B . . Viral Encephalitis: Rabies 20-34
Figure 20-8.3C . . Type I Viral Encephalitis 20-35
Figure 20-8.4A . . *Naegleria Fowleri* 20-35
Figure 20-8.4B . . Cerebral Toxoplasmosis 20-36
Figure 20-8.5A . . Multiple Sclerosis: Demyelination. 20-37
Figure 20-8.5B . . Multiple Sclerosis: Oligoclonal Bands 20-38
Figure 20-8.5C . . Central Pointe Myelinolysis 20-38
Figure 20-9.1 . . . Cortical Neuritic Plaques 20-39
Figure 20-9.2 . . . Idiopathic Parkinson Disease. 20-40
Figure 20-9.3 . . . Huntington Disease 20-41
Figure 20-9.5 . . . Pick Disease Frontotemporal Dementia. 20-42
Figure 20-10.2A. . Pilocytic Astrocytoma 20-43
Figure 20-10.2B. . Grade II Oligodendroglioma 20-44
Figure 20-10.2C. . Ependymoma 20-44
Figure 20-10.2D . Medulloblastoma 20-45
Figure 20-10.2E. . Homer-Wright Rosettes 20-45
Figure 20-10.2F. . Schwannoma. 20-46
Figure 20-10.2G . Meningioma 20-46
Figure 20-10.2H . Crantopharyngioma 20-47

Chapter 21 Peripheral Nervous System Pathology

Figure 21-2.1A . . Demyelination/Remyelination 21-3
Figure 21-2.1B . . Pes Cavus 21-4

Please visit us at www.Groupinsiders.com

© DeVry/Becker Educational Development Corp. All rights reserved.

Table of Contents

Pathology Figures

Chapter 22 Optic Pathology

Figure 22-1.0 . . . Anatomy of the Eye 22-1
Figure 22-2.2 . . . Congenital Abnormalities 22-2
Figure 22-3.2 . . . Chalazion 22-3
Figure 22-4.3 . . . Bacterial, Viral, Allergic Conjunctivitis. 22-4
Figure 22-4.4 . . . Pterygium 22-5
Figure 22-5.0 . . . Uveitis 22-6
Figure 22-6.0 . . . Normal Retina 22-7
Figure 22-6.2A . . Hypertensive Retinopathy 22-8
Figure 22-6.2B . . Hypertensive Retinopathy 22-8
Figure 22-8.0 . . . Ocular Melanoma 22-11
Figure 22-9.1 . . . Ocular Glaucoma 22-12

Chapter 23 Connective Tissue Disorders

Figure 23-1.1 . . . Ehlers-Danlos Syndrome. 23-1
Figure 23-1.2 . . . Keloid. 23-2
Figure 23-1.3A . . Marfan Syndrome 23-3
Figure 23-1.3B . . Extracellular Matrix: Elastin. 23-4

Chapter 24 Joint Pathology

Figure 24-1.0 . . . Joint Histology. 24-1
Figure 24-2.1A . . Osteoarthritis 24-2
Figure 24-2.1B . . Osteoarthritis 24-3
Figure 24-2.1C . . Joint Space Narrowing 24-3
Figure 24-2.1D . . Heberden Nodes in Osteoarthritis 24-3
Figure 24-2.2 . . . Distribution of Primary OA 24-4
Figure 24-3.1A . . Pannus Formation 24-6
Figure 24-3.1B . . Joints Involved in Rheumatoid Arthritis. 24-6
Figure 24-3.1C . . Nodules 24-8
Figure 24-3.1D . . Arthritis Mutilans 24-9
Figure 24-3.1E . . Clinical Course of RA 24-9
Figure 24-3.3A . . Ankylosing Spondyloarthritis 24-10
Figure 24-3.6 . . . Psoriatic Arthritis 24-11

Please visit us at www.Groupinsiders.com

© DeVry/Becker Educational Development Corp. All rights reserved.

Table of Contents

Pathology Figures

Figure 24-4.1A . . Uric Acid Synthetic Pathways. 24-12
Figure 24-4.1B . . Lab Test for Gout 24-13
Figure 24-4.1C . . Tophi 24-13
Figure 24-4.1D . . Pseudogout. 24-14
Figure 24-4.1E . . Calcium Pyrophosphate Deposition Positive Birefringence 24-14
Figure 24-5.2 . . . Septic Arthritis 24-15

Chapter 25 Bone Pathology

Figure 25-1.3 . . . Anatomy of a Bone 25-1
Figure 25-1.4A . . Compact Bone. 25-2
Figure 25-1.4B . . Cancellous/Spongy Bone 25-2
Figure 25-1.4C . . Lamellar Bone 25-2
Figure 25-1.5 . . . Origin of Bone Cells 25-3
Figure 25-1.6 . . . Osteocytes 25-3
Figure 25-2.1 . . . Achondroplasia 25-4
Figure 25-2.3 . . . Osteogenesis Imperfecta 25-5
Figure 25-2.4 . . . "Marble Bone" Disease 25-5
Figure 25-3.1A . . Osteoporosis 25-7
Figure 25-3.1B . . Osteoporosis/Thinning of Vertebrae 25-7
Figure 25-3.2 . . . Osteitis Fibrosa Cystica/Increased Osteoclastic Activity 25-8
Figure 25-3.3 . . . Osteomalacia 25-9
Figure 25-3.4A . . Rachitic Rosary 25-10
Figure 25-3.4B . . Rickets: Bowing of Legs 25-10
Figure 25-3.5 . . . Renal Osteodystrophy 25-10
Figure 25-3.6A . . First Stage 25-11
Figure 25-3.6B . . Third Stage. 25-11
Figure 25-4.2A . . Osteonecrosis 25-14
Figure 25-4.2B . . Blood Clot and Fracture Site Over Time 25-15
Figure 25-5.1A . . Osteomyelitis 25-16
Figure 25-5.1B . . Tuberculous Osteomyelitis. 25-17
Figure 25-6.3A . . Osteoid Osteoma 25-19
Figure 25-6.3B . . Osteosarcoma 25-19
Figure 25-7.0A . . Osteochondroma 25-20

Please visit us at www.Groupinsiders.com

© DeVry/Becker Educational Development Corp. All rights reserved.

Table of Contents

Pathology Figures

Figure 25-7.0B . . Enchondroma 25-20
Figure 25-7.0C . . Enchondroma 25-20
Figure 25-7.0D . . Tumors 25-21
Figure 25-8.1 . . . Fibrous Dysplasia 25-21
Figure 25-8.2 . . . Ewing Tumor 25-22

Chapter 26 Muscle Pathology

Figure 26-1.0A . . Skeletal Muscle Fiber (part 1) 26-1
Figure 26-1.0B . . Skeletal Muscle Fiber (part 2) 26-2
Figure 26-1.0C . . Skeletal Muscle Fiber (part 3) 26-2
Figure 26-2.1A . . Duchenne Muscular Dystrophy 26-3
Figure 26-2.1B . . Dystrophin 26-4
Figure 26-2.1C . . Duchenne Muscular Dystrophy/Variation in Muscle Fiber Size . . 26-4
Figure 26-2.3A . . Myotonic Dystrophy 26-5
Figure 26-2.3B . . Myotonic Dystrophy 26-6
Figure 26-3.1 . . . Diseases of Neuromuscular Junction 26-7
Figure 26-3.3 . . . Heliotrope Rash 26-8

Chapter 27 Soft Tissue Pathology

Figure 27-2.2 . . . Liposarcoma 27-1
Figure 27-3.2 . . . Superficial Fibromatosis 27-2
Figure 27-3.4 . . . Fibrosarcoma 27-2
Figure 27-4.1 . . . Benign Smooth Muscle Tumor 27-3
Figure 27-4.3 . . . Rhabdomyosarcoma 27-4

Chapter 28 Dermatopathology

Figure 25-1.1A . . Macroscopic Dermatology Findings 28-1
Figure 28-2.1A . . Verruca 28-3
Figure 28-2.1B . . Koilocytes 28-3
Figure 28-2.1C . . Molluscum Contagiosum 28-4
Figure 28-2.2A . . Impetigo Caused by *S. Pyogenes* 28-4
Figure 28-2.2B . . Acne Rosacea 28-5
Figure 28-2.3A . . Tinea Capitis 28-6
Figure 28-2.3B . . KOH Preparation for Wood Lamp 28-6

Please visit us at www.Groupinsiders.com

© DeVry/Becker Educational Development Corp. All rights reserved.

Table of Contents

Pathology Figures

Figure 28-2.3C . . Tinea Corporis 28-7
Figure 28-2.3D . . Tinea Versicolor 28-8
Figure 28-2.3E . . Sporotrichosis 28-9
Figure 28-3.1A . . Erythema Multiforme 28-10
Figure 28-3.1B . . Urticaria (Hives) 28-10
Figure 28-3.3A . . Psoriasis: Pitting of Nails 28-11
Figure 28-3.3B . . Psoriasis 28-11
Figure 28-3.4 . . . A Lichen Planus 28-12
Figure 28-3.5A . . Pemphigus Vulgaris 28-12
Figure 28-3.5B . . Bullous Pemphigoid 28-13
Figure 28-3.5C . . Vesicolobullous Dermatitis 28-13
Figure 28-3.6 . . . Erythema Nodosum 28-13
Figure 28-4.1A . . Junctional Nevus 28-14
Figure 28-4.1B . . Compound Nevus. 28-14
Figure 28-4.1C . . Intradermal Nevus 28-15
Figure 28-4.1D . . Seborrheic Keratosis 28-15
Figure 28-4.2 . . . Actinic Keratosis 28-16
Figure 28-4.3A . . Basal Cell Carcinoma 28-16
Figure 28-4.3B . . Squamous Cell Carcinoma 28-17
Figure 28-4.4A . . Superficial Spreading Melanoma 28-18
Figure 28-4.4B . . Lentigo Maligna Melanoma 28-18
Figure 28-4.4C . . Nodular Melanoma 28-18
Figure 28-4.4D . . Acral Lentiginous Melanoma 28-18

Please visit us at www.Groupinsiders.com

© DeVry/Becker Educational Development Corp. All rights reserved.

Table of Contents

Pathology Tables

Chapter 1 Cellular Pathophysiology

Table 1-2.0 . . . . Oxygen (O_2) Content 1-3
Table 1-2.3 . . . . Causes of Hypoxia 1-17
Table 1-3.2 . . . . Free Radical Formation 1-20
Table 1-3.3 . . . . Free Radical Neutralization 1-21
Table 1-5.3 . . . . Causes of Atrophy 1-28
Table 1-5.4 . . . . Causes of Metaplasia 1-29
Table 1-6.6 . . . . Types of Necrosis 1-33

Chapter 2 The Inflammatory Reaction

Table 2-2.1 . . . . Chemotaxins 2-6

Chapter 3 Tissue Repair and Wound Healing

Table 3-4.0 . . . . Collagen Types 3-7

Chapter 4 Hemodynamics

Table 4-2.1A . . . Use of Bleeding Parameters in Diagnosis. 49
Table 4-2.1B . . . Diagnostic Parameters of Bleeding 4-9
Table 4-8.4 . . . . Shock Differentials. 4-18

Chapter 5 Neoplasia

Table 5-1.1 . . . . Benign vs. Malignant Neoplasms 5-1
Table 5-1.2 . . . . Names for Benign and Malignant Neoplasms 5-1
Table 5-1.4 . . . . Sarcomas 5-3
Table 5-2.1A . . . DNA Damaging Chemicals. 5-5
Table 5-2.1B . . . Radiation and Associated Cancers 5-5
Table 5-2.2A . . . Oncogenes Affecting Growth Factors 5-7
Table 5-2.2B . . . Oncogenes Affecting Signal Transduction 5-8
Table 5-2.2C . . . Oncogenes Affecting Cell Cycle Regulation 5-8
Table 5-2.3 . . . . Inactivation of Tumor Suppressor Genes. 5-10
Table 5-3.1 . . . . Cancer Incidence and Mortality in Adults 5-15
Table 5-4.2 . . . . Serum Tumor Markers 5-16
Table 5-4.3 . . . . Immunohistochemistry. 5-16
Table 5-5.1 . . . . Paraneoplastic Syndromes 5-17
Table 5-5.2 . . . . Paraneoplastic Endocrinopathies 5-17

Please visit us at www.Groupinsiders.com

© DeVry/Becker Educational Development Corp. All rights reserved.

Table of Contents

Pathology Tables

Chapter 6 Red Blood Cell Pathology

Table 6-3.2A . . . α-Thalassemia Genotype Expression 6-11
Table 6-3.2B . . . β-Thalassemia Genotype Expression 6-12
Table 6-3.3 . . . . Microcytic Anemias 6-14
Table 6-4.1 . . . . Vitamin B12 Deficiency 6-15
Table 6-4.2 . . . . Folic Acid Deficiency 6-16
Table 6-4.3 . . . . Clinical Features and Laboratory Findings 6-17
Table 6-7.4 . . . . Differentials of Polycythemia 6-32
Table 6-7.5 . . . . Types of Polycythemia 6-32

Chapter 7 White Blood Cell Pathology

Table 7-4.0 . . . . Leukemias 7-6
Table 7-4.1 . . . . Onset of Leukemias 7-8
Table 7-4.2 . . . . Indications of Leukemias 7-12

Chapter 8 Lymphoid Pathology

Table 8-2.4A . . . Ann Arbor Classification of Tumor Staging 8-3
Table 8-2.4B . . . Characteristics of Subtypes 8-5
Table 8-2.5 . . . . Hodgkin vs. Non-Hodgkin 8-8

Chapter 9 Immunohematology

Table 9-1.5 . . . . Parental-Fetal Blood Group Combinations With Viability Options . . 9-1

Chapter 11 Cardiovascular Pathology

Table 11-1.0 . . . Hypertension 11-1
Table 11-3.4 . . . Hyperlipoproteinemias 11-8

Chapter 12 Pulmonary Pathology

Table 12-6.2 . . . Typical Pneumonia Pathogens 12-16

Chapter 13 Renal Pathology

Table 13-2.5 . . . Acute Renal Failure 13-10

Please visit us at www.Groupinsiders.com

© DeVry/Becker Educational Development Corp. All rights reserved.

Table of Contents

Pathology Tables

Chapter 14 Gastrointestinal (GI) Pathology

Table 14-3.5 . . . Neoplastic Diseases 14-5
Table 14-5.0 . . . Hemorrhagic Gastritis. 14-8
Table 14-5.1 . . . Gastric and Duodenal Ulcers 14-9
Table 14-5.3 . . . Small Bowel Obstruction vs. Small Bowel Infarction 14-14
Table 14-6.0A . . Types and Characteristics of Diarrhea. 14-16
Table 14-6.0B . . Pathogens and Diarrhea 14-16
Table 14-7.0 . . . Malabsorption Syndromes. 14-22
Table 14-9.0 . . . Ulcerative Colitis vs. Crohn Disease 14-24
Table 14-12.1A . Duke Classifications 14-28
Table 14-12.1B . Right-Sided Colorectal Cancer vs. Left-Sided Colorectal Cancer. . 14-29

Chapter 15 Hepatobiliary Pathology

Table 15-1.1 . . . Liver Function Tests (LTFs) 15-4
Table 15-4.1 . . . Viral Hepatitis 15-12

Chapter 17 Male Reproductive Pathology

Table 17-4.0A . . Testicular Tumors: Germ Cell Tumors 17-6
Table 17-4.0B . . Comparison Features 17-7
Table 17-4.0C . . Non-Germ Cell Tumors 17-7
Table 17-6.2 . . . Common Abnormalities 17-13

Chapter 18 Female Reproductive Pathology

Table 18-7.0 . . . Hirsutism vs. Virilization 18-12
Table 18-8.3 . . . Causes of Abnormal Bleeding by Age 18-15
Table 18-8.4 . . . Differentials of Amenorrhea 18-16
Table 18-11.2 . . Classification of Ovarian Tumors 18-22
Table 18-13.0 . . Sexually Transmitted Diseases and Genital Infections. 18-27
Table 18-15.1 . . Nipple Discharge Type 18-32
Table 18-18.0 . . Types of Breast Cancer. 18-35

Please visit us at www.Groupinsiders.com

© DeVry/Becker Educational Development Corp. All rights reserved.

Table of Contents

Pathology Tables

Chapter 19 Endocrine Pathology

Table 19-1.0A . . Cell Surface Receptors: Downstream Mechanisms 19-2
Table 19-1.0B . . Steroid Homone Receptors 19-2
Table 19-3.3 . . . Pituitary Apoplexy and Sheehan Syndrome 19-8
Table 19-3.4 . . . Prolactin Pharmacology 19-9
Table 19-4.3 . . . Summary of Thyroid Disorders 19-15
Table 19-4.4A . . Thyroid Function Tests During Pregnancy 19-17
Table 19-4.4B . . Diagnostic Tests. 19-17
Table 19-5.3 . . . Congenital Adrenal Hyperplasia 19-31
Table 19-6.1 . . . Pancreatic Islet Cells 19-33
Table 19-6.2 . . . Endogenous vs. Exogenous Insulin 19-36
Table 19-6.3A . . Osmolarity Changes Found in Diabetes Mellitus 19-41
Table 19-6.3B . . Summary of Type I and Type II Diabetes 19-42
Table 19-6.3C . . Classification of Diabetic Retinopathy 19-45

Chapter 20 Central Nervous System Pathology

Table 20-5.4 . . . Motor Neuron Signs 20-14
Table 20-7.6A . . Posterior Circulation Deficits 20-27

Chapter 22 Optic Pathology

Table 22-5.0 . . . Granulomatous vs. Nongranulomatous Uveitis. 22-6

Chapter 23 Connective Tissue Disorders

Table 23-1.4 . . . Summary of Collagen Disorders. 23-5

Chapter 24 Joint Pathology

Table 24-2.2 . . . Diseases Affecting Joints. 24-4

Chapter 25 Bone Pathology

Table 25-3.1 . . . Osteoclastogenesis 25-6
Table 25-3.3 . . . Characteristics of Vitamin D Deficiency. 25-9
Table 25-3.5 . . . Osteoporosis and Osteomalacia 25-10
Table 25-3.6A . . Stages of Paget Disease 25-11

Please visit us at www.Groupinsiders.com

© DeVry/Becker Educational Development Corp. All rights reserved.

Table of Contents

Pathology Tables

Table 25-3.6B . . Expected Lab Findings in Metabolic Bone Disease 25-12
Table 25-5.1 . . . Osteomyelitis 25-16
Table 25-6.2 . . . Benign Bone-Forming Tumors 25-18
Table 25-7.0 . . . Cartilage Forming Tumors 25-20

Chapter 26 Muscle Pathology
Table 26-1.0 . . . Muscle Twitch 26-1

Chapter 27 Soft Tissue Pathology
Table 27-1.0 . . . Connective Tissue Tumors 27-1

Please visit us at www.Groupinsiders.com

© DeVry/Becker Educational Development Corp. All rights reserved.

Unit 3

Cardiovascular Pathology

Please visit us at www.Groupinsiders.com

Please visit us at www.Groupinsiders.com

1 Heart Failure

Heart failure is any cause of heart dysfunction that keeps the heart from pumping enough blood to meet the metabolic needs of tissues in the body. Commonly in heart failure, the left ventricle is unable to eject volume of blood into the aorta, resulting in increased left ventricular end-diastolic volume and pressure (LVEDV and LVEDP, respectively). Heart failure is a common end point of many different cardiac diseases. Heart failure can be divided into left- and right-sided heart failure.

1.1 Left-Sided Heart Failure

Left-sided heart failure has a variety of causes, but usually can be broken into five categories.

1.1.1 Etiology of Congestive Heart Failure (CHF)

- **Cardiac Muscle Loss (Ischemia/Infarction):**
  - Most common cause of CHF.
  - Lack of blood supply (ischemia) to cardiomyocytes secondary to myocardial infarction may result in coagulative necrosis.
- **Pressure Overload:** The cardiomyocyte consistently functions at a higher level of contractility to achieve the same amount of cardiac output (CO) as prior, resulting in eventual heart failure.
  - **Hypertension:** Pressure overload can be caused by *hypertension* because it forces the heart to pump against high arterial pressures.
  - **Aortic Stenosis:** Ventricular pressure must increase dramatically to overcome the increased afterload that is created by aortic stenosis, resulting in pressure overload.
- **Volume Overload:** Volume overload can cause left-sided heart failure if an abundance of blood on the left side of the heart overloads the left atrium and ventricle.
  - **Mitral Regurgitation:** One cause of volume overload is *mitral regurgitation* because this causes blood to flow back into the left atrium during systole.
  - **High Output:** The other main cause of volume overload is *high output failure*, which can be seen in patients with severe anemia or thyrotoxicosis.
- **Loss of Contractility:** Impaired muscle contractility may result in congestive heart failure.
  - **Toxicity:** Alcohol and chemotherapeutic drugs, such as doxorubicin, may be toxic to cardiomyocytes.
  - **Infectious Myocarditis:** Adenovirus, amastigotes phase in Chagas, diphtheria, and rheumatic fever; may cause cardiac injury.

USMLE® Key Concepts

For Step 1, you must be able to:

- Differentiate between left- and right-sided heart failure.
- Explain the various types of ischemic heart disease and their complications.
- Identify various types of cardiomyopathy, valvular heart disease, endocarditis, congenital heart disease, and pericardial diseases.

Please visit us at www.Groupinsiders.com

© DeVry/Becker Educational Development Corp. All rights reserved.

- **Restricted Filling:** Impaired filling of the left side of the heart may cause heart failure.
  - **Mitral Stenosis:** Mitral stenosis impairs the filling of the left ventricle during early diastole, resulting in congestion proximally.
  - **Pericarditis/Tamponade:** Inflammation of the pericardium or filling of the pericardial cavity with fluid (secondary to rupture of ventricular aneurysm post-MI) may restrict filling of the cardiac chambers.
  - **Infiltration:** Infiltrative conditions, such as hemochromatosis and/or amyloidosis, restrict cardiac filling.

1.1.2 Left-Sided Heart Failure Patients Present With a Greater Array of *Symptoms* Than Signs

- **Dyspnea:**
  - **Paroxysmal Nocturnal Dyspnea:** Stimulation of J receptors in interstitium resulting in a sudden feeling of gasping of air, usually at night.
  - **Orthopnea:** Fluid overload in left ventrical when lying down; use of pillows, sitting, or standing relieves the dyspnea.

1.1.3 *Signs* of Left-Sided Heart Failure

- **Inspiratory Crackles/Rales:** Pulmonary edema secondary to left-sided heart failure.
- **S3/S4 Heart Sounds on Auscultation:**
  - Sudden diastolic volume overload of the left ventricle.
  - Diastolic filling of a left ventricle that is already full of blood from inadequate ejection of blood from the preceding "beat's" lack of contraction.
- **Mitral Regurgitation:** Stretching of the mitral valve, resulting in a holosystolic murmur upon auscultation.
- **Congestion on Chest X-Ray:**
  - Laterally displaced point of maximal impulse
  - Pale, cool skin

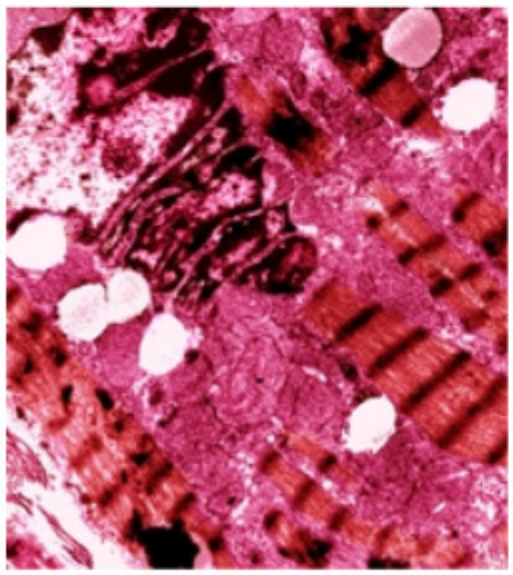

R.D.R./Custom Medical Stock Photo

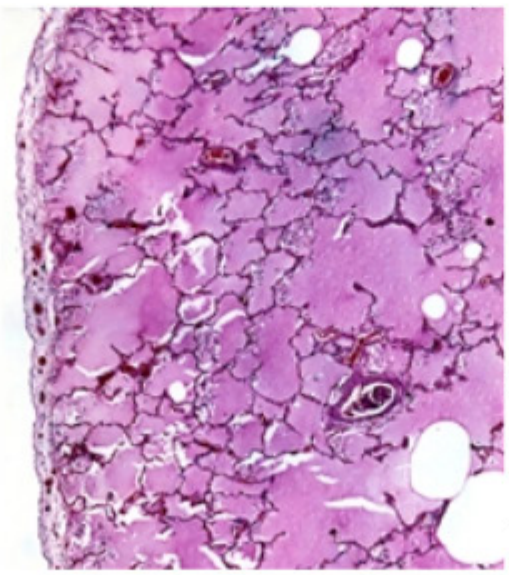

Biophoto Associates/Science Source

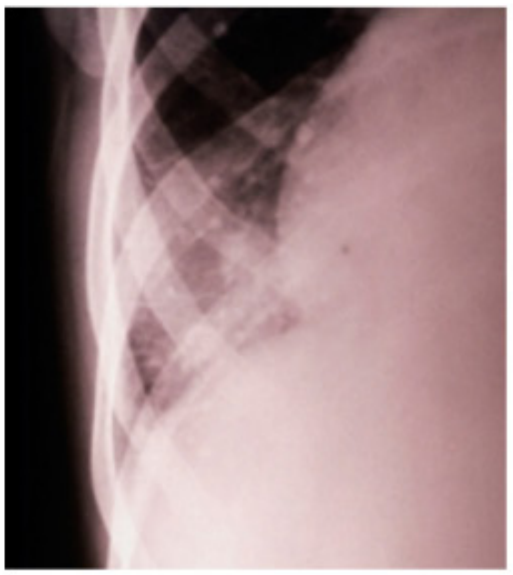

Wellcome Images

▲ **Figure 10–1.1A** Left-Sided Heart Failure, Microscopic

Please visit us at www.Groupinsiders.com

© DeVry/Becker Educational Development Corp. All rights reserved.

1.1.4 Pathophysiology of Ejection Fraction (EF)

- **EF = SV/EDV**
  - Derivation of EF from Stroke volume = End diastolic volume (EDV)−End systolic volume (ESV).
  - Normal ejection fraction is a percentage of approximately 55% to 65% < 50% EF is problematic.
  - *EF does not always have to be decreased to be suggestive of CHF* (see topic 1.1.6, Diastolic Dysfunction).

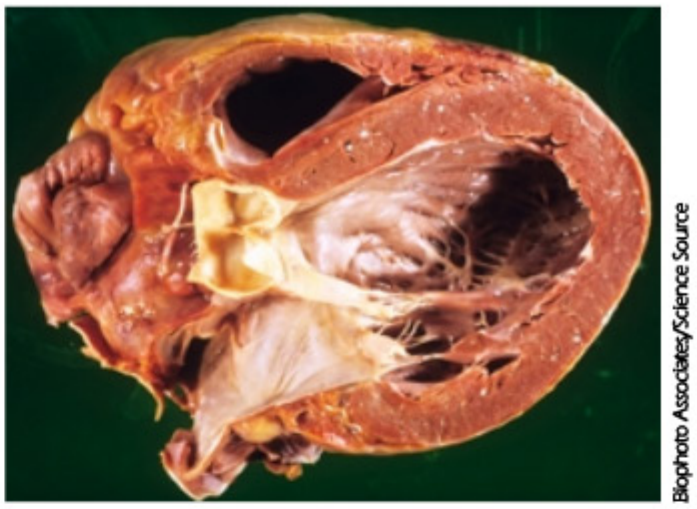
Biophoto Associates/Science Source

▲ **Figure 10–1.1B** Left-Sided Heart Failure Forward Failure

1.1.5 Systolic Dysfunction → Effects of Increased Preload on the Heart

- Frank-Starling relationship states that a certain amount of preload (length) will generate a certain amount of tension (inotropy).

  In CHF, overstretching of muscle fibers results in poor cardiac output; this is called *systolic dysfunction.*
- **Systolic Dysfunction Manifestations:** The overstretching of the left ventricle results in a type of hypertrophy referred to as eccentric. Eccentric hypertrophy represents a slight thickening of the left ventricular wall in a series-type of duplication resulting in a systolic type of dysfunction with a decreased percentage of ejection fraction.

1.1.6 Diastolic Dysfunction → Effects of Increased Afterload on the Heart

Isotonic contraction is the force that must be generated to overcome resistance encountered while ejecting blood.

- **Afterload Indices:** These indices include *systolic wall tension*, *aortic pressure*, and *left ventricular systolic pressure*. Utilizing the Laplace law in the setting of aortic stenosis (AS), the equation states:

  Wall stress (σ) = Wall tension (T)/Wall thickness (h).

  When wall stress increases as a result of increased left ventricular (LV) pressure (tension) secondary to aortic stenosis (AS), one notes that by thickening the ventricular wall (h), the stress would be reduced. A process occurs known as *concentric hypertrophy* in which cardiac muscle is duplicated in a parallel arrangement. This parallel duplication would result in the longrun with diastolic dysfunction demonstrating a normal percentage of ejection fraction.

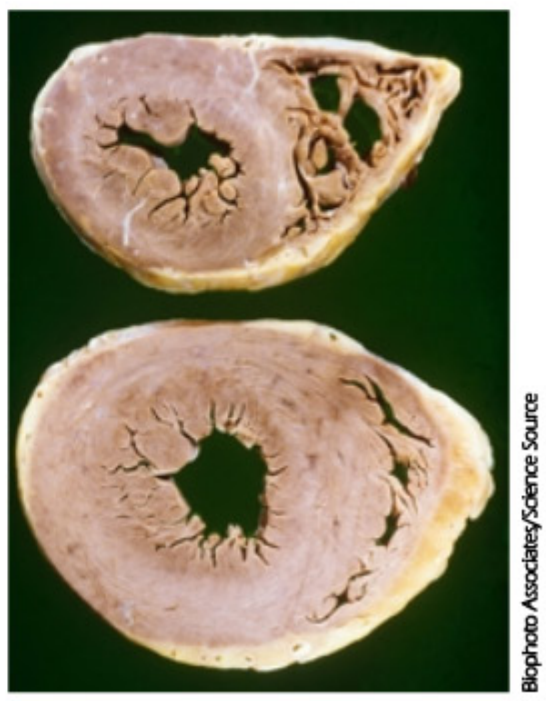
Biophoto Associates/Science Source

▶ **Figure 10–1.1C** Left-Sided Heart Failure

Please visit us at www.Groupinsiders.com

© DeVry/Becker Educational Development Corp. All rights reserved.

1.1.7 Non-compliant Ventricle

This is considered left-sided heart failure due to increased afterload, as seen with essential hypertension (HTN), aortic stenosis, or hypertrophic cardiomyopathy. The adaptive process as seen with the Laplace law results in concentric hypertrophy with very little space left in the chamber for filling of the left ventricle during diastole.

Diastolic Dysfunction Findings

- **Ejection Fraction Is Preserved:** This is not like systolic dysfunction, which is caused by volume overload and overstretching. In diastolic dysfunction, the cardiac output is preserved because of the increase in muscle strength. Only the ventricular filling is compromised.
- **Left Atrial Enlargement:** Decreased ventricular space results in blood backing up into the left atrium.
- **Right-Sided Heart Failure:** Long-standing ventricular resistance results in pulmonary edema and hypertension, and eventual right-sided heart failure (this is, however, not referred to as *cor pulmonale*).
- **Angina:** Concentric hypertrophy, and thus increased muscle mass, results in increased demand of O_2 to the tissue which cannot be met; the result is ischemia and angina.
- **Fourth Heart Sound (S4):** The decreased compliance ("stiff") of the left ventricle makes it difficult for late diastolic filling ("atrial kick") to occur, resulting in a fourth heart sound.

1.1.8 Pulmonary Capillary Wedge Pressure (PCWP)

- This test may be used to estimate the left atrial pressure without entering the high-pressure arterial circulation. It is useful for diagnosis of left-sided heart failure when the pressure in the left side of the heart is increased, causing increased pressure in the pulmonary veins and eventually the pulmonary capillaries.
- In this procedure, a ballooned pressure catheter is inserted through the superior or inferior vena cava entering into the right atrium, right ventricle, and pulmonary artery, and then "wedged" into the branched pulmonary artery. This probe then measures the pressure downstream, which is elevated in left-sided heart failure.

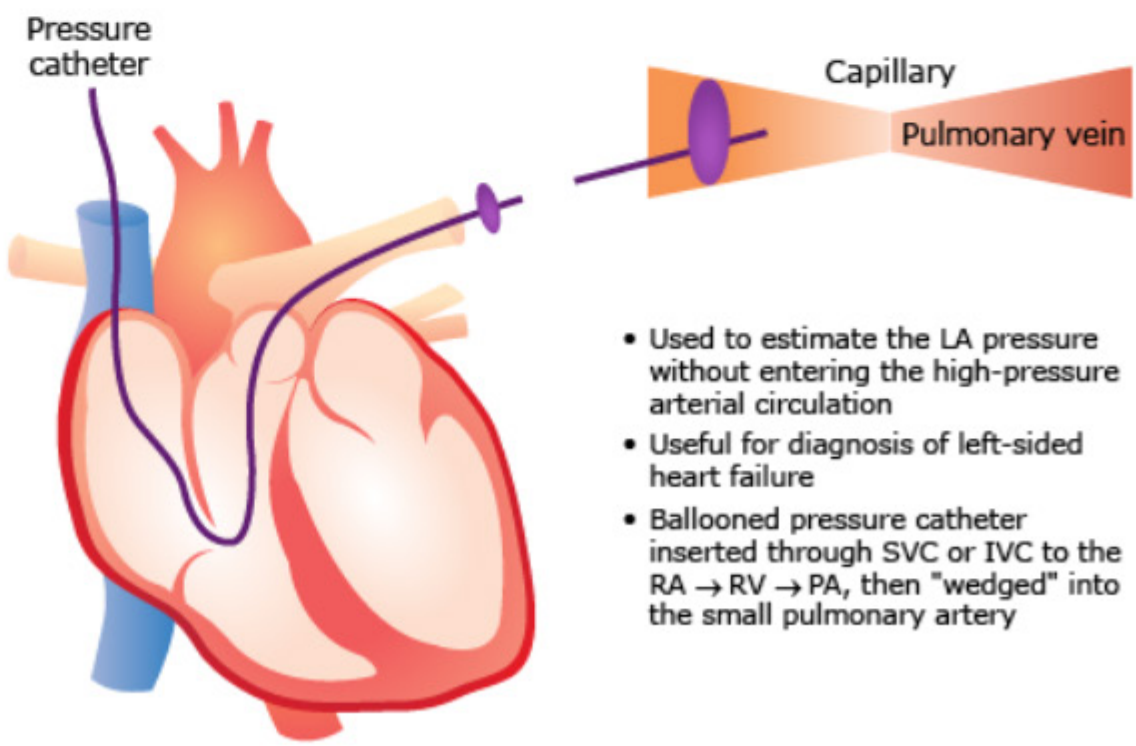

▲ **Figure 10–1.1D** Pulmonary Capillary Wedge Pressure (PCWP)

Please visit us at www.Groupinsiders.com

© DeVry/Becker Educational Development Corp. All rights reserved.

1.1.9 Cardiovascular Function of CHF

This is a high-yield cardiovascular function curve for CHF. Point A is the normal operating point of both curves. Point B is the decreased cardiac performance without compensation. Point C is the adrenergic system that has been activated as a compensatory mechanism. Point D is beyond the point of return and called decompensated heart failure. The acronyms labeled mean the following:

Vol = volume

C_v = venous compliance

SVR = systemic vascular resistance (TPR)

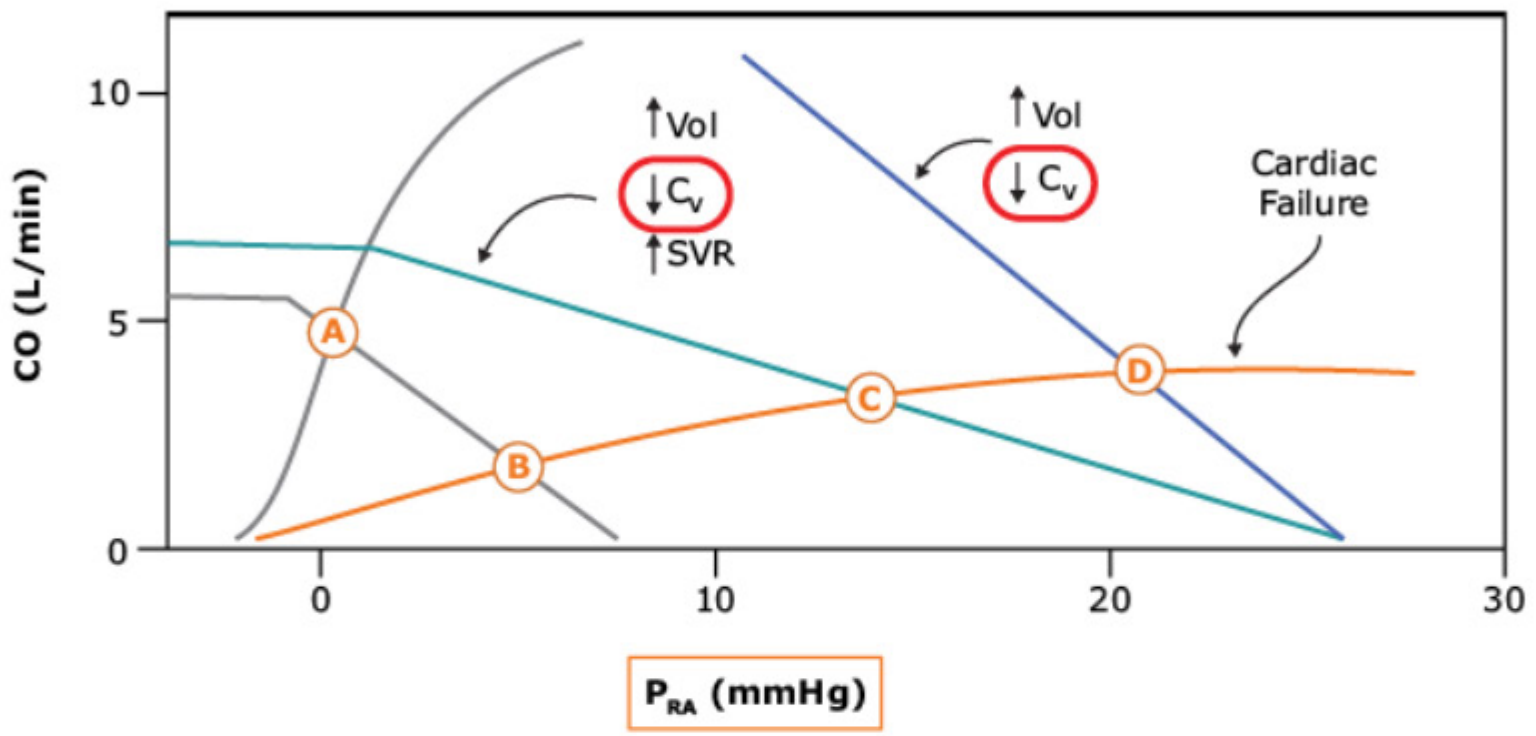

Changes in CO and RAP = P_{RA} in response to cardiac failure and compensatory increases in volume and SVR, and decreased venous compliance (C_v)

A = normal operating point
B = decreased cardiac performance
C = **compensatory** increase in SVR coupled with increased Vol and reduced C_v
D = **decompensated** heart failure ➔ increased P_{RA} and Vol and decrease in C_v

▲ **Figure 10–1.1E** Cardiovascular Function Curves: CHF

1.2 Right-Sided Heart Failure

The most common cause of right-sided heart failure is left-sided heart failure. The blood flow "backs up" into systemic venous circulation.

1.2.1 Pulmonary Hypertension

This is a primary disorder of the pulmonary bed resulting in pulmonary hypertension.

Secondary to Chronic Pulmonary Disease When the pulmonary hypertension creates an increase in right-side afterload, this may eventually lead to right-sided heart failure diagnosed as cor pulmonale.

Please visit us at www.Groupinsiders.com

© DeVry/Becker Educational Development Corp. All rights reserved.

1.2.2 Pathogenesis

Right-sided failure can cause signs and symptoms due to congestion in the central venous system. This includes jugular venous distension (JVD), tricuspid regurgitation, ascites, anasarca, and signs of congestive hepatomegaly, which include a "nutmeg liver" (microscopically, red central areas surrounded by normal brown liver tissue) and a "hepatojugular reflux."

1.2.3 Jugular Venous Distension (JVD)

JVD is analogous to the effects of right atrial pressure. It should be measured as the perpendicular height of visual pulse from the level of the right atrium. Because of the increased pressures in the right atrium due to failure of forward contraction, elevated "cannon a" and perhaps "v" waves may be seen.

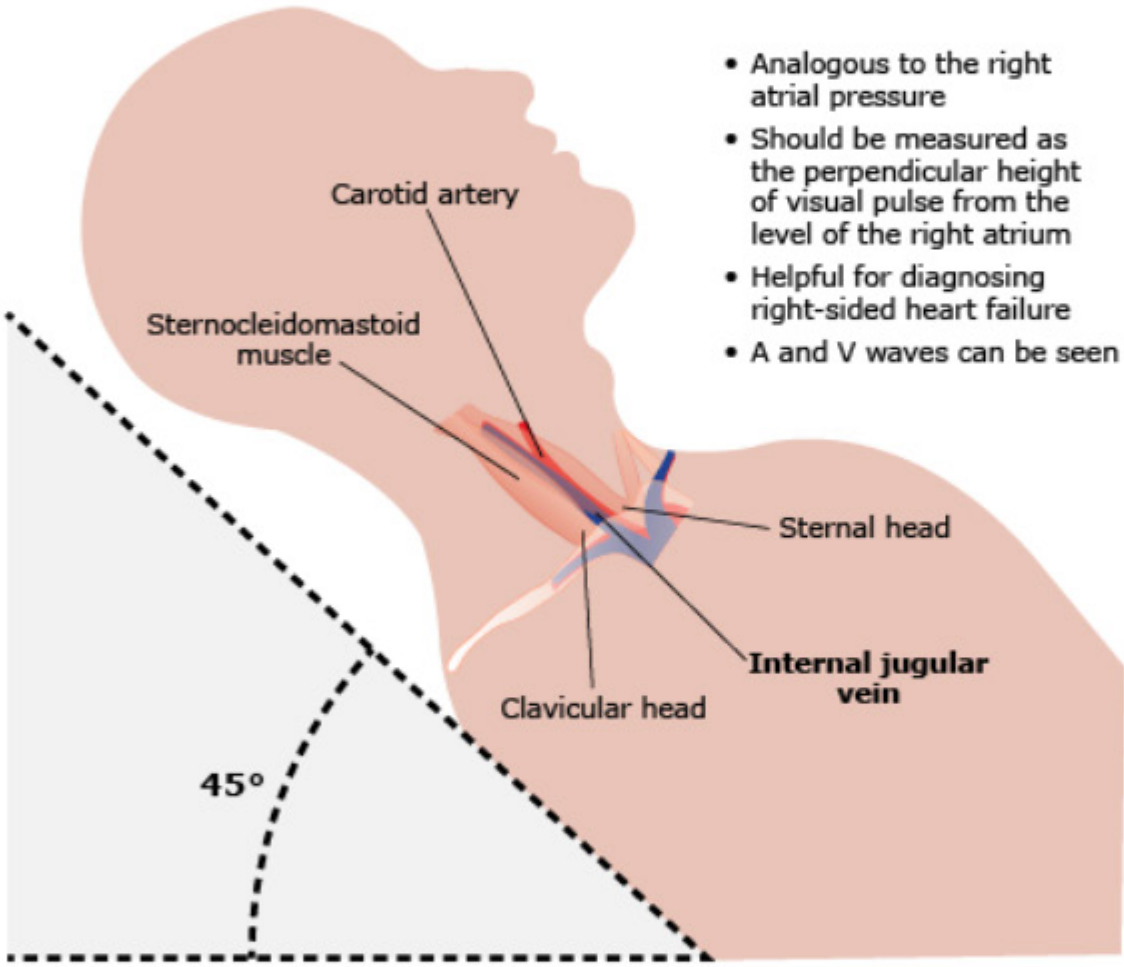

▲ **Figure 10–1.2A** Jugular Venous Pulse

When pressure is applied to the RVQ location in the liver, there is distension of the jugular veins.

Please visit us at www.Groupinsiders.com

© DeVry/Becker Educational Development Corp. All rights reserved.

1.2.4 Morphology

JVD of the internal jugular vein can be seen. Pitting edema (transudate) and centrilobular hemorrhagic necrosis may be seen due to right-sided failure and, therefore, backup into these tissues.

Dr. Allan Harris/Phototake, Inc.

Dr. P. Marazzi/Science Source

▲ **Figure 10–1.2B** Right-Sided Heart Failure

1.2.5 Right Atrial Tracing (RAT)

Normal tracings, including an RAT, heart sounds, and ECG on the *left,* compared with the *right,* which is an RAT of right-sided heart failure depicting a "cannon 'a' wave" representing JVD.

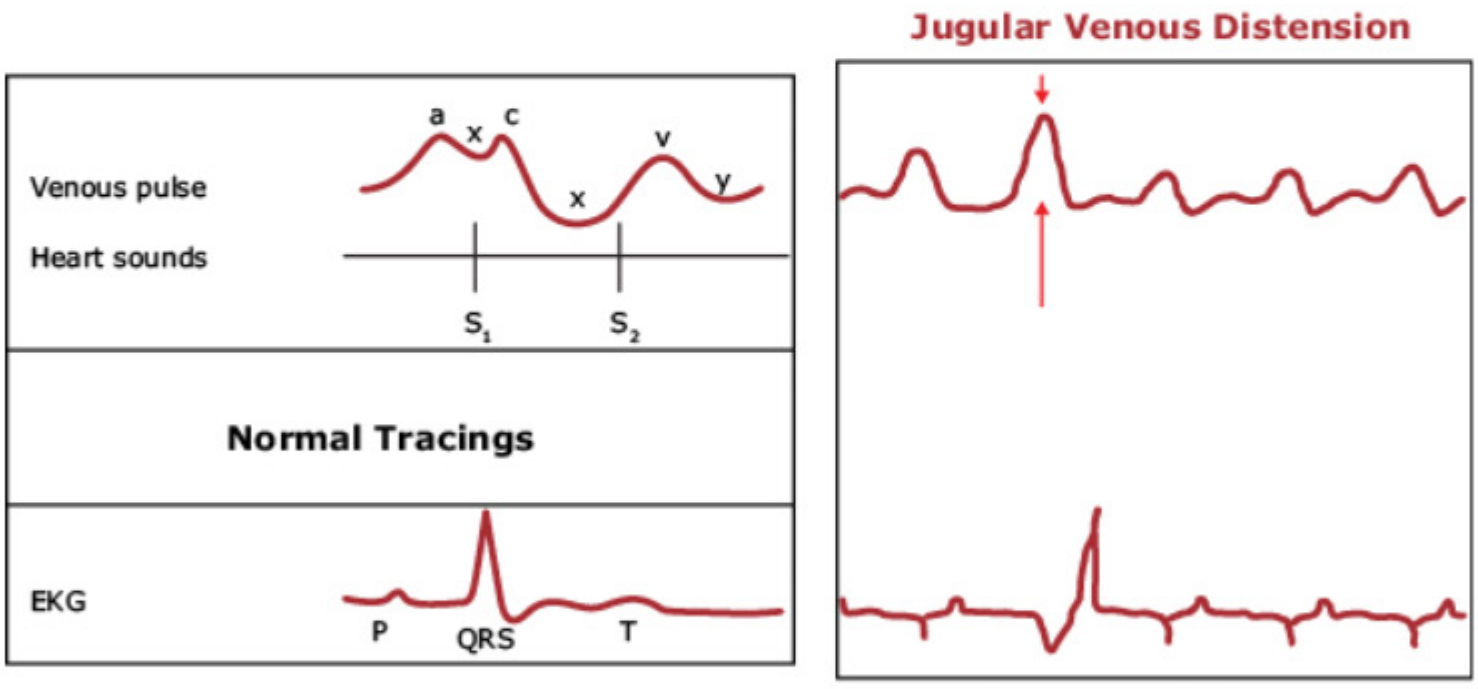

▲ **Figure 10–1.2C** Right Atrial Tracing

Please visit us at www.Groupinsiders.com

© DeVry/Becker Educational Development Corp. All rights reserved.

2 Ischemic Heart Disease

Ischemic heart disease is the result of cardiac perfusion (oxygen) demand not being met by cardiac circulation. Ischemic heart disease can be divided into two different causes: increased demand and decreased supply. The first variety *(increased demand)* is more common in patients with an increased heart rate or with high blood pressure. The second cause is *decreased blood supply*, which can occur when the coronary arteries are narrowed, either as a result of *coronary artery disease* or *vasopasm*.

2.1 Risk Factors

It is very important to know the risk factors for heart disease.

2.1.1 Age/Gender

Age is a risk factor, as is gender. Men have an increased risk from the age 45 onward, whereas women have increased risk from the age of 55 onward—this delayed risk is mostly due to the beneficial effects of estrogen.

2.1.2 Family History

Family history of early coronary artery disease secondary to atherosclerotic disease.

2.1.3 Preventable Risk Factors

Those which are *preventable* are *smoking*, *hypertension* (greater than 140/90), *hyperlipidemia* (LDL >160, HDL <35), and *diabetes mellitus*, often collectively called *metabolic syndrome*.

2.2 Pathogenesis

There are four main types of ischemic heart disease: Stable angina, variant (or *Prinzmetal*) angina, unstable angina, and myocardial infarction.

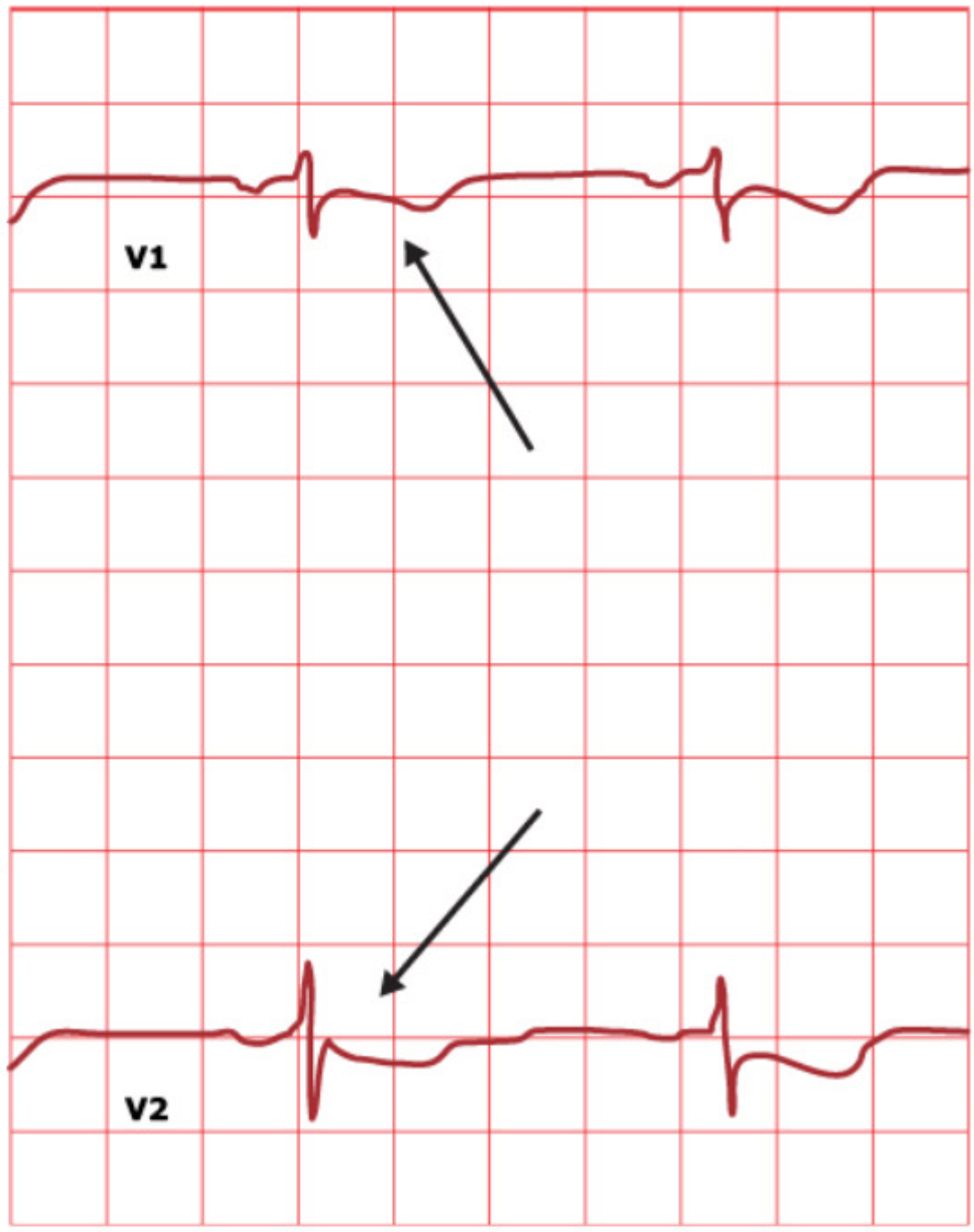

▲ **Figure 10–2.2A** Ischemic Heart Disease: Stable Angina

2.2.1 Stable Angina

Stable angina occurs due to *fixed narrowing* of the coronary arteries, typically due to *atherosclerosis*. The hallmark of stable angina is *chest pain with exertion*, as this increases oxygen demand. Catecholamine-rich states can also cause chest pain in stable angina. The other main feature is that stable angina *improves with rest*.

Please visit us at www.Groupinsiders.com

© DeVry/Becker Educational Development Corp. All rights reserved.

Clinical Application

Treatment

The main treatment for angina is to either *increase blood flow* (using nitrates and calcium channel blockers) or by *decreasing demand* (using beta-blockers). An acute myocardial infarction is treated with rapid revascularization to save as much myocardial tissue as possible. This includes *antiplatelet agents* (such as aspirin), *thrombolytics* (such as tPA and streptokinase), *percutaneous transluminal coronary angioplasty with stent* (to reopen blood vessels), and *coronary artery bypass grafting* (especially for patients with three-vessel disease or left main artery coronary disease).

2.2.2 Variant Angina

Variant (Prinzmetal) angina is caused by vasospasm of the coronary arteries, so it is often idiopathic. One of the few known causes of variant angina is *cocaine use*, which can also increase the cardiac oxygen demand; as a side note, chronic cocaine use can also predispose users to atherosclerosis.

2.2.3 Unstable Angina

Unstable angina is marked by severe coronary artery disease that also develops *transient or non-occlusive thrombosis*. Unstable angina typically causes *ischemic damage to the subendocardial tissue*, as this is the "end of the oxygen supply line." One of the ways that unstable angina differs from the other forms of angina is that it causes symptoms that *progress* or *crescendo* over time. Patients also develop *symptoms at rest*.

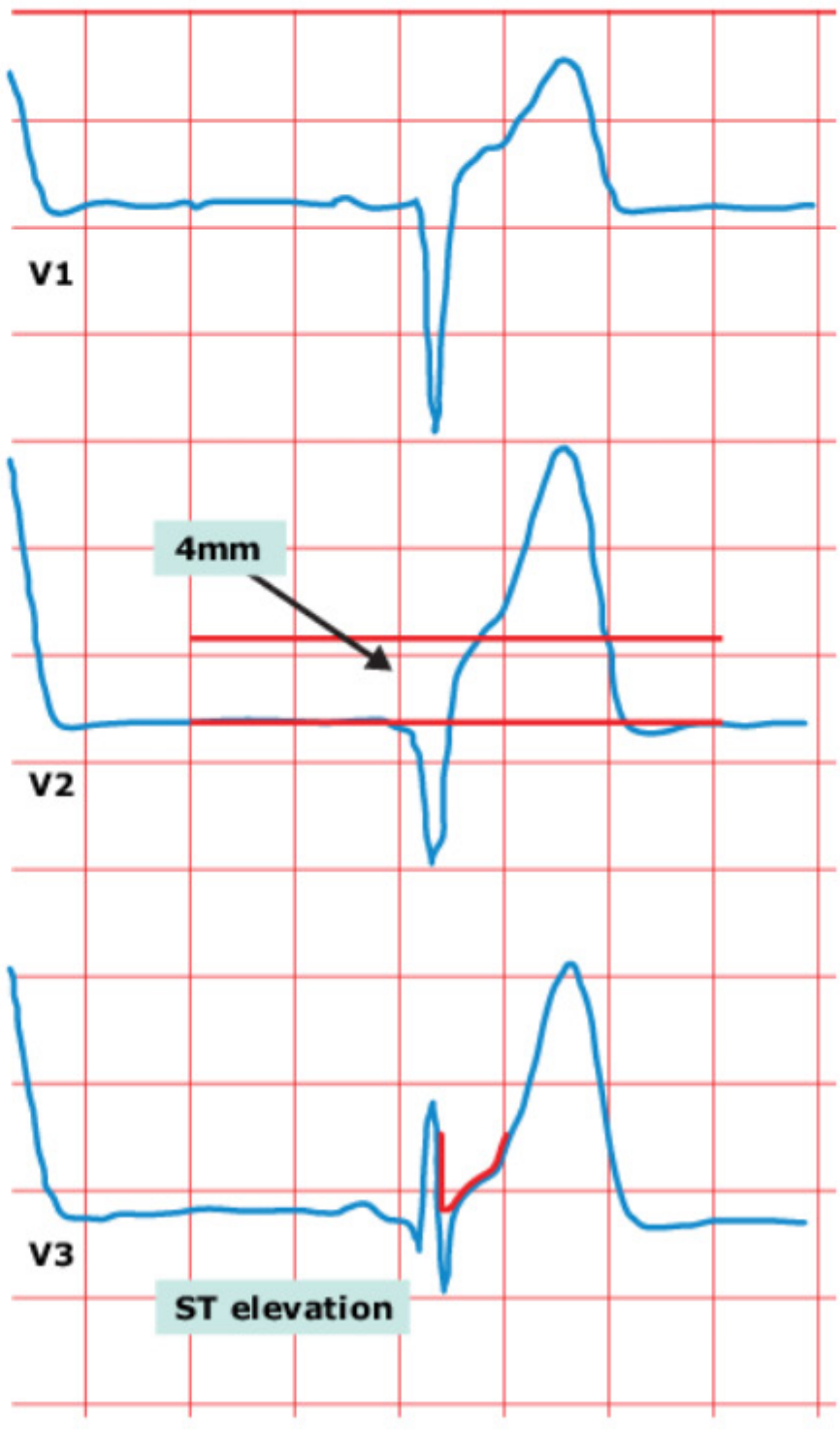

▶ **Figure 10–2.2B** Ischemic Heart Disease: Variant (Prinzmetal) Angina

Please visit us at www.Groupinsiders.com

© DeVry/Becker Educational Development Corp. All rights reserved.

2.2.4 Myocardial Infarction (MI)

Myocardial infarction is the most severe form of ischemic heart disease and is marked by *complete occlusion of a coronary artery*. The most common cause is the *rupture of an atherosclerotic plaque*. When a plaque ruptures, the underlying endothelium is exposed, resulting in *platelet aggregation* and the *formation of a thrombus*, which will occlude the artery.

Subendocardial infarction will take place only when the interior one third of the cardiac wall is infarcted, most commonly resulting as non-Q-wave MI. Total occlusion of a coronary vessel causes *transmural* ischemia. This is seen as Q waves on an ECG. Within seconds, the affected cells are *depleted of ATP*. Within minutes, there is *reversible contractility loss*. Within the first 20 to 40 minutes, *irreversible injury* begins to accumulate.

- Caused by complete occlusion of coronary artery
- Most commonly caused by rupture of an atherosclerotic plaque
- Exposed subepithelium leads to platelet aggregation and thrombus formation, which occludes the artery

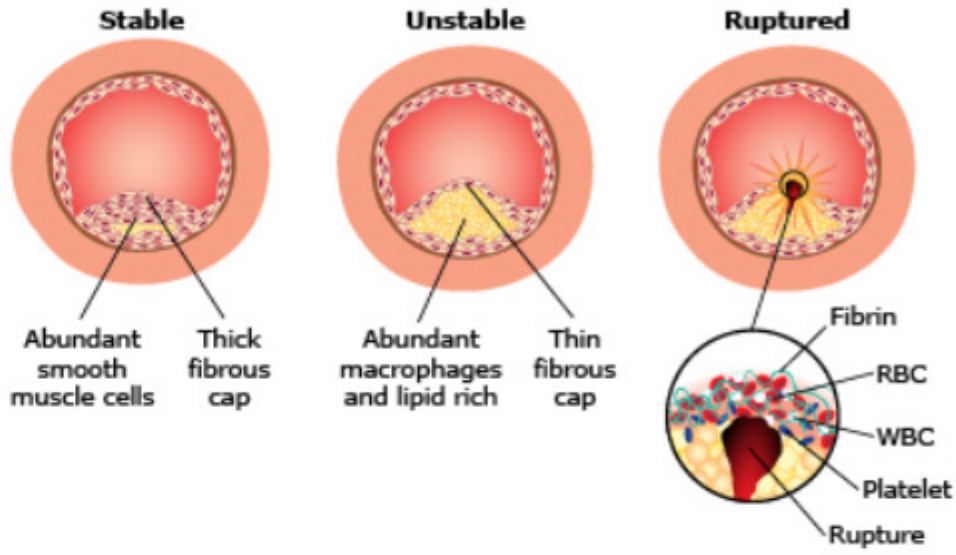

▲ **Figure 10–2.2C** Ischemic Heart Disease: Myocardial Infarction

A second phase of cardiac injury, known as *reperfusion injury (discussed below),* occurs with *revascularization* of the affected areas of the heart and is mediated by *reactive oxygen species* (or free radicals).

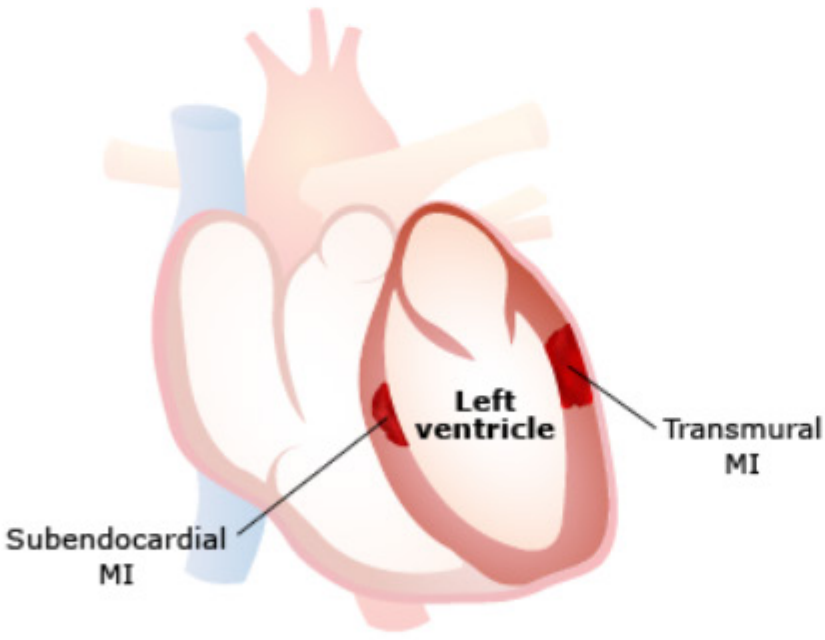

- Two myocardial infarction patterns:
  - Subendocardial:
    - Only interior 1/3 of cardiac muscle wall impacted
    - No Q-waves on ECG
  - Transmural:
    - Full myocardial thickness infarction
    - Q-waves on ECG

▲ **Figure 10–2.2D** Ischemic Heart Disease: Myocardial Infarction

Please visit us at www.Groupinsiders.com

© DeVry/Becker Educational Development Corp. All rights reserved.

▲ **Figure 10–2.2E** Ischemic Heart Disease: Myocardial Infarction

Reperfusion Injury If reperfusion occurs <3 hours after cessation of blood flow, there is a greater chance of salvaging ischemic tissue.

However, reperfusion of the irreversibly damaged cells results in death of the cells and the presence of contraction bands due to the entry of Ca^{2+} into the cytosol.

If reperfusion occurs >3 hours, there is a much greater chance that previously ischemic cells will also be irreparably damaged (called reperfusion injury) and will die along with those that were irreparably damaged prior to reperfusion. Hence, the overall size of the infarction will increase.

Superoxide FRs, calcium entering the cytosol, and proteases from neutrophils all contribute to irreversible injury of myocardial tissue. Calcium produces the contraction bands.

2.2.5 Anatomy

In the case of a myocardial infarction, the anatomy of the vessel is important. The *left anterior descending artery (LAD)* supplies the anterior two thirds of the *interventricular septum and the anterior left ventricle*. The left circumflex coronary artery supplies the *lateral wall*. Occlusion of the *right coronary artery* can affect the *posteroinferior left ventricle, the right ventricle, and both the SA and AV nodes.*

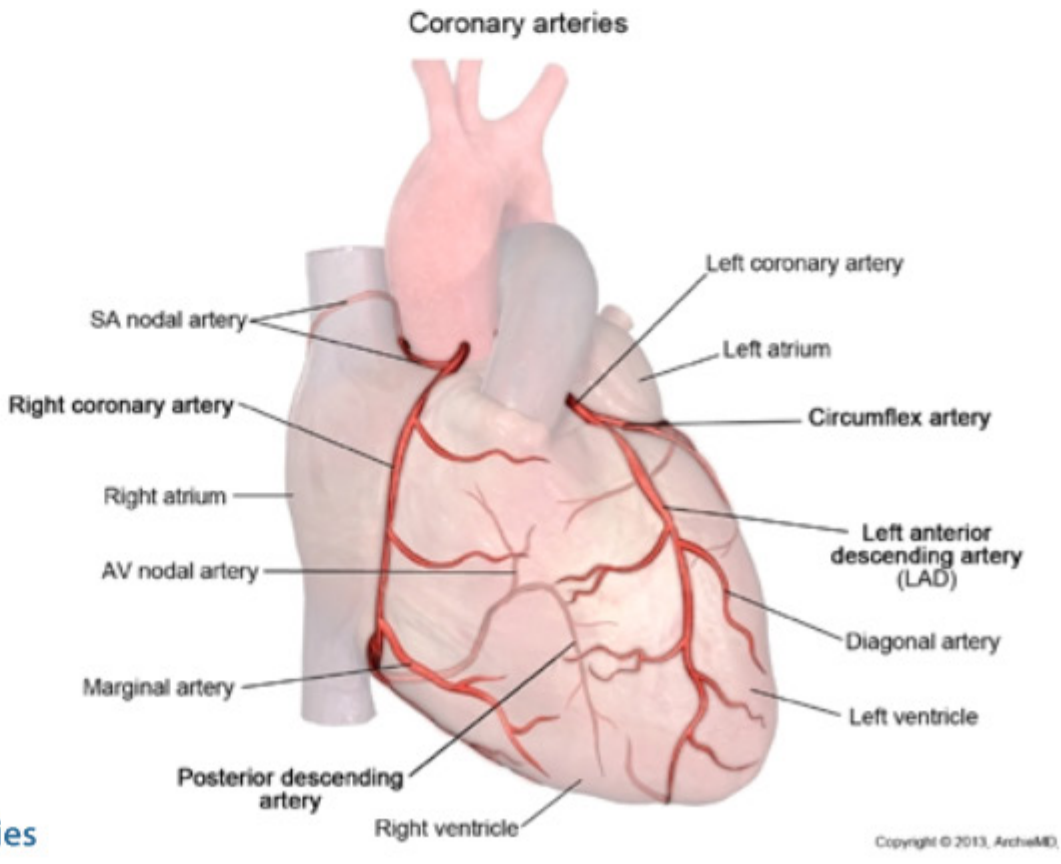

▶ **Figure 10–2.2F** Coronary Arteries

Please visit us at www.Groupinsiders.com

© DeVry/Becker Educational Development Corp. All rights reserved.

2.2.6 Morphology (Gross)

The morphology of a coronary thrombus will go through a progression of changes.

- **0 to 12 Hours:** In the first 12 hours, the infarct may be *inapparent* or be seen as *pale areas*.
- **12 to 24 Hours:** 12 to 24 hours after the event, the infarct will have a *yellow-tan and well-delineated appearance* as coagulation necrosis sets in.
- **10 Days to 2 Weeks:** 10 to 14 days after the infarction, the infarct will resemble a *pale/yellow necrotic area* that is rimmed by a zone of *highly vascular tissue*.
- **More Than 2 Months:** After 2 months, the infarcted tissue will be gradually replaced by a *fibrous scar*.

2.2.7 Morphology (Microscopic)

- **Day 1:** Microscopically, on Day 1, wavy necrotic fibers will be apparent with inter-fiber space from cell death.
- **Day 3:** By Day 3, *neutrophilic infiltration* can be seen.
- **Day 7:** By Day 7, the necrotic degree begins to be removed by *macrophages.*

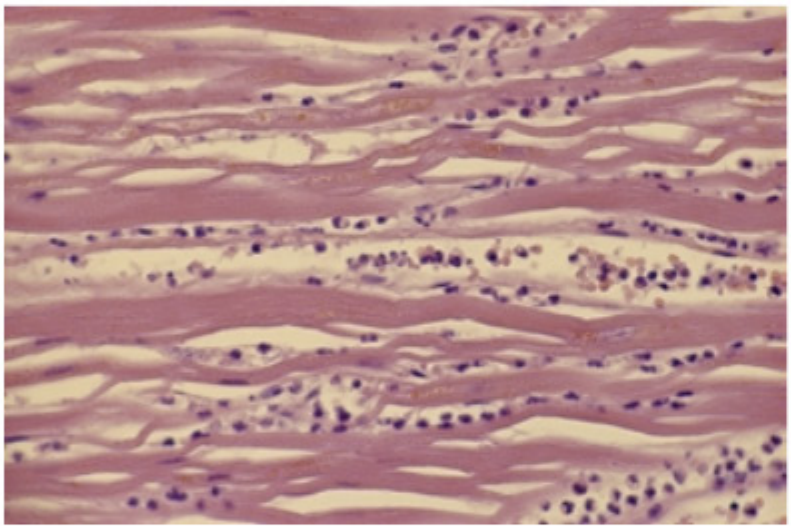

Biophoto Associates/Science Source

▲ **Figure 10–2.2G** Ischemic Heart Disease: Myocardial Infarction Morphology—Day 1

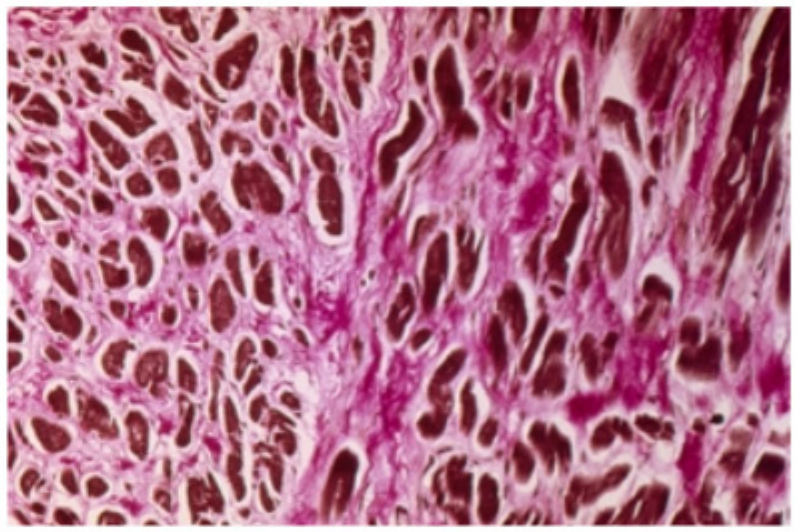

SPL/Science Source

▲ **Figure 10–2.2H** Ischemic Heart Disease: Myocardial Infarction Morphology—Day 7

Please visit us at www.Groupinsiders.com

© DeVry/Becker Educational Development Corp. All rights reserved.

Clinical Application

- **Clinical Pathology:** The initial signs and symptoms of a myocardial infarction include the onset of a *crushing chest pain radiating to the left arm, jaw, or neck*. Patients may also experience *shortness of breath, diaphoresis, tachycardia/palpitations, and nausea/vomiting*. In severe cases, patients may go into *cardiogenic shock*.

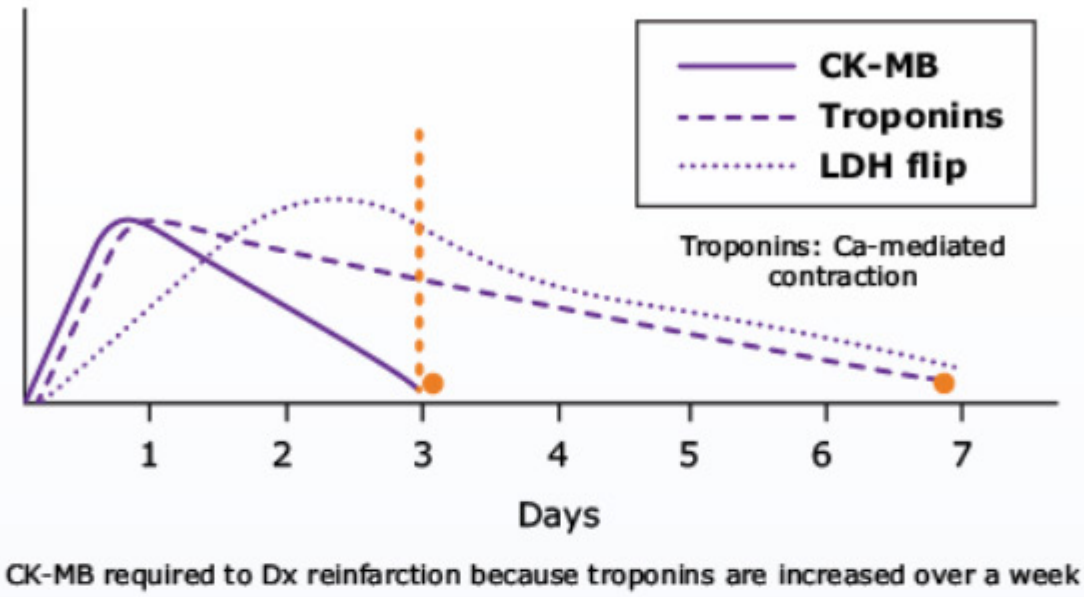

▲ **Figure 10–2.2I** CK-MB Required to Dx Reinfarction Because Troponins Are Increased Over a Week

- **Laboratory Signs:** One of the main ways that myocardial infarctions are diagnosed clinically is via cardiac enzymes, which are released by dying cells. One of the enzymes, CK-MB, is elevated *within 4 to 8 hours after the event, peaks at approximately 18 hours, and normalizes after 2 to 3 days.* Another one, Troponin I, *elevates at 3 to 6 hours, peaks at 16 hours and normalizes after 7 to 10 days*. Tropoinin I also is a more specific marker for myocardial infarction than CK-MB, so it is more widely used. LDH is not currently used, but it is persistently elevated after an MI.

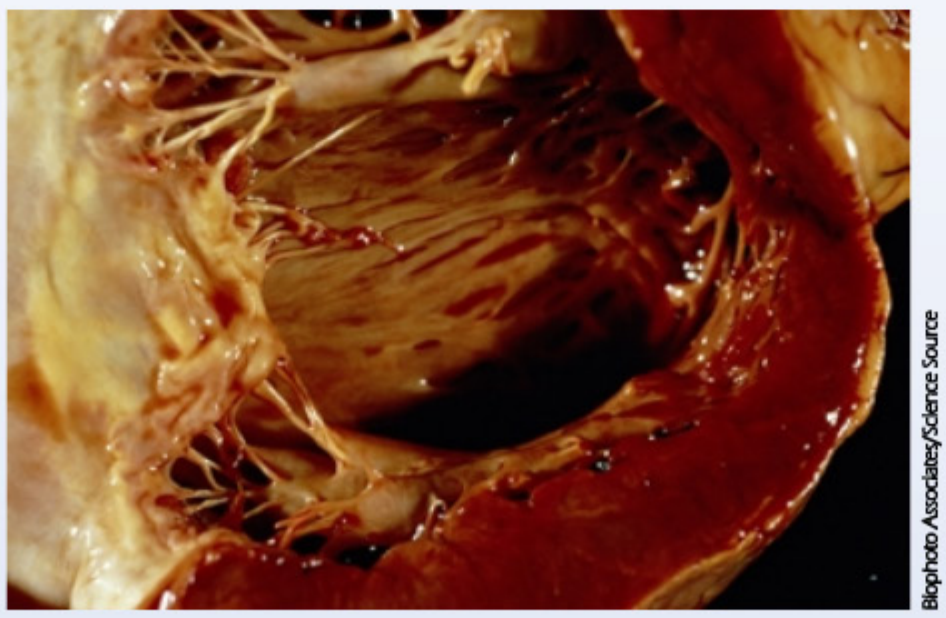
Biophoto Associates/Science Source

▲ **Figure 10–2.2J** Ischemic Heart Disease: Myocardial Infarction

Please visit us at www.Groupinsiders.com

© DeVry/Becker Educational Development Corp. All rights reserved.

2.2.8 Complications

- **Sudden Death:** One of the main complications of an MI is *sudden death*, which is most commonly caused by *cardiac arrhythmias* as the infarcted heart is very prone to arrhythmias. Patients may also develop *cardiogenic shock*.
- **Cardiac Rupture:** Another cause of death is *cardiac rupture*, which most commonly occurs *three to seven days after the infarction*. Cardiac rupture can cause tamponade if it occurs in the ventricular wall or *valvular insufficiency*. If it occurs in the papillary muscles (causing acute shortness of breath and a new murmur, such as a holosystolic murmur heard at the apex and radiating to the axilla).
- **CHF**
- **Pericarditis:** Fibrinous type of pericarditis
- **Mural Thrombus:** Cardiac wall motion abnormalities can cause thrombosis to form, leading to embolic lesions to be thrown off.
- **Ventricular Aneurysm:** *Ventricular aneurysms*, which represent a weakening of the wall and/or lost contractile tissue, may cause heart failure, which can be seen as persistent ST segment elevation on a 12-lead ECG.

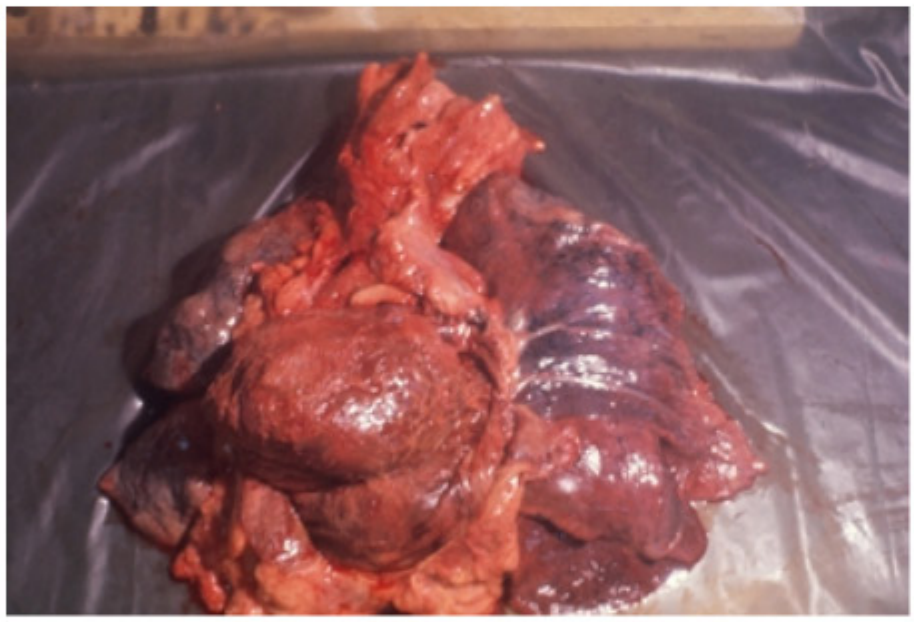

Biophoto Associates/Science Source

▲ **Figure 10–2.2K** Fibrinous Pericarditis Ventricular Aneurysm

Please visit us at www.Groupinsiders.com

© DeVry/Becker Educational Development Corp. All rights reserved.

3 Cardiomyopathy

Cardiomyopathy describes causes of myocardial muscle defects. There are three types of cardiomyopathy: *dilated, hypertrophic,* and *restrictive*. All forms of cardiomyopathy lead to two common endpoints. The first endpoint is *congestive heart failure,* which can lead to either diastolic or systolic dysfunction. The second potential endpoint is *cardiac arrhythmias*, because these myopathies can disrupt normal cardiac architecture, disrupting the normal electrical conduction of the heart. All three forms will be discussed in more detail.

3.1 Dilated Cardiomyopathy

Dilated cardiomyopathy typically presents with an enlarged heart marked by *dilated atria* and *ventricles*. The most common etiology is *idiopathic*, although it can also be caused by certain *medications*, and alcohol, which exhausts stores of thiamine (vitamin B1), doxorubicin, and adriamycin. *Viral* and *parasitic myocarditis* also can cause dilated cardiomyopathy. Dilated cardiac myopathy can cause *systolic dysfunction*, which can lead to CHF, and can also develop *valvular insufficiency* because of widening of the valvular ring. Pathological signs are increased size of the ventricular chamber, thin ventricle walls, and enlarged atria.

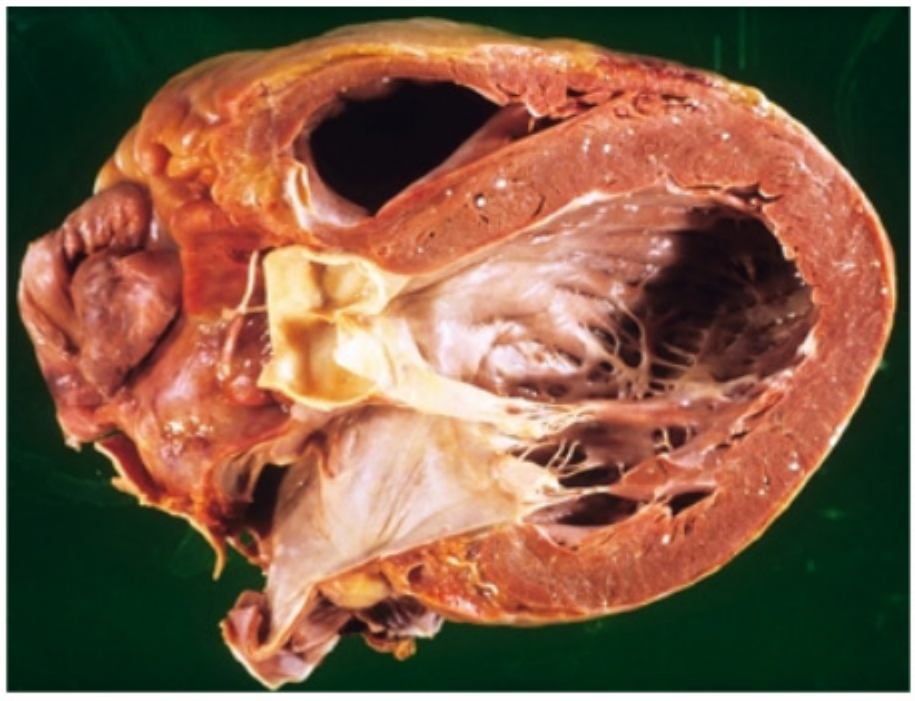

Biophoto Associates/Science Source

▲ **Figure 10–3.1** Dilated Cardiomyopathy

Please visit us at www.Groupinsiders.com

© DeVry/Becker Educational Development Corp. All rights reserved.

3.2 Hypertrophic Cardiomyopathy

Hypertrophic cardiomyopathy causes hypertrophy of the left ventricle, especially the interventricular septum. Fifty percent of the cases are familial form with an autosomal dominant inheritance pattern with mutation in heavy chain of β-myosin and troponins. Pathologically, the enlarged septum can obstruct outflow of the aorta. The murmur becomes more intense with decreased preload. The factors that decrease preload include Valsalva maneuver, standing up, and the use of inotropic drugs (e.g., digoxin). The murmur becomes less intense with increased preload. The factors that increase preload include inspiration, being in a supine position, and negative inotropic agents (e.g., β-blockers). The disruptive cardiac cellular architecture can also cause conduction disturbances and cardiac arrhythmias. Finally, the thickening of the cardiac muscles can cause diastolic dysfunction. This condition can cause sudden and unexpected cardiac death in young adults, as well as dyspnea on exertion.

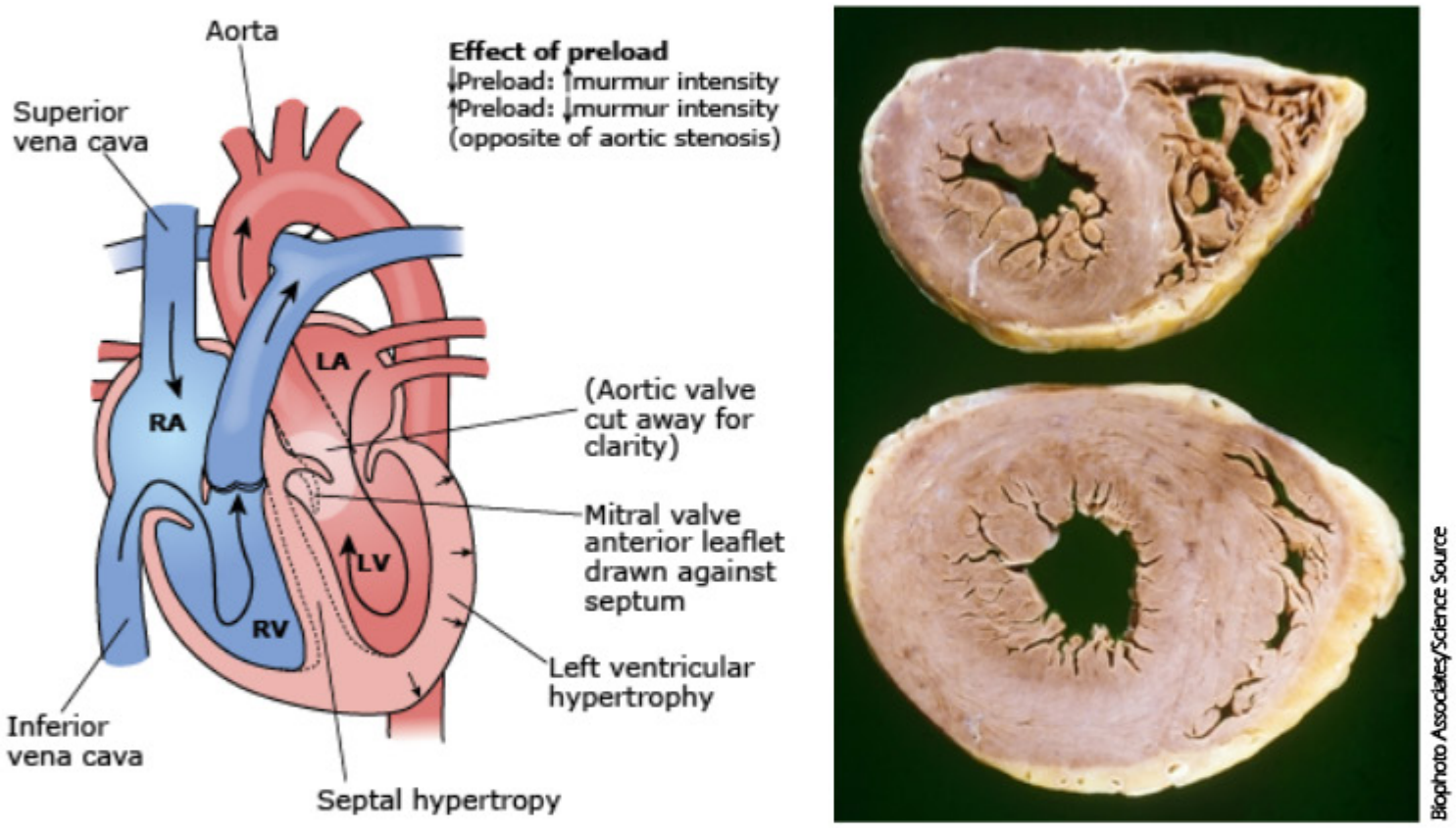

▲ **Figure 10–3.2** Hypertrophic Cardiomyopathy

3.3 Restrictive Cardiomyopathy

Restrictive cardiomyopathies result in *decreased ventricular compliance* (also known as a stiff heart). This type of cardiomyopathy is usually caused by *infiltrative disorders*, such as amyloidosis, hemochromatosis, sarcoidosis, lysosomal storage disease, and Pompe disease. Pathologically, these diseases cause *decreased compliance*, resulting in *diastolic dysfunction and heart failure*, due to inability of the heart to relax. Patients will also develop left ventricular hypertrophy, a thickened interventricular septum, and decreased ventricular chamber size.

Please visit us at www.Groupinsiders.com

© DeVry/Becker Educational Development Corp. All rights reserved.

4 Valvular Heart Disease

Valvular heart disease describes any sort of defect of the heart valves. There are two main types: *Stenotic* lesions, which cause the heart valves to fail to *open* properly and cause problems with *forward flow*, and *regurgitation* or *insufficiency lesions*, in which the valve fails to *close* properly, leading to inappropriate *backward flow*. Either type of valvular disease can lead to *congestive heart failure* as well as an increased risk of developing *bacterial endocarditis*. Different types of inflammatory diseases can lead to valvular heart disease.

4.1 Functional Defects

Functional valve defects can be either of the *stenotic variety*, caused by a *hardened valve*, resulting in systolic output obstruction, or *the regurgitation variety*, in which there is reflux during diastole through the incompetent valve. The most common causes of functional valve defects are *enlargement of the valve ring, infective endocarditis*, and *chronic rheumatic heart disease*.

4.1.1 Aortic Stenosis

Aortic stenosis is typically due to age-related stenosis and calcification of the valve. It is also more common in patients that are born with a bicuspid aortic valve (the aortic valve is normally present with three cusps). The reduced valve compliance and orifice area *decreases cardiac output*, resulting in left ventricular hypertrophy (concentric type as discussed previously resulting in diastolic dysfunction). The LVH can cause *angina, syncope*, and *left heart failure*.

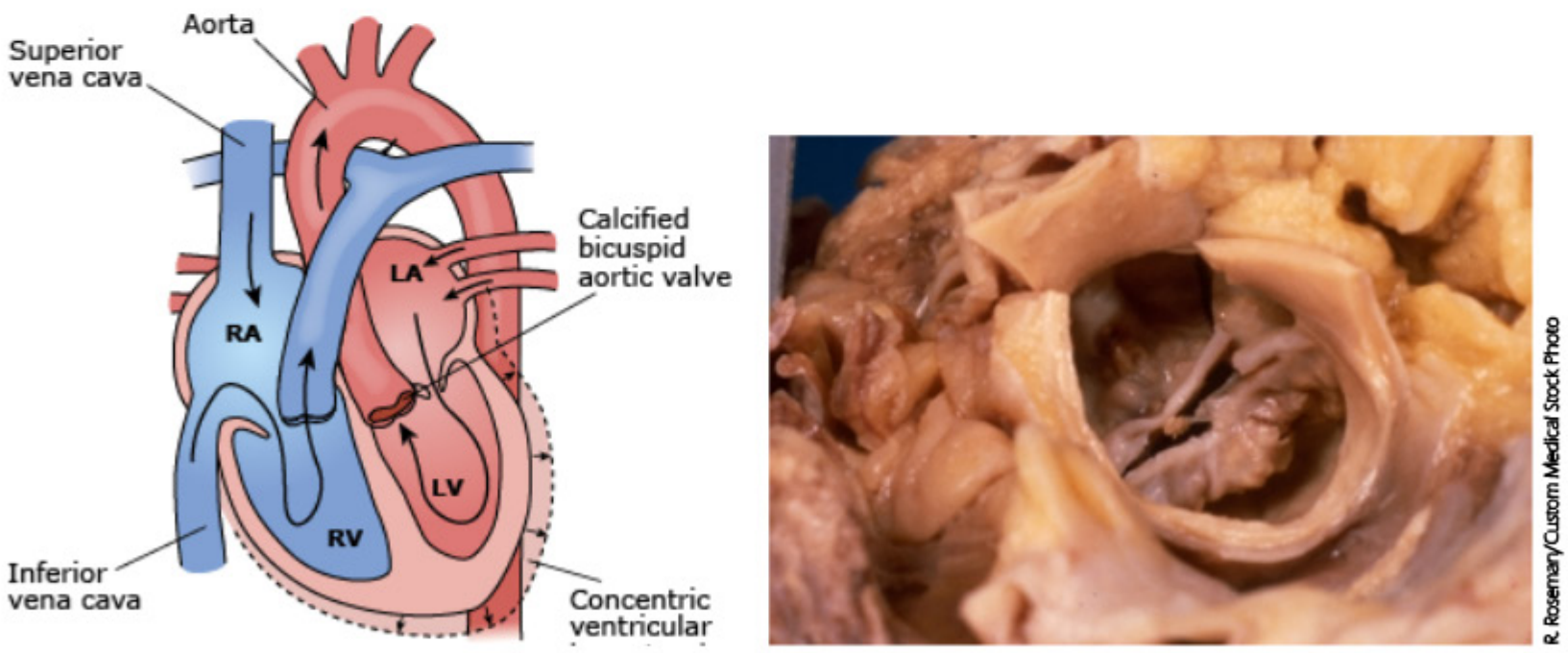

▲ **Figure 10–4.1A** Aortic Stenosis

Please visit us at www.Groupinsiders.com

© DeVry/Becker Educational Development Corp. All rights reserved.

4.1.2 Aortic Regurgitation

Aortic regurgitation is classically caused by long-standing hypertension. It also can be secondary to *dilation of the valvular ring* (which can occur with *marfans syndrome*), *syphilitic aortic aneurysms*, and *aortitis* (*for example, "secondary to many causes" includes ankylosing spondylitis*). Aortic regurgitation can also be secondary to rheumatic heart disease and infective endocarditis. Because aortic insufficiency causes blood to regurgitate into the left ventricle, it causes left ventricle volume overload. The typical signs are increased systolic ejection resulting in pounding peripheral pulses (water-hammer) and head "bobbing" (Musset sign). The classic heart murmur is an *early diastolic murmur heard best at the left sternal border radiating to the apex*. Patients with aortic insufficiency typically do well until late in the course of the disease, resulting in heart failure. As a result, these patients have to be followed with periodic echocardiograms to measure left ventricular dilation and ejection fraction. When a patient's LV ejection fraction approaches 50%, it is appropriate to consider valve replacement.

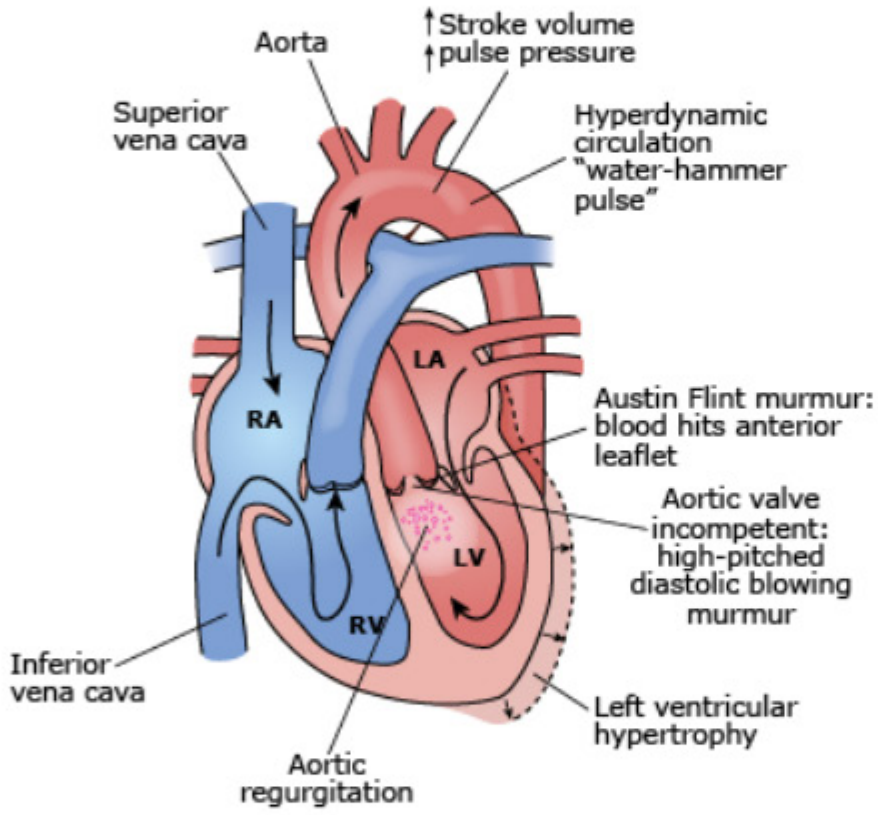

▲ **Figure 10–4.1B** Aortic Regurgitation

4.1.3 Mitral Stenosis

Mitral stenosis is classically caused by chronic rheumatic heart disease and typically causes *left heart failure*. It can cause both *backward failure*, resulting in increased left atrial pressure causing pulmonary congestion, and *forward failure*, resulting in decreased filling of the left ventricle, which decreases cardiac output. Clinical signs include dyspnea, hemoptysis and, on auscultation, an *opening snap* and *mid-diastolic murmur heard best at the apex*. This condition can cause *enlargement of the left atria*, which can cause atrial fibrillation, dysphagia (due to esophagus compression), and hoarseness (due to irritation of the recurrent laryngeal nerve, also known as *Ortner syndrome*).

Please visit us at www.Groupinsiders.com

© DeVry/Becker Educational Development Corp. All rights reserved.

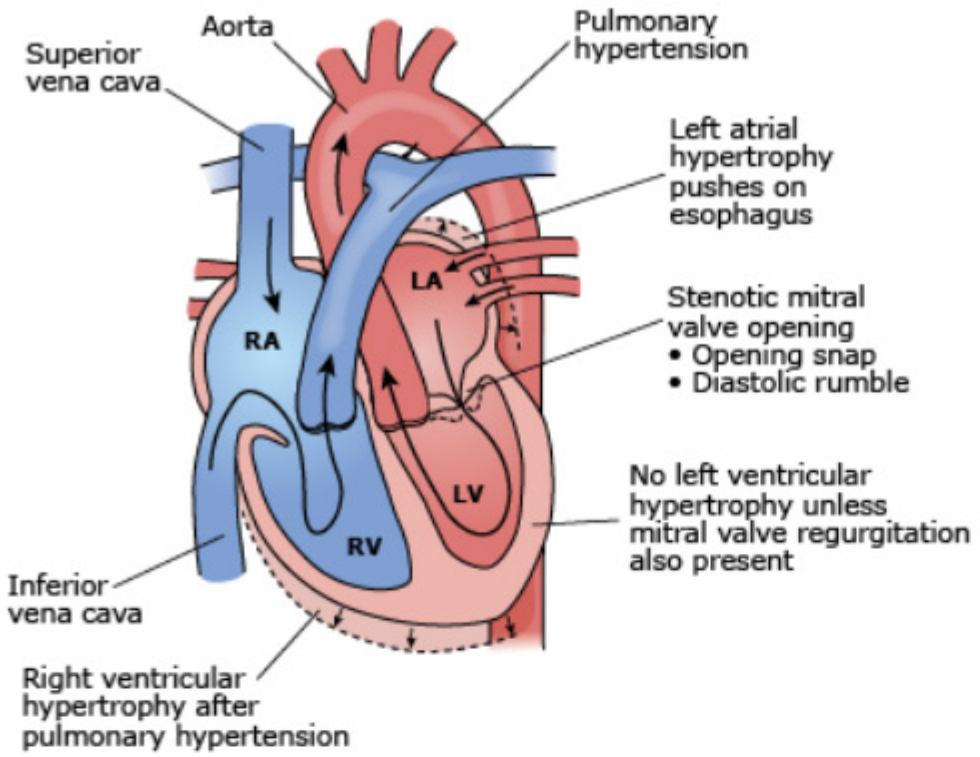

▲ **Figure 10–4.1C** Mitral Stenosis

4.1.4 Mitral Regurgitation

Mitral valve regurgitation is typically caused by mitral valve prolapse. It can also be caused by *left heart failure*, particularly when left atrial enlargement stretches the valvular ring of the mitral valve. Other possible causes *include rheumatic heart disease* and *infective endocarditis*. Clinically, this form of heart disease causes volume overload in *both the left atrium and ventricle*. On chest auscultation, you can hear a *pansystolic murmur* that is best heard at the *apex*. Like mitral valve prolapse, this disease is well compensated until late in the course of the disease, at which point it presents with left heart failure.

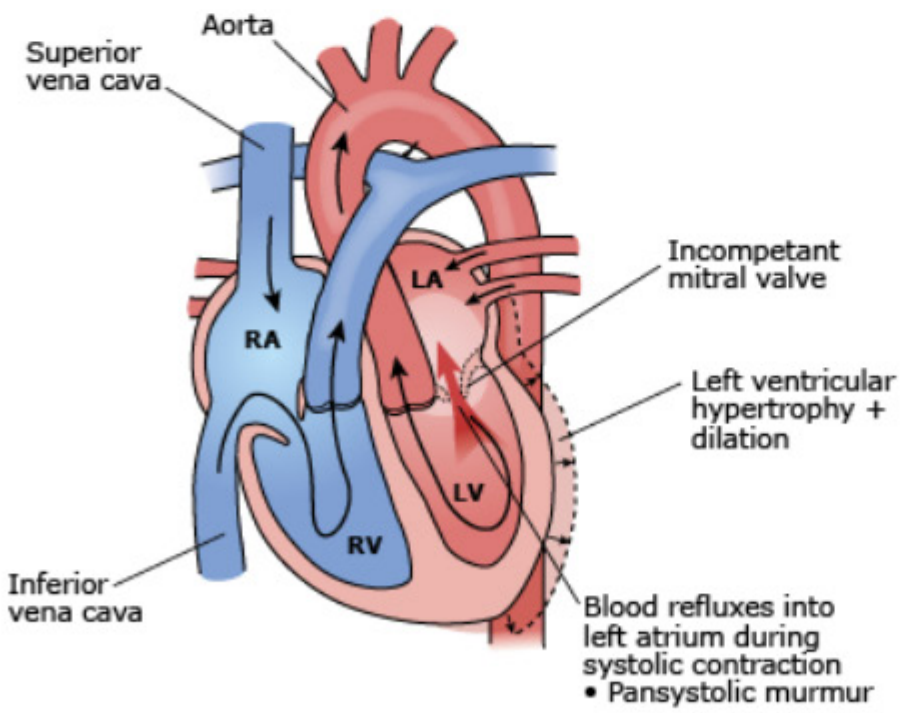

▲ **Figure 10–4.1D** Mitral Regurgitation

Please visit us at www.Groupinsiders.com

© DeVry/Becker Educational Development Corp. All rights reserved.

4.1.5 Mitral Valve Prolapse

Prolapse of the mitral valve is due to posterior bulging of the mitral valve into the left atrium. This occurs during systole and is the *most common form of valvular heart disease*. Mitral valve prolapse is more common in young women and it is usually idiopathic. However, it can be inherited in an *autosomal dominant* fashion and it is also associated with Marfan syndrome and Ehlers-Danlos syndrome. Mitral valve prolapse results from the accumulation of a proteoglycan called *dermatan sulfate* and causes *myxomatous degeneration of the valve leaflets*. On auscultation, patients can have a mid-systolic click and a late systolic murmur, heard best at the apex. Most patients with mitral valve prolapse are *asymptomatic*, but they can have episodic palpitations, chest pain, and fatigue. Patients also have an increased risk of other complications, including mitral insufficiency, endocarditis, and arrhythmias. Symptomatic patients can be treated with *negative inotropic agents* such as beta-blockers and calcium channel blockers.

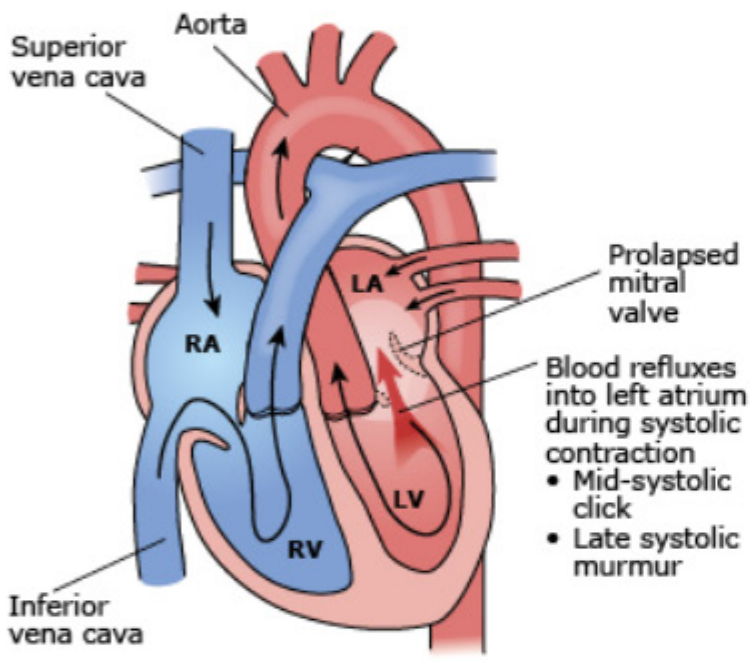

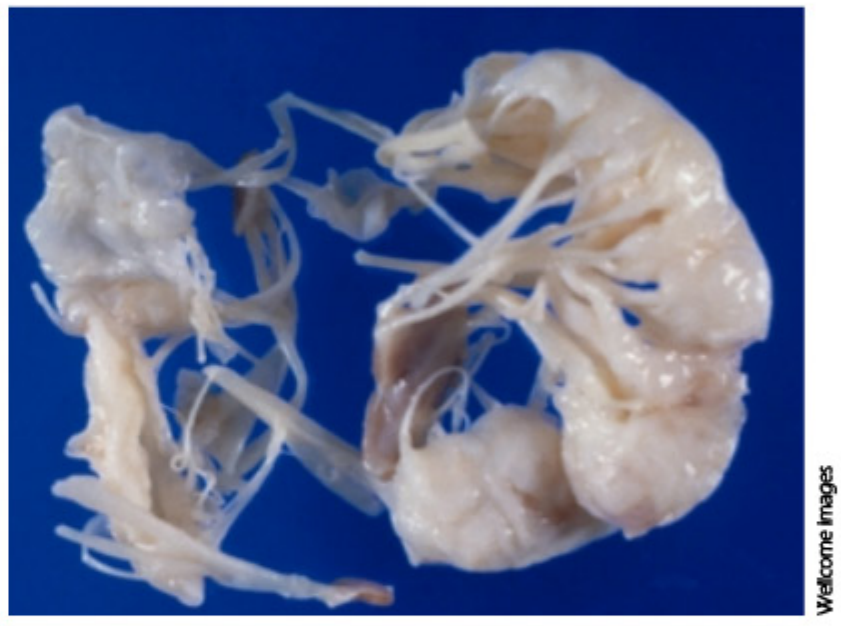

▲ **Figure 10–4.1E** Mitral Valve Prolapse

4.1.6 Other Valve Diseases

- **Tricuspid Regurgitation:** Relatively common, occurs in right heart failure as well as endocarditis, especially in IVDA and patients with rheumatic heart disease.
- **Tricuspid Stenosis:** Typically due to rheumatic heart disease in lower percentage of the diseased population.
- **Pulmonic Stenosis:** May be seen congenitally (e.g., rubella infection passed on in a vertical transmission form).
- **Pulmonic Regurgitation:** This typically occurs in the setting of pulmonary hypertension or in patients with right heart failure.

Please visit us at www.Groupinsiders.com

© DeVry/Becker Educational Development Corp. All rights reserved.

5 Endocarditis

Endocarditis refers to endothelial damage with thrombosis on endocardial surfaces known as vegetations, typically seen on heart valves, that could lead to valvular failure. There are two major types of endocarditis. The first is infectious endocarditis, which has a microbial etiology, and the second is a non-infectious type.

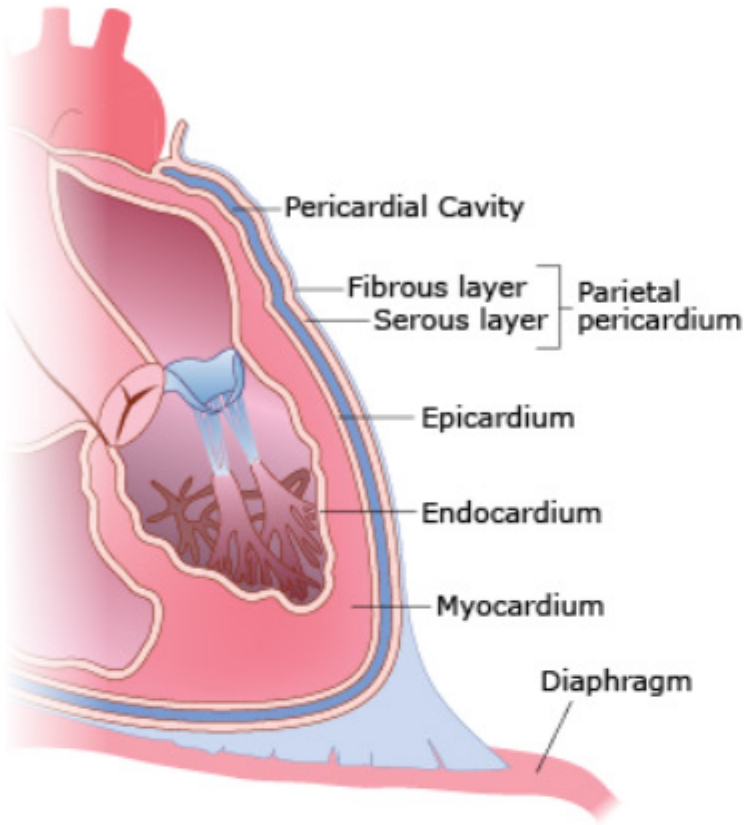

▲ **Figure 10–5.0A** Review: Layers of Cardiac Wall

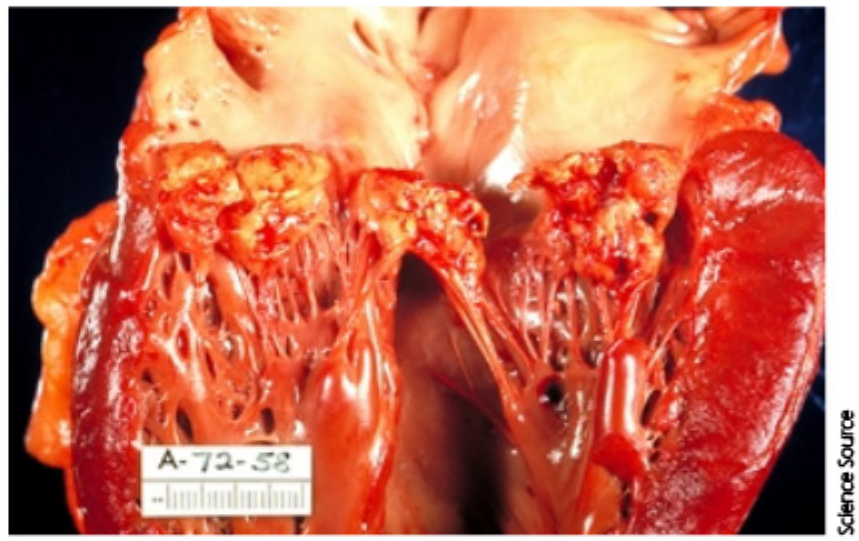

▲ **Figure 10–5.0B** Endocarditis

5.1 Infective Endocarditis

5.1.1 Native Valve Endocarditis (NVE)

The classic clinical presentation and clinical course of infective endocarditis has been characterized as either acute or subacute. Widespread use of antibiotics and an increase in immunosuppressed patients have blended the two types; however, the classification still has clinical merit.

- **Acute Type:** Acute NVE frequently involves normal valves and usually has an aggressive course. Underlying structural abnormalities do not have to be present, as they are with the subacute type. It is a rapidly progressive illness in individuals who are either healthy or are immunocompromised. Virulent organisms, such as *Staphylococcus aureus* and group B streptococci, are typically the causative agents of this type of endocarditis. Due to this condition's prodromal acceleration, the manifestations are different from what you would see in subacute endocarditis.
- **Subacute Type:** Subacute NVE typically affects valves that have underlying abnormalities. Its course is indolent and may last for many months. α-Hemolytic streptococci or enterococci are typically the causative agents of subacute endocarditis.

Please visit us at www.Groupinsiders.com

© DeVry/Becker Educational Development Corp. All rights reserved.

Please visit us at www.Groupinsiders.com

Clinical Application

Complications of Subacute Endocarditis

1. *Osler nodes* result from the deposition of immune complexes on the pads of fingers or toes. The resulting inflammatory response leads to swelling, redness, and pain.
2. *Janeway lesions* are non-tender, small erythematous or hemorrhagic macular or nodular lesions on the palms or soles, only a few millimeters in diameter. These are microabscesses of the dermis with marked necrosis and inflammatory infiltrate not involving the epidermis. Janeway lesions are flat, ecchymotic, and *painless*.
3. *Splinter hemorrhage* is a result of septic emboli that deposit underneath the nail beds.
4. *Roth spots* are septic emboli that lodge in the retinal blood vessels.

Dr. Ken Greer/Visuals Unlimited, Inc.

▲ **Figure 10–5.1** Janeway Lesion

5.1.2 Prosthetic Valve Endocarditis (PVE)

PVE accounts for 10% to 20% of cases of infective endocarditis. The two types of prosthetic valves include pure mechanical valves, which become infected within the first three months of implantation. The second type, known as the bioprosthetic type, are more likely to be infected after one year. The most common causative organisms of PVE include coagulase-negative staphylococci, α-hemolytic streptococci, *Candida* species, enterococci, and gram-negative bacilli are the common causative organisms.

5.1.3 Intravenous Drug Abuser (IVDA) Endocarditis

Left-sided valvular endocarditis is more frequent than right-sided endocarditis; however, the involvement of the tricuspid valve is highly suspicious of IVDA. There is usually no underlying abnormality of the valve. *Staphylococcus aureus* is the most common causative organism.

5.1.4 Rheumatic Heart Disease

Untreated pharyngitis with group A streptococci (*S. pyogenes*) may lead to rheumatic fever and then lead into rheumatic heart disease, more commonly of the left-sided heart valves, including the mitral and aortic valves. More detail will follow.

Looking Ahead

See topic 5.3.2 for the clinical pathology of rheumatic fever.

© DeVry/Becker Educational Development Corp. All rights reserved.

5.2 Non-infectious Endocarditis

5.2.1 Nonbacterial Thrombotic Endocarditis (NBTE)

Also known as *marantic endocarditis*, NBTE is due to the appearance of sterile vegetations of fibrin or platelets on valves, especially the mitral valve. This is most commonly seen in patients with *colon* and *pancreatic cancer*.

5.2.2 Libman-Sacks Endocarditis

This form of endocarditis is caused by *sterile* vegetations that appear on the mitral valve. These vegetations are due to *autoimmune valvulitis* and are associated with systemic lupus erythematosus (SLE).

5.2.3 Culture-Negative Endocarditis

When cultures are taken of suspected PVE or NVE and they come back as negative, fastidious gram-negative organisms known as the "HACEK" group may be involved: *Haemophilus parainfluenzae, Actinobacillus actinomycetemcomitans* (now renamed *Aggregatibacter actinomycetemcomitans), Cardiobacterium hominis, Eikenella corrodens and Kingella kingae*. In initial culture-negative endocarditis, *Coxiella burnettii* or *Bartonella* species are often involved.

5.2.4 Complications

The main complications of endocarditis are *valvular insufficiency/ stenosis, abscess formation (ring abscesses), septic emboli* (which can cause infarction/abscesses in distant sites, such as the brain, kidney, and spleen), and *immune complex formation* causing glomerulonephritis/renal failure.

Clinical signs of endocarditis include *fevers, chills,* and *weight loss*. Patients may also develop a new *cardiac murmur* and will have chronically positive blood cultures. Other signs include *Roth spots*, which are retinal lesions caused by septic emboli, or *splinter hemorrhages* on the nails, hands, and feet.

5.3 Rheumatic Fever

Rheumatic fever is an immune-mediated systemic inflammatory disease that follows patients after a *group A streptococcal infection*. It is most common in *children 5 to 15 years old* and often occurs several weeks after the resolution of an acute pharyngitis. The etiology of rheumatic fever is that susceptible individuals make antibodies against the *streptococcal M protein*, which can cross-react with native proteins. This causes an autoimmune reaction in various tissues, particularly the *heart* (leading to pericarditis, myocarditis, and endocarditis), the *joints* (polyarthritis), and *skin* (resulting in a lesion known as erythema marginatum).

ISM/Phototake, Inc.

▲ **Figure 10–5.3A** Rheumatic Fever

Please visit us at www.Groupinsiders.com

© DeVry/Becker Educational Development Corp. All rights reserved.

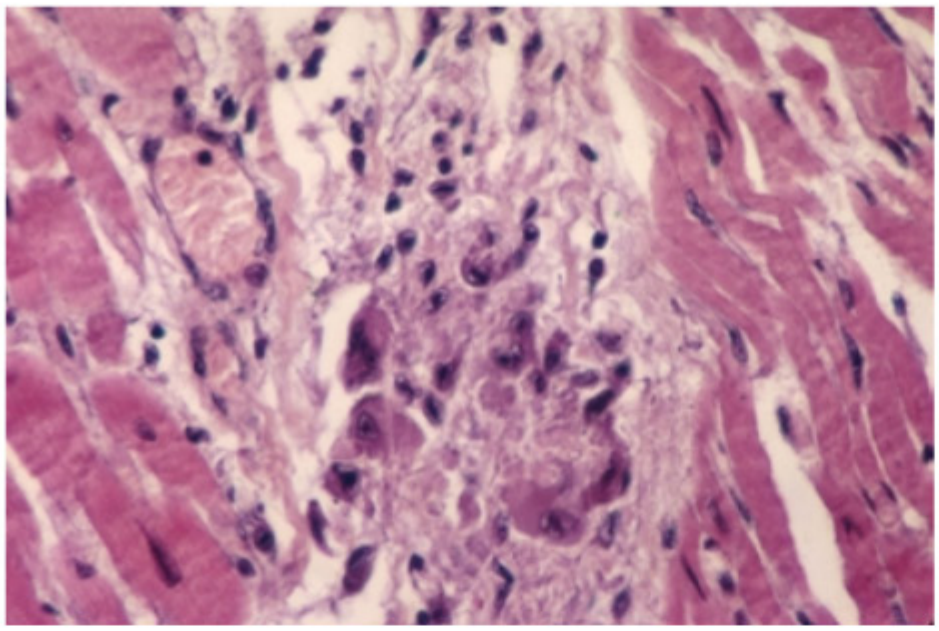

O.J. Staats MD/Custom Medical Stock Photo

▲ **Figure 10–5.3B** Rheumatic Fever (Histology)

5.3.1 Cardiac Pathology

Patients with rheumatic fever are prone to develop *fibrinous pericarditis*, which can cause a *friction rub* and chest pain. They also are prone to *myocarditis*, which is the most common cause of death in patients with rheumatic fever. On histology, *rheumatic myocarditis* is characterized by the appearance of *Aschoff bodies*, which are central areas of fibrinoid necrosis surrounded by lymphocytes, plasma cells, and macrophages (reactive histiocytes known as *Anitschkow cells*). Patients can also develop *endocarditis*, which typically affects the mitral and aortic valve. These valves can develop *sterile vegetations*, causing valvular insufficiency. As a long-term consequence, patients may also develop *repeated injury*, causing fibrosis and valvular stenosis. These patients have an increased risk of developing *CHF* and *bacterial endocarditis*. Characteristic signs on gross pathology include mitral valve thickening, distortion, stenosis, and a commissural fusion.

5.3.2 Clinical Pathology

The diagnosis of rheumatic fever is made based on the Jones criteria. Diagnosis of rheumatic fever requires *two major criteria or one major and two minor criteria, plus evidence of a streptococcal infection*.

- **Major Criteria:** The *major* components are migratory polyarthritis, pancarditis, skin rash *(erythema marginatum)*, Syndenham chorea (a classic neurological finding), and subcutaneous nodules.
- **Minor Criteria:** The *minor* criteria are fever, arthralgias (these only count if there is no migratory polyarthritis), increased levels of acute phase reactants, elevated ESR, and prolonged PR interval.

Please visit us at www.Groupinsiders.com

© DeVry/Becker Educational Development Corp. All rights reserved.

6 Congenital Heart Disease

Before discussing congenital heart disease, it is important to know the basics of fetal circulation. In fetal circulation, oxygenated blood comes from the placenta via a *single umbilical vein* passing through the umbilicus, bypassing the liver through its first shunt called the ductus venosus, entering the *inferior vena cava* to then enter the fetal right atrium. In the fetal right atrium it then encounters its second shunt, called the *foramen ovale*, which allows blood to go from the right to the left atrium without entering into the lungs. Blood entering the fetal right atrium through the superior vena cava enters the right ventricle and any blood that does go into the pulmonary artery encounters a third shunt, the *ductus arteriosus*, which communicates with the arch of aorta. After birth, both of these passageways close: First the foramen ovale closes almost immediately, and the ductus arteriosus closes after a few hours.

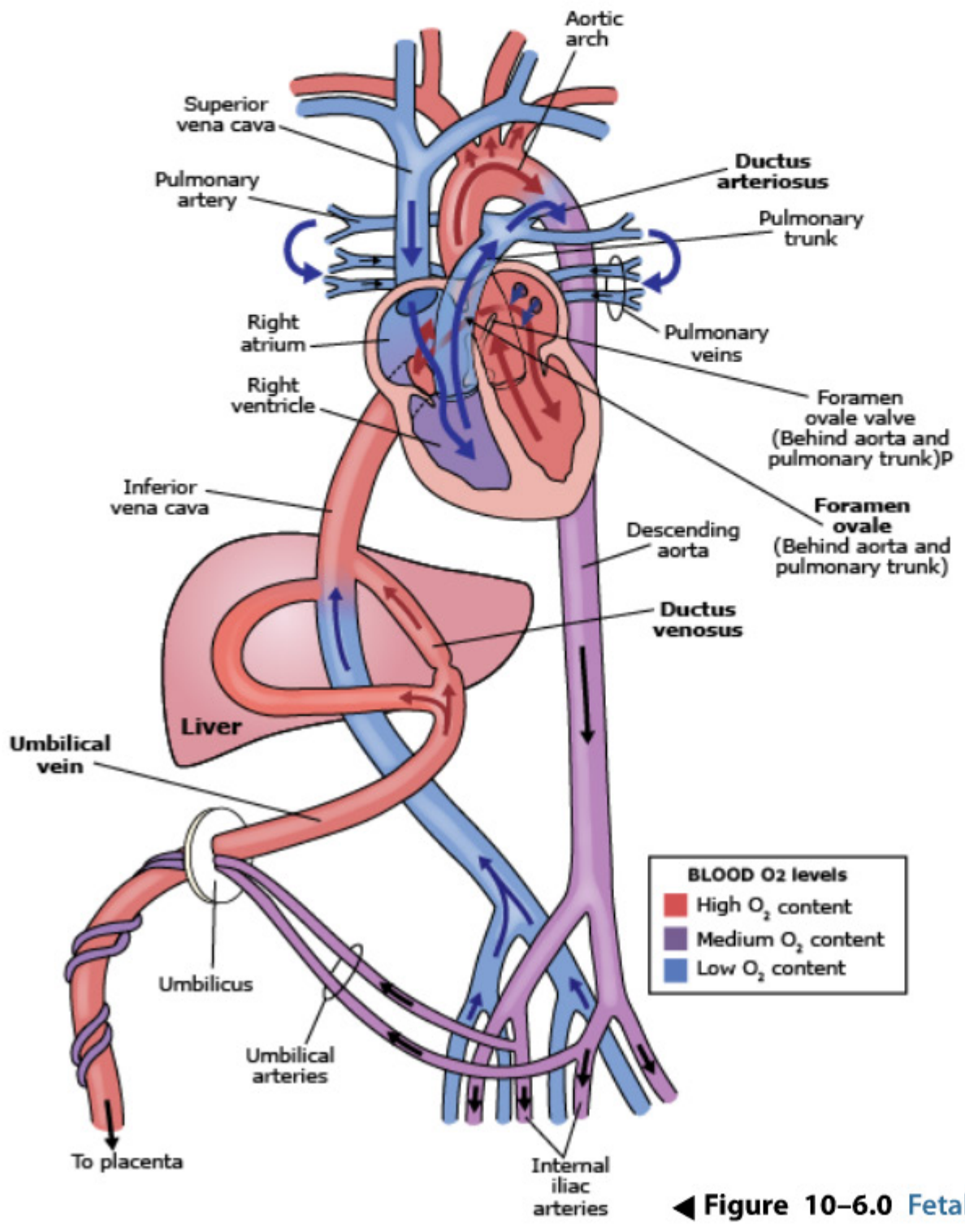

◀ **Figure 10–6.0** Fetal Circulation

Please visit us at www.Groupinsiders.com

© DeVry/Becker Educational Development Corp. All rights reserved.

6.1 Etiology

All *congenital heart defects* result from errors in embryogenesis that occur between three and eight weeks after gestation. By far, the most common cause is *idiopathic*, which accounts for approximately 90% of cases. Other causes include *genetic abnormalities* (seen in various trisomies, cri-du-chat and Turner syndrome), *viral infections* (congenital rubella), *fetal alcohol syndrome*, and *metabolic diseases* (such as diabetes). Some of these causes are associated with specific cardiac defects. For example, fetal alcohol syndrome is associated with *atrial septal defects*, and both cri-du-chat and Edwards syndrome (trisomy 18) are associated with *ventricular septal defects*. Congenital rubella infection can cause a *patent ductus arteriosis,* and Turner syndrome classically causes *coarctation of the aorta*.

6.2 Cardiac Shunts

Congenital heart disease can cause blood to shunt from one side of the heart to the other.

6.2.1 Right-to-Left Shunt

With a *right-to-left shunt*, blood is shunted past the lungs and causes *early cyanosis*, as the blood is not adequately oxygenated. If there is no mixing of blood into the pulmonary circulation, the baby will die. In these cases, an *atrial septal defect* and *patent ductus arteriosis* will be protective. Clinical signs of a right-to-left shunt include cyanosis, digital clubbing, shortness of breath, and secondary polycythemia (a compensatory response to poor oxygenation). Causes of right-to-left shunts include tetralogy of Fallot, transposition of the great arteries, truncus arteriosus, tricuspid atresia, and total anomalous pulmonary venous return (TAPVR).

- **Tetralogy of Fallot:** The most common cyanotic congenital heart disease, *Tetralogy of Fallot* is marked by an *overriding aorta, pulmonary valve stenosis, a ventricular septal defect, and right ventricular hypertrophy*. The pulmonary valve stenosis impedes blood flow into the pulmonary circulation, so blood flows from the right ventricle into the overriding aorta via the ventricular septal defect. This means that the majority of the blood *bypasses* the lungs, resulting in hypoxia and cyanosis. When the young patient (child) is experiencing cyanosis, he or she will squat to increase total peripheral resistance to reverse the shunt from a right-to-left to a temporary state of left-to-right shunt, relieving the cyanotic episode. This is referred to as *tet spells*.

Please visit us at www.Groupinsiders.com

© DeVry/Becker Educational Development Corp. All rights reserved.

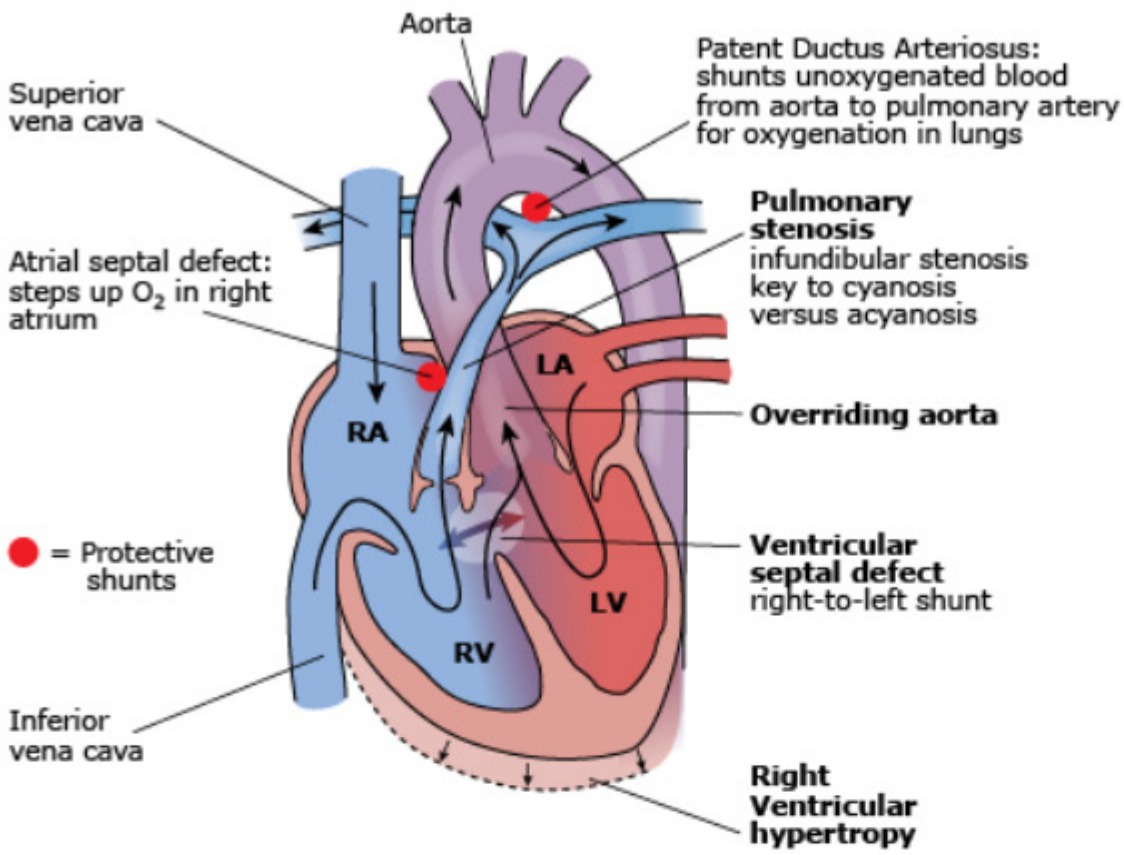

National Medical Slide Bank/Custom Medical Stock Photo

▲ **Figure 10–6.2A** Tetralogy of Fallot

Please visit us at www.Groupinsiders.com

© DeVry/Becker Educational Development Corp. All rights reserved.

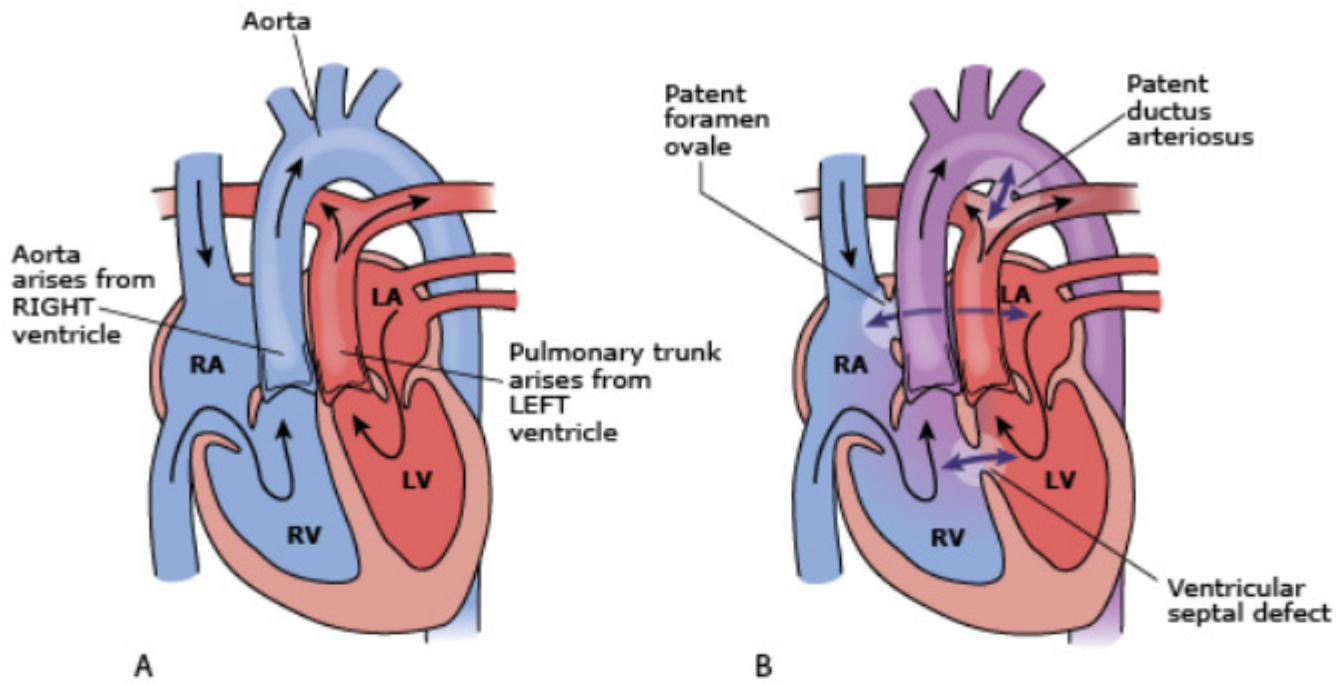

▲ **Figure 10–6.2B** Transposition of the Great Arteries

- **Transposition of the Great Arteries:** *Transposition of the great arteries* results when the aorta rises from the right ventricle and the pulmonary artery arises from the left ventricle. As a result, blood flow bypasses the lungs, causing hypoxia and cyanosis. Patients with a transposition of the great arteries must have either an ASD, VSD, or patent ductus arteriosus to allow for mixing of oxygenated blood.
- **Truncus Arteriosus:** *Truncus arteriosus* is a result of the septum between the aorta and pulmonary artery failing to form. As a result, venous and arterial blood mix, causing cyanosis. The high-pressure output from the left ventricle into the pulmonary artery causes pulmonary hypertension, potentially leading to congestive heart failure.

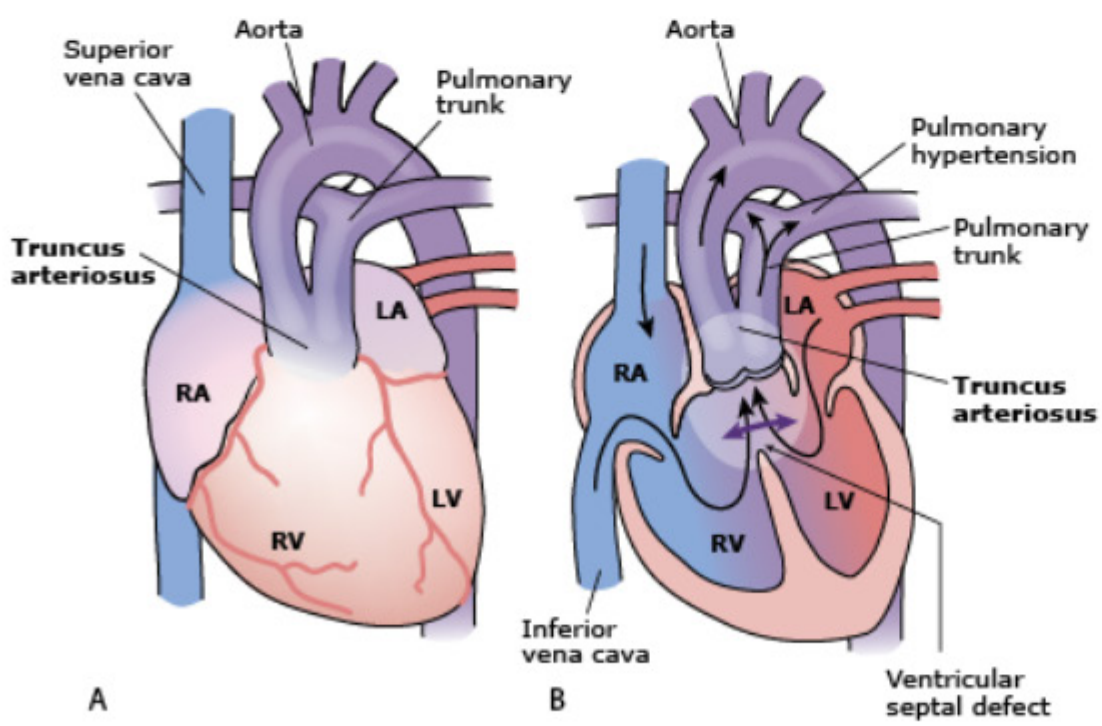

▲ **Figure 10–6.2C** Truncus Arteriosus

Please visit us at www.Groupinsiders.com

© DeVry/Becker Educational Development Corp. All rights reserved.

- **Tricuspid Atresia:** *Tricuspid atresia* occurs when the tricuspid valve fails to form, which causes *right ventricular hypoplasia*. Patients with tricuspid atresia usually will have both an ASD and a VSD; the ASD allows blood to flow from the right atrium to the left and the VSD allows the left ventricle to communicate with the pulmonary artery. Again, like the other cyanotic diseases, mixing of the arterial and venous blood leads to hypoxia and cyanosis.

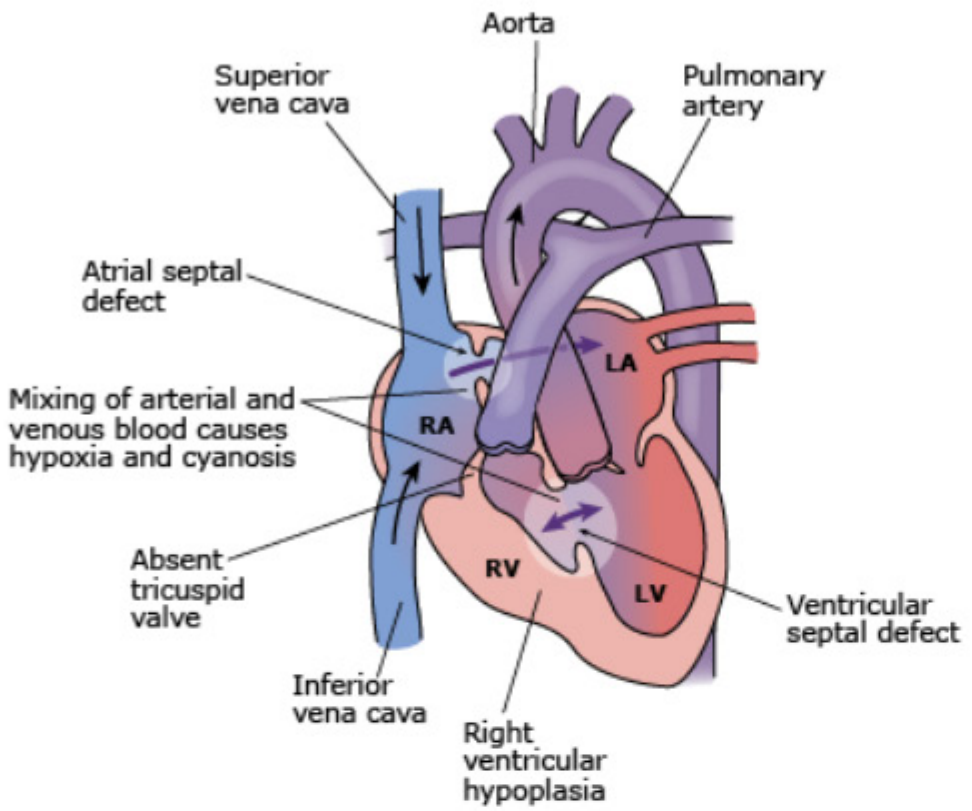

▲ **Figure 10–6.2D** Tricuspid Atresia

- **Total Anomalous Pulmonary Venous Return:** *Total anomalous pulmonary venous return* is the result of the pulmonary veins delivering oxygenated blood to the *right* atrium instead of the left. An ASD allows the right heart to communicate with the left. Mixing of arterial and venous blood causes hypoxia and cyanosis.

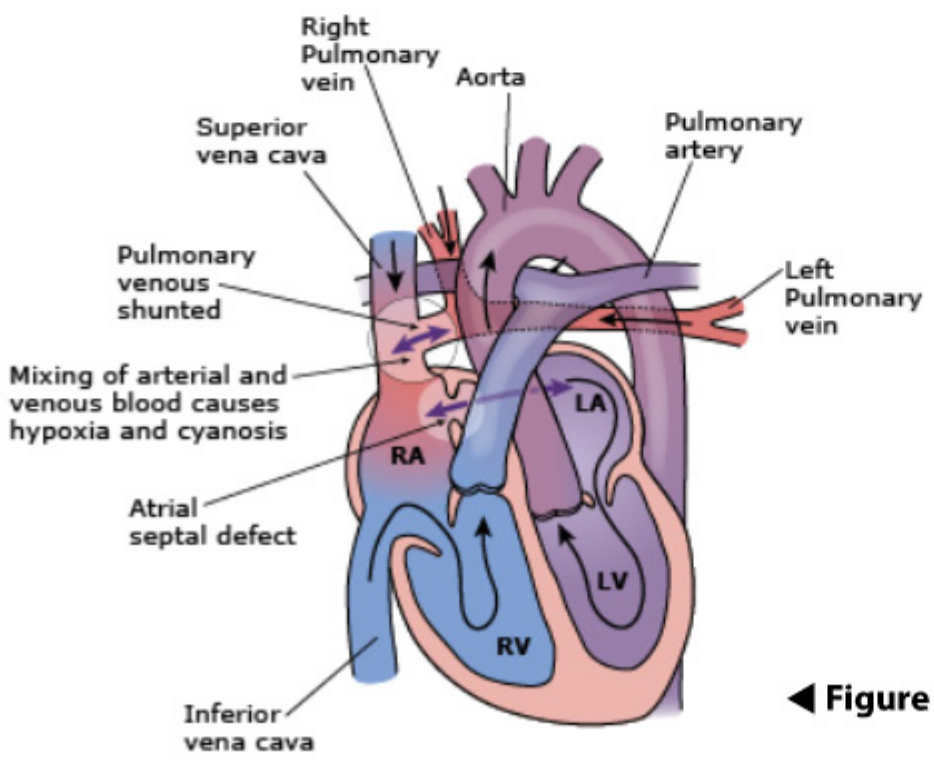

◀ **Figure 10–6.2E** Total Anomalous Pulmonary Venous Return (TAPVR)

Please visit us at www.Groupinsiders.com

© DeVry/Becker Educational Development Corp. All rights reserved.

6.2.2 Left-to-Right Shunts

Initially, these shunts are left to right because the left ventricle has a greater pressure. However, in severe cases, the increased blood flow to the pulmonary circulation causes *pulmonary hypertension and RV hypertrophy*. This can cause the shunt to be reversed and to become a right-to-left shunt, also known as *Eisenmenger syndrome*. This causes blood to bypass the lungs, causing hypoxia and cyanosis *late* in the course of the disease.

- **Atrial Septal Defect:** These defects are the most common form of congenital heart disease in adults but are often discovered incidentally, as they are commonly asymptomatic. Atrial septal defects are associated with *fetal alcohol syndrome* and are caused by failure of the *foramen ovale* to close (i.e. most commonly the ostium secondum type). Most ASDs are small, but for ones that are large enough to be symptomatic, patients may develop *fatigue, heart failure,* and *Eisenmenger syndrome*.

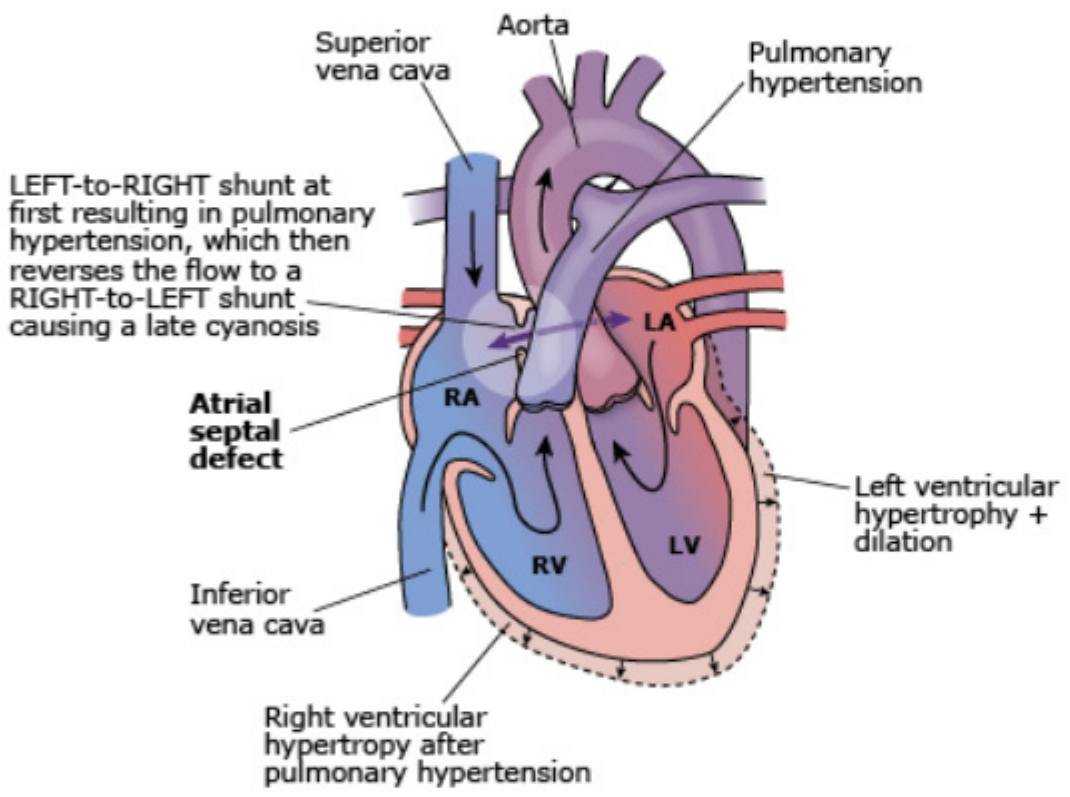

▲ **Figure 10–6.2F** Atrial Septal Defect

- **Ventricular Septal Defect (VSD):** Ventricular septal defects are *the most common overall congenital heart disease* and are associated with cri-du-chat syndrome (partial loss of chromosome 5) and Edwards syndrome (trisomy 18). These defects are caused by a deficiency in the membranous portion of the interventricular septum (most commonly in children); blood flows from the left ventricle to the right. If the defect is large enough, it can cause *tachycardia, failure to thrive (in infants), right heart failure, and Eisenmenger syndrome*.

Please visit us at www.Groupinsiders.com

© DeVry/Becker Educational Development Corp. All rights reserved.

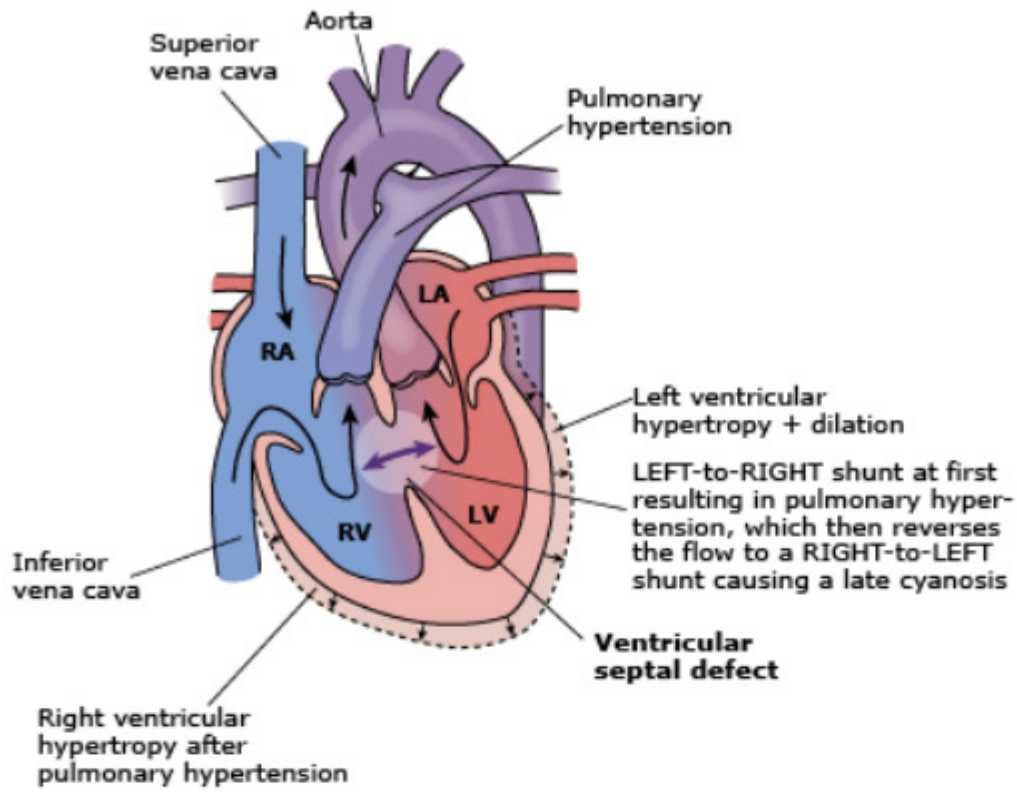

▲ **Figure 10–6.2G** Ventricular Septal Defect (VSD)

- **Patent Ductus Arteriosus (PDA):** *Patent ductus arteriosus* occurs if the ductus arteriosus fails to close after birth. It causes blood to flow from the aorta (which has a high pressure) into the pulmonary artery. This causes a characteristic *machine-like* murmur. If the shunt reverses, patients will have a *differential cyanosis* that only affects the lower extremities.

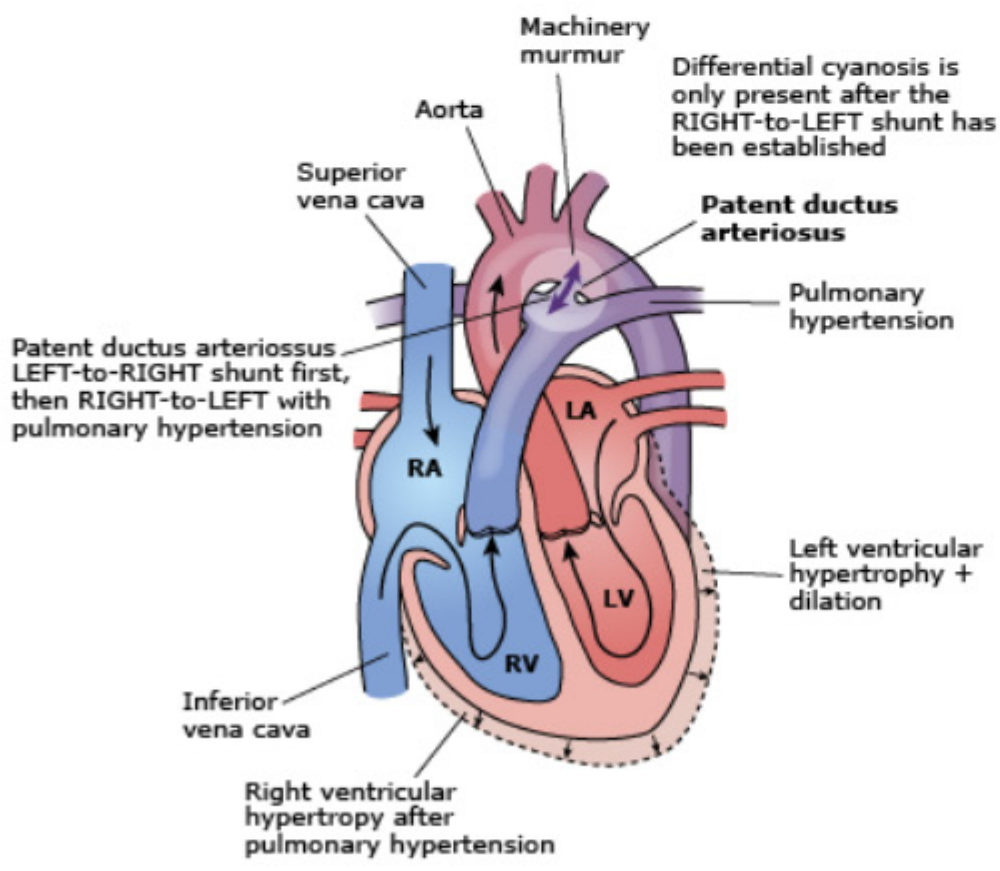

▲ **Figure 10–6.2H** Patent Ductus Arteriosus (PDA)

Please visit us at www.Groupinsiders.com

© DeVry/Becker Educational Development Corp. All rights reserved.

6.3 Coarctation of the Aorta

This is a congenital narrowing of the aorta and is more common in males. It can be either proximal or distal to the ductus arteriosus and can cause congestive heart failure, intracerebral hemorrhage, and a dissecting aortic aneurysm. Coarctations proximal to the ductus arteriosus, called pre-ductal, are usually detected in infancy and cause heart failure, weak pulses, and cyanosis of the lower extremities. These are associated with *Turner syndrome*. Coarctations distal to the ductus arteriosus, called post-ductal, usually present in older children or adults. Patients will have *hypertension in their upper extremities* and *hypotension of the lower extremities*.

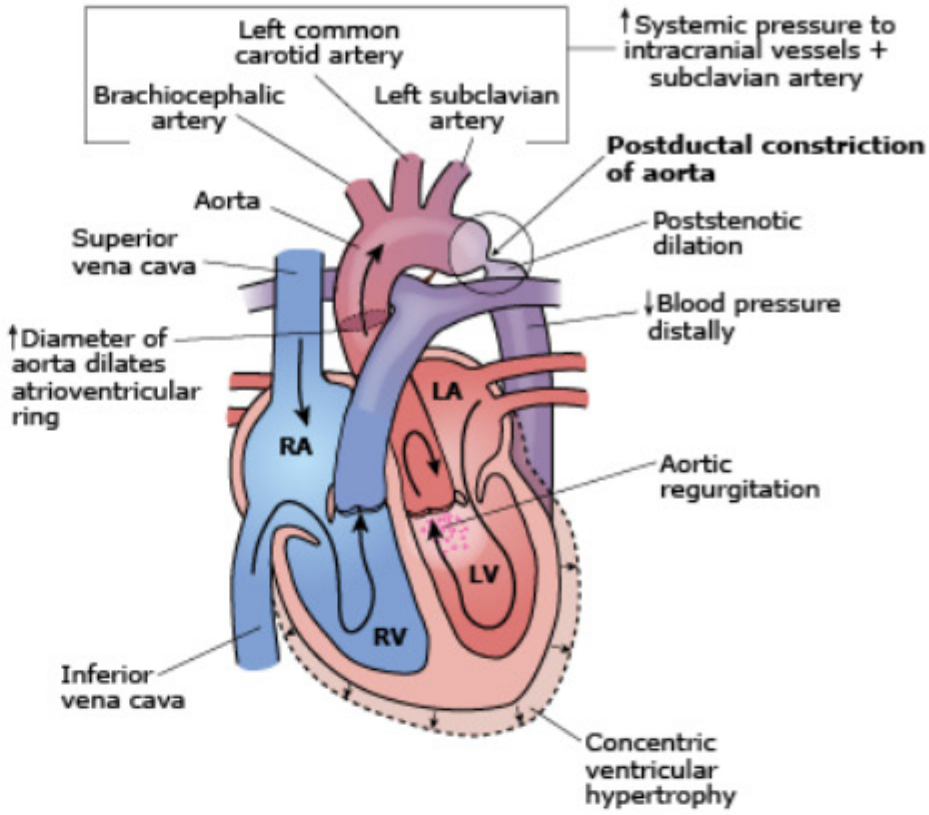

▲ **Figure 10–6.3A** Coarctation of the Aorta

6.3.1 Collateral Circulation in Coarctation of the Aorta

- Anterior and posterior intercostal arteries develop collateral circulation and increased pressure, causing retrograde flow though posterior intercostal arteries back into the aorta.
- Internal thoracic artery becomes the superior epigastric artery, which forms collateral with inferior epigastric artery, which develops retrograde blood flow and empties into the external iliac artery.
- Ischemia of the lower limbs results in claudication in buttocks and calf muscles. It also triggers the renin-angiotensin-aldosterone-system (RAAS) due to decreased perfusion to the renals.
- Due to increased blood flow through the upper extremities, there is notching of the ribs.

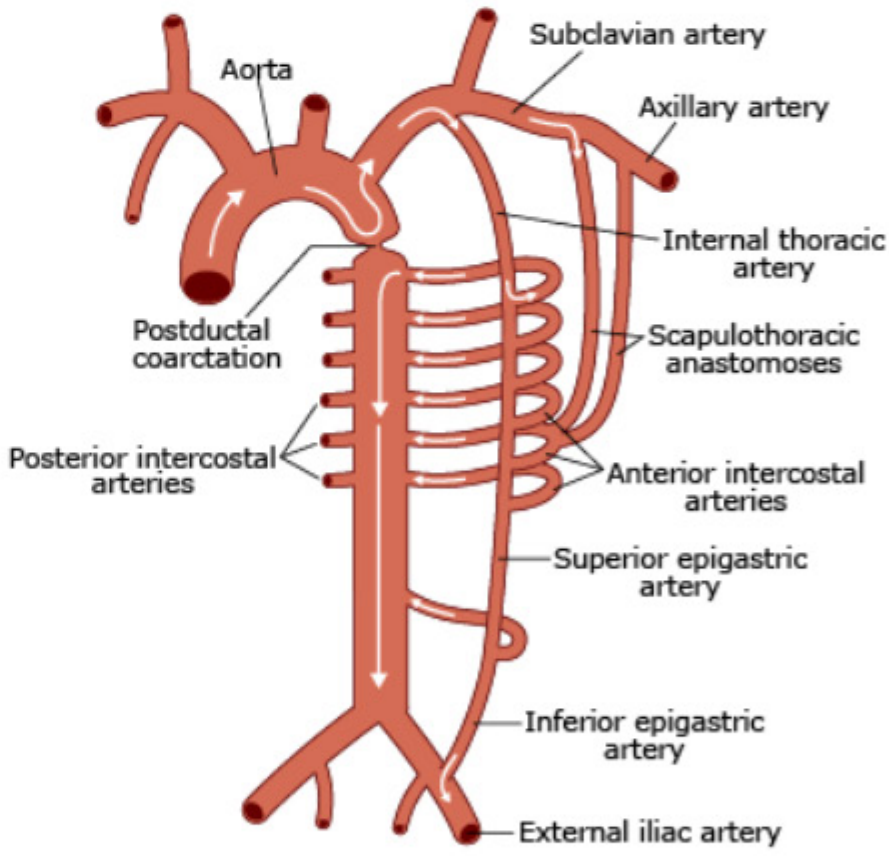

▲ **Figure 10–6.3B** Collateral Circulation in Coarctation of the Aorta

Please visit us at www.Groupinsiders.com

© DeVry/Becker Educational Development Corp. All rights reserved.

7 Myocardial and Pericardial Disease

7.1 Myocarditis

- Myocarditis describes inflammation of the myocardium. Some cases are from *infections*. Most common viral myocarditis is from adenovirus; others are from human herpesvirus 6 (HHV-6) and parvovirus. At present, Coxsackie virus has dropped off the top five causes of viral myocarditis. Protozoal infections such as trypanosomes, during the amastigote stages, may cause myocarditis as a manifestation of Chagas disease.
- Some cases are *immune-mediated*, as is the case with post-viral and post-streptococcal myocarditis. The other causes do not fit neatly into a category and include sarcoidosis, systemic lupus erythematosis (SLE), and often the most common presentation, giant cell myocarditis. Morphologically, the myocardium will be normal sized or dilated and you will see diffuse or patchy lesions with *mononuclear inflammatory and lymphocytic infiltrates* as well as damaged cardiac myocytes. The ventricles also may have pale foci or hemorrhagic lesions due to damage.
- Clinically, these patients may be *asymptomatic* or they can have *fever, chest pain, fatigue,* and *palpitations.* A characteristic lab finding is elevations in cardiac enzymes, such as Creatinine Kinase-MB (CK-MB) and Troponin I (TnI).
- Ultimately, myocarditis can cause CHF, arrhythmias, and sudden death if untreated.

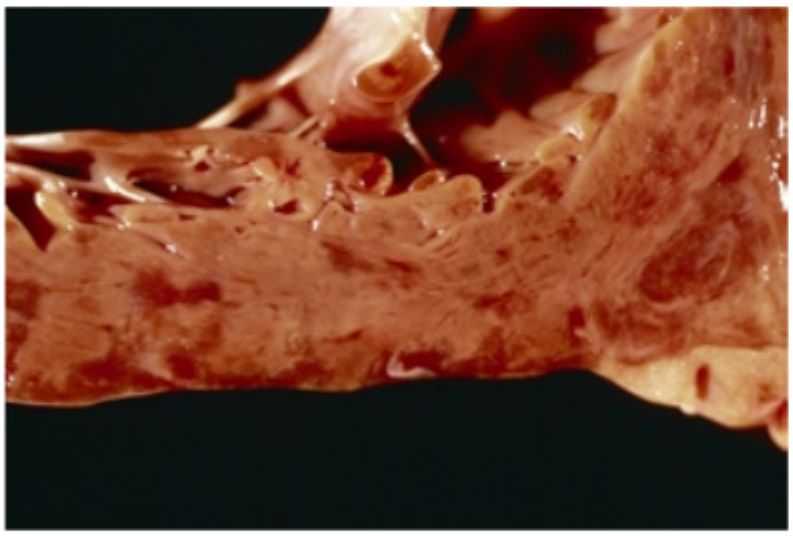

CNRI/Science Source

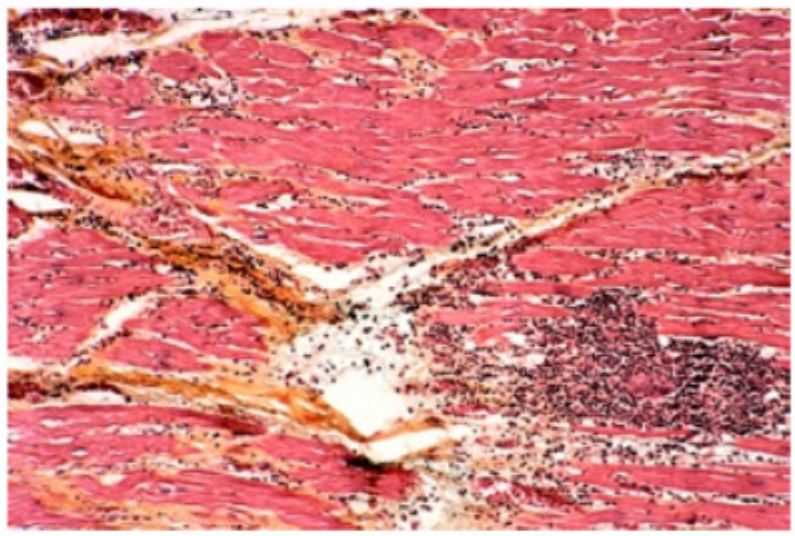

Dr. Frederick Skvara/Visuals Unlimited, Inc.

▲ **Figure 10–7.1** Myocarditis

7.2 Pericarditis

Pericarditis is an inflammation of the pericardium and is often associated with a *pericardial effusion*. It can be caused by *infection, autoimmune disease, trauma, myocardial infarction,* and *uremia,* which indicates the need for immediate hemodialysis. On pathology, an inflammatory reaction is found on the surfaces of the epicardium and pericardium with few numbers of polymorphonucelar leukocytes, lymphocytes, and histiocytes.

Please visit us at www.Groupinsiders.com

© DeVry/Becker Educational Development Corp. All rights reserved.

7.2.1 Types

There are four main types of pericarditis.

- **Fibrinous:** This type can be found with uremia and post-myocardial infarction
- **Suppurative:** This type of pericarditis is associated with bacterial infections.
- **Hemorrhagic:** Hemorrhagic type is associated with trauma, tuberculosis, or malignancy.
- **Restrictive:** Restrictive type may be a result of scarring seen during the repair process of myocardial injury. It also can be seen with infiltrative diseases such as hemochromatosis, and amyloidosis seen with a number of conditions (e.g., multiple myeloma).

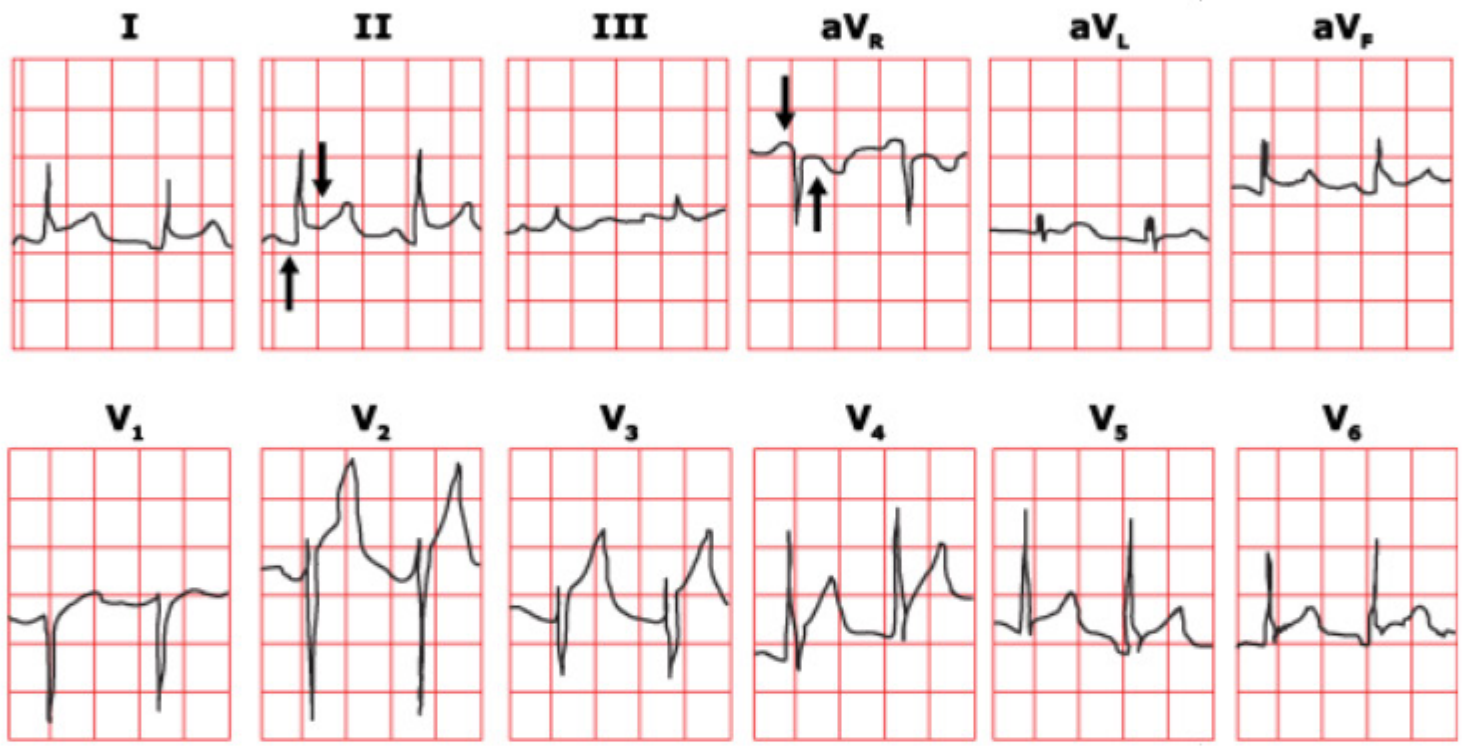

▲ **Figure 10–7.2A** Acute Pericarditis: EKG

7.2.2 Clinical Pathology

The key signs are *precordial chest pain.* The pain does not disappear with holding of the breath. The pain increases with inspiration and leaning backward. The pain eases with leaning forward, which causes separation of the two layers of the pericardium. Because the heart chambers are compromised, a *friction rub* may be heard consisting of three components. All three components are louder than normal and include an atrial systole, an even louder ventricular systole, and finally, rapid ventricular filling. *Muffled heart sounds* and distension of the neck veins with inspiration, known as *Kussmaul sign,* and an exaggerated decrease of blood pressure during inspiration, define pulsus paradoxus.

Please visit us at www.Groupinsiders.com

© DeVry/Becker Educational Development Corp. All rights reserved.

These three components make up what is known as the Beck triad. ECG shows diffuse ST-elevation of all leads. There are no reciprocal depressions due to the entire heart being affected. This is not a myocardial infarction.

Management The concept of treatment revolves around anti-inflammatory agents such as NSAIDs and corticosteroids.

7.2.3 Pericardial Tamponade

The normal pericardium accommodates 15–20 mL of fluid. The premise in cardiac tamponade is that there is accumulation of fluid in the pericardial cavity, as may be seen with a ruptured ventricular aneurysm. Diastolic filling of the ventricles is compromised, leading to decreased stroke volume and thus cardiac output. Signs of cardiac tamponade include tachycardia, decreased pulse pressure, Beck triad.

Management Management includes removing excess fluid from the pericardial cavity. Measurement of the pericardial cavity fluid is performed by echocardiogram, followed by pericardiocentesis to remove excess fluid as treatment.

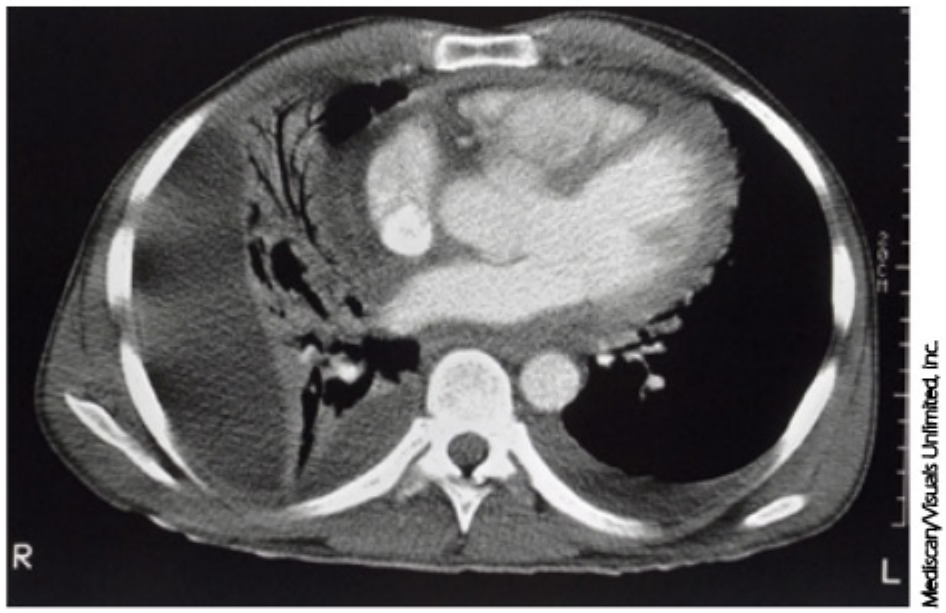

▲ **Figure 10–7.2B** Pericardial Tamponade

7.2.4 Tumors in the Heart

There are two main tumors of the heart: *Myxomas* (benign tumors, most commonly found in the left atrium, cause mitral stenosis and typically affect adults) and *rhabdomyomas* (benign tumor, arises from heart muscle, and affects infants and children).

Please visit us at www.Groupinsiders.com

© DeVry/Becker Educational Development Corp. All rights reserved.

Please visit us at www.Groupinsiders.com

1 Hypertension

Two categories of hypertension:

1. **Primary (Essential) Hypertension**
   95% of hypertension
2. **Secondary Hypertension**

▼**Table 11–1.0** Hypertension

Category		SBP	DBP
Optimal		<120	<80
Normal		<130	<85
High Normal		130–139	85–89
Hypertension	Stage 1	140–159	90–99
	Stage 2	160–179	100–109
	Stage 3	≥180	≥110

1.1 Primary (Essential) Hypertension

Involves genetic factors which cause:

- **Reduced renal sodium excretion**
  - Excess sodium increases plasma volume.
  - Excess plasma volume increases stroke volume and *systolic blood pressure*.
  - African-American and elderly patients.
- **Vasoconstriction**
  - Excess sodium opens calcium channels in arteriole smooth muscle cells, causing vasoconstriction, increasing TPR, and increasing *diastolic blood pressure*.
- Stress, cigarette smoking, obesity, and physical inactivity may also contribute.

1.2 Secondary Hypertension

1.2.1 Renal Disease

Most common cause of secondary hypertension.

- Glomerular disease
- Renal artery stenosis
  - Atherosclerosis in elderly males or unilateral fibromuscular dysplasia in 15- to 30-year-old females.

USMLE® Key Concepts

For Step 1, you must be able to:

- Differentiate among various types of hypertension.
- Differentiate among the pathogeneses of the three types of arteriosclerosis.
- Differentiate among the various types of hyperlipoproteinemia.
- Identify the various types of benign and malignant vascular tumors.

Connection to Physiology

See Unit 5, "Cardiovascular Integration and Heart Disease," for discussion of systolic and diastolic blood pressures of blood vessels:

- Total peripheral resistance (TPR) determines the rise or fall of diastolic blood pressure.
- Systolic, or active pressure, determines the stroke volume component.

Please visit us at www.Groupinsiders.com

© DeVry/Becker Educational Development Corp. All rights reserved.

1.2.2 Two Syndromes

Chronic/benign: 95%

Malignant hypertension: 5%

1. Chronic/Benign

Initially asymptomatic, but has long-term consequences:

- Left ventricular hypertrophy
- Congestive heart failure
- Coronary arteriosclerosis/myocardial infarction
- Intracerebral hemorrhage
- Aneurysm
- Chronic renal failure

2. Malignant Hypertension

- Acute, markedly elevated blood pressures
- Most commonly found in young, African-American males
- Presents with:
  - Marked increase in diastolic blood pressure
  - Papilledema and focal retinal hemorrhages
  - Left ventricular hypertrophy and, eventually, failure
- It most often results in early death from congestive heart failure, cerebrovascular accident, or renal failure.
- Extreme hypertension causes glomerular arterioles and glomerular capillaries to rupture.
- Fibrinoid necrosis of glomerular arterioles
- Renal cortex has "flea-bitten" appearance
- Untreated, leads to renal failure

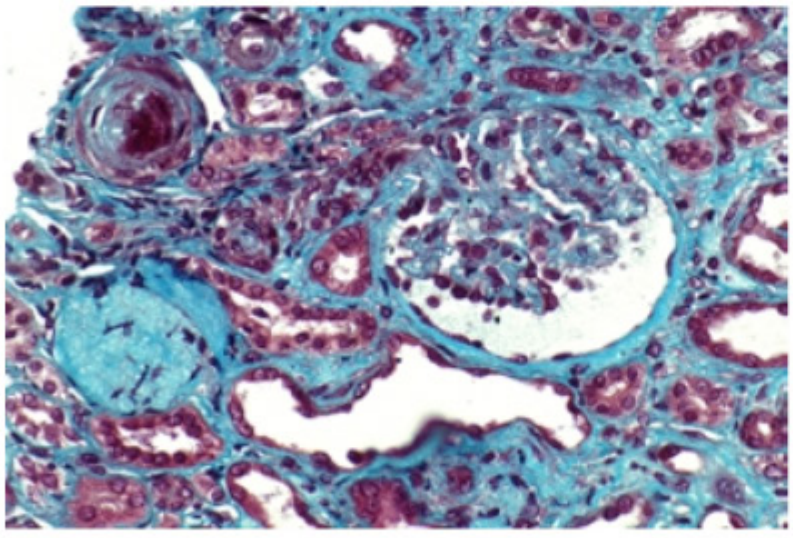

ISM/Phototake, Inc.

▲ **Figure 11–1.2** Malignant Nephrosclerosis

Please visit us at www.Groupinsiders.com

© DeVry/Becker Educational Development Corp. All rights reserved.

2 Arteriosclerosis

Sclerosis is the thickening or hardening of a body part. *Arteriosclerosis* is thickening of arteries with loss of elasticity being replaced by "hardening" of the arteries. The three types of arteriosclerosis are:

1. **Medial Calcification (Mönckeberg Medial Sclerosis)**
   - Dystrophic calcification of muscular arteries
   - Clinically insignificant
2. ***Arteriolo*sclerosis**
3. ***Ather*osclerosis**

2.1 Arteriolosclerosis

Arteriolosclerosis is the hardening of the small arteries and arterioles. The two types of this disease are hyaline arteriolosclerosis and hyperplastic arteriolosclerosis.

2.1.1 Hyaline Arteriolosclerosis

Etiology

- **Diabetes mellitus:** Non-enzymatic glycosylation of basement membrane proteins
- **Chronic hypertension:** Increased pressure pushes plasma proteins into the vessel wall

Pathogenesis

Hyaline thickening and deposition of protein in the arteriole walls

Morphology

Pink, glassy vessel thickening with narrowed lumen

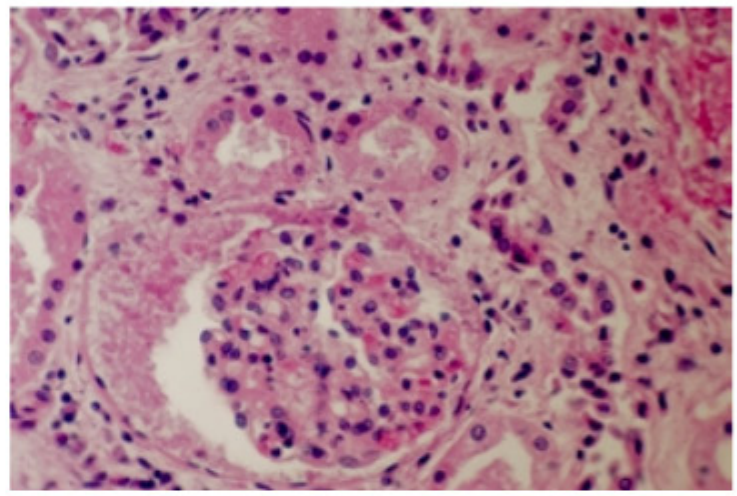

Ida Wyman/Phototake, Inc.

▲ **Figure 11–2.1A** Hyaline Arteriolosclerosis

2.1.2 Hyperplastic Arteriolosclerosis

Etiology Acute (malignant) hypertension

Pathogenesis Smooth muscle hyperplasia in response to pressure

Morphology Onion skin appearance of vessels

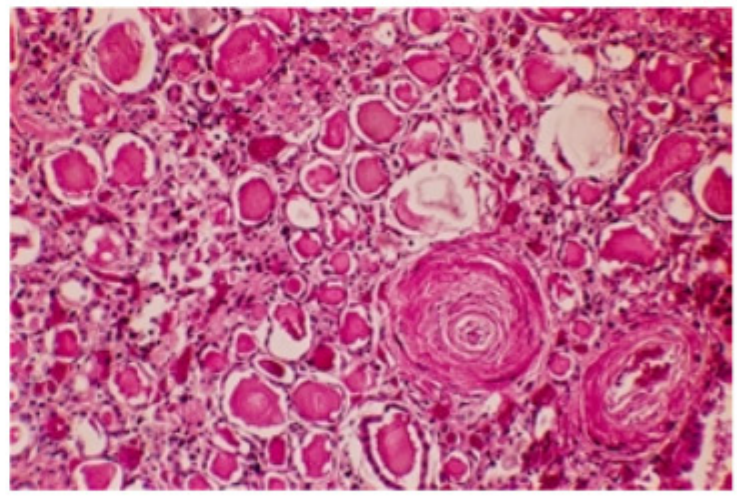

Ida Wyman/Phototake, Inc.

▲ **Figure 11–2.1B** Hyperplastic Arteriolosclerosis

Please visit us at www.Groupinsiders.com

© DeVry/Becker Educational Development Corp. All rights reserved.

2.2 Atherosclerosis

Atherosclerosis is the hardening of muscular and elastic arteries. It is caused by the formation of fibrous plaques with a lipid-rich core on the sides of the arteries. Plaque formation begins with injury to the endothelial cells lining the arteries. Atherosclerosis is the most frequent cause of vascular disease-associated morbidity and mortality.

Etiology

Risk factors for endothelial cell injury:

- Age, male gender, family history
- Hypertension
- Hyperlipidemia
- Diabetes mellitus
- Smoking
- Others

Pathogenesis

- Plaque formation begins with endothelial cell injury:
  - Hypercholesterolemia
  - Hypertension
  - Hyperhomocysteinemia
  - Mechanical injury
  - Immune mechanisms
- Inflammation with macrophages and platelets to repair endothelium.
- Inflammatory cells stimulate medial smooth muscle hyperplasia.
- These smooth muscle cells then migrate to the intimal layer, where cholesterol enters to meet with already existing macrophages to form foam cells.
- These foam cells are covered by a fibrous plaque, which is now referred to as an atheromatous plaque or visible fatty streak.

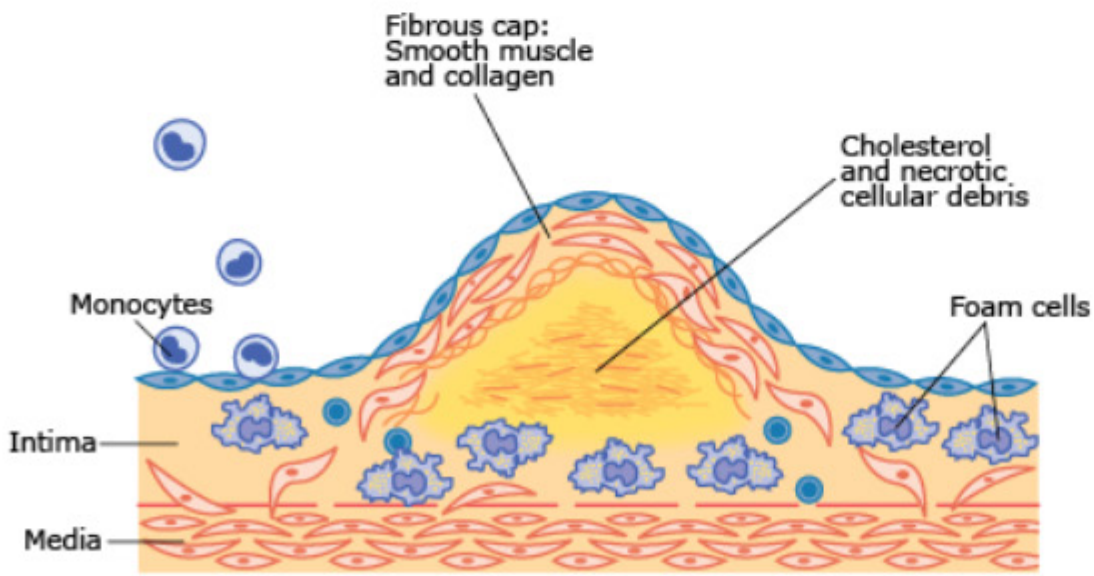

▲ **Figure 11–2.2A** Atherosclerosis

Please visit us at www.Groupinsiders.com

© DeVry/Becker Educational Development Corp. All rights reserved.

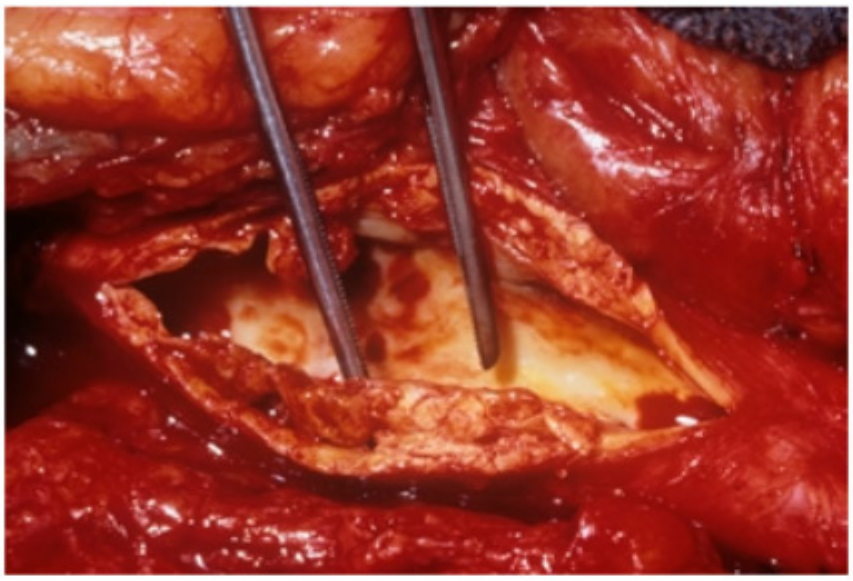

SIU/Visuals Unlimited, Inc.

▲ **Figure 11–2.2B** Atherosclerosis

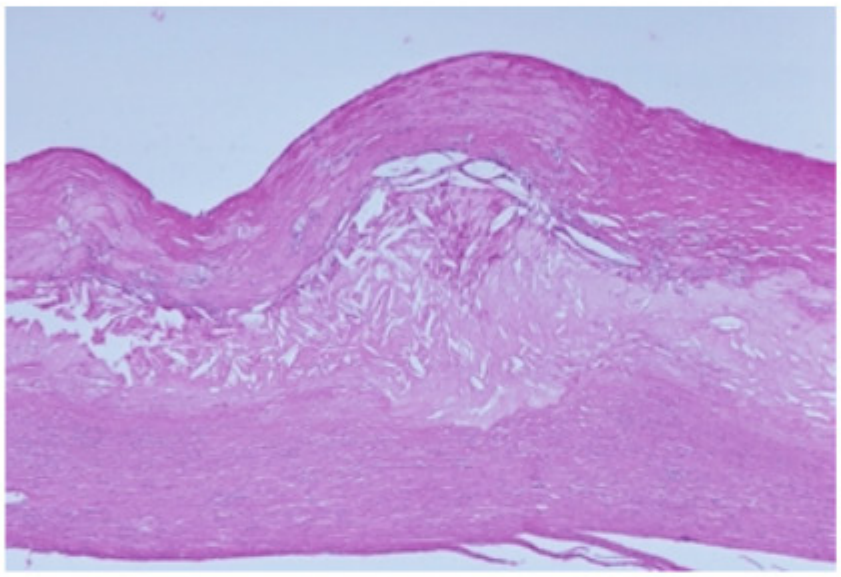

Carolina Biological Supply Co./Visuals Unlimited, Inc.

▲ **Figure 11–2.2C** Atherosclerosis (Histology)

- Over time, the plaque can become calcified or ulcerated.
- Ruptured or ulcerated plaque becomes a nidus for thrombus formation.
- *C-reactive peptide (CRP)* is elevated in patients with inflammatory plaques.

Clinical Findings Developing thromboses (atheromatous plaques) eventually erode and ulcerate, throwing off emboli, which journey to and lodge in smaller tributaries, resulting in ischemia to the following distal tissues and its manifestation:

- Coronary arteries: Myocardial infarction
- Carotid arteries: Stroke
- Mesenteric arteries: Ischemic bowel disease

Please visit us at www.Groupinsiders.com

© DeVry/Becker Educational Development Corp. All rights reserved.

3 Hyperlipoproteinemia

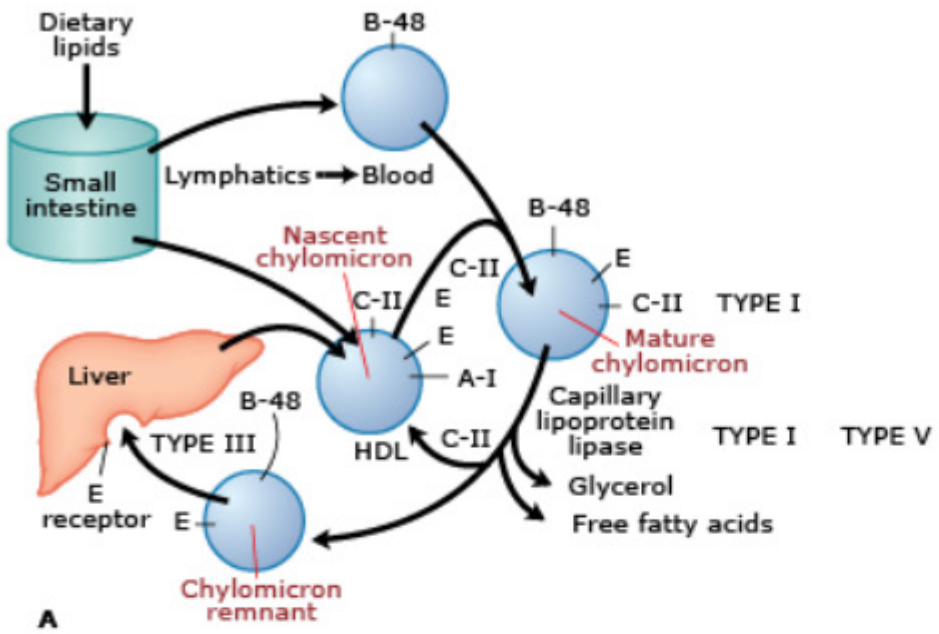

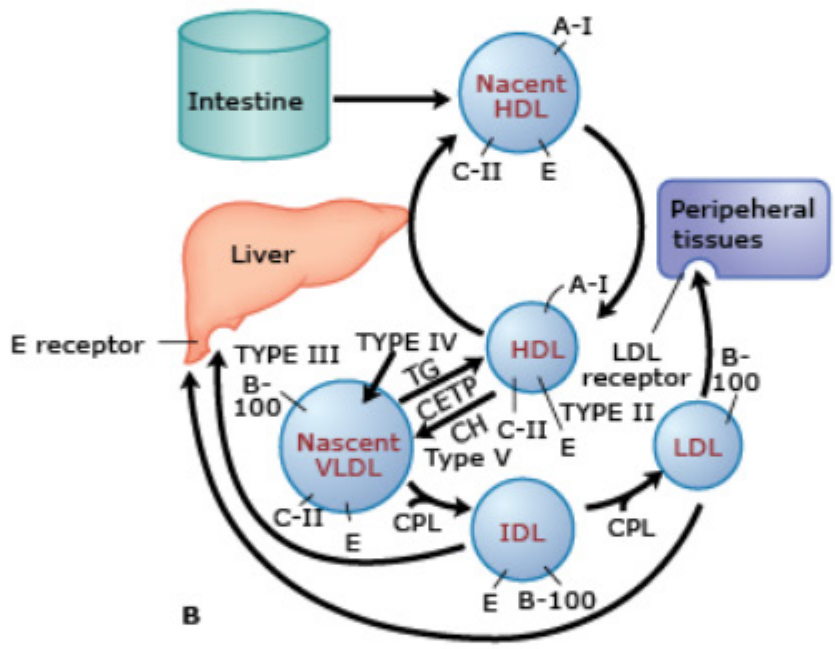

CHYLOMICRONS

Tryglyceride derived from diet (saturated fat)

VLDL

TG derived from liver

LDL

Carries CH; derived from VLDL

HDL-CH

"Good CH"; higher the better because it defoams foam cells and renders them less atherogenic.
There is no need for fasting for accurate HDL-CH.

CHYLOMICRONS: Supranate

VLDL (TG/5): Infranate

Only ↑TG causes turbidity of plasma, not ↑in cholesterol.

▲ **Figure 11–3.0** Lipid Metabolism and Hyperlipoproteinemias

Please visit us at www.Groupinsiders.com

© DeVry/Becker Educational Development Corp. All rights reserved.

3.1 Type I Hyperlipoproteinemia

Type 1 hyperlipoproteinemia is a rare childhood disease of autosomal recessive pattern.

Pathogenesis

- Deficiency in *capillary lipoprotein lipase* and defect in *ApoC$_2$*.
- This causes an unnatural increase in chylomicrons, and thus serum *triglycerides leading to pancreatitis*.

Clinical and Laboratory Findings

- Eruptive skin xanthomas
- Turbid supranate
- Triglycerides >1,000 (up to 10,000)

3.2 Type II Hyperlipoproteinemia

- Autosomal dominant
- LDL receptor deficiency in liver
- LDL >190
- TG <300 is known as type IIa
- TG >300 is known as type IIb

3.2.1 Acquired Hypercholesterolemia

- Primary hypothyroidism results in decreased LDL receptor synthesis and function.
- Nephrotic syndrome results in an increase in LDL, correlating to the degree of hypoalbuminemia.
- Extrahepatic cholestasis causes an increase in cholesterol due to the blockage of bile excretion.

3.2.2 Familial Hypercholesterolemia

- Autosomal dominant disorder
- Deficiency of LDL receptors
- Premature coronary arterial disease and strokes
- Tendon xanthomas in the Achilles tendon is pathognomonic.
- Xanthelasma are raised plaques on the eyelids.

Biophoto Associates/Science Source

▲ **Figure 11–3.1** Hyperlipoproteinemia

GIRAND/BSIP/SuperStock

▲ **Figure 11–3.2** Xanthelasma

Please visit us at www.Groupinsiders.com

© DeVry/Becker Educational Development Corp. All rights reserved.

3.3 Type III Hyperlipoproteinemia

- Familial dysbetalipoproteinemia (remnant removal disease)
- Defect in *$ApoE_2$* synthesis
- Increase in *IDL*
- LDL <190
- TG >300
- Palmar xanthomas

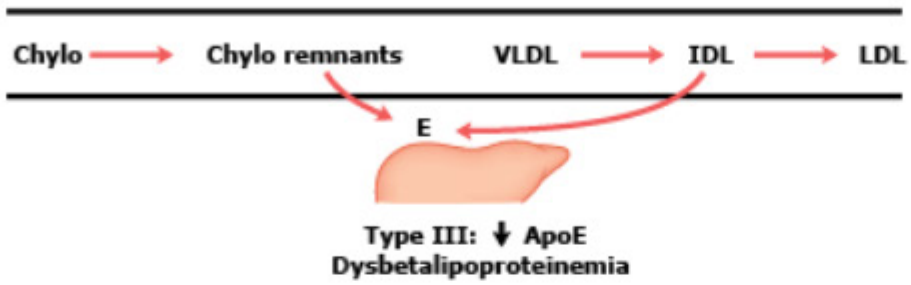

▲ **Figure 11–3.3** Type III Hyperlipoproteinemia

3.4 Type IV Hyperlipoproteinemia

- Familial *hypertriglyceridemia* is the most common lipid disorder.
- Increase in VLDL
- TG >300 but <1,000
- Serum cholesterol levels normal
- Eruptive xanthomas
- Autosomal dominant; associated with excess alcohol consumption, oral contraceptive use, and diabetes mellitus.

▼ **Table 11–3.4** Hyperlipoproteinemias

Type	Serum Elevation	Lipoprotein Elevation
I	Cholesterol and triglycerides	Chylomicrons
IIa	Cholesterol	LDL
IIb	Cholesterol and triglycerides	LDL, VLDL
III	Cholesterol and triglycerides	IDL
IV	Triglycerides	VLDL
V	Cholesterol and triglycerides	VLDL, chylomicrons

Dr. Ken Greer/Visuals Unlimited, Inc.

▲ **Figure 11–3.4** Types III and IV Hyperlipoproteinemia

Please visit us at www.Groupinsiders.com

© DeVry/Becker Educational Development Corp. All rights reserved.

4 Aneurysms

4.1 Abdominal Aortic Aneurysm (AAA)

This fusiform aneurysm develops in the abdominal aorta, between the renal arteries and their bifurcation.

Etiology

- Atherosclerosis
- Hypertension

Clinical Findings

- Presents as asymptomatic pulsatile mass.
- Rupture presents with severe back pain.

Dr. Barry Slavery/Visuals Unlimited, Inc.

▲ **Figure 11–4.1** Aneurysms

Important Concept

Important aneurysms to know for Step 1 Pathology:

- Mycotic aneurysm
- Berry (or saccular) aneurysm from topic on "Autosomal Dominant Polycystic Kidney" in chapter 13, "Renal Pathology."
- Syphilitic aneurysm

Please visit us at www.Groupinsiders.com

© DeVry/Becker Educational Development Corp. All rights reserved.

4.2 Aortic Dissection

Epidemiology

- Men with a mean age of 40 to 60 years.
- Young patients with a connective tissue disorder such as Marfan syndrome or Ehlers-Danlos syndrome.

Pathogenesis Cystic *medial degeneration* (CMD)

- Elastic tissue fragmentation
- Matrix material collects in areas of fragmentation in the tunica media
- Stressors such as pregnancy, hypertension, coarctation of the aorta, or connective tissue disease mentioned above may lead to an *intimal tear*:
  - Usually occurs within 10 cm of the aortic valve
  - Blood dissects proximally and/or distally

▲ **Figure 11–4.2** Cystic Medial Necrosis

Clinical Findings Acute onset of severe retrosternal chest pain radiating to the back

- Aortic valve regurgitation, which is shown to be widened on an echocardiogram.
- Loss of the upper extremity pulse due to compression of the subclavian artery.
- Rupture into the pericardial cavity resulting in cardiac tamponade is the most common cause of death in these patients.

Looking Ahead

See chapter 23, "Connective Tissue Pathology," for more on Marfan syndrome and Ehlers-Danlos syndrome.

Please visit us at www.Groupinsiders.com

© DeVry/Becker Educational Development Corp. All rights reserved.

5 Benign Vascular Tumors

5.1 Telangiectasia

Telangiectasia are small, dilated blood vessels located at the surface of the skin.

5.1.1 Spider Telangiectasia

Spider telangiectasia are associated with liver disease, pregnancy, and hyperestrinism.

BSIP/Phototake, Inc.

▲ **Figure 11–5.1A** Spider Telangiectasia

5.1.2 Hereditary Hemorrhagic Telangiectasia (Osler-Weber-Rendu Syndrome)

- Autosomal dominant disorder characterized by dilation and convolution of capillaries and venules of the skin and mucous membranes.
- Causes epistaxis or gastrointestinal bleeding.

Mediscan/Visuals Unlimited, Inc.

▲ **Figure 11–5.1B** Hereditary Telangiectasia

Please visit us at www.Groupinsiders.com

© DeVry/Becker Educational Development Corp. All rights reserved.

5.2 Hemangioma

- Localized increase in the number of vessels.
- Not technically tumors, but hamartomas.
- Vessels are often abnormally dilated.

5.2.1 Capillary ("Strawberry") Hemangioma

- Subcutaneous—skin, mucous membranes
- Small, bright red or blue lesions

BSIP/Phototake, Inc.

▲ **Figure 11–5.2** Capillary Hemangioma

5.2.2 Cavernous Hemangioma

- Visceral masses consisting of large, dilated vascular channels.
- Seen in *von Hippel-Lindau disease*, an autosomal dominant disorder with hemangioblastomas of the cerebellum, brainstem, and retina.

5.3 Sturge-Weber Syndrome

Characterized by facial port-wine stain, leptomeningeal venous angiomas, and neurologic manifestations—including mental deficiency and seizures.

5.4 Single (Simple) Lymphangioma

- Masses composed of small lymphatic channels
- Subcutaneous—head and neck, axilla

5.5 Cavernous Lymphangioma (Cystic Hygroma)

- Occurs in neck and axilla of children
- Massively dilated cystic spaces lined by endothelial cells
- Associated with Turner syndrome

Zephyr/Science Source

▲ **Figure 11–5.3** Sturge-Weber Syndrome

Please visit us at www.Groupinsiders.com

© DeVry/Becker Educational Development Corp. All rights reserved.

6 Malignant Vascular Tumors

6.1 Kaposi Sarcoma

- Caused by HHV-8 in immunocompromised patients
- Manifest as red-purple subcutaneous macules

Collection CNRI/Phototake, Inc.

▲ **Figure 11–6.1** Kaposi Sarcoma

6.2 Angiosarcoma

- Most common in liver (*hepatic angiosarcoma*)
- Associated with arsenic, polyvinyl chloride, and thorotrast (radioactive contrast)

Please visit us at www.Groupinsiders.com

© DeVry/Becker Educational Development Corp. All rights reserved.

7 Vasculitis

Vasculitis is a group of inflammatory disorders of the blood vessels.

7.1 Overview of Vasculitis

Etiology Inflammation caused by either:

- Antibody-dependent cellular cytotoxicity (type II hypersensitivity)
- Antigen-antibody complex deposition (type III hypersensitivity)

Pathogenesis

- Stages
  - Acute inflammation, either granulomatous (large vessel vasculitis), necrotizing (most others), or both (Wegener granulomatosis)
  - Healing by fibrosis
- Leads to vascular insufficiency caused by either:
  - Narrowing of vessels by inflammation and fibrosis
  - Thrombosis and infarction

Clinical Findings

- Multisystem inflammatory disease
- Rapidly progressive major organ dysfunction: Endothelial damage → luminal occlusion → end-organ ischemia → dysfunction
- Constitutional symptoms:
  - Fever
  - Weight loss
- Labs: High ESR, severe anemia (hemolysis), thrombocytosis (inflammation)
- Evidence of small-vessel inflammation:
  - In the kidneys: Active urinary sediment
  - In the lungs: Hemoptysis, dyspnea
  - In the skin: Palpable purpura/hemorrhage
- Acute neurologic changes:
  - Foot drop
  - Altered mental status

Please visit us at www.Groupinsiders.com

© DeVry/Becker Educational Development Corp. All rights reserved.

Diagnosis

- Tissue biopsy of affected organ to determine:
  - Vessel size
  - Histologic features of vessel inflammation:
    - —Vessel wall necrosis
    - —Granulomas/giant cells
    - —Immune complex and/or C3 deposition
    - —Angiography of mesenteric or cerebral vessels as clinically indicated
- Tests suggesting immune complex formation and/or deposition:
  - Rheumatoid factor and cryoglobulins
  - Antinuclear antibodies (ANA)
  - Low C3 or C4 levels (consumption)
  - Tests suggesting necrotizing vasculitis without immune complex deposition: ANCA
- Tests suggesting systemic inflammation:
  - ESR
- C-reactive protein (CRP)
- Categorized by size of vessel involved:
  - *Large vessels:*
    - —Giant cell (temporal) arteritis
    - —Takayasu arteritis
  - *Medium-sized vessels:*
    - —Kawasaki disease
    - —Polyarteritis nodosa (PAN)
  - *Small vessels:*
    - —*Pauci-immune vasculitis*
      - Wegener granulomatosis
      - Churg-Strauss syndrome
      - Microscopic polyangiitis
  - *Small vessel vasculitis with immune complex involvement:*
    - —Henoch-Schönlein purpura
    - —Buerger disease (a better and a more high-yield name for this condition [Buerger] is thromboangiitis obliterans).

Important Concept

Do not confuse Buerger disease with Berger disease. (Berger disease is covered under Henoch-Schönlein purpura topic 7.5.1.)

Please visit us at www.Groupinsiders.com

© DeVry/Becker Educational Development Corp. All rights reserved.

7.2 Large Vessel Vasculitis

7.2.1 Giant Cell (Temporal) Arteritis

- Most common form—usually affects elderly.
- Most often affects temporal, facial, and ophthalmic branches of carotid arteries.
- **Symptoms:** Headache, vision changes, systemic flu-like symptoms. Significant elevation in ESR.
- May cause blindness if untreated.
- **Treatment:** Corticosteroids

7.2.2 Takayasu Arteritis

- Most commonly seen in young women (15 to 45 years) of Asian descent.
- Inflammation and stenosis of medium and large arteries.
- Most commonly affects branches of the aortic arch.
- Classic presentation is *pulselessness* of the upper extremities, claudication, and vision changes.
- Multiple bypass surgeries usually performed; vessels heal with fibrosis, sometimes severe.
- **Treatment:** Corticosteroids

▲ **Figure 11–7.2** Takayasu Arteritis

Please visit us at www.Groupinsiders.com

© DeVry/Becker Educational Development Corp. All rights reserved.

7.3 Medium Vessel Vasculitis

7.3.1 Kawasaki Disease (Mucocutaneous Lymph Node Syndrome)

- Affects infants and young children; most common "acquired" childhood heart disease in the U.S.
- Acute necrotizing vasculitis of small- and medium-sized vessels
- Signs and symptoms
  - Fever
  - Conjunctivitis and oral erythema
  - Generalized *maculopapular desquamating rash*
  - Cervical lymphadenopathy
- Lesions = PAN
- May → aneurysms, thrombosis
- May → healing → luminal narrowing
- Anti-endothelial cell antibodies may be responsible for lesions
- **Treatment**
  - Self-limited in most; 1% to 2% mortality from coronary aneurysm or thrombosis (MI)
  - IV immunoglobulin

Wellcome Images/Custom Medical Stock Photo

▲ **Figure 11–7.3A** Kawasaki Disease

7.3.2 Polyarteritis Nodosa (PAN)

- Affects young adults: Male > female
- Systemic disease: Especially affects kidneys and GI tract
- Characterized by necrotizing, immune-mediated inflammation of small and medium arteries
- Associated with *HBV infection* (30%)
- Presentation
  - Abdominal pain and mononeuritis multiplex—most common presenting findings
  - Fever
  - Arthralgia
  - Rash
  - Kidney failure, hypertension
  - GI bleeding
- Diagnosed by biopsy or angiogram: *Classic → mesenteric vessel segmental luminal narrowing*

Connection to Pharmacology

Aspirin and corticosteroids should be administered under strict supervision due to increased risk for Reye syndrome and blood vessel rupture.

Memory Aid

Think of PAN as the adult version of Kawasaki disease "FEEL My conjunctivitis... ."

Fever, **E**rythematous rash, **E**dema, **L**ymphadenopathy, **M**ucosal involvement, and **conjunctivitis**.

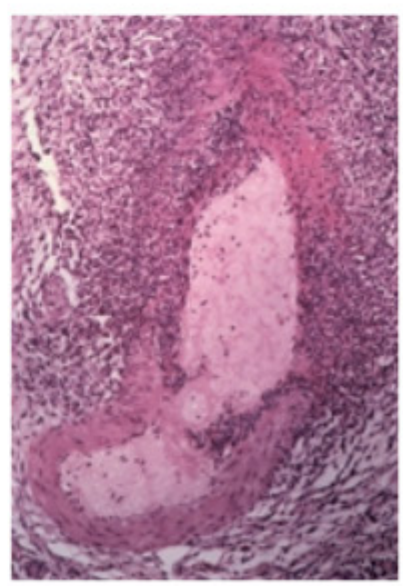

Wellcome Images

▲ **Figure 11–7.3B** Polyarteritis Nodosa

Please visit us at www.Groupinsiders.com

© DeVry/Becker Educational Development Corp. All rights reserved.

7.4 Small Vessel Pauci-immune Vasculitis

7.4.1 Churg-Strauss Syndrome (Allergic Granulomatous Angiitis)

- A necrotizing vasculitis of small- and medium-sized arteries and veins; potentially a variant of polyarteritis nodosa
- Prominent involvement of pulmonary vasculature, with *eosinophilia*, and asthma-like reactive airway symptoms; classically associated with asthma, nasal polyps, and (perhaps) use of leukotriene antagonists
- Skin, lung, gut, and kidney findings not unlike PAN are common
- *Eosinophilia* and granulomatous vasculitis seen on tissue biopsy
- Steroids very effective
- *p-ANCA* antibody positive in 70% of cases

7.4.2 Wegener Granulomatosis

- Rare; occurs in middle age
- Necrotizing granulomas of small- to medium-sized vessels
- Classic triad:
  - *Lung involvement*—bilateral pneumonitis
  - Necrotizing *glomerulonephritis*
  - Chronic sinusitis, ulcers
- Clinically, resembles anti-GBM disease, but with addition of sinonasal involvement
- High mortality if untreated
- Associated with *c-ANCA* antibody:
  c-ANCA = proteinase 3 (PR3)

7.4.3 Microscopic Polyangiitis (MPA)

- Very similar to Wegener and (sometimes) indistinguishable
- Associated with p-ANCA antibody
  - *p-ANCA* = myeloperoxidase (MPO)
  - Also associated with p-ANCA: UC, Crohn
- Less likely to have lung involvement

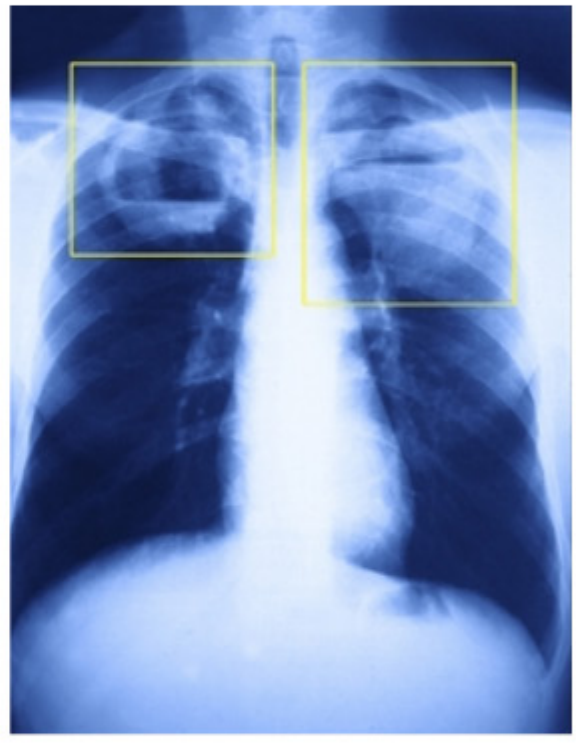
James Cavallini/Science Source

▲ **Figure 11–7.4** Wegener Granulomatosis

Please visit us at www.Groupinsiders.com

© DeVry/Becker Educational Development Corp. All rights reserved.

7.5 Small Vessel Involvement With Immune Complex Deposition

7.5.1 Henoch-Schönlein Purpura

- Most common vasculitis in children:
  - Precedes URTI
  - Vasculitis of the small vessels involving:
    - —Skin
    - —GI (intussusception)
    - —Kidney (hematuria)
      (Also known as Berger disease, which shares the same pathogenesis as HSP with IgA deposition on the glomerular basement membrane with *kidneys*.)
    - —Joint vessels
- *Biopsy shows IgA deposition* in arterioles, capillaries, and venules
- Palpable purpura found on lower extremities and buttocks

Mediscary/Visuals Unlimited, Inc.

▲ **Figure 11–7.5A** Henoch-Schönlein Purpura

7.5.2 Behçet Disease

- Systemic disease associated with CNS, eye, mucosal involvement
- Relapsing, small vessel vasculitis; most commonly presents as *recurrent oral and genital ulcers*
- *Pathergy* common (for example, numerous antigens provoke the response)
- Hypercoagulable state resulting in large vessel thrombosis is common
- Treatment evolving and includes anti-TNF therapy

Dr. Ken Greer/Visuals Unlimited, Inc.

▲ **Figure 11–7.5B** Behçet Disease

Please visit us at www.Groupinsiders.com

© DeVry/Becker Educational Development Corp. All rights reserved.

7.6 Other Important Small Vessel Vasculitis

7.6.1 Buerger Disease (Thromboangiitis Obliterans)

- Occurs in young males, especially heavy smokers
- Acute inflammation found in small- to medium-sized arteries of the extremities
- Causes claudication, thrombophlebitis (vascular inflammation), ulceration, and gangrene
- Improves with smoking cessation

Medicimage/Visuals Unlimited, Inc.

▲ **Figure 11–7.6A** Buerger Disease

7.6.2 Raynaud Disease (Primary)

- Vasculitis of medium-sized vessels in fingers and toes
- Exaggerated vasomotor response to cold or stress; found mostly in young women

7.6.3 Raynaud Syndrome (Secondary)

- Adult men and women
- Secondary to other diseases
  - For example: Systemic sclerosis, **CREST** syndrome
    - —**C**alcinosis (calcium deposits), usually in the fingers
    - —**R**aynaud
    - —**E**sophageal dysmotility
    - —**S**clerodactyly, a tapering deformity of the bones of the fingers
    - —**T**elangiectasia on fingers, face, or inside of the mouth

ISM/Phototake, Inc.

◀ **Figure 11–7.6B** Raynaud Phenomenon

Please visit us at www.Groupinsiders.com

© DeVry/Becker Educational Development Corp. All rights reserved.

Unit 4

Respiratory Pathology

Please visit us at www.Groupinsiders.com

Please visit us at www.Groupinsiders.com

1 Basics of the Pulmonary System

Facilitates the mechanism of air flow from the conducting zone.

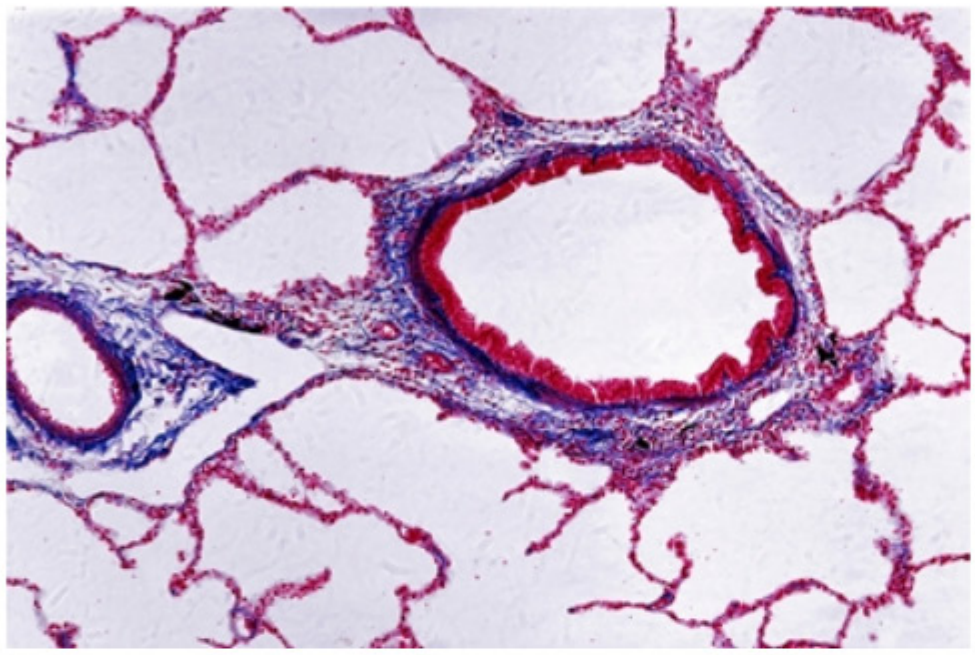

doc-stock/Visuals Unlimited, Inc.

▲ **Figure 12–1.0A** Lower Airways

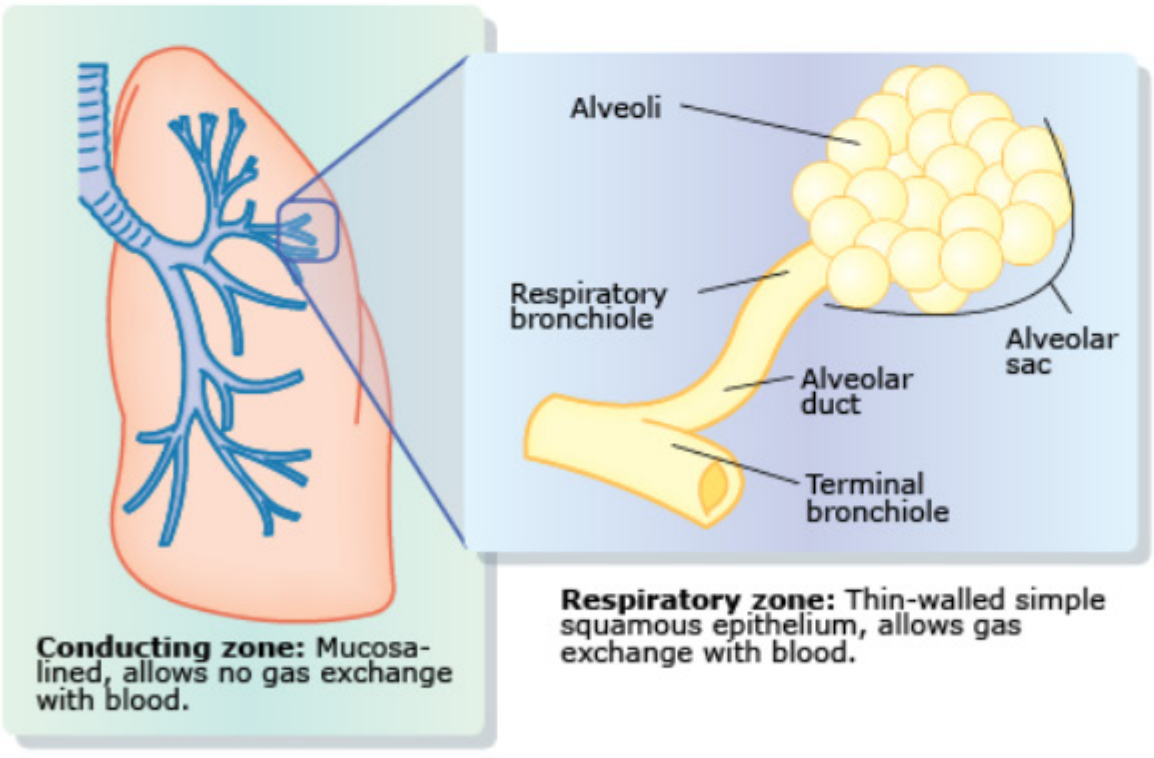

▲ **Figure 12–1.0B** Conducting Zone and Respiratory Zone

USMLE® Key Concepts

For Step 1, you must be able to:

- Differentiate amongst the four types of chronic obstructive lung disease and interpret their findings on pulmonary function tests.
- Identify various types of restrictive lung disease and decipher their findings using pulmonary function tests.
- Explain the differences between various types of pulmonary lung cancers.

Please visit us at www.Groupinsiders.com

© DeVry/Becker Educational Development Corp. All rights reserved.

2 Pulmonary Function Tests

2.1 Calculation of the Alveolar-arterial (A-a) Gradient

- An increased A-a gradient indicates hypoxemia of pulmonary origin.
- A normal A-a gradient indicates hypoxemia of extrapulmonary origin.
- Calculation of alveolar gas exchange.
- A-a gradient of >30 mHg indicates a medically significant value: Examples of hypoxemia include ventilation, diffusion, and perfusion defects along with right-to-left cardiac shunts. See chapter 1, "Cellular Pathophysiology," for more on hypoxia.
- Normal A-a gradient hypoxemia is caused by the following:
  - Depression of the respiratory center in the medulla.
  - Upper airway obstruction: Epiglottitis due to *H. influenzae* or croup due to parainfluenza virus.
  - Chest bellows dysfunction:
    —Paralyzed diaphragm
    —ALS

Connection to Physiology

See *Physiology*, chapter 1, "Anatomy."

2.2 Spirometry

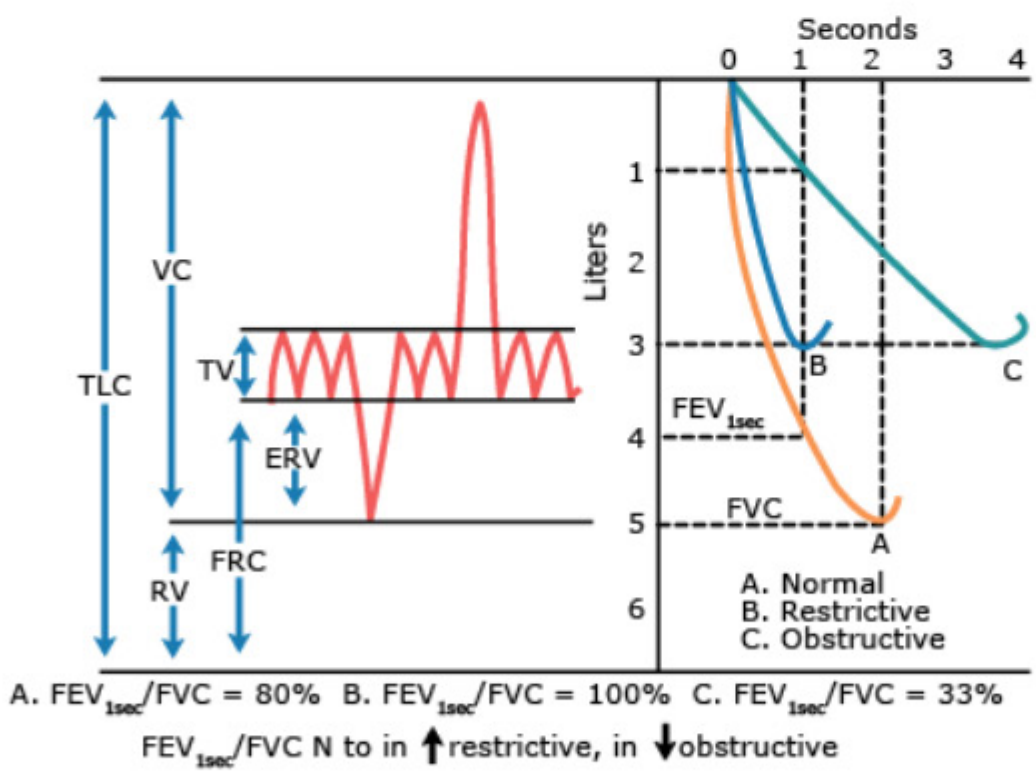

▲ **Figure 12–2.2** Spirometry

FEV_{1sec} / FVC N to ↑ in restrictive, ↓ in obstructive

Please visit us at www.Groupinsiders.com

© DeVry/Becker Educational Development Corp. All rights reserved.

3 Atelectasis

- *Atelectasis* is the collapse of areas of aerated lung parenchyma.
- There are two types of atelectasis:

  1. Compression atelectasis: Pleural cavity partially or completely filled by fluid pus, blood, or air compressing respiratory components that participate in gas exchange.

  2. Resorption atelectasis: Occurs 24 to 36 hours post-surgical. Air is resorbed out of the distal airways via pulmonary capillaries. Patient presents fever and, upon physical examination, no breath sounds or tactile fremitus are observed.

- **Clinical significance:** Reduces oxygenation and predisposes to infection.

3.1 Adult Respiratory Distress Syndrome

- Damage to alveolar-capillary interface results in leaking of protein-rich fluid into alveoli.
- Results in intra-alveolar hyaline membranes, leading to impaired gas exchange.
- Causes:
  - Septic shock is the most common cause.
  - Gastric aspiration
  - Severe trauma
    - —Amniotic fluid emboli
    - —Hantavirus transfusion reactions
    - —Drugs (bleomycin)

Please visit us at www.Groupinsiders.com

© DeVry/Becker Educational Development Corp. All rights reserved.

Pathogenesis

- Whatever the cause may be, alveolar macrophages are involved. They release cytokines, attracting droves of neutrophils, causing massive damage to type I and type II pneumocytes.
- Due to damage to the alveoli, dense proteinaceous debris such as increased *hyaline*, and desquamated cells, including lamellar bodies in type II pneumocytes, accumulate in the lung parenchyma.
- Diffuse alveolar damage with hyaline accumulation in the parenchyma.

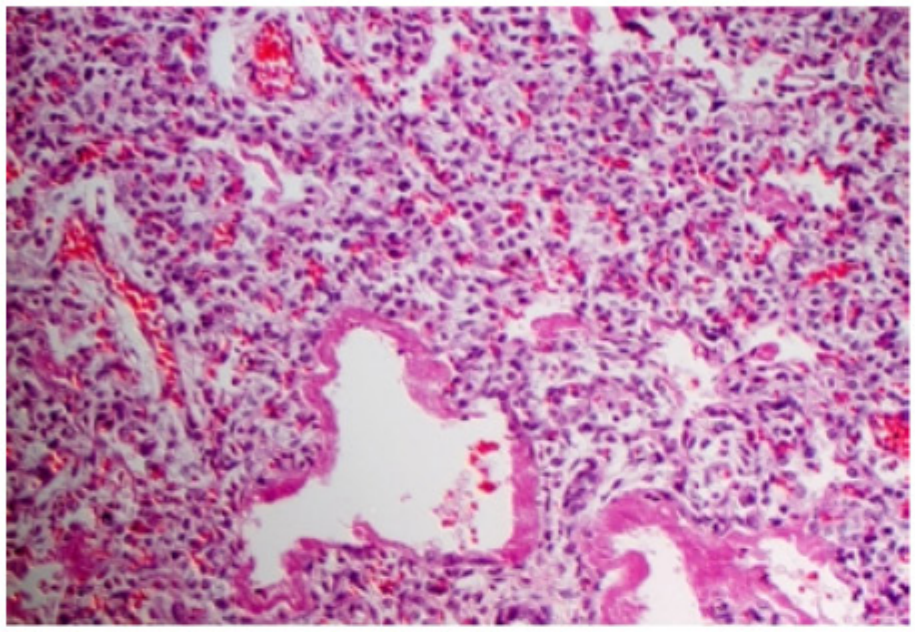

J.L. Carsory/Custom Medical Stock Photo

▲ **Figure 12–3.1** Alveolar Damage

Clinical Features

- Dyspnea and tachypnea
- Increasing cyanosis and hypoxemia progressing to respiratory failure
- Diffuse bilateral interstitial fibrosis and "honeycomb" appearance of the lung

3.2 Hyaline Membrane Disease

- Lack of surfactant (immaturity) results in respiratory failure in the newborn (most common cause).
- *What is surfactant?*
  - Substance made up of primarily dipalmitoyl phosphatidylcholine (lecithin), secreted by type II pneumocytes.
  - Reduces surface tension, allowing expansion and preventing atelectasis.
  - Assessed by fetal pulmonary maturity index (lecithin-sphingomyelin ratio).
- Most common cause of death in premature infants.
- Also associated with maternal diabetes (high levels of insulin in fetal blood counteract steroids and, therefore, decrease formation of surfactant).
- Birth by C-section (no steroids from stress of birth).
- O_2 must be given as therapy and, no matter how much precaution is exercised, the newborn is at high risk of blindness and bronchopulmonary dysplasia.

Please visit us at www.Groupinsiders.com

© DeVry/Becker Educational Development Corp. All rights reserved.

4 Chronic Obstructive Lung Disease (COPD)

- Group of disorders with airflow obstruction.
- Result is V/Q mismatch.
- Decreased FEV1 with increased or normal forced vital capacity.
- **Obstructive:** Increase in resistance to airflow due to partial or complete obstruction.
  - Emphysema
  - Chronic bronchitis
  - Asthma
  - Bronchiectasis
- **Pulmonary mechanics in the bronchioles:** During inspiration, air is conducted through the conducting zone on its way to the respiratory zone, where gas exchange takes place. After gas exchange has taken place, the CO_2 must be removed. This process of ensuring that air is exhaled through the airways unimpeded is the responsibility of elastic tissue. Elastic tissue does this through a process called *applying radial traction* to maintain airway patency.

4.1 Emphysema

- **Definition:** Abnormal, permanent enlargement of the air spaces distal to the terminal bronchiole accompanied by destruction of their walls.
- Strongly associated with smoking.
- **Clinically:** Increased A/P diameter of the chest, increased TVC, hypoxia.
- **Types**
  - **Centrilobular (aka Centriacinar) Emphysema**
    This is a condition in which the patient has been smoking, which tends to be chemotactic to neutrophils. These neutrophils release excessive elastase that inactivate α-1-antitrypsin, thereby destroying elastic tissue that normally maintains the airway patent. Granted, not all of the elastic tissue is lost. It tends to affect the elastic tissue in the upper lobe where air will be able to get in, but then gets trapped in the respiratory bronchiole, increasing residual volume. Compare this with panacinar emphysema type, below.

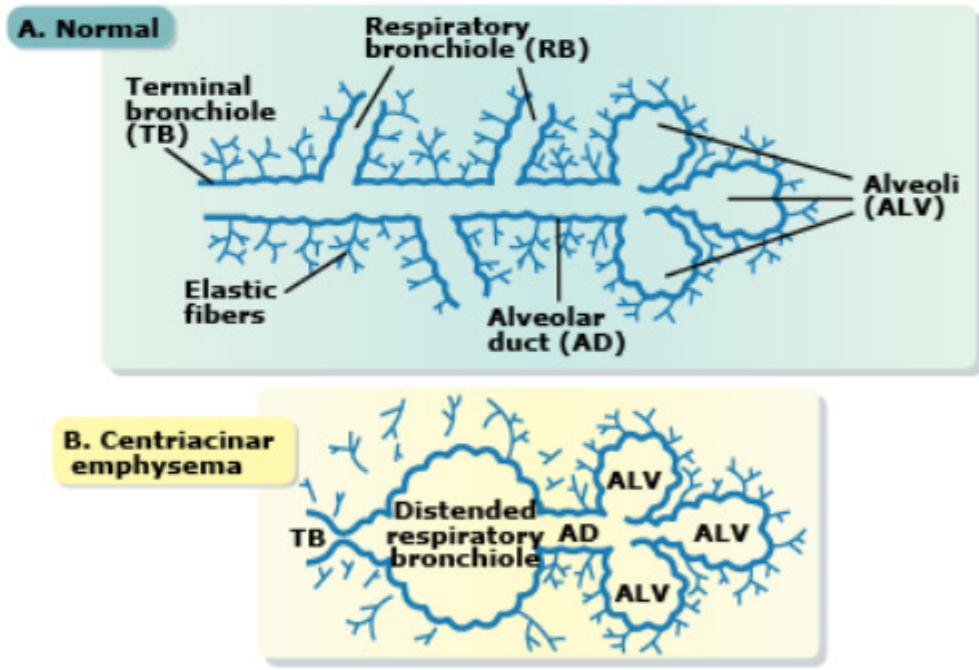

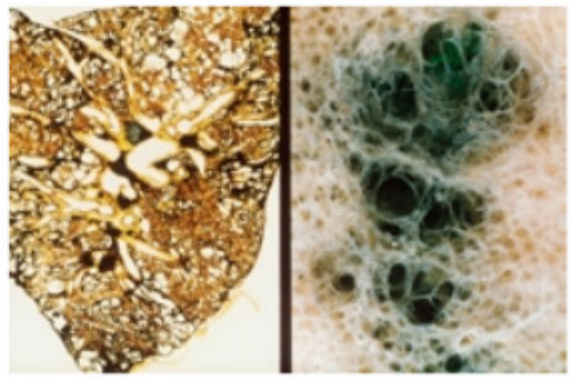

Biophoto Associates/Science Source

▶ **Figure 12–4.1A**
Centrilobular Emphysema

Please visit us at www.Groupinsiders.com

© DeVry/Becker Educational Development Corp. All rights reserved.

- **Panacinar Emphysema**
  This is a condition in which the patient is genetically lacking α-1-antitrypsin, and also can be seen in smokers. The entire respiratory unit of the entire lung has been destroyed. The genetics for α-1-antitrypsin deficiency include the following:
  — pi gene on c14
  — piZ allele codes for structurally deficient protein that accumulate in liver
  — piZZ in homozygous states associated with panacinar emphysema and hepatic cirrhosis
  See chapter 15, "Hepatobiliary Pathology."

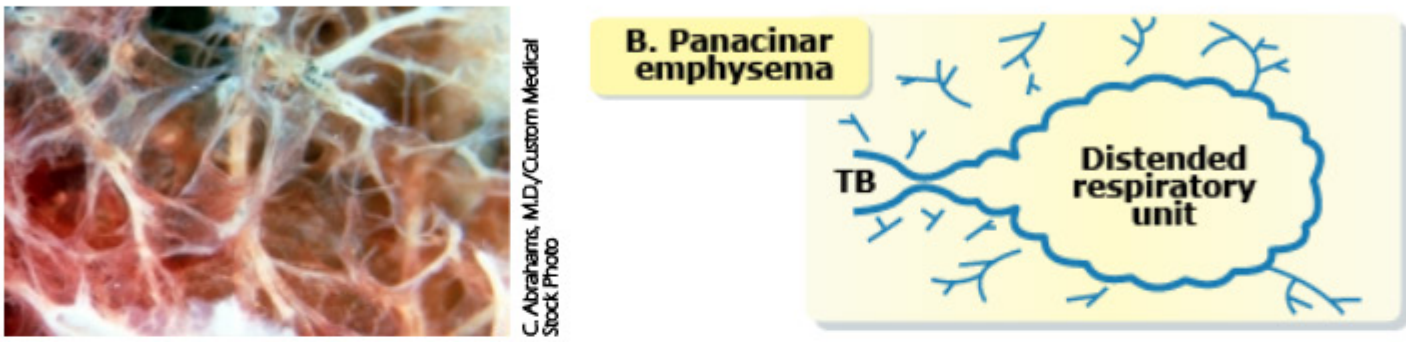

C. Abrahams, M.D./Custom Medical Stock Photo

▲ **Figure 12–4.1B** Panacinar Emphysema

Clinical Findings

- Late onset of decreased levels of PaO_2 results in the stimulation of aortic/carotid bodies with decreased (respiratory alkalosis) to normal $PaCO_2$.
- Lungs are hyperinflated, resulting in the heart taking on a vertical direction.
- Chest x-ray shows increased anterior-posterior diameter with a depressed diaphragm.

Mediscan/Visuals Unlimited, Inc.

▲ **Figure 12–4.1C** Chest X-Ray of Emphysema

4.2 Chronic Bronchitis

Definition

Patient who has persistent cough with sputum production for at least three months in at least two consecutive years.

- Hypoxemia has an early onset versus emphysema.

Pathogenesis

- Chronic irritation by inhaled substances (especially by smoking).
- Hyperplasia of submucosal glands results in hypersecretion of mucus (increased Reid index).

Clinical Findings

- Upon inspiration, O_2 can bypass the mucus plugs and enter the alveoli, but the issue lies with the decreased ability to exhale, thus trapping CO_2 (↑ **$PACO_2$**) and resulting in chronic respiratory acidosis: blue bloater (cyanosis and wheezing).
- Chest x-ray reveals a large, horizontally oriented heart.

Please visit us at www.Groupinsiders.com

© DeVry/Becker Educational Development Corp. All rights reserved.

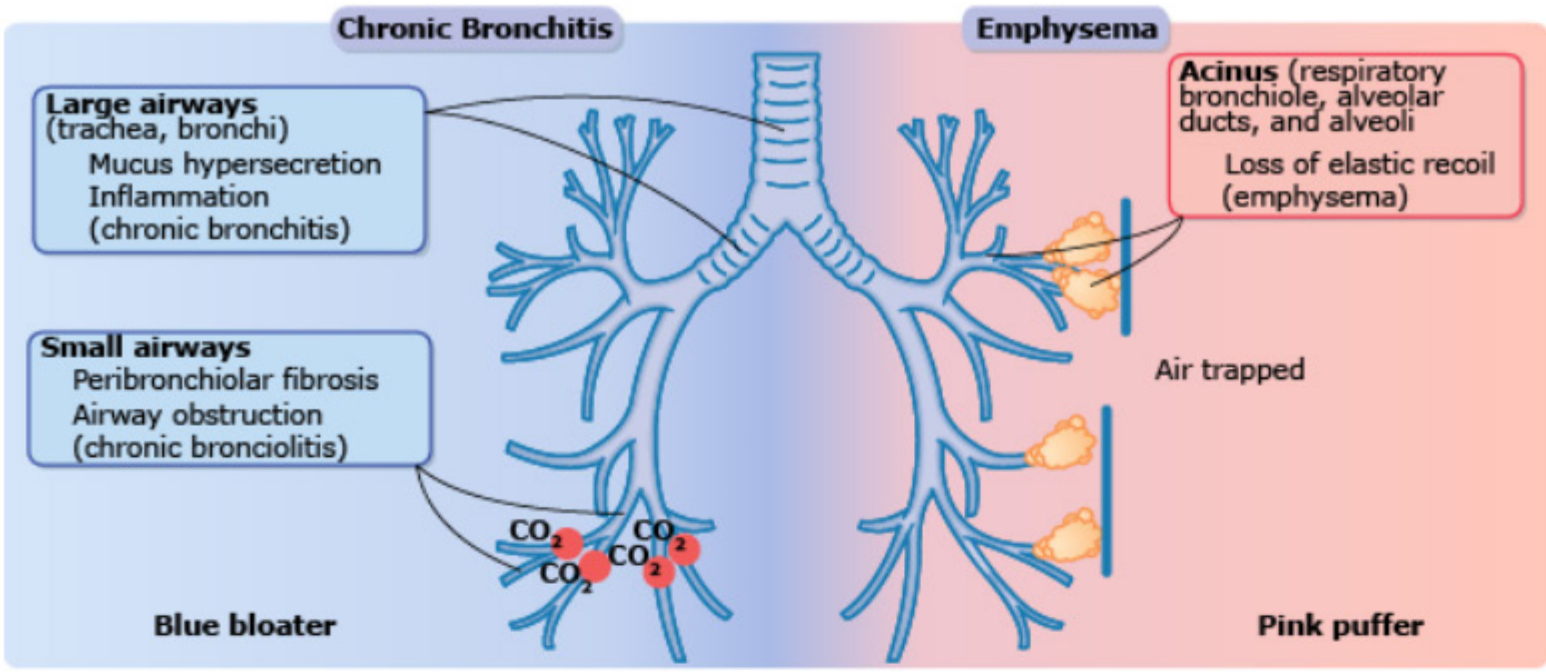

▲ **Figure 12–4.2** Chronic Bronchitis vs. Emphysema

4.3 Asthma

- Chronic relapsing inflammatory disorder of airways characterized by reversible bronchoconstriction.

Types

- **Atopic Asthma (Most Common)**
  - Environmental antigens
  - Type I hypersensitivity via IgE bound to mast cells
  - Begins in childhood
- **Intrinsic Asthma**
  - Initiated by diverse, nonimmune mechanisms: aspirin, viral infections, exercise
  - Think adults

Pathogenesis

- Chronic airway inflammation and bronchial hyper-responsiveness
- Antigens stimulate induction of $CD4^+Th_2$-cells
- Mast cell release, inflammation, and bronchoconstriction

Clinical Features

- Attack lasts several hours
- Prolonged coughing, with dyspnea and wheezing on expiration
- Status asthmaticus: Severe form of asthma leading to respiratory failure
- Episodic, reversible airway disease

Important Concept

Clinical Pearl

Respiratory alkalosis occurs initially and, if the condition worsens with increased obstruction, respiratory acidosis occurs. This signals the need for intubation.

Please visit us at www.Groupinsiders.com

© DeVry/Becker Educational Development Corp. All rights reserved.

4.4 Bronchiectasis

- Chronic necrotizing infection of the bronchi and bronchioles, leading to abnormal dilation of the airways

Biophoto Associates/Science Source

▲ **Figure 12–4.4** Dilated Bronchi and Bronchioles in Bronchiectasis

- Predisposing conditions (obstruction)
  - Tumor, foreign bodies, mucous impaction
  - Chronic sinusitis, as seen with cilia immobility syndromes

Clinical Features

- Fever
- Persistent cough and foul-smelling sputum
- Recurrent infections can lead to lung abscess

Pathogenesis

- Obstruction and infection
- Bronchial wall inflammation with weakening and dilation of airways

Pathology

- **Gross:** Dilated airways (most often lower lobes)
- **Microscopic:** Acute and chronic inflammatory exudates within walls of bronchi and bronchioles

Please visit us at www.Groupinsiders.com

© DeVry/Becker Educational Development Corp. All rights reserved.

5 Restrictive Lung Disease

- Disorders with reduced lung expansion and reduced TLC. Includes:
  - Bony abnormalities
  - Neuromuscular diseases
  - Interstitial lung diseases

Definition

Heterogeneous group of diseases characterized by diffuse and chronic involvement of the pulmonary connective tissue and interstitium.

Pathophysiology

- Reduced oxygen diffusing capacity
- Reduced lung volume
- Reduced pulmonary compliance
- Secondary pulmonary hypertension and cor pulmonale

Restrictive Lung Disease Types:

↓ Compliance, ↑ Elasticity. FEV_{1sec}/FVC N/ ↑. Alveolitis → fibrosis

- **Pneumoconiosis**
  - Coal dust anthracosis
  - Silicosis
  - Berylliosis
  - Asbestosis
- **Hypersensitivity**
- **Sarcoidosis**
- **Idiopathic Pulmonary Fibrosis**

5.1 Pneumoconiosis

- **Definition:** Pulmonary reaction to inhalation of mineral dusts.
- **Definition of progressive massive fibrosis(PMF):** Fibrosing reaction in the lung that can be a complication of any pneumoconiosis.

5.1.1 Coal Workers Pneumoconiosis

- Inhalation of coal dust (carbon and silica)
- Anthracosis:
  - Inhalation of carbon dust
  - Typically benign with carbon-laden macrophages

Types

- Simple (coal macules around bronchioles)
- Progressive massive fibrosis
  - Fibrotic nodules filled with black fluid
  - Can be associated with bronchiectasis and pulmonary hypertension

Anthrocotic depositions secondary to coal workers pneumoconiosis

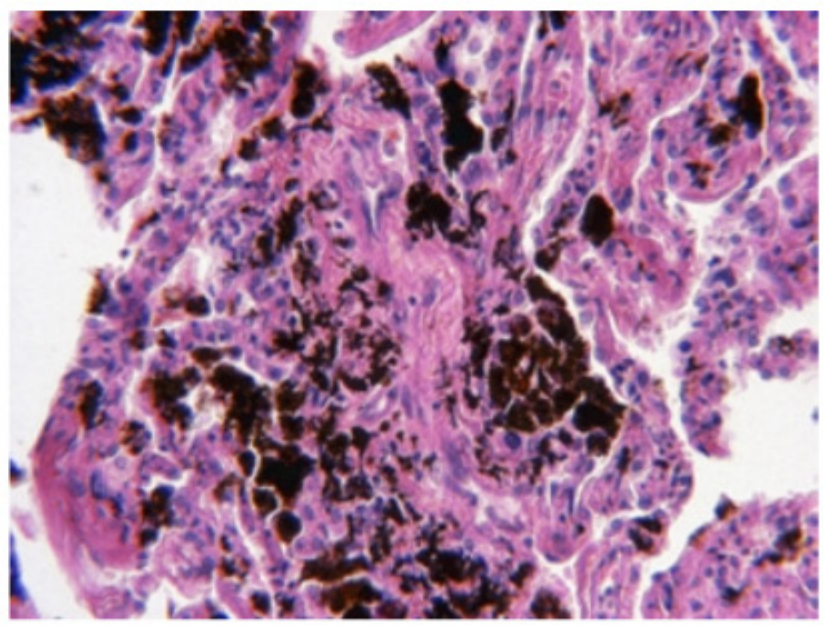

Dr. Gary Gaugler/Science Source

▲ **Figure 12–5.1A** Anthrocotic Depositions

Please visit us at www.Groupinsiders.com

© DeVry/Becker Educational Development Corp. All rights reserved.

5.1.2 Pneumoconiosis: Silicosis

- Lung disease caused by inhalation of crystalline silicon dioxide.
- **Epidemiology:** Most prevalent chronic occupational disease (miners, glass manufactures, and stone cutters) in the world.
- Tiny, discrete pale to blackened nodules in the upper zones of the lungs.
- Scarring has contracted the upper lobe into a small dark mass with pleural thickening.
- Usually presents as a slowly progressive, nodular, and fibrosing pneumoconiosis.
- Increased susceptibility to TB.

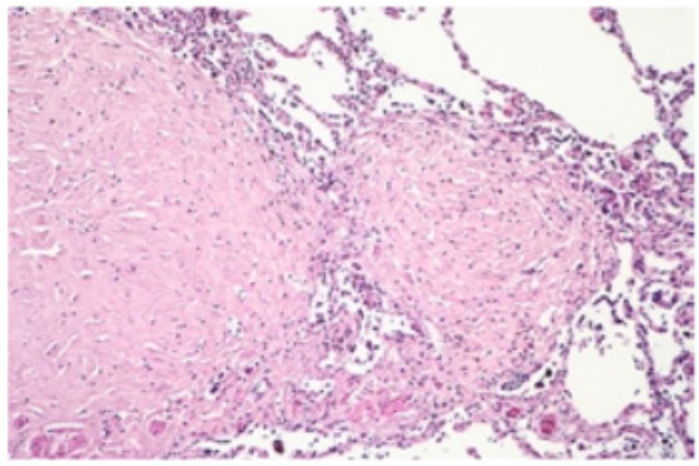

Dr. Gladden Willis/Visuals Unlimited, Inc.

▲ **Figure 12–5.1B** Silicotic Nodule

5.1.3 Pneumoconiosis: Asbestosis

Pathophysiology

- Inhalation of asbestos fibers.
- Asbestos (ferruginous) bodies: Fibers are coated by alveolar macrophages with iron, stained with Prussian blue stain, which appear golden brown, fusiform with a translucent center.
  - Taken up by macrophages, resulting in fibroblastic response resulting in diffuse pulmonary interstitial fibrosis.
  - Also shows dense hyalinized fibrocalcific plaques of the parietal pleura.

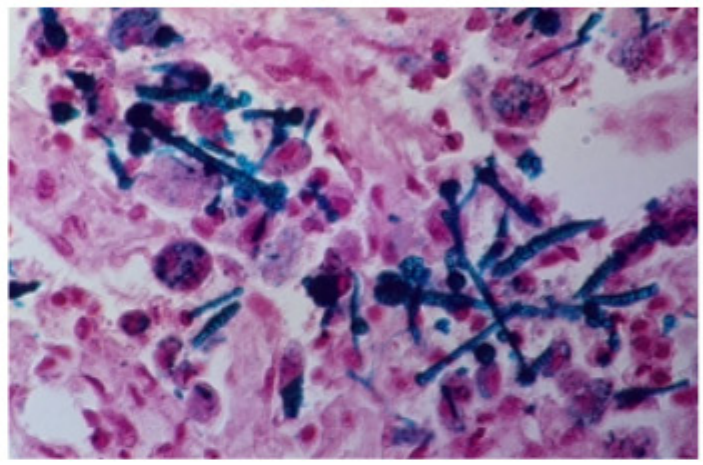

Ron Boardman/Life Science Images/FLPA/Science Source

▲ **Figure 12–5.1C** Ferruginous Bodies

Clinical Course

- **Occupations:** Shipyard, inhalation, construction, and brake-lining
- Diffuse pleural fibrosis
- Pleural effusion
- *Cancers:*
  - Bronchogenic carcinoma more common
  - Mesotheliomas

Dr. E. Walker/Science Source

◀ **Figure 12–5.1D** Mesothelioma

Please visit us at www.Groupinsiders.com

© DeVry/Becker Educational Development Corp. All rights reserved.

Types of Asbestosis

- **Serpentine**
  - Most common type
  - Curved and flexible
- **Amphibole**
  - Straight and brittle
  - More pathogenic and highly associated with mesotheliomas

5.1.4 Pneumoconiosis: Berylliosis

Occupations

Beryllium exposure in the aerospace industry and nuclear reactors

Pathology

- Type IV hypersensitivity reaction resulting in granuloma formation
- Acute pneumonitis
- Chronic exposure:
  - Pulmonary *noncaseating granulomas* and fibrosis
  - Hilar lymph node granulomas
  - Systemic granulomas

5.2 Hypersensitivity Pneumonitis

Definition

Immunologically mediated, predominantly interstitial lung disorders caused by intense, often prolonged exposure to inhaled organic dusts and related occupational antigens.

Pathology

- Interstitial pneumonitis composed of lymphocytes, plasma cells, and macrophages
- Interstitial fibrosis
- Obliterative bronchiolitis
- Granuloma formation (over 50% of cases)

Clinical Symptoms

- Fever, dyspnea, and cough
  - Farmers lung: Exposure to thermophilic actinomycetes
  - Silo fillers: Oxides of nitrogen
  - Pigeon breeders lung: Proteins from excreta and feathers of birds
  - Humidifier lung: Thermophilic bacteria in heated water reservoirs
  - Byssinosis: In textile workers, induced by inhalation of airborne fibers of cotton, linen, and hemp; referred to as "Monday morning blues."

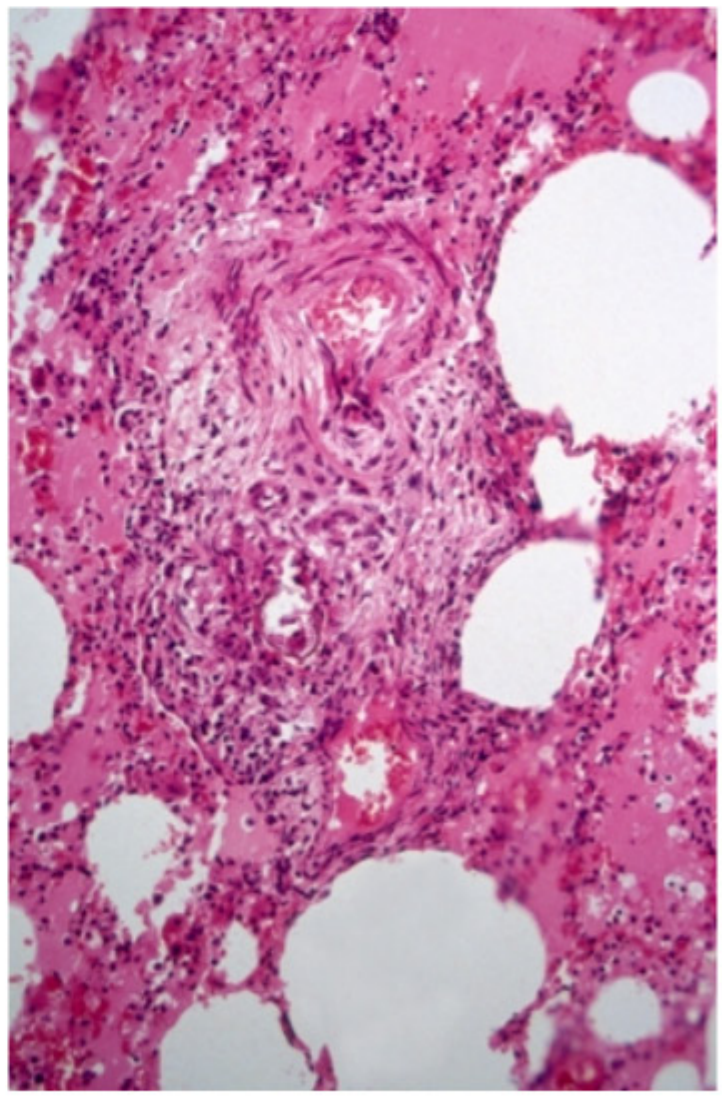

SB Lucas/Wellcome Images

▲ **Figure 12–5.2** Interstitial Granuloma

Please visit us at www.Groupinsiders.com

© DeVry/Becker Educational Development Corp. All rights reserved.

Types

- **Simple Pulmonary Eosinophilia** (Löffler syndrome):
  - Eosinophilia and septal infiltration of eosinophils
  - Transient pulmonary lesions
  - Benign clinical course
- **Tropical Eosinophilia** (infection with microfilariae): Secondary to chronic pulmonary eosinophilia
  - Parasitic, fungal, and bacterial infections
  - Hypersensitivity pneumonitis
  - Allergic bronchopulmonary aspergillosis
- **Chronic Eosinophilic Pneumonia:** Focal areas of consolidation with eosinophils located in septa and alveola

5.3 Sarcoidosis

- CD4 T_h cells interacting with unknown antigen processes by macrophages: Mycobacterial KATG protein
- Think young adult African-American

Pathology

- **Lungs**
  - Bilateral hilar lymphadenopathy
  - Increased serum angiotensin converting enzyme (ACE)
  - Increased *1-α-hydroxylase*: Hypercalcemia and hypercalciuria
- Hypergammaglobulinemia
- Anergy due to consumption of CD4 T_h; for example, negative tuberculin
- Skin lesions: Erythema nodosum
- Eye: Anterior uveitis
- Microscopic: Systemic noncaseating granulomas composed of tightly clustered epithelioid cells, often with Langhans or foreign-body-type giant cells

5.3.1 Idiopathic Pulmonary Fibrosis

Definition

Pulmonary disorder characterized histologically by diffuse interstitial inflammation and fibrosis; known histologically as usual interstitial pneumonitis.

Pathology

Alternating areas of fibrosis and normal appearing lung

Clinical Features

Progressive dyspnea, hypoxemia, and cyanosis

Please visit us at www.Groupinsiders.com

© DeVry/Becker Educational Development Corp. All rights reserved.

6 Pulmonary Vascular Disease

Pulmonary vascular disease may develop depending where the root cause may have begun. For example in chapter 10, "Cardiovascular Disorders" we discussed pulmonary congestion secondary to left-sided heart failure. Here we shall begin with the discussion of pulmonary vascular disease originating from the lung, either it be primary or secondary.

6.1 Pulmonary Hypertension

6.1.1 Primary

- Unknown etiology
- Poor prognosis
- Usually in the absence of heart/lung disease

6.1.2 Secondary

- COPD (most common): Increased pulmonary blood flow
- Eisenmenger syndrome : Increased resistance in pulmonary circulation
- Pulmonary embolism
- Hypoxic vasoconstriction
- Increased blood viscosity (for example, polycythemia)

6.1.3 Clinical Features

- Dyspnea and fatigue
- Right-sided heart failure

6.2 Pulmonary Infection

6.2.1 Pneumonia

Epidemiology

Classified as *community-acquired* or *nosocomial:*

- **Community-acquired:** Presence or absence of lung consolidation; typical or atypical
- **Typical community-acquired pneumonia**
  Extent of lung consolidation:
  - Majority are caused by bacteria, most commonly by *Streptococcus pneumoniae*.
  - Acquired by inhalation from an infected patient or aspiration of nasopharyngeal flora while sleeping.
  - Foreign particles may aspirate to different sites in the lung, depending on the position of the patient. Overall, the most common site of deposit of foreign particle aspiration is the superior segment of the right lower lobe in the supine position. In the erect position, foreign particles deposit in the posterobasal segment of the right lower lobe. In the right-sided position, they deposit in the posterior segment of the right upper lobe.

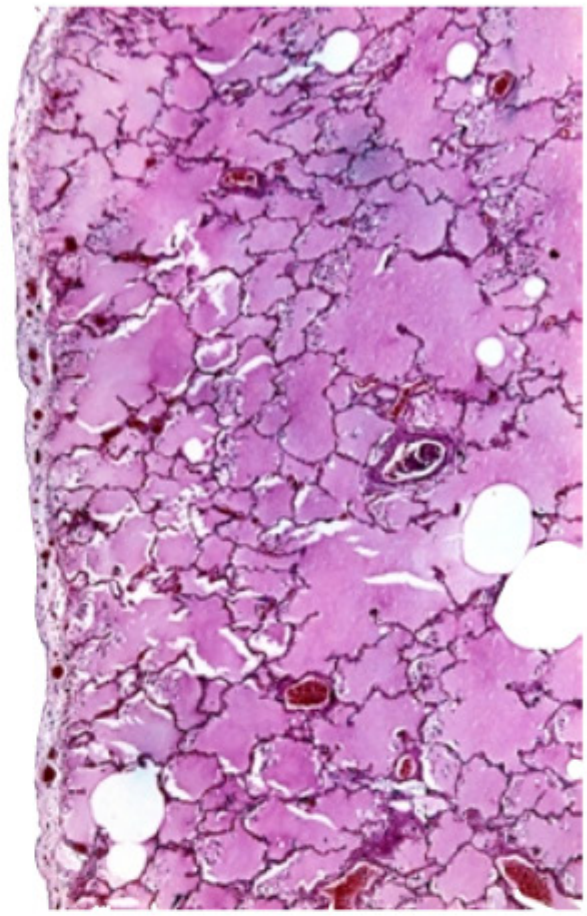
Biophoto Associates/Science Source

▲ **Figure 12–6.0** Hemosiderin-Laden Alveolar Macrophage

Connection to Physiology

See *Physiology*, chapter 22, "Five Major Causes of Hypoxemia."

Please visit us at www.Groupinsiders.com

© DeVry/Becker Educational Development Corp. All rights reserved.

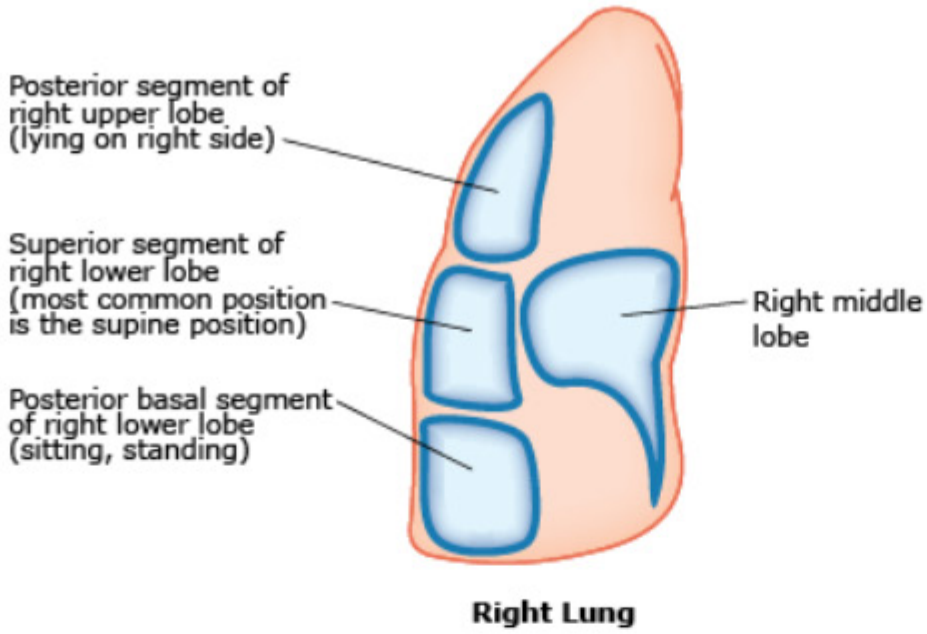

▲ **Figure 12–6.2A** Sites of Aspiration of Foreign Particles

6.2.2 Bronchopneumonia

Lung has patchy areas of consolidation.

Pathogenesis

- Begins as an acute bronchitis and spreads locally into the lungs.
- Usually involves the lower lobes or right middle lobe.
- Microabscesses are present in the areas of consolidation.

6.2.3 Lobar Pneumonia

Complete consolidation of area.

Biophoto Associates/Science Source

▲ **Figure 12–6.2B** Lobar Pneumonia With Consolidationb

MEDIMAGE/Science Source/Custom Medical Stock Photo

▲ **Figure 12–6.2C** Bronchopneumonia With Patchy Consolidation

Please visit us at www.Groupinsiders.com

© DeVry/Becker Educational Development Corp. All rights reserved.

- Complications: Lung abscesses, empyema, sepsis
- Clinical findings of *typical pneumonia*:
  - Chest radiograph is the gold standard for screening
  - Sudden onset of fever with productive cough
  - Chest pain and tachycardia
  - Alveolar exudate indicates consolidation
  - Dullness to percussion and increased vocal tactile fremitus
  - Late inspiratory crackles
  - Bronchophony, egophony, and bronchial breath sounds

Michael Abbey/Science Source

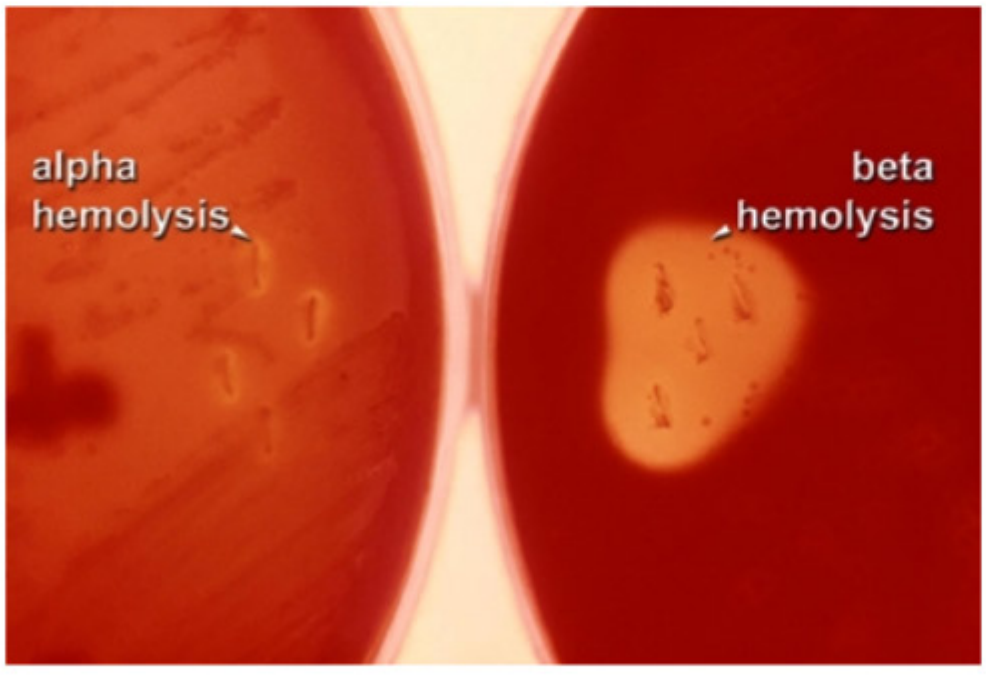

CDC/Richard R. Facklam, PhD

▲ **Figure 12–6.2D** Typical Pneumonia

Connection to Microbiology

See *Microbiology* for discussion of pathogens and subcategories of viruses, bacteria, and fungi.

Please visit us at www.Groupinsiders.com

© DeVry/Becker Educational Development Corp. All rights reserved.

▼Table 12–6.2 Typical Pneumonia Pathogens

Typical Pneumonia Pathogens	High-Yield Comments
Viruses	
Rhinovirus	Most common cause of a cold, which may begin with congestion, causing sinusitis as a secondary effect.
Respiratory syncytial virus	Most common cause of atypical pneumonia seen in children during late fall/winter. Passive immunity is provided by palivizumab. Bronchiolitis with wheezing.
Parainfluenza	Laryngotracheobronchitis (croup). Mucosal edema leading to obstruction in the trachea. Steeple sign on chest x-ray.
Cytomegalovirus	Immunocompromised patient. Eosinophilic intranuclear inclusion.
Influenza	Contains neuraminidase, which dissolves mucus and releases virus. Contains hemagglutinins, which adhere. Associated with superinfections with *Staph. aureus*, Reye syndrome, and Guillain-Barré syndrome.
Hantavirus	Inhalation of urine/feces from deer mice in southwestern U.S. Associated with ARDS, renal failure.
Bacteria	
Mycoplasma pneumoniae	Most common cause of atypical pneumonia. Associated with cold hemagglutinin.
Chlamydia trachomatis	Responsible for afebrile pneumonia in newborns with staccato (choppy) cough, wheezing.
Chlamydophila pneumoniae	May cause atypical pneumonia and therefore present with no signs of consolidation, which include production of interstitial exudate, no cough. May possess atherogenic potential.
Staphylococcus aureus	Commonly associated as a superantigen. Productive cough with *yellow sputum*. Common association with CF, IVDA, hemorrhagic pulmonary edema, and abscess formation. Tension pneumatocyst leads to tension pneumothorax.
Corynebacterium diphtheriae	Toxin inhibits protein synthesis (ADP-ribosylation of ef2) and β-oxidation (cardiac).
Haemophilus influenzae	Gram-negative rod. Common cause of acute epiglottitis ("thumb-print sign") leading to upper-airway obstruction and inspiratory stridor.

Photo Credits (top to bottom): Dr. Gladden Willis/Visuals Unlimited, Inc.; CDC/PHANIE/Science Source; Michael Abbey/Science Source; Science Source

Please visit us at www.Groupinsiders.com

© DeVry/Becker Educational Development Corp. All rights reserved.

▼Table 12–6.2 Typical Pneumonia Pathogens *(continued)*

Typical Pneumonia Pathogens	High-Yield Comments
Pseudomonas aeruginosa	Most common cause of nosocomial (hydrophilic, respirator organism) pneumonia and death due to pneumonia in CF patients. Productive cough with *green sputum* (pyocyanin).
Klebsiella pneumoniae	Productive cough with *mucoid sputum*. Most common cause of typical lobar pneumonia found in the elderly, especially in nursing homes. Commonly associated with alcoholics.
Legionella pneumophila	Gram-negative rod that stains with silver stain. Hydrophilic organism that is found in ship water coolers; *mists* of various locations, including rain forests of zoos; produce section of grocery stores; and outdoor summertime cooling fans. It causes destruction of the juxtaglomerular cells in the renal afferent arteriole, resulting in hyporeninemic hypoaldosteronism.
Fungi	
Cryptococcus neoformans 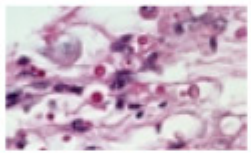	Budding yeast with narrow-based buds, thick capsule. Look for pneumonia in the homeless population due to roosting of pigeons underneath bridges.
Aspergillus fumigatus	Presence as septate mold. 1) Aspergilloma (massive hemoptysis). 2) Allergic bronchopulmonary aspergillosis (types I and III HSR) leading to bronchiectasis. 3) Hemoptysis due to vessel invasion.
Histoplasma capsulatum 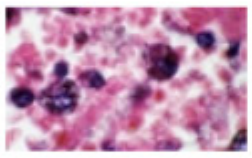	Most common cause of systemic fungus. Found along the path of the Mississippi River. Yeasts are found in macrophages. Acquired through cave explorations (spelunkers) where individuals might be exposed to bat guano. May reactivate primary TB, with military spread and formation of solitary granulomas.
Blastomyces dermatitides 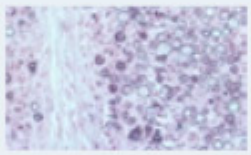	Same demographics as histoplasma. Associated with beaver dams. May manifest in the skin, leading to squamous cell carcinoma. "***B***road-***B***ased ***B***uds."
Coccidiodes immitis 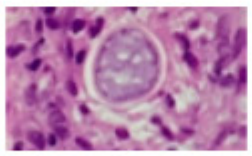	Found to be a common cause of pneumonia in the southwestern U.S. (dry climate). Inhalation of arthrospore in the dust with spherules found with endospores in the lungs. Inflammation of subcutaneous fat, referred to as erythema nodosum, is commonly associated.
Pneumocystis jiroveci 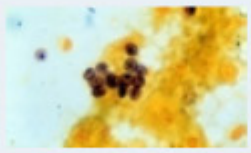	Unicelluar fungi with cysts and spores present on silver stain. Opportunistic infection when $CD4^+$ count is <200/mm^3 in AIDS patients.

Photo Credits (top to bottom): Dr. Gladden Willis/Visuals Unlimited, Inc.; Daniel Snyder/Visuals Unlimited, Inc.; Dr. Cecil H. Fox/Science Source; CNRI/Science Source/Custom Medical Stock Photo; Michael Abbey/Science Source; C. Abrahams, MD/Custom Medical Stock Photo

Please visit us at www.Groupinsiders.com

© DeVry/Becker Educational Development Corp. All rights reserved.

6.3 Tuberculosis

6.3.1 Primary Pulmonary Tuberculosis

- Ghon complex:
  - Primary TB with Ghon focus (periphery) and complex (hilar node involvement as well).
  - Progressive spread with cavitation, tuberculous pneumonia, miliary tuberculosis, Pott disease of spine, TB meningitis.

6.3.2 Secondary Pulmonary Tuberculosis

- Reactivation TB with atypical cavities; greater degree of damage due to previous sensitization.

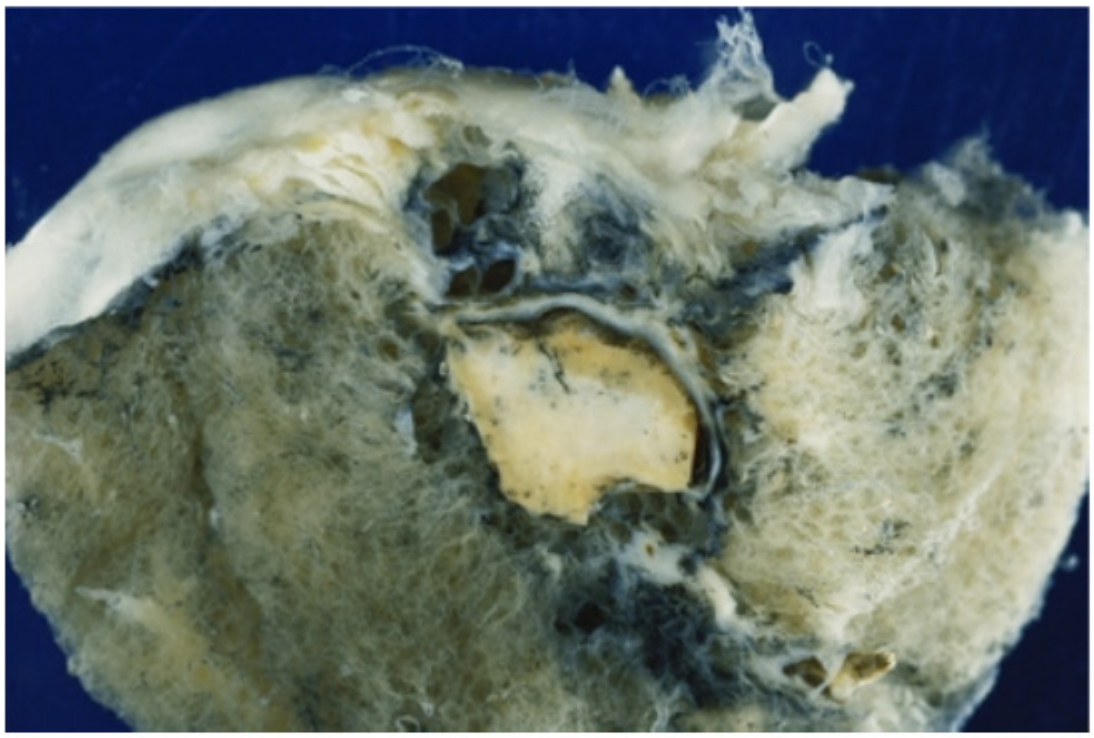

Biophoto Associates/Science Source

▲ **Figure 12–6.3A** Primary Ghon Complex

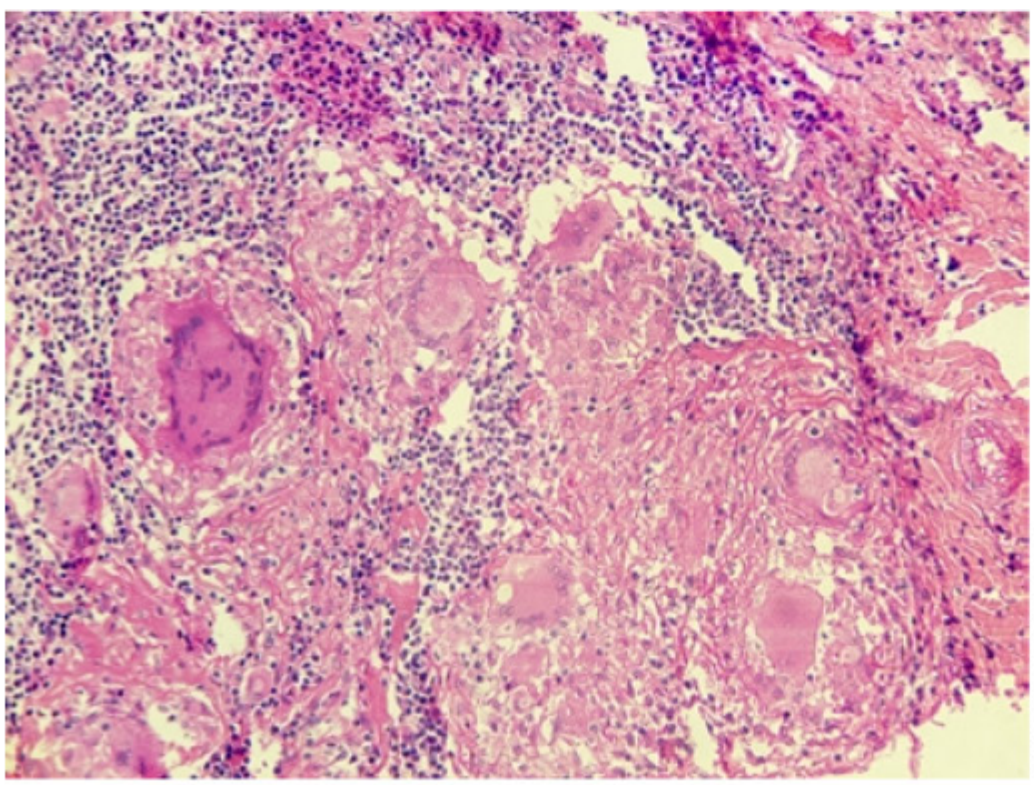

Gary DeLong/Science Source

▲ **Figure 12–6.3B** Caseous ("Cheese-Like") Necrosi

Connection to Microbiology

See *Microbiology*, chapter 3, "Bacteriology" for more discussion of tuberculosis.

Please visit us at www.Groupinsiders.com

© DeVry/Becker Educational Development Corp. All rights reserved.

7 Lung Cancer

- Patient presents with hemoptysis, weight loss.
- Chest x-ray shows lung nodule or multiple lung nodules: *Metastases more common than primary.*
- Primary divided into bronchogenic and others.

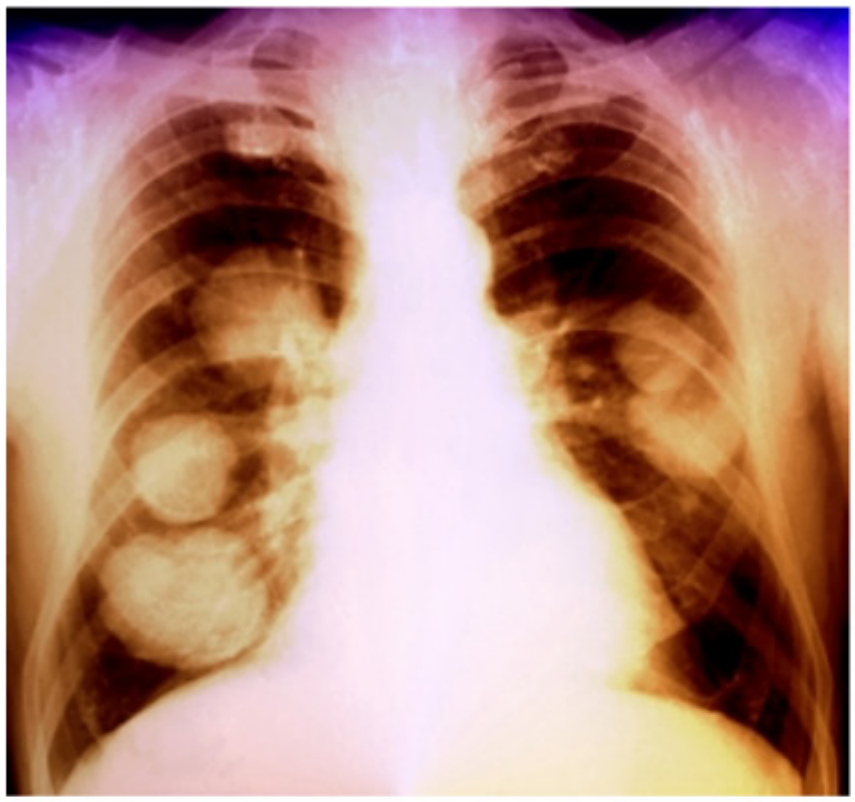

Zephyr/Science Source

▲ **Figure 12–7.0** Chest X-Ray With Multiple Lung Nodules

7.1 Bronchogenic Carcinoma

Classification

- Small cell carcinoma (aka oat cell carcinoma)
- Non-small cell carcinoma:
  - Squamous cell carcinoma
  - Adenocarcinoma
- Leading cause of cancer death in both men and women.
- Increasing in incidence (especially women).

Risk Factors

- Tobacco smoking: Directly proportional to number of cigarettes a day and number of years smoked.
- Industrial exposure to nickel and chromates.
- Granulomatous infections and scarring.
- Asbestos (most common lung cancer seen with asbestos).

Science Source

▲ **Figure 12–7.1A** Bronchogenic Carcinoma

Please visit us at www.Groupinsiders.com

© DeVry/Becker Educational Development Corp. All rights reserved.

7.1.1 Small Cell Carcinoma

- Undifferentiated, highly malignant
- Linked to smoking
- Not cured by surgery
- Oat cell or spindle shaped
- Centrally located nodules
- Paraneoplastic syndrome:
  - SIADH
  - ACTH

7.1.2 Squamous Cell Carcinoma

- Usually male smokers
- Centrally located nodules
- Frequently cavitary
- Spreads locally
- Defined by keratin pearls or intercellular bridges.
- PTH-rP with hypercalcemia

7.1.3 Adenocarcinoma

- Less linked to smoking
- Two types
  1. **Bronchial-derived:** Scar carcinoma
  2. *Bronchioloalveolar*: Multiple densities on x-ray mimicking pneumonia
- Perhipherally located nodule
- Most common type of lung cancer in women and nonsmokers

With undifferentiated *adenocarcinoma* located in the *periphery*.

7.2 Non-bronchogenic

- Bronchial carcinoid:
  - Usually younger than age 40
  - Neuroendocrine differentiation of the Kulchitsky cells of bronchial mucosa and resemble intestinal carcinoids

Clinical Features

- *Carcinoid syndrome*
- Persistent cough and hemoptysis
- Usually polypoid lesion in major bronchi

SIU/Visuals Unlimited, Inc.

▲ **Figure 12–7.1B** Chest X-Ray With Small or Squamous Bronchogenic Carcinoma

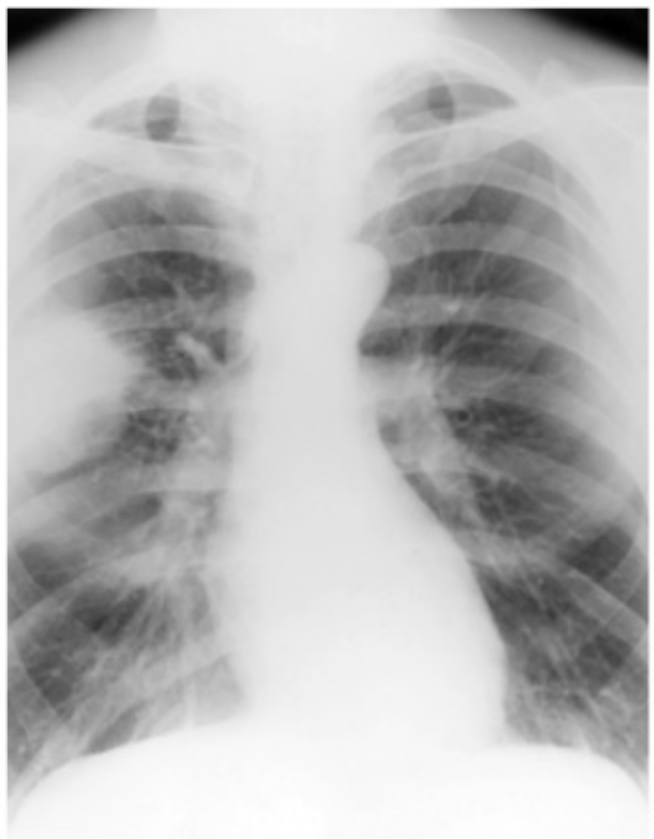
Biophoto Associates/Science Source

▲ **Figure 12–7.1C** Adenocarcinoma Located Peripherally

Please visit us at www.Groupinsiders.com

© DeVry/Becker Educational Development Corp. All rights reserved.

Local Effects of Tumor Spread

- Pneumonia, abscess due to tumor obstruction of airway
- Pleural effusion, often bloody
- Hoarseness: Recurrent laryngeal nerve invasion
- Dysphagia: Esophageal invasion
- Diaphragmatic paralysis: Phrenic nerve invasion
- Rib destruction: Chest-wall invasion
- SVC syndrome: SVC compression by tumor results in facial swelling, cyanosis, and dilation on veins of head, neck, and upper extremities.
- Pancoast tumor: Involvement of apex of lung with Horner syndrome: ptosis, miosis, and anhidrosis due to involvement of cervical sympathetic plexus.
- Pericarditis and cardiac tamponade: Pericardial involvement

7.3 Pleural Space Pathology

- **Pneumothorax:** Air in space
- **Pleural Effusion:** Edema in space
- Related to infection, cancer, heart failure
- Empyema: Pus in pleural space
- Hydrothorax: Meigs syndrome: Ascities, and ovarian fibroma
- **Hemothorax:** Blood in pleural cavity
- **Chylothorax:** Accumulation of milky fluid of lymphatic origin in pleural space

Please visit us at www.Groupinsiders.com

© DeVry/Becker Educational Development Corp. All rights reserved.

7.4 Pneumothorax

- **Spontaneous Pneumothorax**
  - Hole in pleura (like sticking balloon with a needle; lung collapses).
  - Trachea shifted same side (only with total lung collapse).
  - Dyspnea and pleuritic chest pain. Absent breath sounds and tactile fremitus.
  - Tympanitic to percussion.

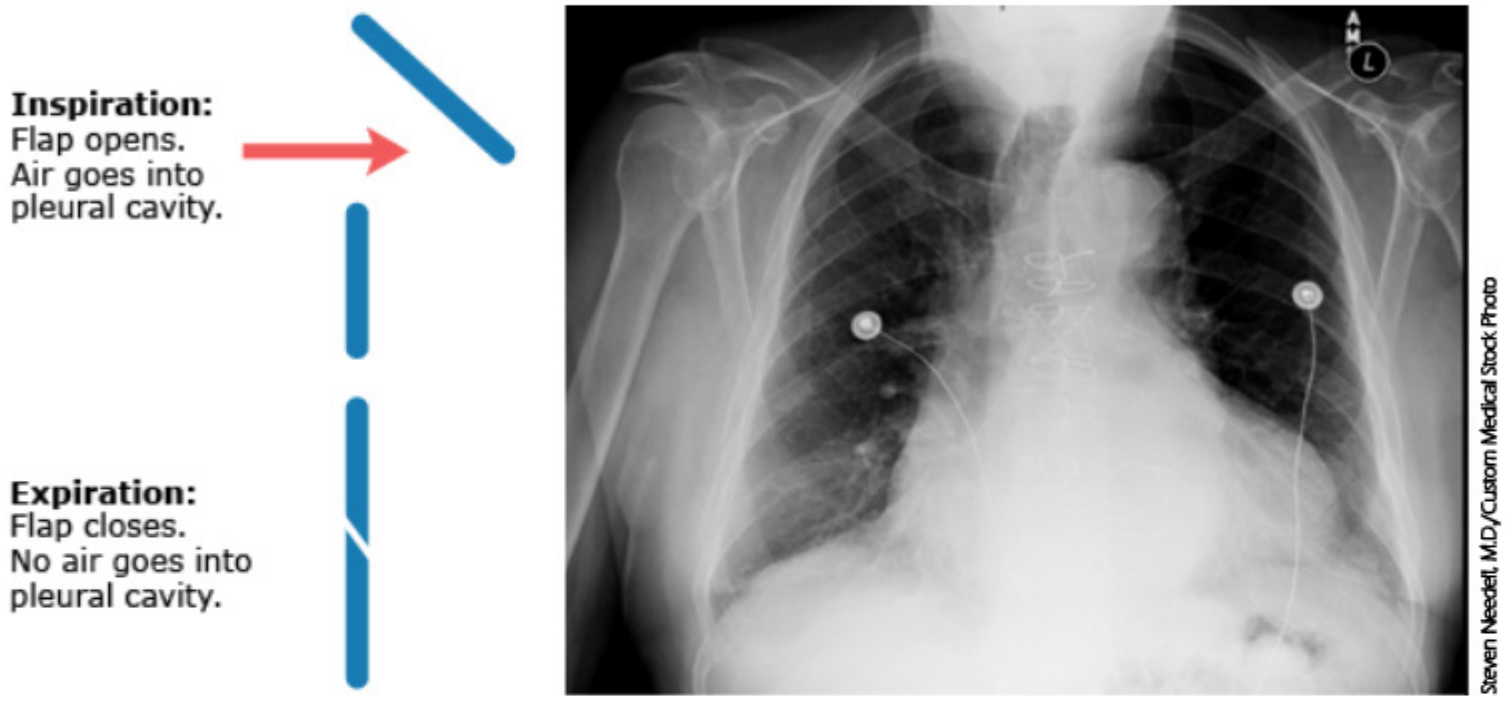

▲ **Figure 12–7.4** Tension Pneumothorax and Tracheal Deviation

- **Tension Pneumothorax**
  - Inspiration: Flap opens. Air goes into pleural cavity.
  - Expiration: Flap closes. No air goes into pleural cavity.
    - —Knife wound (flap over hole).
    - —Like filling tire with air: Pressure is greater in the pleural cavity than in the atmosphere.
    - —Flap prevents air from leaving the pleural space.
    - —Trachea shifted to opposite side. Diaphragm is pushed down.
    - —Dyspnea, pleuritic chest pain.

7.5 Mesothelioma

- Malignancy of serosa lining the pleura:
  - May arise from either the visceral or parietal pleura.
  - **Risk Factor:** Smoking and asbestos (bronchogenic carcinoma is a more common cancer manifestation of asbestos).
  - **Pathology:** Diffuse lesion that spreads widely in pleural space.

▲ **Figure 12–7.5** Mesothelioma

Please visit us at www.Groupinsiders.com

© DeVry/Becker Educational Development Corp. All rights reserved.

Unit 5

Renal Pathology

Please visit us at www.Groupinsiders.com

Please visit us at www.Groupinsiders.com

1 Overview of the Renal System

1.1 Renal Functions

- **Excrete Waste Products:** Urea, creatinine, uric acid.
- **Maintain Acid-Base Balance:** Synthesis and excretion of bicarbonate/hydrogen ions.
- **Reabsorb Essential Substances:** Sodium, glucose, amino acids.
- **Regulate Water and Sodium Metabolism**
- **Maintain Vascular Tone:**
  - Angiotensin II (ATII) vasoconstricts glomerular arterioles.
  - Angiotensin II (ATII) stimulates the synthesis and release of aldosterone.
- **Produce Erythropoietin**
- **Maintain Calcium Homeostasis:** 1-α-Hydroxylase synthesized in the proximal renal tubular cells, converts 25-hydroycholecalciferol to 1,25-dihydroxycholecalciferol.

1.2 Gross Renal Anatomy

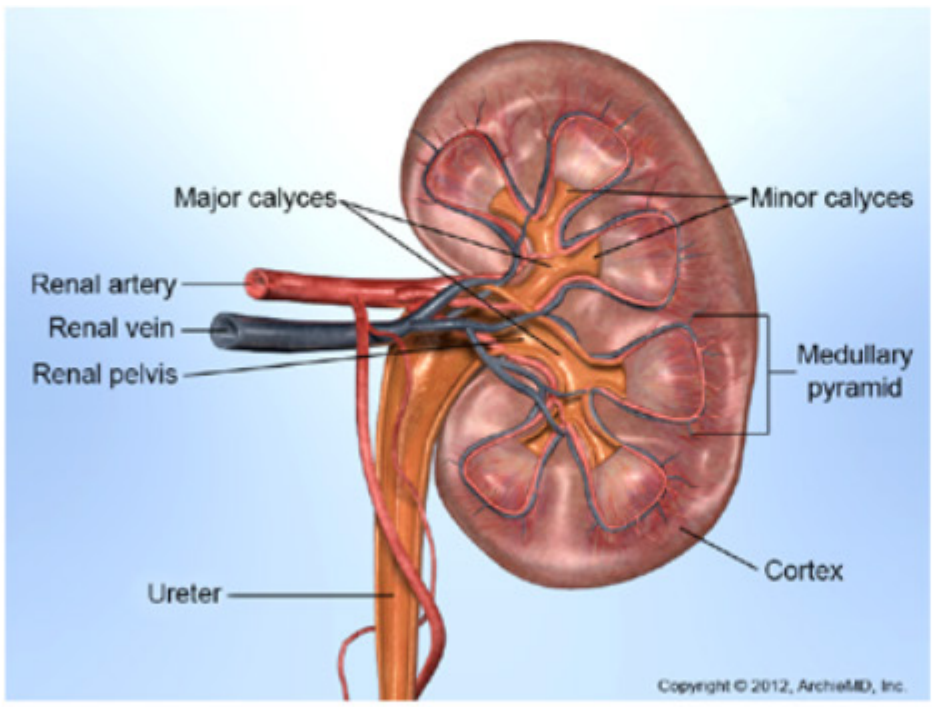

▲ **Figure 13–1.2** Renal Anatomy

USMLE® Key Concepts

For Step 1, you must be able to:

- Manipulate renal labs in reference to azotemia under different pathological conditions.
- Differentiate glomerular, tubular, and interstitial diseases of the renal system.
- Interpret laboratory findings of renal vascular diseases.
- Identify renal stone formations.
- Describe clinically significant renal malignancies.

Please visit us at www.Groupinsiders.com

© DeVry/Becker Educational Development Corp. All rights reserved.

1.3 Renal Arteries

- Arise from the aorta.
- At each renal hilum, the main renal artery branches.
- These branches further subdivide into *interlobular*, *arcuate*, and *intralobular* arteries.
- These ultimately give rise to the *afferent arterioles*.

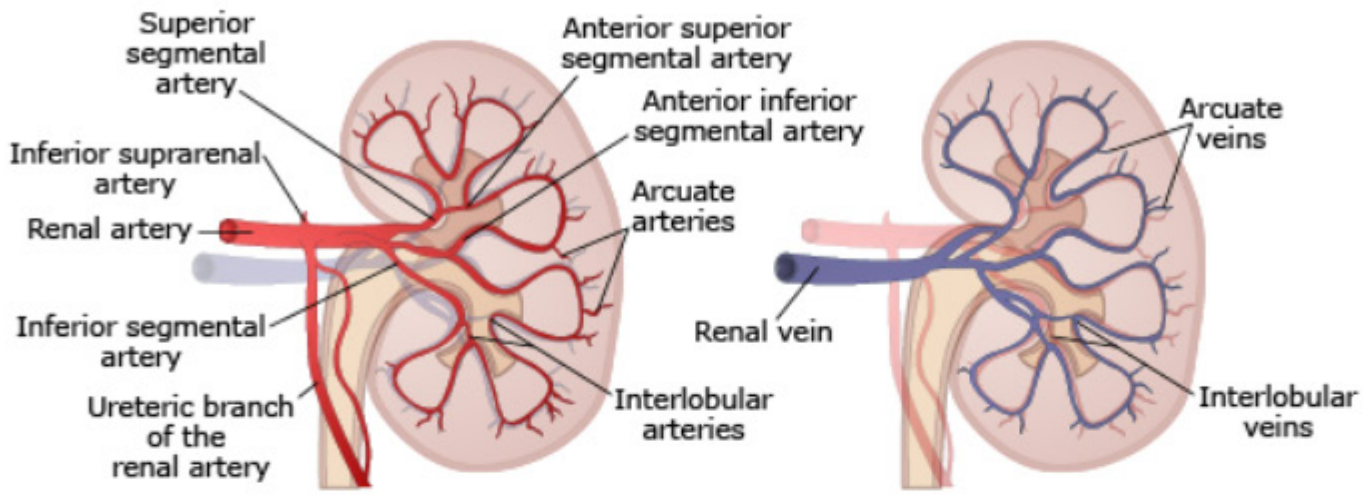

▲ **Figure 13–1.3** Renal Arteries and Veins

1.4 Renal Blood Flow

- Over 20% of cardiac output.
- Organ with highest blood flow per weight and lowest oxygen extraction.
- Renal function is profoundly dependent on blood supply.

Please visit us at www.Groupinsiders.com

© DeVry/Becker Educational Development Corp. All rights reserved.

2 Renal Functional Anatomy

2.1 Overview of Functional Anatomy

There are two primary regions of the kidney: the *cortex* and the *medulla*. The key functional unit of the kidney is the *nephron*.

2.1.1 Cortex

The cortex makes up 75% of kidney mass.

2.1.2 Medulla

The medulla makes up about 20% of kidney mass. It is composed of:

- Renal pyramids
- Renal columns
- Calyces
- Renal pelvis

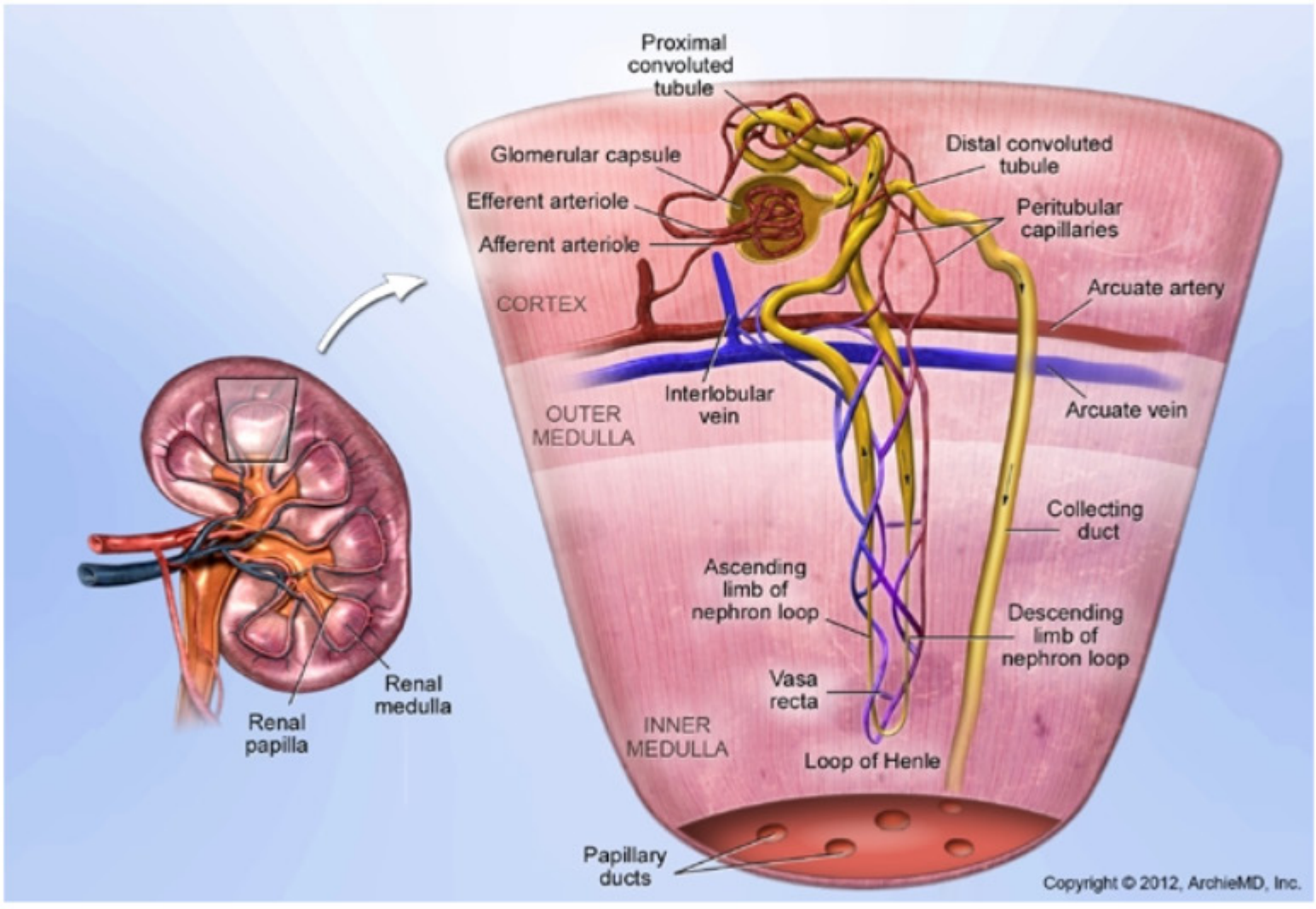

▲ **Figure 13–2.1** Renal Functional Anatomy

Please visit us at www.Groupinsiders.com

© DeVry/Becker Educational Development Corp. All rights reserved.

2.1.3 Nephron

There are 1.2 million nephrons in the kidney. The three types of nephron are:

1. **Superficial Cortical Nephrons (40%):** Short loop of Henle, only reach the outer medulla.
2. **Mid-cortical Nephrons:** Have short or long loops of Henle.
3. **Juxtamedullary Nephrons:** Large glomeruli and long loops of Henle, which extend into the inner medulla and papillae; important in urine concentration.

Nephrons are composed of:

- Glomerulus
- Proximal convoluted tubule
- Loop of Henle
- Distal convoluted tubule
- Cortical collecting duct
- Medullary collecting duct

Each segment of the nephron has a unique cellular makeup, specialized for its particular role in the control of fluid and electrolyte balance.

2.2 Blood Flow

- **Afferent Arteriole:** Brings whole blood to the glomerulus of each nephron.
- **Efferent Arteriole:** Takes "concentrated" (i.e., plasma-reduced) blood from the glomerulus to the peritubular capillaries and vasa recta.
- **Vasa Recta:** Also known as the straight arteries of the kidney, these capillaries of the medulla allow blood, which is plasma-reduced (with increased concentrations of proteins, blood cells, and glucose) and has high osmotic "pull," to surround convoluted tubules and loop of Henle.

2.3 Basic Renal Physiology

The kidney performs to two basic processes:

- **Filtration:** Selective filtration based on *size* and *charge* occurs at glomeruli.
- **Modification of Filtrate:** Reabsorption and secretion of substances throughout the tubules.

Please visit us at www.Groupinsiders.com

© DeVry/Becker Educational Development Corp. All rights reserved.

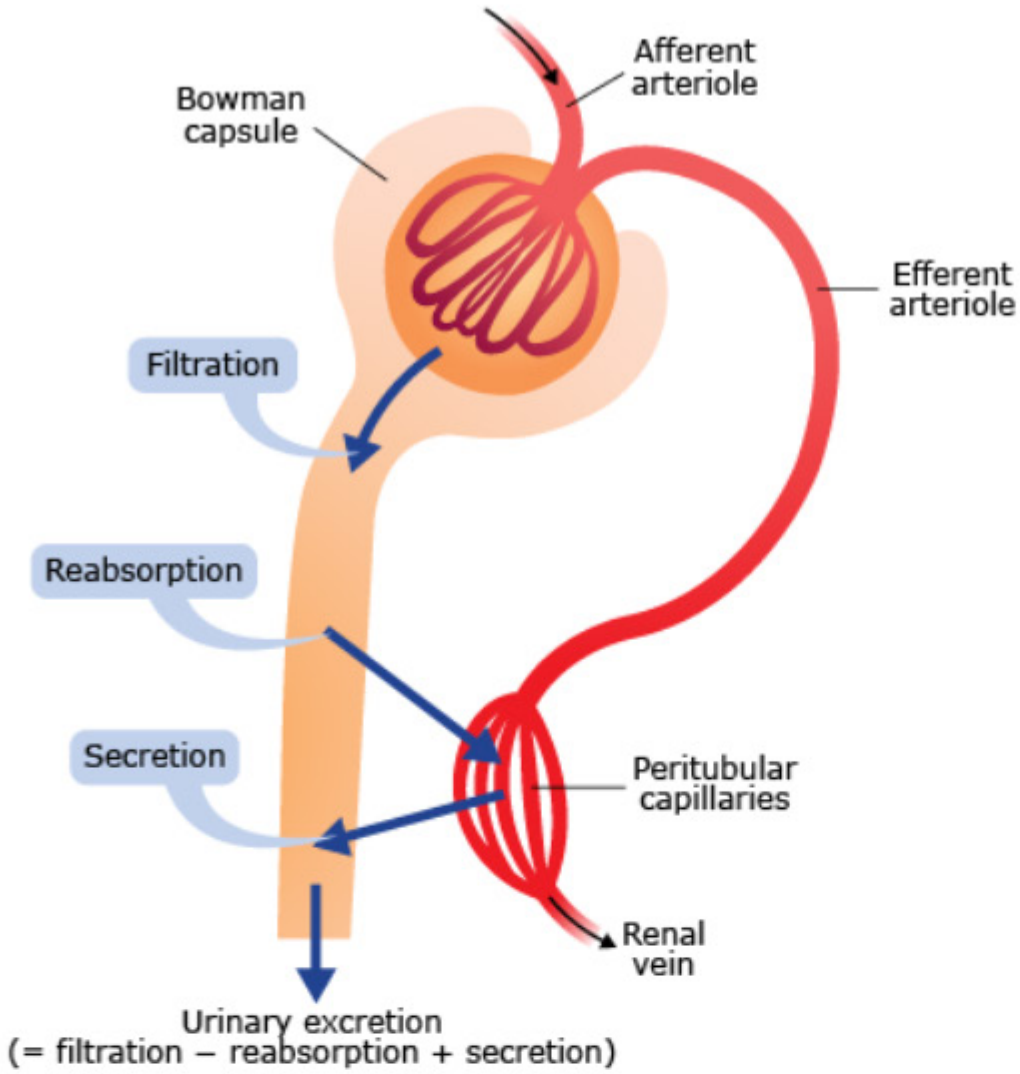

▲ **Figure 13–2.3A** Basic Renal Processes

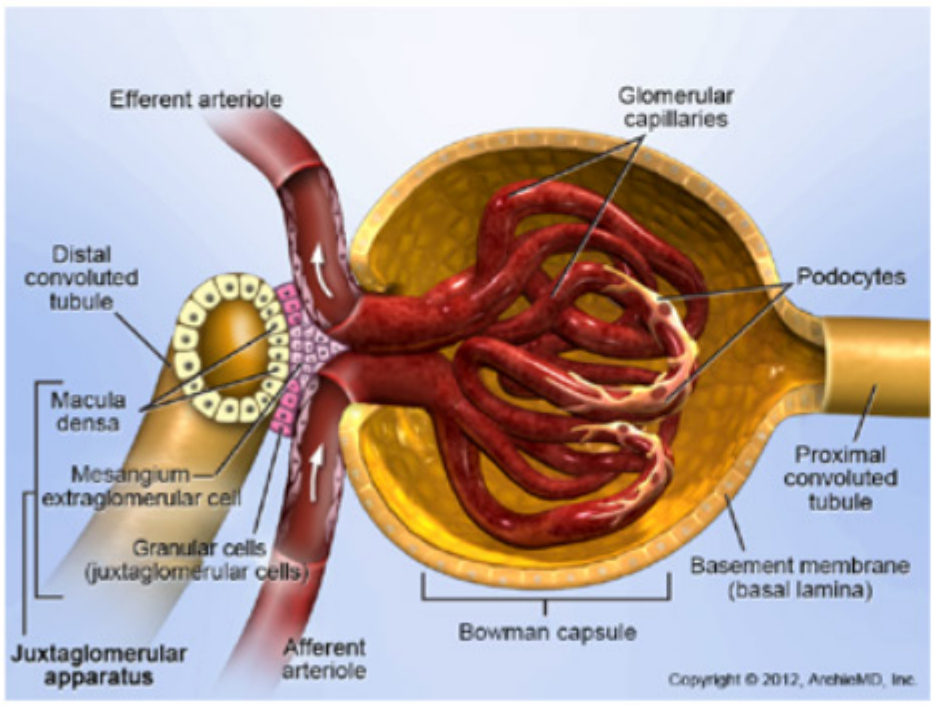

▲ **Figure 13–2.3B** Bowman Capsule and Glomerular Anatomy

Please visit us at www.Groupinsiders.com

© DeVry/Becker Educational Development Corp. All rights reserved.

2.4 Filtration

Filtration occurs in the glomerulus. Afferent arterioles enter the glomerulus and expand into a tuft of capillaries. These tufts increase the *surface area* of the capillaries dramatically, which greatly enhances the amount of filtration possible. The capillary tufts are *fenestrated* (have holes), which allows fluid to be filtered into the glomerulus, while preventing large particles such as large proteins and blood cells from passing through.

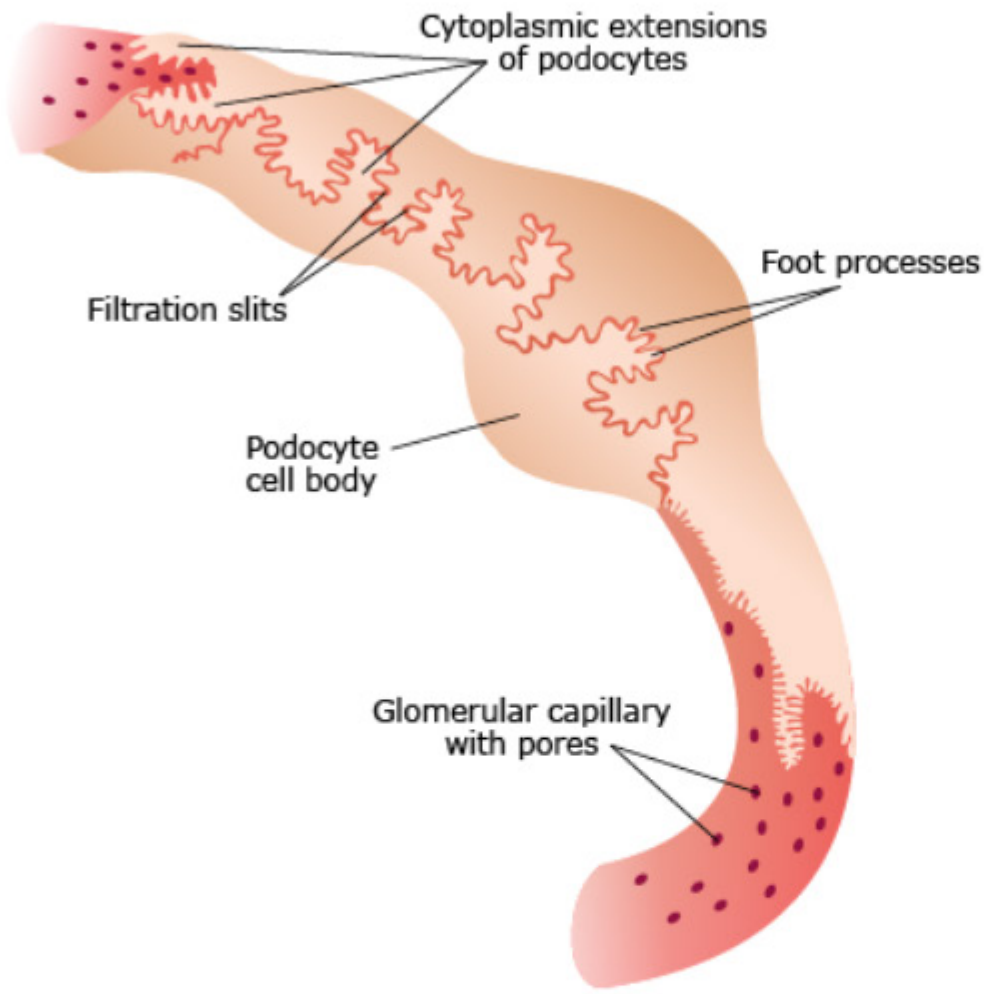

▲ **Figure 13–2.4A** Fenestrated Capillary Tufts

Please visit us at www.Groupinsiders.com

© DeVry/Becker Educational Development Corp. All rights reserved.

There are three layers of renal *filtration barriers*:

1. **Blood Side:** Fenestrated endothelial cells of glomerular capillaries (pores).
2. **Glomerular Basement Membrane (lamina):** Negatively charged, which repels negatively charged proteins.
3. **Urine Side:** Podocytes, also known as visceral epithelial cells, which lie over the glomerular basement membrane. Between podocytes are tiny openings, *filtration slits*, which are covered by *slit diaphragms*.

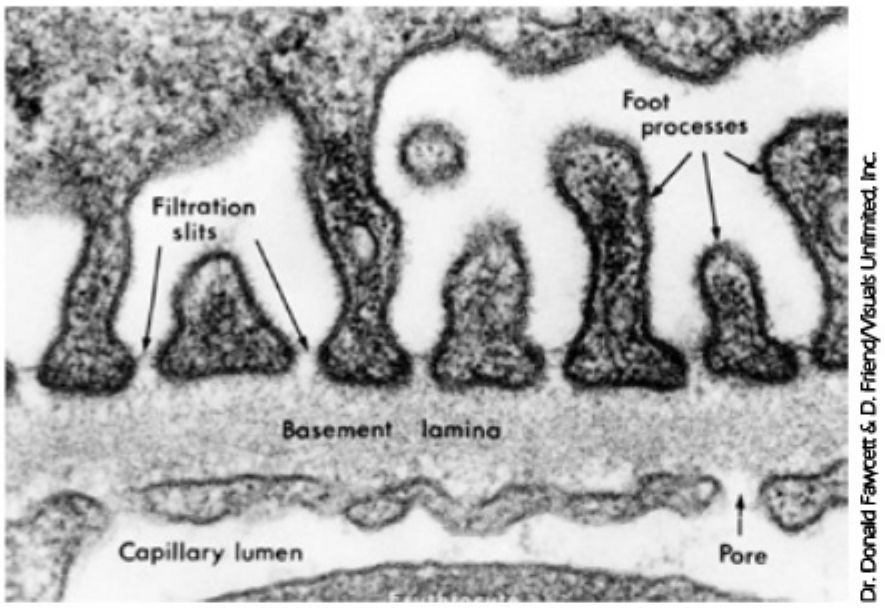

▲ **Figure 13–2.4B** Renal Filtration Barriers

2.5 Renal Function Tests

- Serum blood urea nitrogen (BUN)
- Serum creatinine
- Serum BUN: Creatinine (Cr) ratio

2.5.1 Serum Blood Urea Nitrogen (BUN)

- Normal serum *BUN 7-18 mg/dL*:
  - BUN is end-product of amino acid and *pyrimidine* metabolism.
  - Filtered and partly reabsorbed in the proximal tubule.
- Serum levels are dependent on:
  - Glomerular filtration rate (GFR).
  - Protein content in the diet.
  - Proximal tubule reabsorption.
  - Functional status of the urea cycle.
- Congestive heart failure is the most common cause of increased BUN.

2.5.2 Serum Creatinine

- Normal serum creatinine is 0.6–1.2 mg/dL:
  - Metabolic end product of creatine in muscle.
  - Filtered in the kidneys and *not* reabsorbed; slightly secreted.
  - Overestimate of renal clearance.

Please visit us at www.Groupinsiders.com

© DeVry/Becker Educational Development Corp. All rights reserved.

- Serum concentration varies with age and muscle mass:
  - Clearance decreases with advancing age, so serum creatinine increases with advancing age.
  - Serum creatinine increases in muscle wasting.
- Creatine supplements found in athletes: ↑ serum creatinine.

2.5.3 Serum BUN: Creatinine (Cr) Ratio

- Depends on changes that occur:
  - Before the kidneys (prerenal).
  - Within the kidney parenchyma (renal).
  - After the kidneys (postrenal).
- Normal ratio is ≤15.
- *Azotemia* is disturbance in *serum* BUN and creatinine.
- *Uremia* is the systemic *clinical* manifestations of azotemia.

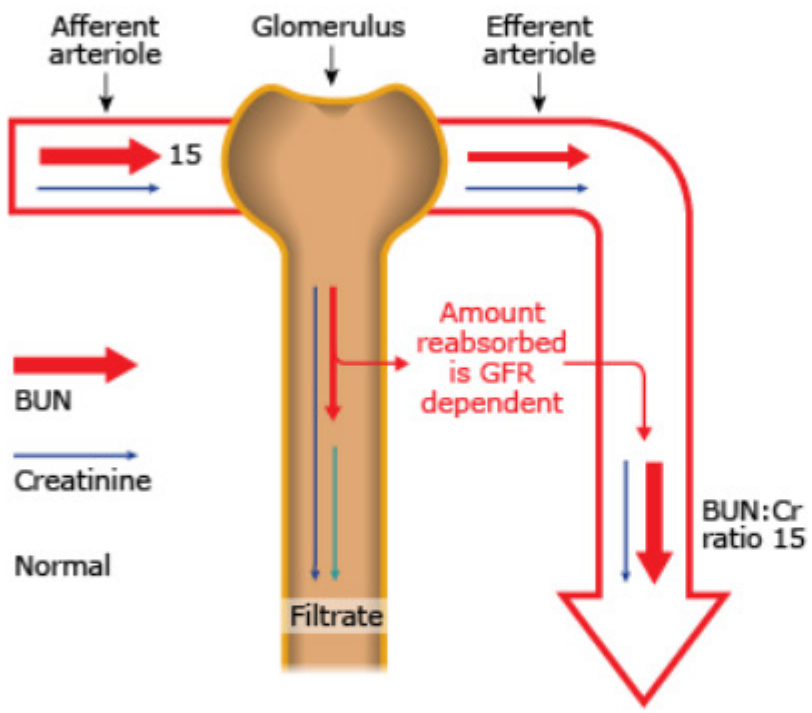

▲ **Figure 13–2.5A** Renal Handling of BUN/Cr

Prerenal Azotemia ↓ cardiac output, ↓ GFR; ratio >15

- Caused by a decrease in cardiac output such as in hypovolemia (hemorrhage), congestive heart failure.
- Hypoperfusion of the kidneys decreases GFR and causes creatinine and urea to "back up" in blood.
- After filtration, some urea is reabsorbed, but no creatinine.
- Increased serum BUN: Cr ratio >15 secondary to increased urea build-up in serum.
- Example: Serum BUN 80 mg/dL; serum creatinine 4 mg/dL; BUN/Cr ratio is 20.

Important Concept

- *Creatinine* is filtered; it is not reabsorbed. It is, however, slightly secreted by the peritubular capillaries.
- *Urea* is filtered and partly reabsorbed in the proximal tubule.

Please visit us at www.Groupinsiders.com

© DeVry/Becker Educational Development Corp. All rights reserved.

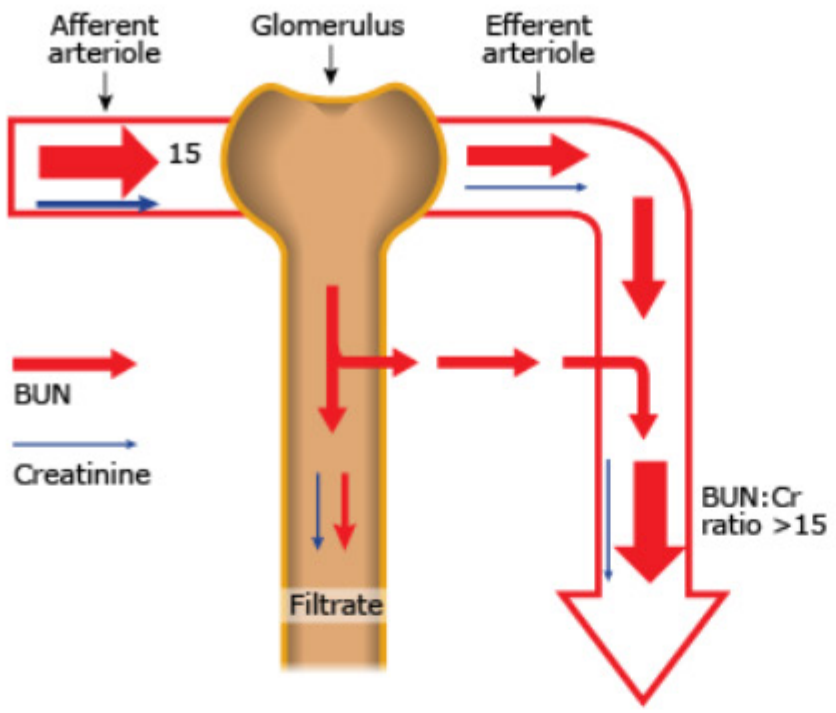

▲ **Figure 13–2.5B** Prerenal Azotemia

(Intrinsic) Renal Azotemia

- Caused by parenchymal damage to the kidneys as in acute tubular necrosis and chronic renal failure.
- Decreased GFR causes creatinine and urea to back up in blood.
- Proximal renal tubules are damaged preventing BUN reabsorption, resulting in both urea and creatinine being lost in the urine.
- Most commonly, decreased or perhaps normal BUN: Cr ratio of <15.
- Example: Serum BUN 80 mg/dL, serum creatinine 8 mg/dL; BUN/Cr ratio is 10.

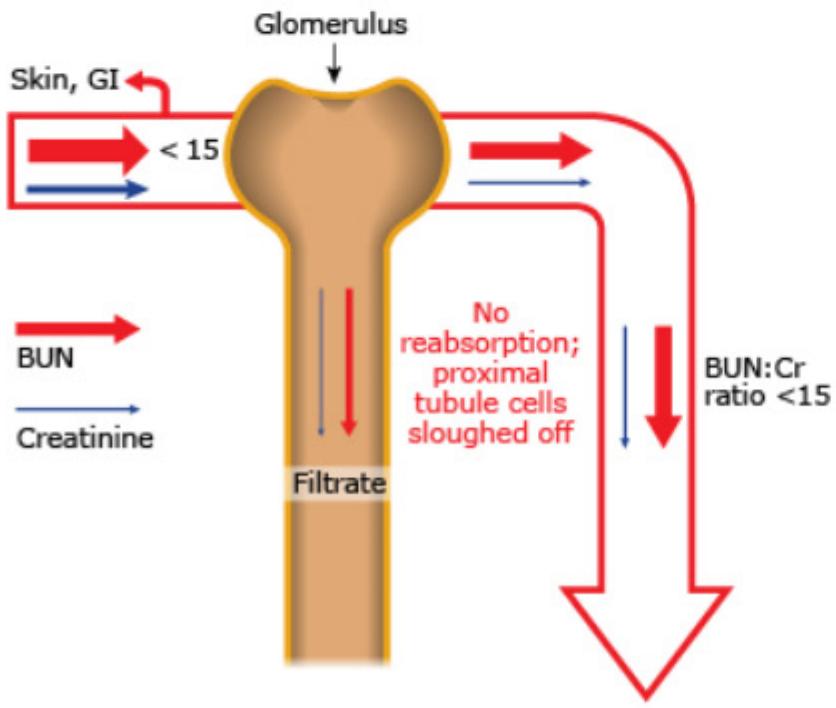

▲ **Figure 13-2.5C** Renal Azotemia

Please visit us at www.Groupinsiders.com

© DeVry/Becker Educational Development Corp. All rights reserved.

2.5.4 Postrenal Azotemia

- Caused by urinary tract obstruction, such as blockage of ureters by stones or prostate hyperplasia.
- Obstruction anywhere along the path of urine flow decreases GFR due to increased hydrostatic pressure in the Bowman's space. As a result, urea and creatinine will back up in the tubule, but only urea will be reabsorbed into serum, while creatinine remains contained within the tubule.
- Increased serum BUN: Cr ratio >15.
- Persistent obstruction leads to parenchymal damage and renal azotemia (ratio ≤15).

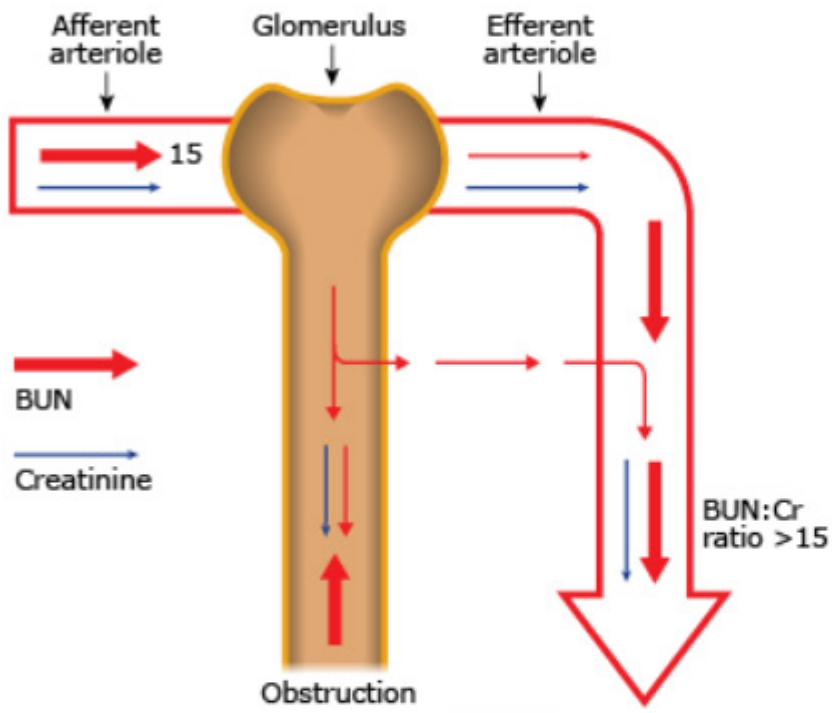

▲ **Figure 13–2.5D** Postrenal Azotemia

▼ **Table 13–2.5** Acute Renal Failure

Variable	Prerenal	Renal	Postrenal
Urine osmolality	>500	<350	<350
Urine Na	<10	>20	>40
Fe_{Na}	<1%	>2%	>4%
Serum BUN/Cr	>20	<15	>15

Please visit us at www.Groupinsiders.com

© DeVry/Becker Educational Development Corp. All rights reserved.

3 Renal Pathology

Renal pathology can be confusing, so keep the following in mind. First, remember that renal pathology can be classified into two broad groups: *Congenital* and *acquired*. Second, remember that the functional anatomy most commonly affected includes the following:

- Interstitium
- Glomeruli
- Tubules
- Blood vessels

3.1 Renal Embryology

- **Pronephros:** Week 4, then degenerates.
- **Mesonephros:** Functions as interim kidney for first trimester; later contributes to male genital system.
- **Metanephros:** Permanent; beginnings first appear during fifth week of gestation; nephrogenesis continues through weeks 32–36 of gestation.
  - **Ureteric Bud:** Derived from caudal end of mesonephros; gives rise to ureter, pelvises, calyces, and collecting ducts; fully canalized by 10th week.
  - **Metanephric Mesenchyme:** Ureteric bud interacts with this tissue; interaction induces differentiation and formation of glomerulus and renal tubules to distal convoluted tubule.
- **Clinical Features**
  - Aberrant interaction between the ureteric bud and metanephric tissue may result in several congenital malformations of the kidney.
  - Uteropelvic junction (UPJ) with kidney:
    - Last to canalize.
    - Most common site of obstruction (hydronephrosis) in fetus.

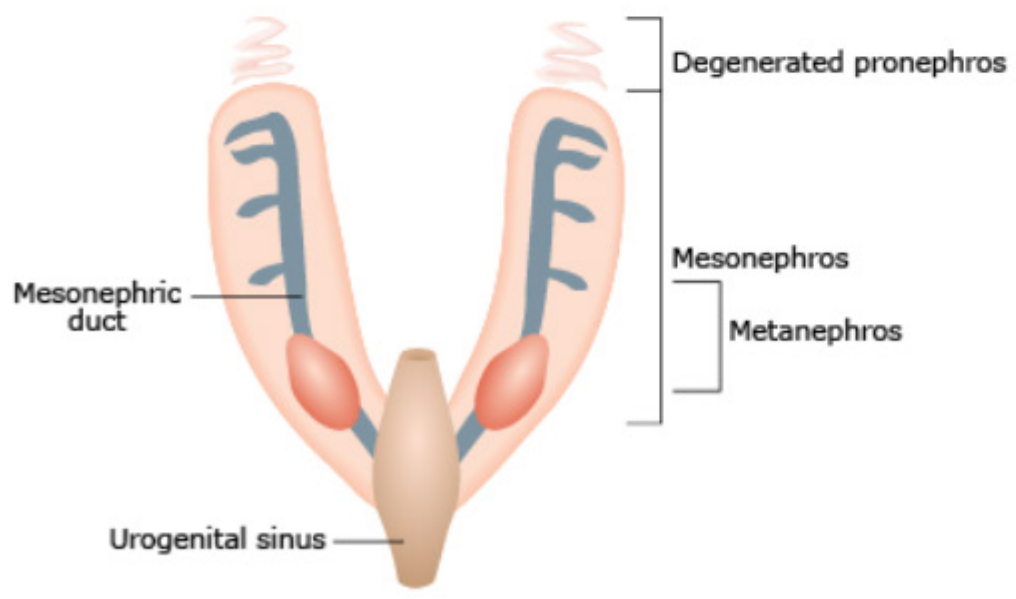

▲ **Figure 13–3.1** Developmental Landmarks of the Renal System

Please visit us at www.Groupinsiders.com

© DeVry/Becker Educational Development Corp. All rights reserved.

3.2 Congenital Abnormalities

3.2.1 Renal Agenesis

- **Bilateral:** Failure of ureteric bud development.
  - Incompatible with life.
  - Potter sequence:
    - *Oligohydramnios* results in Potter sequence; detected by ultrasound.
    - Potter facies (flattened nose, low-set ears, recessed chin).
    - Hypoplastic lung.
    - Defects in extremities.
- **Unilateral**
  - Compatible with life (remaining kidney undergoes compensatory hypertrophy).
  - Patients have renal insufficiency.
  - Progressive glomerular sclerosis.

3.2.2 Hypoplasia

- Failure of kidney to develop normal weight.
- Decreased number of renal calyces and lobes.

3.2.3 Ectopic Kidney

- Frequently in pelvis.
- Tortuosity of ureters predisposes to pyelonephritis.

3.2.4 Horseshoe Kidney

- Common (1:750 autopsies).
- Fusion of the inferior poles of both kidneys.
- During ascent from the pelvis, kidneys may get trapped under the inferior mesenteric artery and remain in the lower abdomen.
- Normal renal function.
- Clinical Features:
  - Associated with Turner syndrome.
  - Increased risk of nephrolithiasis.

3.3 Autosomal Dominant Polycystic Kidney Disease (ADPKD)

- Autosomal dominant mutation in PKD-1 gene (chromosome 16) or PKD-2 gene (chromosome 4). Incidence: 1:1,000, with mutation to PKD-1 gene representing 85% of cases.
- Characterized by multiple *bilateral* renal cysts that damage renal parenchyma and cause renal failure.
- Clinical Features:
  - Hypertension (due to increased renin)
  - Hematuria
  - Flank pain
  - Urinary tract infection
  - Renal stones
  - Secondary polycythemia

Important Concept

Turner syndrome: XO

- Coarctation of the aorta
- Cystic hygroma
- Horseshoe kidney
- Primary amenorrhea

Please visit us at www.Groupinsiders.com

© DeVry/Becker Educational Development Corp. All rights reserved.

- Associated with:
  - Hepatic cysts: polycystic liver disease
  - Saccular (berry) aneurysm
  - Mitral valve prolapse
- Slow progression to chronic renal failure (age 40–60 years).

3.4 Juvenile (Autosomal Recessive) Polycystic Kidney Disease (ARPKD)

- Early development of progressive renal failure.
- Numerous cysts give the kidneys a sponge-like appearance.
- Dilated elongated channels are present at right angles to the cortical surface.
- Frequently have cysts in the liver and portal bile ducts = congenital hepatic fibrosis.
- Variable age on onset:
  - Neonates present with renal and pulmonary symptoms, die early.
  - Infants present with renal symptoms.
  - Juveniles present with liver symptoms (e.g., variceal bleeding).

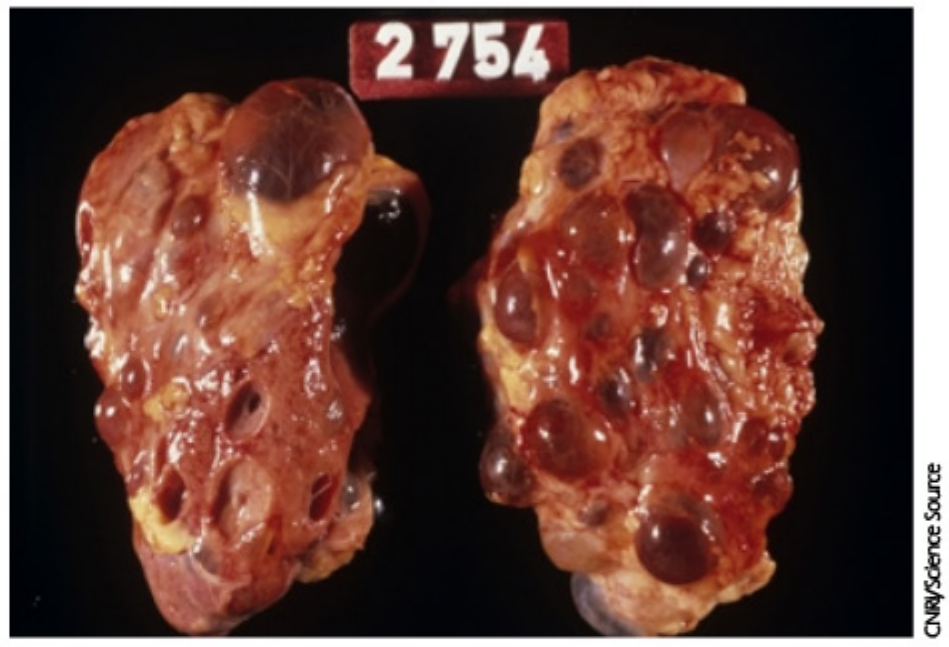

▲ **Figure 13–3.4A** Polycystic Kidney Disease

3.5 Renal Cysts

3.5.1 Simple Renal Cysts

- Translucent
- Filled with clear fluid
- Lined by gray, smooth membrane
- Membranes composed of a single layer of cuboidal epithelium
- May have microscopic hematuria
- Usually not clinically significant

3.5.2 Acquired Renal Cysts

- Associated with *dialysis*
- Increased risk of renal cell carcinoma

3.5.3 Medullary Cystic Disease

- Fibrosis and progressive renal insufficiency with urinary concentrating defects.
- Ultrasound shows small kidney with 70% developing nephrolithiasis.
- Poor prognosis.

Please visit us at www.Groupinsiders.com

© DeVry/Becker Educational Development Corp. All rights reserved.

4 Glomerular Disease

4.1 Overview of Glomerular Disease

- Glomerular disease tends to be immunologically mediated.
- Interstitial and tubular disease tends to be mediated by either toxic or infectious processes.
- Immune-mediated damage to glomerulus is either caused by antigen-antibody complexes or antibodies only (not associated with circulating antigens):
  - Antigen-antibody complexes deposited around basement membrane.
  - Antibodies not associated with circulating antigens react directly on cells of the glomerulus.
- Antibody-mediated glomerular injury:
  - Deposition of circulating immune complexes gives a *granular immunofluorescence pattern*.
  - Anti-GBM antibody GN is characterized by a *linear immunofluorescence pattern*.
  - Antibodies against glomerular antigens deposit in a granular pattern.

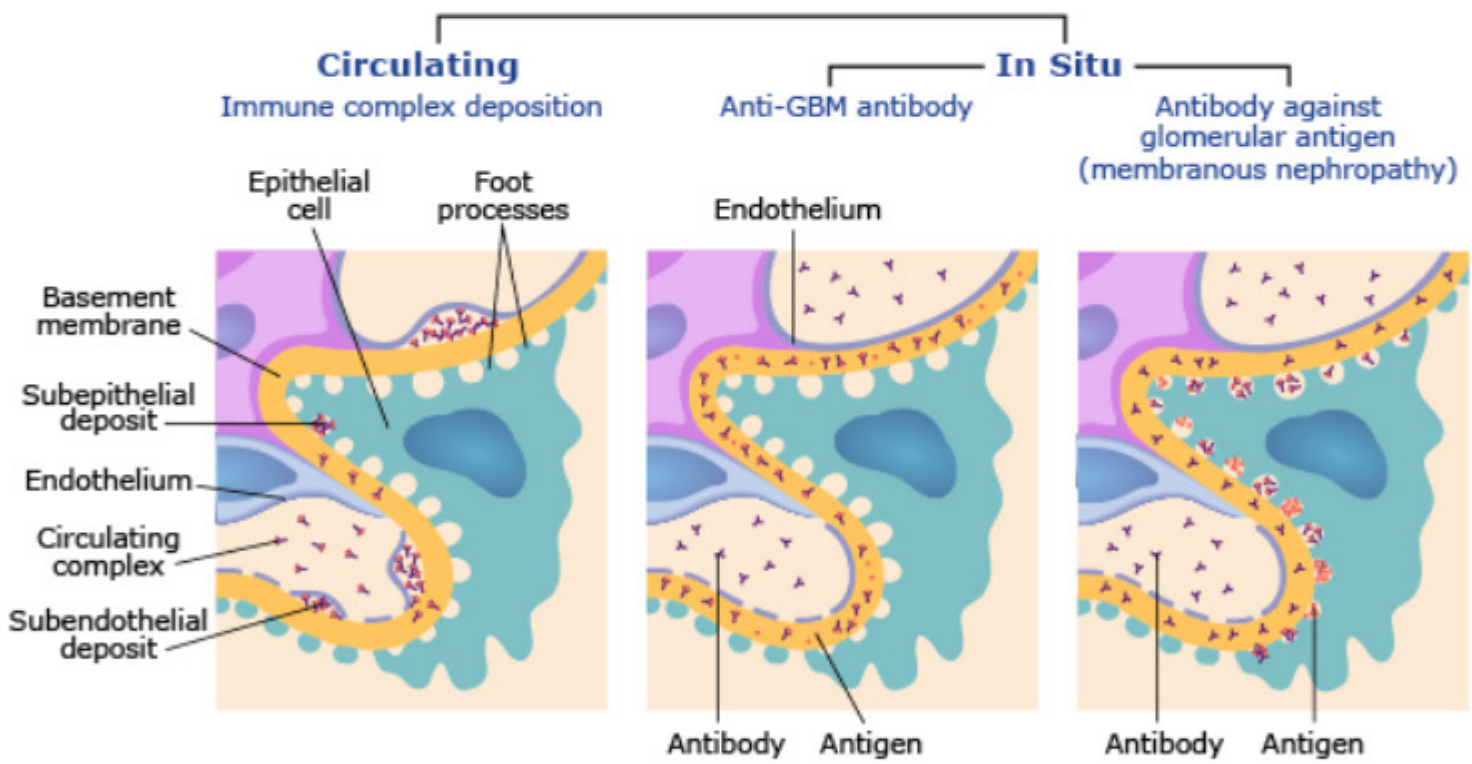

▲ **Figure 13–4.1A** Immune-Glomerulopathy Patterns

4.1.1 Approach to Glomerulopathies

- Identify the presenting clinical syndrome: e.g., nephritic or nephrotic.
- Define the pathologic features: Proliferative, crescentic, membranous.
- Attempt to establish the specific disease that provoked glomerular injury: SLE, Henoch-Schönlein purpura, etc.

Please visit us at www.Groupinsiders.com

© DeVry/Becker Educational Development Corp. All rights reserved.

4.1.2 Glomerular Diseases

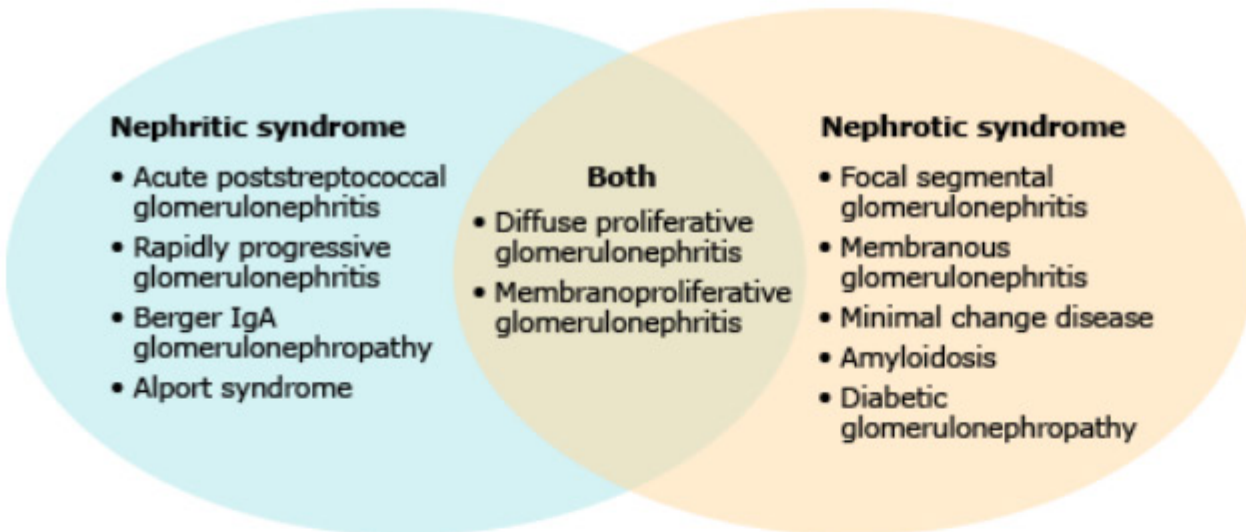

▲ **Figure 13–4.1B** Glomerular Diseases

4.1.3 Renal Biopsy

- Histological alterations in GN:
  - Hypercellularity
  - Basement membrane thickening
  - Hyalinization and sclerosis

Hypercellularity Increase in the number of cells in the glomerular tufts.

- May be due to proliferation of mesangial or endothelial cells.
- Leukocytic infiltration.
- Crescent formation.

BM Thickening

- Light Microscopy: Thickening of the capillary walls.
- Electron Microscopy:
  - Deposition of amorphous, electron-dense material on either side of the glomerular basement membrane (GBM).
  - Thickening of the basement membrane proper as in diabetic glomerulosclerosis.
- Immunofluorescence: Granular or linear patterns of GBM.

Hyalinization and Sclerosis

- Hyalinization consists of an accumulation of an amorphous substance made up of plasma proteins.
- It is usually a consequence of endothelial or capillary wall injury.

Please visit us at www.Groupinsiders.com

© DeVry/Becker Educational Development Corp. All rights reserved.

4.2 Histologic Changes of Glomerular Disorders

- Diffuse: All glomeruli are involved.
- Focal: Few glomeruli are involved.
- Global: The entire glomerulus is involved.
- Segmental: Only part of the glomeruli are involved.
- Proliferative: Hypercellular glomeruli.
- Membranous: Thickening of glomerular basement membrane.
- Glomerular disease involving the glomeruli with or without systemic disease.
- Examples:
  - Focal segmental glomerulosclerosis
  - Diffuse proliferative glomerulonephritis
  - Mesangial proliferative
  - Membranous glomerulonephritis
  - Minimal change disease
  - SLE, diabetic nephropathy

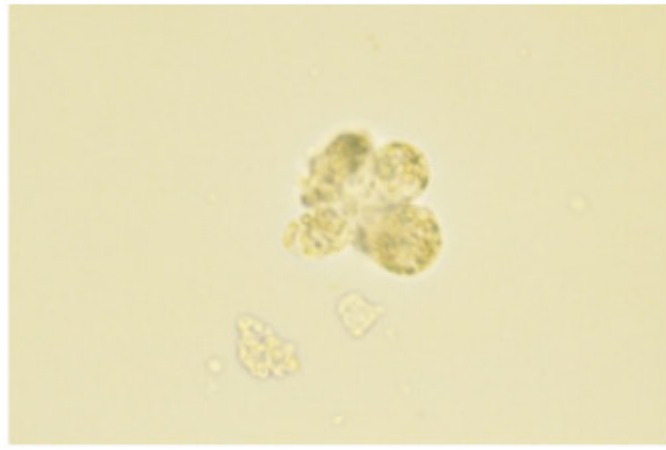

Custom Medical Stock Photo

▲ **Figure 13–4.3A** Fatty Casts

4.3 Nephrotic Syndrome

4.3.1 Clinical Features

- Massive proteinuria (>3.5g/day/24h)
- Hypoalbuminemia
- Edema (due to decreased oncotic pressure)
- Hyperlipidemia and hypercholesterolemia
- Hypercoagulable state: Decreased antithrombin III

4.3.2 Etiology

- Minimal change disease
- Focal segmental glomerulosclerosis
- Membranous glomerulonephritis
- Membranoproliferative glomerulonephritis
- Diabetic nephropathy
- Amyloid

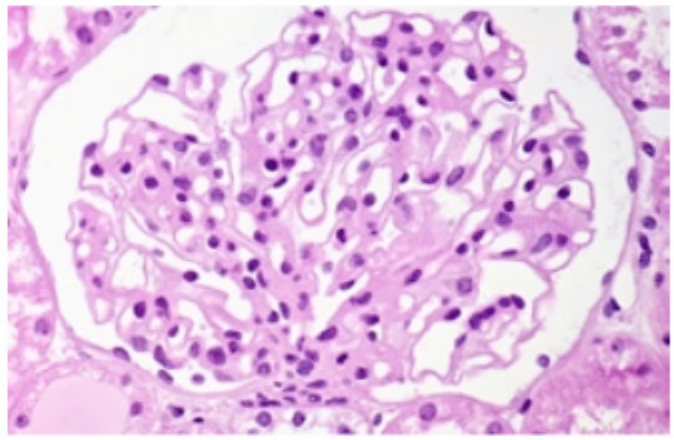

Dr. Gladden Willis/Visuals Unlimited, Inc.

▲ **Figure 13–4.3B** Normal Glomerulus Light Microscopy

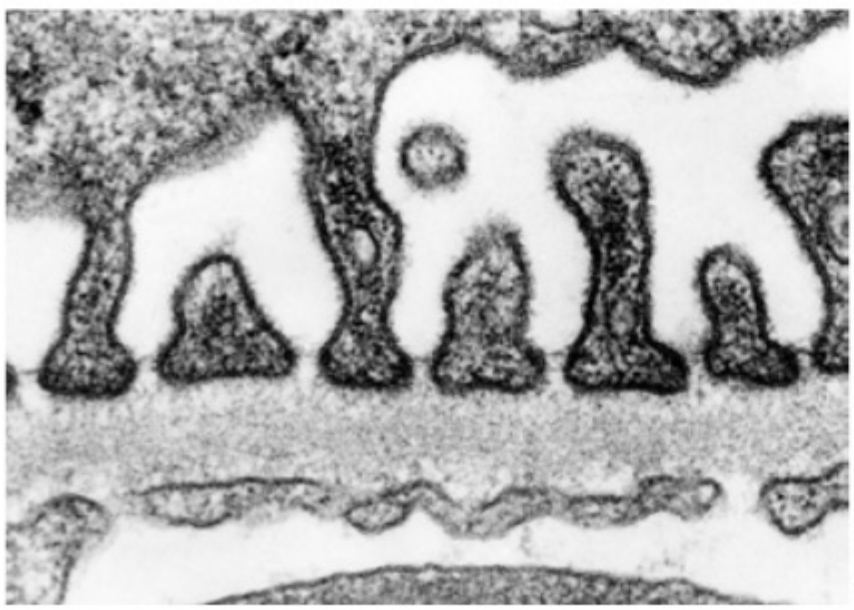

Dr. Donald Fawcett & D. Friend/Visuals Unlimited, Inc.

▲ **Figure 13–4.3C** Normal Glomerulus Electron Microscopy

Please visit us at www.Groupinsiders.com

© DeVry/Becker Educational Development Corp. All rights reserved.

4.3.3 Minimal Change Disease

- Most frequent cause of nephrotic syndrome in children.
- Characterized by normal microscopy and EM with diffuse loss of foot processes or foot process fusion of epithelial cells in glomeruli.
- Clinical Features:
  - Responsive to corticosteroids.
  - Majority with complete recovery.

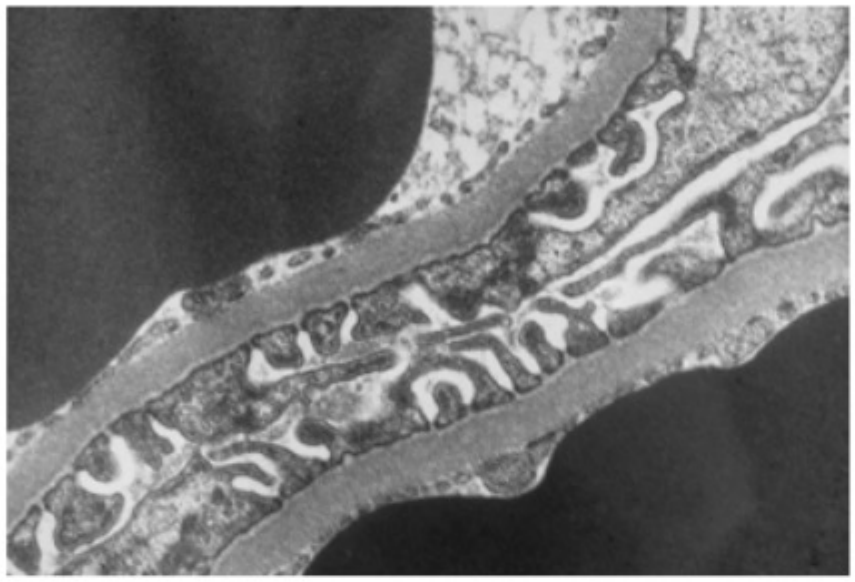

Dr. Fred Hossler/Visuals Unlimited, Inc.

▲ **Figure 13–4.3D** Minimal Change Disease

4.3.4 Focal Segmental Glomerulosclerosis

- Older patients
- Light Microscopy: Sclerosis of some glomeruli *(focal)* and only a portion the glomeruli involved *(segmental)*
- Electron Microscopy: Fusion of epithelial foot processes (podocytes)
- Immunofluorescence: IgM and C3 in the sclerotic lesions
- Associations:
  - HIV
  - African-American (genetic propensity)
  - Heroin use
  - Sickle cell disease
  - Obesity
- Pathology: Effacement of the epithelial cell foot processes
- Clinical Features:
  - Poor response to corticosteroids
  - Most progress to chronic renal failure

Please visit us at www.Groupinsiders.com

© DeVry/Becker Educational Development Corp. All rights reserved.

4.3.5 Membranous Glomerulonephritis

- *Most common* cause of nephrotic syndrome in *adults*.
- High incidence in teenagers and young adults.
- Light Microscopy: Diffuse thickening of glomerular *capillary wall*.
- Electron Microscopy: Accumulation of immunoglobulin-containing deposits along the basement membrane (intramembranous and *subepithelial*) with "spike and dome" appearance observed, due to projections of GBM (spike) between subepithelial deposits (domes).
- Immunofluorescence: Granular deposition of IgG or C3 (general characteristic of immune complex disease).

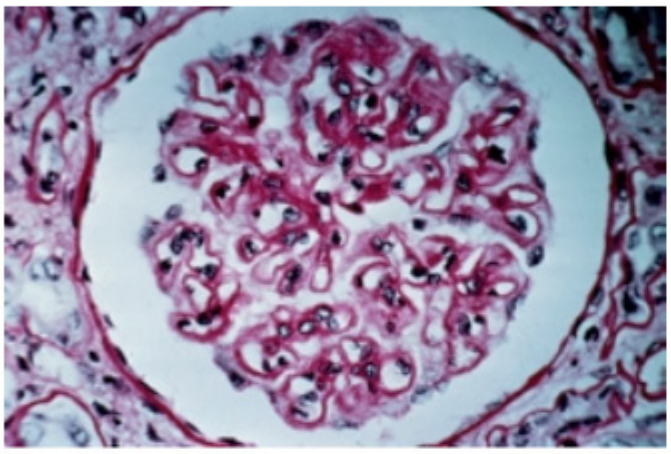
Wellcome Images

Notice the increased thickness of the glomerular basement membrane due to subepithelial deposition of immune complexes more clearly noticed under electron microscopy.

▲ **Figure 13–4.3E** Light Microscopy of Membranous Glomerulonephritis

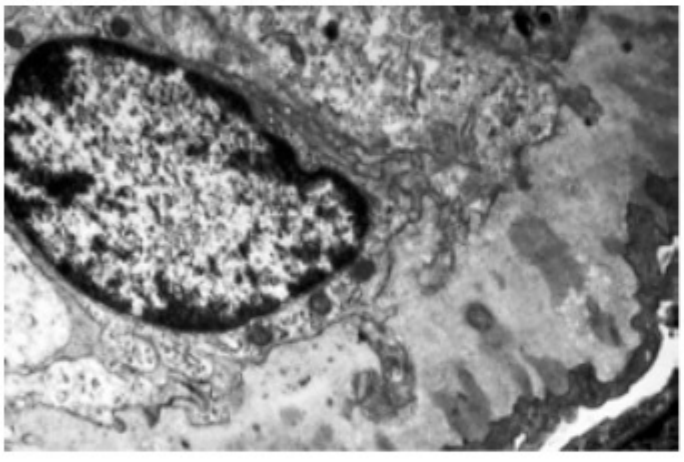
Wellcome Images

▲ **Figure 13–4.3F** Electron Microscopy of Membranous Glomerulonephritis

- Associations (usually primary but can be secondary):
  - Drugs: Penicillamine, captopril, gold, and NSAIDs
  - Malignancy: Lung, colon, and melanoma
  - Systemic lupus erythematosus (10% of patients)
  - Infections: HBV, HCV, syphilis, schistosomiasis, and malaria
  - Metabolic: Diabetes mellitus
- Prognosis:
  - Often progresses and rarely responds to steroid Tx.
  - Can progress to end-stage renal disease.
  - Can cause renal vein thrombosis.

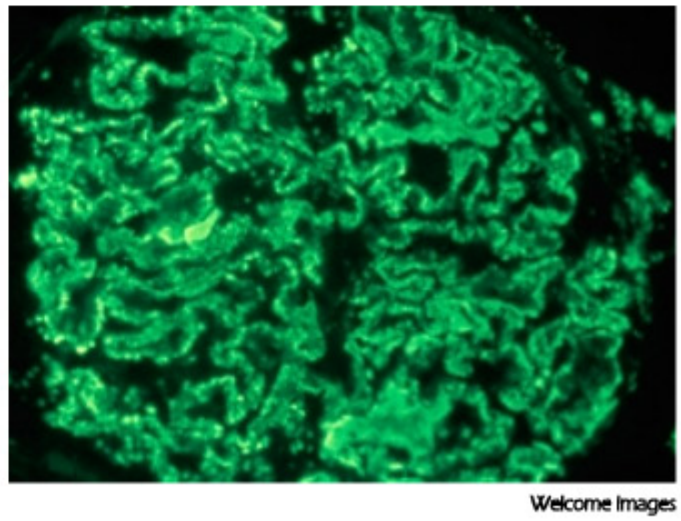
Welcome Images

▲ **Figure 13–4.3G** Membranous-Granular Pattern

Please visit us at www.Groupinsiders.com

© DeVry/Becker Educational Development Corp. All rights reserved.

4.3.6 Membranoproliferative Glomerulonephritis

Clinical Features

- Characterized by thickening of basement membrane with proliferation of glomerular cells.
- In its primary form, it is usually idiopathic and can present with nephritic or nephrotic features:
  - Immune complex: SLE, HBV, HCV, HIV.
  - CLL, lymphoma, melanoma.
- Some patients present with hematuria only.
- Some patients present with proteinuria in the non-nephrotic range.
- Some patients present with combined nephrotic-nephritic picture:
  - Decreased C3.
  - Prognosis: Chronic renal failure develops over 10 years.
  - Types I and II are both *similar under light microscopy* but different under electron microscopy and immunofluorescence.

Nonspecific Membranoproliferative Glomerulonephritis Findings

- Light Microscopy:
  - Global thickening of the GBM.
  - Glomeruli are large and hypercellular ("lobular appearance").

Membranoproliferative Glomerulonephritis Type I

- Immunofluorescence: Immune complex deposits giving a granular appearance.
- Electron Microscopy: Subendothelial electron dense deposits.

Membranoproliferative Glomerulonephritis Type II

- Immunofluorescence: Immune complex with c3 deposited in a granular pattern.
  - Most patients have antibody vs. c3 convertase (called C3 nephritic factor [NeF]).
  - Clinically characterized by decreased levels of serum c3: Hypocomplementemia.
- Electron Microscopy:
  - There is inclusion or interposition of cellular elements.
  - Dense deposits in the lamina densa of GBM; referred to as dense deposit disease (DDD).
  - Such interposition gives rise to the appearance of "split" BMs: This gives rise to the so-called tram-track appearance.

Please visit us at www.Groupinsiders.com

© DeVry/Becker Educational Development Corp. All rights reserved.

4.3.7 Diabetic Nephropathy

Chronic diabetes leads to matrix deposition and glycosylation of proteins leading to derangements of the glomerulus.

Clinical Features

- Microalbuminuria progressing to nephrotic range proteinuria.
- Hypertension.
- Progression to end-stage renal disease.
- Light Microscopy: Increase in mesangial matrix produces *Kimmelstiel-Wilson* nodules.
- Electron Microscopy (in order)
  1. Hyalinization of efferent arteriole.
  2. Thickened glomerular basement membrane.

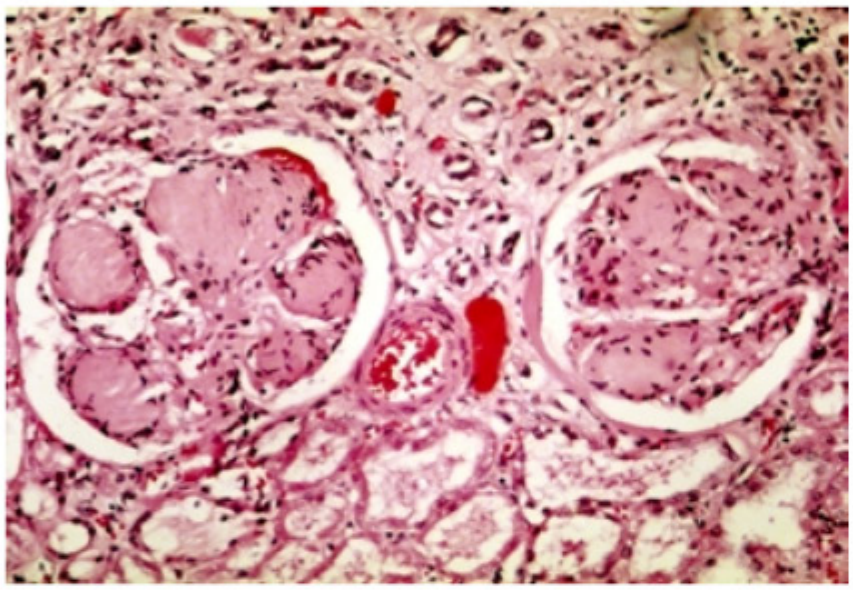

Courtesy of Dr. Edwin P. Ewing, Jr./CDC Image Library

▲ **Figure 13–4.3H** Diabetic Nephropathy

4.3.8 Renal Amyloid

- Subendothelial and mesangial amyloid deposits (congo red shows apple-green birefringence).
- Most commonly due to chronic inflammatory diseases such as rheumatoid arthritis or plasma cell disorders such as myeloma.

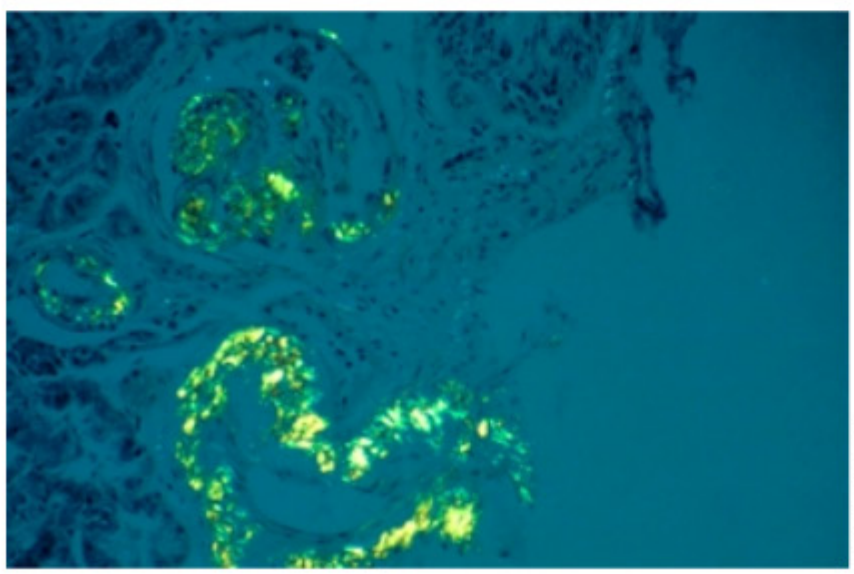

Wellcome Images

▲ **Figure 13–4.3I** Renal Amyloid

Please visit us at www.Groupinsiders.com

© DeVry/Becker Educational Development Corp. All rights reserved.

4.4 Nephritic Syndrome

Clinical Features

- Hematuria
- RBC casts
- Hypertension
- Azotemia
- Oliguria
- Proteinuria <3.5 gm/day
- May progress to rapidly progressive glomerulonephritis:
  - Acute nephritis
  - Proteinuria
  - Acute renal failure

4.4.1 Post-Streptococcal Glomerulonephritis

- Malaise, fever, nausea, oliguria, and hematuria two to four weeks after recovery from group A β-hemolytic streptococci (GAS) infection.
- Mild proteinuria, periorbital edema, and hypertension.
- Damage due to Ab–Ag complexes.

Histology

- Light Microscopy: Shows both kidneys being involved—enlarged (diffuse), hypercellular (proliferative).
- Electron Microscopy: Shows subepithelial "humps."
- Immunofluorescence: For IgG and C3, is "lumpy-bumpy" (i.e., course).

Lab Findings

- RBC casts.
- Azotemia.
- Decreased serum C3.
- Increased titers of antistreptococcal antibodies (ASO, anti-DNase B, and anticationic proteinase).

Prognosis

- Children: Complete recovery in >95% of cases.
- Adults: Complete recovery in 60% of cases.
- Some progress to RPGN.

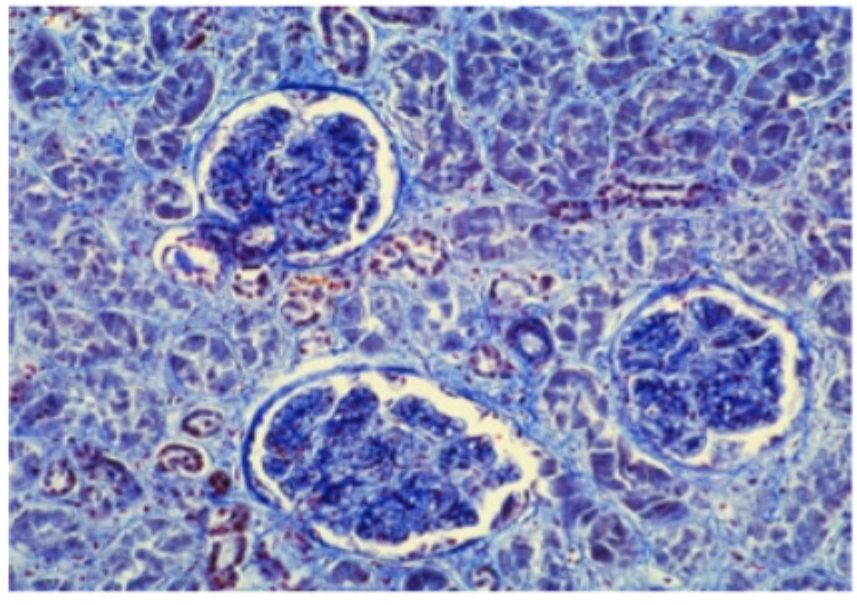

Astrid & Hanns-Frieder Michler/Science Source

▶ **Figure 13–4.4A** Subepithelial Hump of Post-Streptococcal Glomerulonephritis

Please visit us at www.Groupinsiders.com

© DeVry/Becker Educational Development Corp. All rights reserved.

4.4.2 IgA Nephropathy (Berger Disease)

- Characterized by presence of prominent IgA in mesangium.
- Most common type of glomerulonephritis worldwide.
- Clinical Features:
  - Gross hematuria in association with an upper respiratory tract infection (URTI). "Synpharyngitic hematuria"—no latent period.
  - Lasts for several days and recurs every few months.
  - 25% to 50% slowly progress to chronic renal failure.
- Can be a component of:
  - Henoch-Schönlein purpura.
  - Celiac disease.

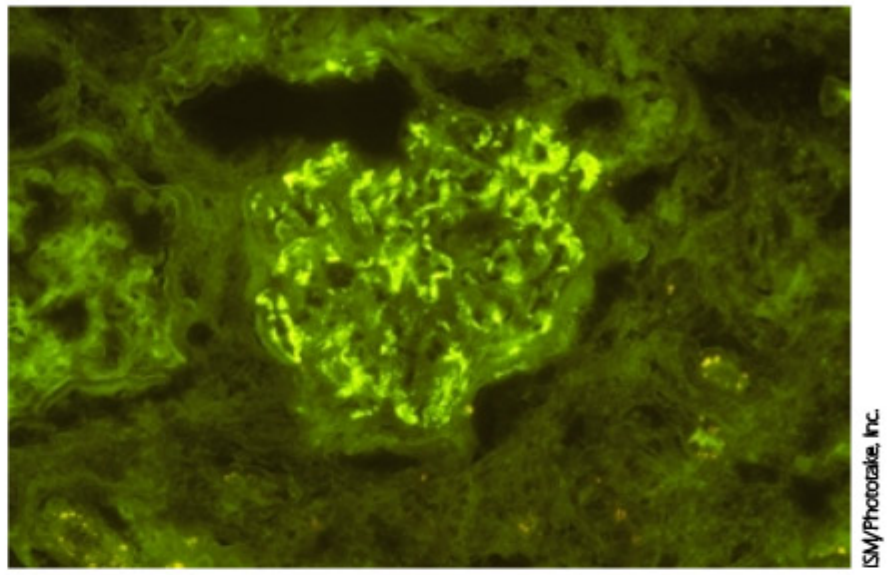

▲ **Figure 13–4.4B** IgA in Mesangium

4.4.3 Alport Syndrome

- Defective GBM synthesis is the underlying cause of this syndrome.
- Most cases are X-linked.
- Due to mutations in COL4A5.
- Electron Microscopy:
  - Shows irregular thickening of BM.
  - Lamination of lamina densa and foci of rarefaction.

4.5 Rapidly Progressive Glomerulonephritis (RPGN)

- Glomerulonephritis (RPGN).
- Clinically defined as nephritic syndrome progressing rapidly (in weeks) to renal failure.
- Patients present with hematuria, RBC casts in urine, and moderate proteinuria.
- H&E: Formation of fibrin crescents between Bowman capsule and glomerular tuft.
- Poor prognosis with rapid progression to end-stage renal disease.
- Type 1: Anti-GBM disease—Linear deposits of IgG and C3 on GBM.
  - Idiopathic (most common type).
  - Goodpasture syndrome (10%).
- Type 2: Immune complex mediated disease.
  - Post strep/infectious (50%).
  - Systemic lupus erythematosus.
  - Henoch-Schönlein purpura (IgA deposition).
- Type 3: Pauci-immune disease (ANCA+).
  - Wegener granulomatosis (Anti-proteinase 3, c-ANCA).
  - Polyarteritis nodosa (Anti-myeloperoxidase, p-ANCA).

Please visit us at www.Groupinsiders.com

© DeVry/Becker Educational Development Corp. All rights reserved.

4.5.1 Type I RPGN Anti-glomerular Basement Membrane (GBM) Disease

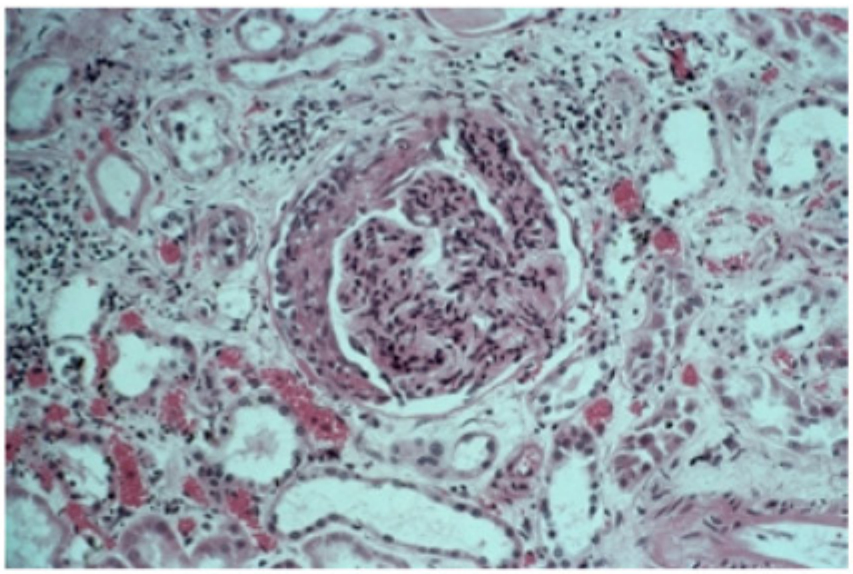
Wellcome Images

▲ **Figure 13–4.5A** Rapidly Progressive Glomerulonephritis

Goodpasture Syndrome

- Antibodies versus GBM in glomerular and pulmonary alveolar basement membranes
- Linear immunofluorescence (IgG)
- Characterized by anti-GBM antibodies
- Clinically shows:
  - Male patient in mid-20s
  - Nephritic syndrome
  - Pneumonitis with hemoptysis
  - May progress to RPGN

4.5.2 Type II RPGN Immune Complex Mediated

Post-Streptococcal (discussed previously)

Systemic Lupus Erythematosus Can manifest as nephritic, nephrotic, or both:

- Type I: No renal involvement.
- Type II: Mesangial form.
  - Slight increase in mesangial cells and matrix.
  - Slight proteinuria and minimal hematuria.
- Type III: Focal proliferative form.
- Type IV: Diffuse proliferative form.
  - Prototype of SLE nephropathy.
  - Combination of nephritic and nephrotic features.
  - Immune complex deposition (subendothelial) and gross thickening of BM results in wire-loops.
- Type V: Membranous form—10% of SLE patients have a primary membranous glomerulonephritis.

Important Concept

The two most important SLE-induced renal diseases for Step 1 are:

- Type IV (diffuse)
- Type V (membranous)

Please visit us at www.Groupinsiders.com

© DeVry/Becker Educational Development Corp. All rights reserved.

Henoch-Schönlein Purpura

- Characterized by purpuric skin lesions involving extensor surfaces of arms, legs, and buttocks.
- Systemic childhood disorder.
- Deposition of *IgA*, IgG, and C3 in mesangial region.
- Clinical Features:
  - Abdominal pain
  - Vomiting
  - Intestinal bleeding
  - Palpable purpura on legs and buttocks
  - Renal failure
  - Nonmigratory arthralgia

▲ **Figure 13–4.5B** Henoch-Schönlein Purpura

4.5.3 Type III RPGN Pauci-Immune Disease (ANCA+)

- **ANCA** = **a**nti-**n**eutrophil **c**ytoplasmic **a**ntibodies
- **P**erinuclear (**p**-ANCA):
  - Polyarteritis nodosa
    - —Necrotizing immune-complex inflammation of small- and medium-sized muscular arteries
    - —Anti-myeloperoxidase, p-ANCA
  - Churg-Strauss (asthma and eosinophilia)
  - Microscopic angiitis
- **C**ytoplasmic (**c**-ANCA):
  - Wegener granulomatosis
    - —Focal necrotizing vasculitis
    - —Necrotizing granulomas in the upper airway and lung
    - —Necrotizing glomerulonephritis
    - —Anti-proteinase 3, c-ANCA
    - —Clinically has perforation of nasal septum, sinusitis, cough, hemoptysis, and red cell casts

Please visit us at www.Groupinsiders.com

© DeVry/Becker Educational Development Corp. All rights reserved.

5 Diseases Affecting Tubules and Interstitium

5.1 Fanconi Syndrome

- Hereditary or acquired dysfunction of proximal renal tubules
- Clinically manifests as:
  - Glycosuria
  - Hyperphosphaturia/hypophosphatemia
  - Aminoaciduria
  - Systemic acidosis

5.2 Cystinuria

- Genetic defect in tubular reabsorption of cystine
- Clinically manifests as cystine stones

5.3 Hartnup Disease

- Genetic defect of tubular reabsorption of tryptophan
- Clinically manifests with pellagra-like symptoms

5.4 Acute Tubular Necrosis (ATN)

- Most common cause of acute renal failure in the United States
- Characterized by destruction of tubular epithelial cells
- Reversible through regeneration
- Clinical Features:
  - Oliguria
  - Metabolic acidosis
  - Hyperkalemia
- Cardiac problems during the initial oliguric phase: Dirty brown granular casts

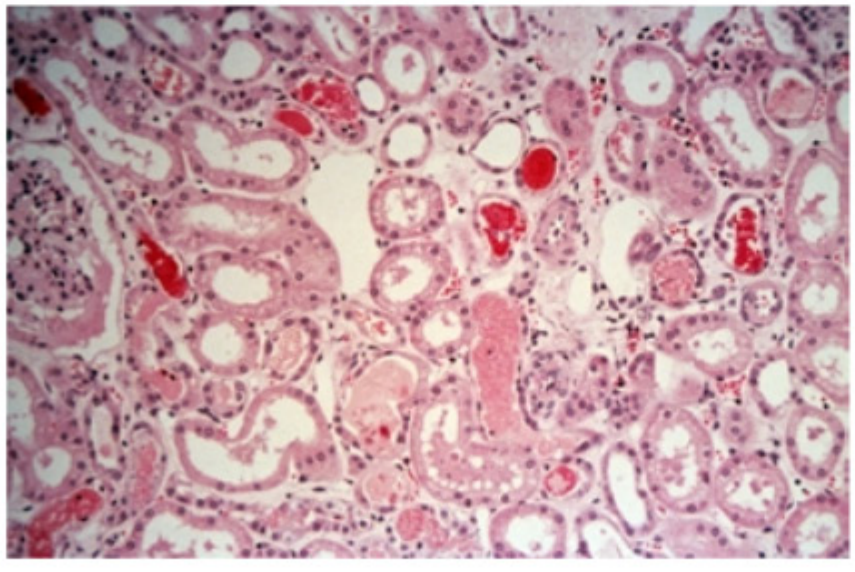

Welcome Images

▲ **Figure 13–5.4** Acute Tubular Necrosis

Please visit us at www.Groupinsiders.com

© DeVry/Becker Educational Development Corp. All rights reserved.

5.4.1 Ischemia ATN

- Most often precipitated by prerenal azotemia
- Coagulation necrosis of PCT and TAL

5.4.2 Nephrotoxic ATN

- Drugs (penicillin, sulfonamides, and aminoglycosides), contrast agents, heavy metals (Pb), and organic solvents
- Ethylene glycol (also associated with massive intratubular oxalate crystal deposition)
- Mushroom poisoning
- Myoglobin

5.5 Tubular Interstitial Nephritis (TIN)

5.5.1 Acute Drug-Induced TIN

- Acute renal failure due to hypersensitivity reaction.
- Patient presents with fever, dysuria, oliguria, rash, and eosinophilia.
- Eosinophiluria (WBC casts) is pathognomic for hypersensitivity AIN (or atheroembolic disease).
- Caused by sulfonamides, penicillins *(methicillin)*, thiazides, diuretics, and NSAIDs.
- Resolves with removal of drug.

5.5.2 Analgesic Nephropathy

- Caused by combination of acetaminophen and aspirin.
- Renal papillary necrosis with ring-sign necrosis.
- Pathology: Edema and infiltration of interstitium by mononuclear cells and eosinophils.

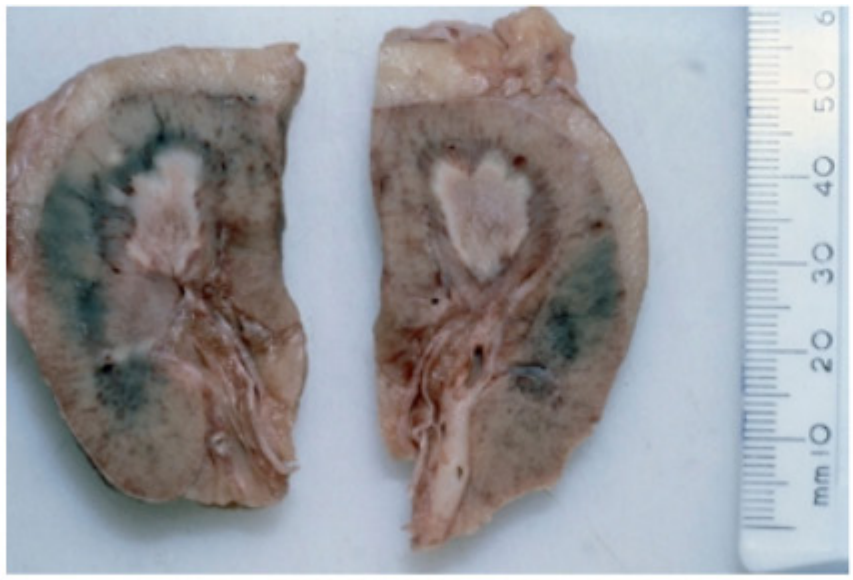

Wellcome Images

▲ **Figure 13–5.5** Renal Papillary Necrosis with Ring-Sign Necrosis

Please visit us at www.Groupinsiders.com

© DeVry/Becker Educational Development Corp. All rights reserved.

5.6 Urate Nephropathy

- Caused by precipitation of uric acid crystals in the renal tubules.
- Due to:
  - Tumor lysis syndrome seen with chemotherapy of leukemia or lymphoma.
  - Deposition of MSU in gout.

5.7 Nephrocalcinosis

- Diffuse calcium deposition in the kidney parenchyma.
- May cause (with hypercalcemia), or be an effect (due to hyperphosphatemia) of, renal failure.
- Causes of hypercalcemia can include:
  - 1° or ectopic hyperparathyroidism
  - Sarcoidosis with hypervitaminosis D
  - Milk-alkali syndrome
  - Metastatic disease

5.8 Multiple Myeloma

Multiple myeloma can damage the kidney in several ways:

- Bence Jones proteins are toxic to epithelial cells.
- Bence Jones proteins combine with Tamm-Horsfall proteins to form casts.
- Amyloidosis from light chain deposition.
- Hypercalcemia associated with MM.

Looking Ahead

For more on gout, see chapter 24, "Joint Pathology."

Please visit us at www.Groupinsiders.com

© DeVry/Becker Educational Development Corp. All rights reserved.

6 Infection

6.1 Infection of the Urinary Tract

- Occurs via:
  - Ascending infection from the bladder to the kidney:
    —Gram-negative rods: *Escherichia coli*, *Proteus*, and *Klebsiella*.
    —Normal flora of the colon.
  - Hematogenous spread to the kidney (Staph and *E. coli*).
- Increased incidence in women, especially during pregnancy.
- Predisposing factors include:
  - Obstruction.
  - Catheters.
  - Congenital abnormalities resulting in reflux.

Clinical Features

- Cystitis: Lower urinary tract infections—urinary frequency, pyuria, and hematuria, but *no white cell casts*.
- Pyelonephritis: Upper urinary tract infections—fever, flank tenderness (CVA tenderness on exam), and *presence of urinary white blood cells and white cell casts*.

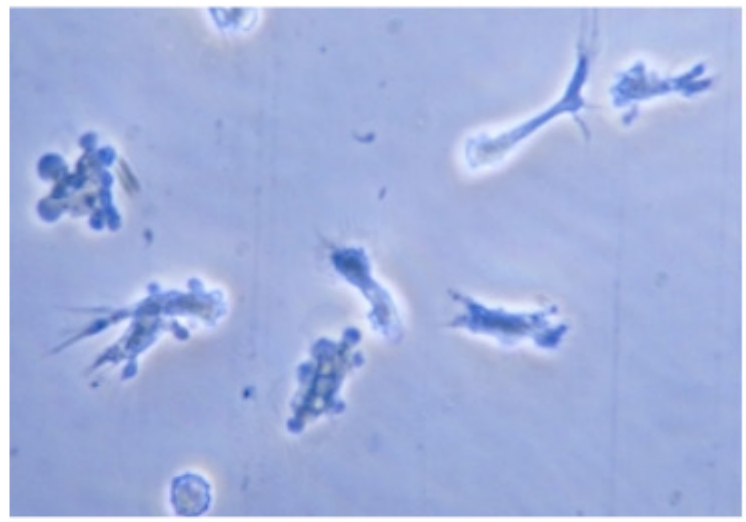
Carolina Biological Supply Co./Phototake, Inc.

▲ **Figure 13–6.2A** White Blood Cell Casts

Complications

- Papillary necrosis: Tips or distal two third of pyramids have gray-white to yellow necrosis that resembles infarction.
- Pyonephrosis: Suppurative exudates fill renal pelvis, calyces, and ureter.
- Perinephric abscess: Suppurative inflammation through renal capsule into perinephric tissue.

6.2 Reflux Nephropathy

- Most common form of chronic pyelonephritic scarring: Blunting of calyces.
- Urinary infection in setting of congenital vesicoureteral reflux and intrarenal reflux.

Clinical Features

- Fever, flank pain
- Lower urinary tract signs:
  - Frequency
  - Dysuria
  - Suprapubic pain
- WBC Casts

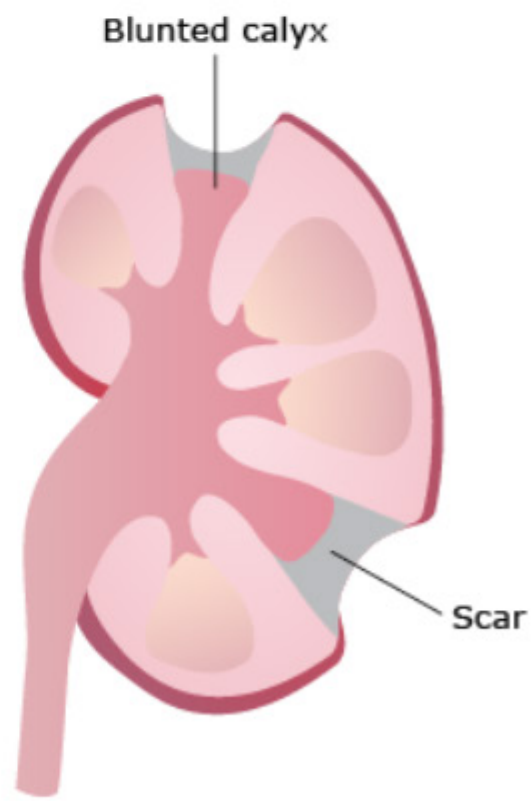

▲ **Figure 13–6.2B** Blunted Calyx

Please visit us at www.Groupinsiders.com

© DeVry/Becker Educational Development Corp. All rights reserved.

7 Vascular Disease

7.1 Renal Artery Stenosis

- Fibromuscular dysplasia (young women): Characterized by fibromuscular thickening and may involve intima, media, or adventitia of artery.
- Atherosclerosis (older men).

Clinical Features

- Low blood flow to JGA activates renin-angiotensin yielding increased aldosterone.
- Aldosterone grabs sodium to increase volume and drops K.
- Results in HTN with decreased K and elevated renin.

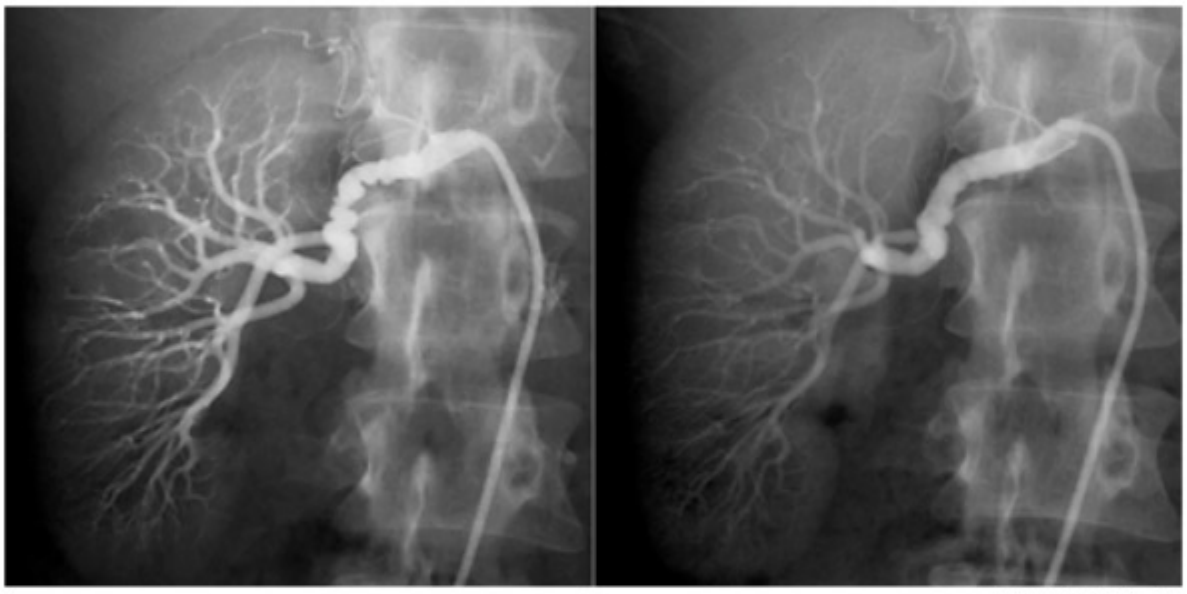

PDSN/Phototake, Inc.

▲ **Figure 13–7.1** Fibromuscular Dysplasia of the Renal Artery

7.2 Benign Nephrosclerosis

This vascular disease causes sclerosis of renal arterioles and small arteries, resulting in focal ischemia of parenchyma.

Risk Factors

- Hypertension
- Diabetes mellitus

Pathogenesis

- Medial and intimal thickening
- Narrowed lumen
- Hyaline deposition in arterioles

Clinical Features Renal failure and uremia

Connection to Physiology

For more on the actions of aldosterone, see *Physiology*, chapter 34, "The Adrenal Glands."

Please visit us at www.Groupinsiders.com

© DeVry/Becker Educational Development Corp. All rights reserved.

7.3 Malignant Nephrosclerosis

- Renal disease associated with malignant hypertension.
- Pathogenesis: Fibrinoid necrosis—endothelial injury and vplatelet deposition.

Clinical Features

- Papilledema
- Encephalopathy
- Renal failure

7.4 Thrombotic Microangiopathies

- Group of disorders with thrombosis in capillaries and arterioles throughout the body clinically manifesting as:
  - Microangiopathic hemolytic anemia
  - Thrombocytopenia
  - Renal failure (some cases)
- Categories:
  - Hemolytic-uremic syndrome
  - Thrombotic thrombocytopenic purpura

7.5 Hemolytic Uremic Syndrome

See chapter 11, "Cardiovascular Pathology."

7.6 Thrombotic Thrombocytopenic Purpura

See chapter 11, "Cardiovascular Pathology."

7.7 Sickle Cell Nephropathy

See chapter 6, "Red Blood Cell Pathology."

Please visit us at www.Groupinsiders.com

© DeVry/Becker Educational Development Corp. All rights reserved.

8 Urinary Tract Obstruction

8.1 Obstructive Uropathy

- Obstruction increases susceptibility to:
  - Infection
  - Stone formation
  - Renal swelling (hydronephrosis)

Pathology

- Enlarged kidneys
- Dilation of pelvis and calyces
- Interstitial inflammation
- Cortical tubular atrophy with marked interstitial fibrosis

Clinical Features Hydronephrosis on ultrasound

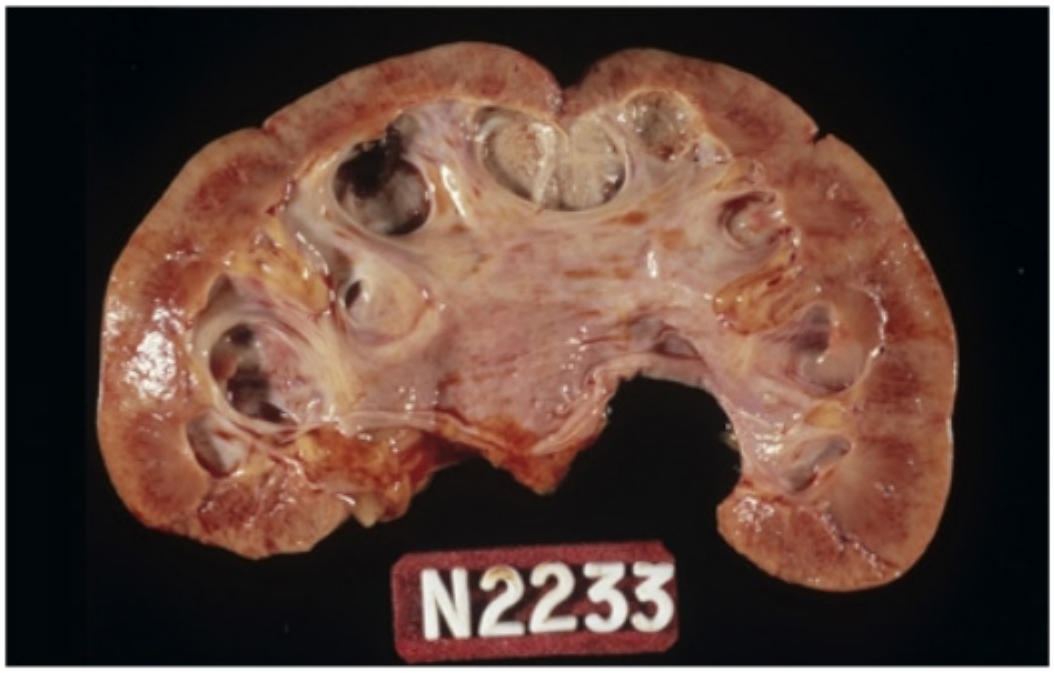

CNRI/Science Source

▲ **Figure 13–8.1** Hydronephrosis of the Renal Parenchyma

8.1.1 Urolithiasis

- Stone in the urinary tract
- Increased incidence in men
- Cause:
  - Supersaturation of stone contents
  - Low urine volume favors supersaturation
- Can be of several types

Please visit us at www.Groupinsiders.com

© DeVry/Becker Educational Development Corp. All rights reserved.

8.1.2 Types of Renal Calculi

- **Calcium Oxalate vs. Phosphate**
  - 80%–85% of stones
  - Radiopaque
  - Calcium oxalate, calcium phosphate, or both
  - Associated with hypercalcemia:
    - Hyperparathyroidism
    - Malignancy (mets or paraneoplastic)
    - Sarcoid
    - Milk-alkali syndrome
    - Vitamin D intoxication
- **Staghorn Stone (Magnesium, Ammonium, Phosphate)**
  - Second most common form
  - Radiopaque
  - Alkaline urine from ammonia-producing organisms (*Proteus*, Staph) helps
  - Can form large staghorn calculi (cast of renal pelvis) that can be nidus for UTI
- **Uric Acid Stone**
  - Radiolucent
  - Hyperuricemia:
    - Gout
    - Leukemia/myeloproliferative disease
- **Cystine Stones**
  - Radiolucent
  - Secondary to genetic defect in renal reabsorption of amino acids, especially cystine

Please visit us at www.Groupinsiders.com

© DeVry/Becker Educational Development Corp. All rights reserved.

9 Renal Failure

Chronic renal failure results from constellation of clinical signs and symptoms (see also azotemia discussed previously in this chapter).

9.1 Clinical Features

- **Bone:** Vitamin D deficiency
  - Hypocalcemia
  - Secondary hyperparathyroidism
  - Renal osteodystrophy
  - Osteitis fibrosa cystica
- **Cardiovascular**
  - Na^+/H_2O retention
  - Hypertension and congestive heart failure
- **Uremia**
  - Azotemia
  - Metabolic acidosis (due to decrease acid secretion and decreased bicarb production)
  - Hypertension (increased renin)
  - Hyperkalemia (leading to arrhythmias)
  - Sodium and H_2O excess (CHF and pulmonary edema)
  - Hypocalcemia (renal osteodystrophy)
  - Anemia (decreased EPO)
  - Neurologic disorders, urochrome in the skin, bleeding due to platelet dysfunction, fibrinous pericarditis
  - Urinalysis reveals waxy broadcasts

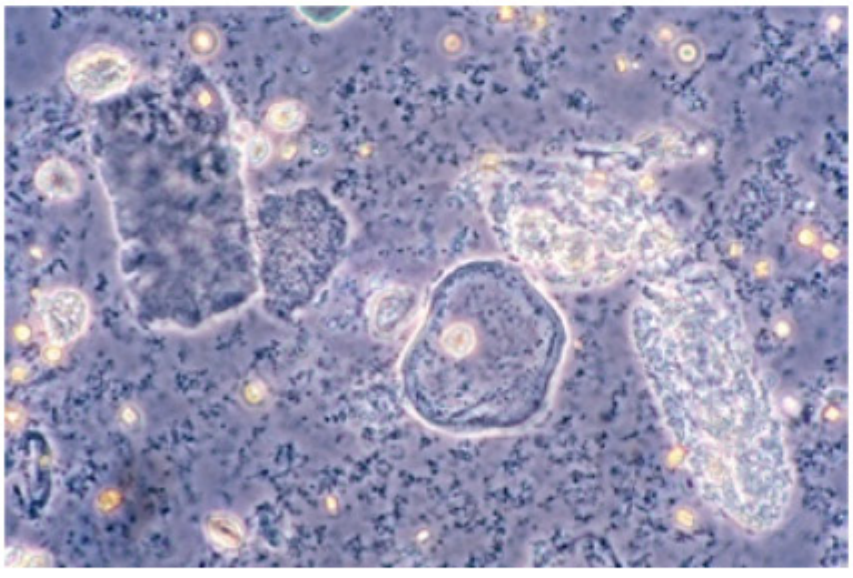

Dr. Frederick Skvara/Visuals Unlimited, Inc.

▲ **Figure 13–9.1** Urinalysis Waxy Broadcasts

Please visit us at www.Groupinsiders.com

© DeVry/Becker Educational Development Corp. All rights reserved.

10 Tumors of the Kidney

10.1 Malignant Tumor: Renal Cell Carcinoma

- *Most common* renal malignancy of *adults*.
- Males > females; ages 50–70 years.
- Associated with tobacco and obesity.
- Can be hereditary (multiple) or sporadic (single).
- Associated with Von Hippel-Lindau syndrome (hemangioblastomas of the cerebellum and retina).
- Clinical triad of flank pain, abdominal mass, and hematuria.
- Also associated with increase in ectopic hormone production:
  - Parathyroid hormone related-peptide (PTH-rP)
  - Erythropoietin
- Frequently invades renal vein and inferior vena cava resulting in early hematogenous spread.
- Pathology: Polygonal clear cells.

CNRI/Science Source

▲ **Figure 13–10.1** Renal Cell Carcinoma

10.2 Wilms Tumor

- Most common renal malignancy of *children* aged 2–5 years.
- Presents as unilateral large flank mass in a child with hypertension.
- Deletions in 11p (WT-1 and WT-2 are tumor suppressor genes).
- Can be part of the WAGR syndrome (associated with deletion of WT-1 gene):
  - Wilms tumor
  - Aniridia: Absence of the iris
  - Genital abnormalities
  - Intellectual disability
- Can be part of Beckwith-Wiedemann syndrome (associated with deletion of WT-2 gene):
  - Wilms tumor
  - Hemihypertrophy
  - Macroglossia
  - Organomegaly
  - Neonatal hypoglycemia

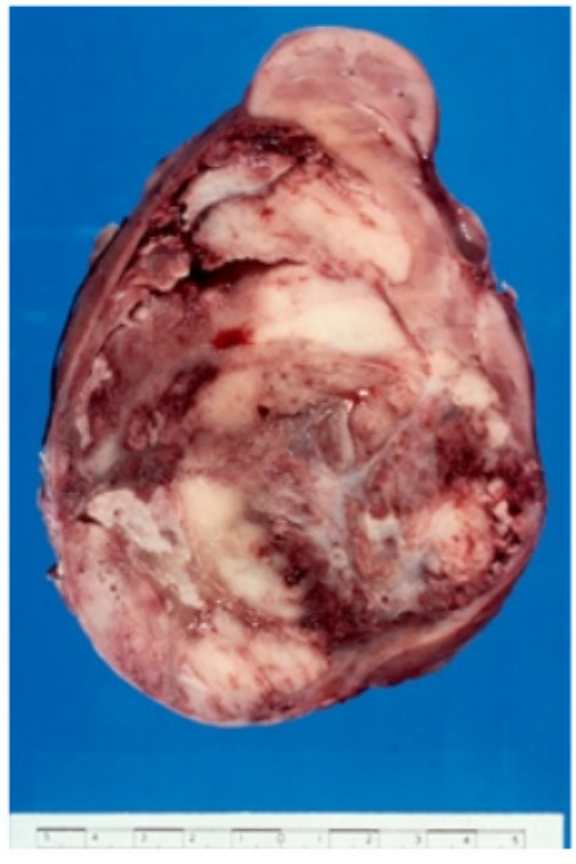

Wellcome Images/Custom Medical Stock Photo

▲ **Figure 13–10.2** Wilms Tumor

Please visit us at www.Groupinsiders.com

© DeVry/Becker Educational Development Corp. All rights reserved.

11 Lower Urinary Tract Pathology

11.1 Urothelial Carcinoma

11.1.1 Transitional Cell Carcinoma of the Urinary Bladder

- Most common tumor of the urinary collecting system.
- Presents with hematuria.
- Associated with the following:
  - Exposure to benzidine or β-naphthylamine (aniline) dyes
  - Cyclophosphamide
  - Smoking cigarettes
  - Phenacetin

11.1.2 Squamous Cell Carcinoma of the Urinary Bladder

Squamous metaplasia of collecting system must first occur:

- Chronic inflammatory process.
- *Schistosoma haematobium* infection.

11.1.3 Adenocarcinoma

- A second high-yield type of cancer of the urinary bladder.
- Not triggered by the same factors that trigger squamous cell carcinoma of the urinary bladder.
- Associated with urachus:
  - Fistula of urinary tract between bladder and umbilicus.
  - May serve as foci for infection.
  - Carcinomas may arise here.

Please visit us at www.Groupinsiders.com

© DeVry/Becker Educational Development Corp. All rights reserved.

Please visit us at www.Groupinsiders.com

Unit 6

Gastrointestinal Pathology

Please visit us at www.Groupinsiders.com

Please visit us at www.Groupinsiders.com

1 Gastrointestinal (GI) Pathology Overview

- The gastrointestinal system consists of:
  - The GI tract—oral cavity, esophagus, stomach, small intestine, colon, and anal canal (covered in order).
  - Accessory organs—liver, pancreas, and biliary tract.
- GI tract diseases fall into several categories:
  - **Inflammatory**
    Esophagitis
  - **Vascular**
    —Mallory-Weiss syndrome
    —Esophageal varices
  - **Neoplastic**
  - Squamous cell carcinoma
  - Adenocarcinoma

USMLE® Key Concepts

For Step 1, you must be able to:

- Identify various oropharyngeal pathologies.
- Differentiate amongst various esophageal pathologies.
- Explain the pathogenesis of various gastric pathologies.
- Identify various mechanical, malabsorptive, and neoplastic processes of the small and large intestine.
- Differentiate amongst different types of malabsorbtive and diarrheal conditions, and identify the causative organism responsible for these pathological conditions.

2 Oral Cavity

2.1 Congenital: Cleft Lip/Palate

Failure of fusion of facial processes.

2.2 Infectious Diseases of the Oral Cavity

- Actinomycosis: Gram-positive anaerobic filamentous bacteria found in a draining sinus tract, usually the jaw, where yellow sulfur granules may be discovered.
  - HSV type 1, mumps, Coxsackievirus, *Candida albicans*
  - Oral melanin pigmentation that may be found de nova in Peutz-Jeghers syndrome associated with hamartomatous polyps and carries a 50% risk of colorectal cancer (see topic 11.1).
  - Erythroplakia versus leukoplakia (see chapter 28, "Dermatopathology")

Watney Collection/Phototake, Inc.

▶ **Figure 14–2.2** Peutz-Jeghers Syndrome

Please visit us at www.Groupinsiders.com

© DeVry/Becker Educational Development Corp. All rights reserved.

3 Esophagus

3.1 Signs and Symptoms of Esophageal Diseases

- Indigestion with GERD is the most common esophageal symptom.
- Dysphagia of solids only: Obstructive diseases such as esophageal webs and early onset of esophageal cancer
- Dysphagia of solids and liquids: Achalasia, systemic sclerosis, myasthenia gravis
- Odynophagia: If painful deglutition is found, infections must be ruled out and HIV must be considered as a differential.

3.1.1 Tracheoesophageal Fistula

Etiology

- Congenital
- Presents in *neonates*

Morphology

- The most common manifestation type presents with:
  - Proximal blind-ending esophagus
  - Fistula between trachea and distal esophagus

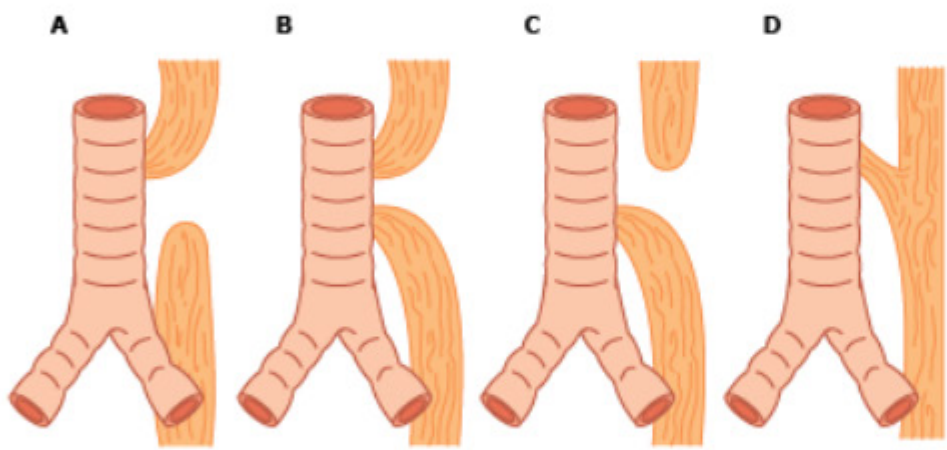

▲ **Figure 14–3.1A** Tracheoesophageal Fistula (Pattern C)

Clinical Findings

- Inability of fetus to swallow amniotic fluid results in maternal *polyhydramnios*.
- Vomiting with first feeding.
- Must be thought of with the constellation of **VATER**
  - **V** = Vertebral abnormality
  - **A** = Anal atresia
  - **TE** = Tracheoesophageal fistula
  - **R** = Renal disease or absent radius (limb deformity)

Imaging Studies

- Infant radiograph shows gastric bubbles.
- Looping of nasogastric tube in blind-ending proximal esophagus.
- Passage of gastric contents into the respiratory tract causes *aspiration pneumonia*.

Please visit us at www.Groupinsiders.com

© DeVry/Becker Educational Development Corp. All rights reserved.

Please visit us at www.Groupinsiders.com

3.1.2 Esophageal Webs

Etiology

- Acquired; usually in women 30 to 50 years old.
- Upper esophageal webs are associated with *iron-deficiency anemia (Plummer-Vinson syndrome)*.

Morphology Protrusion of esophageal mucosa into esophagus.

Pathogenesis Causes obstruction, leading to *dysphagia for solids*.

3.1.3 Achalasia

Etiology Idiopathic or acquired (Chagas disease)

Pathogenesis

- *Lack of ganglion cells in myenteric plexus*.
- Causes impaired peristalsis and decreased relaxation of the lower esophageal sphincter.

Morphology

- Dilated lower esophagus
- *Classic "bird-beak sign" on barium swallow*

Clinical Pathology

- *Progressive dysphagia for solids, then liquids*
- Risk for aspiration pneumonia and esophageal rupture

3.1.4 Hiatal Hernia

Pathogenesis/Morphology Protrusion of the stomach through a widened esophageal hiatus of the diaphragm.

Clinical Findings Causes gastroesophageal reflux and esophagitis that may be severe and medically intractable, requiring surgery.

- *Incarcerated hernia = surgical emergency*

3.1.5 Gastroesophageal Reflux Disease (GERD)

Etiology Risk factors include hiatal hernia, smoking, alcohol, caffeine, and fatty or spicy foods.

Pathogenesis Decreased tone of the lower esophageal sphincter, allowing reflux of gastric contents into the esophagus.

Clinical Pathology Causes heartburn, reflux esophagitis.

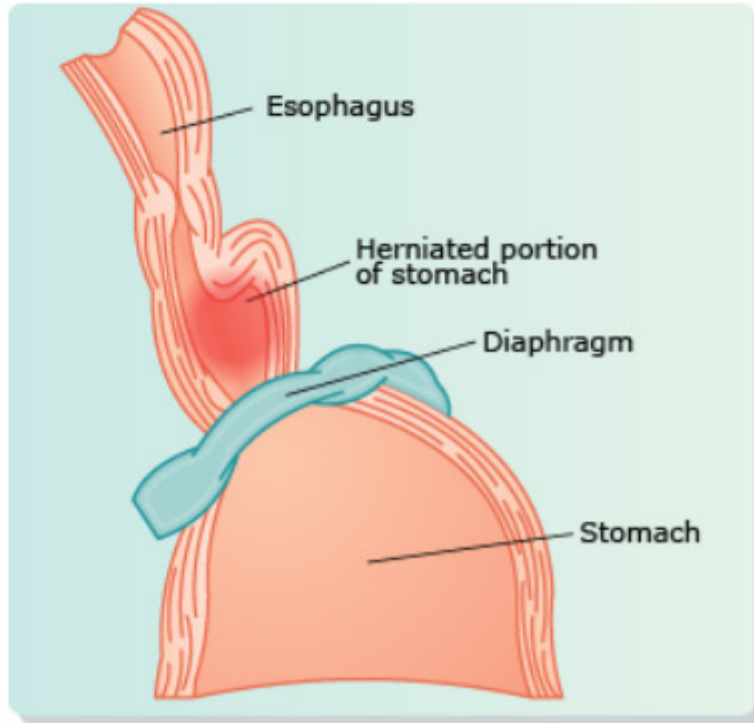

▶ **Figure 14–3.1B** Hiatal Hernia

© DeVry/Becker Educational Development Corp. All rights reserved.

3.2 Esophagitis

Inflammation of the esophageal mucosa

Etiology

- Reflux esophagitis—chronic GERD
- Infectious esophagitis—HSV, CMV, *Candida* in immunosuppressed patients.
- Chemical esophagitis—ingestion of strong acid or alkali

Pathogenesis Chronic inflammation leads to:

- Strictures and dysphagia
- *Esophageal metaplasia*, such as change from esophageal squamous epithelium to columnar gastric epithelium (Barrett esophagus) with increased risk of adenocarcinoma.

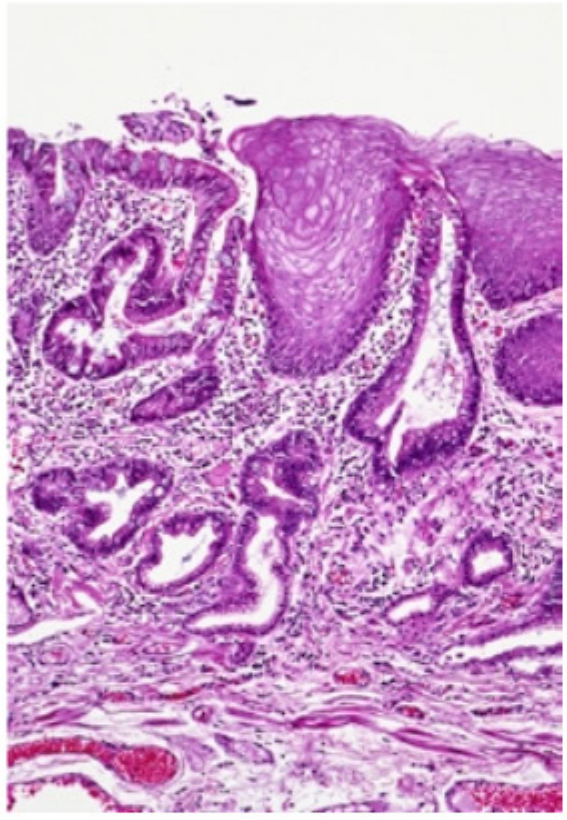

Dr. Gladden Willis/Visuals Unlimited, Inc.

▲ **Figure 14–3.2** Esophagus: Normal GEJ and Mucosa

3.3 Mallory-Weiss Syndrome

Etiology Prolonged *severe vomiting*, most often in *alcoholics* and *bulimics.*

Morphology Longitudinal tears in the esophageal mucosa near the gastroesophageal junction

Clinical Pathology

- Hematemesis, sometimes severe with significant blood loss
- Rarely leads to esophageal rupture (*Boerhaave syndrome*), which is often fatal.

Please visit us at www.Groupinsiders.com

© DeVry/Becker Educational Development Corp. All rights reserved.

3.4 Esophageal Varices

Etiology *Portal hypertension* from liver disease, usually cirrhosis

Pathogenesis

- Increased pressure in the esophageal venous system
- Causes dilation of submucosal veins in the lower third of the esophagus and are then prone to rupture.

Clinical Pathology Asymptomatic, except in case of *rupture*, which causes severe, potentially fatal, hemorrhage.

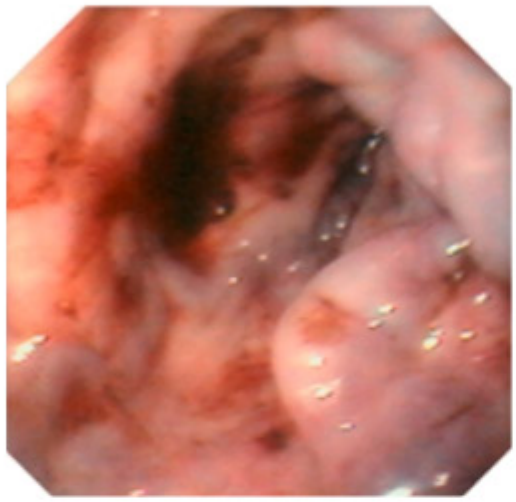

David M. Martin, MD/Science Source/ Custom Medical Stock Photo

▲ **Figure 14–3.4** Esophageal Varices

3.5 Esophagus: Neoplastic Diseases

▼ **Table 14–3.5** Neoplastic Diseases

	Squamous Cell Carcinoma	Adenocarcinoma
Epidemiology	Most common outside U.S.; M > F; >50 years	Most common in U.S.; M > F; >40 years old
Risk factors	Smoking, alcohol, achalasia	Esophagitis, Barrett esophagus
Location	Mid-esophagus	Distal esophagus

David M. Martin, MD/Science Source/ Custom Medical Stock Photo

▲ **Figure 14–3.5** Esophageal Adenocarcinoma

Please visit us at www.Groupinsiders.com

© DeVry/Becker Educational Development Corp. All rights reserved.

4 Gastric Diseases

Structural/Functional

- Pyloric stenosis
- Congenital diaphragmatic hernia
- Hypertrophic gastropathy

Inflammatory

- Acute gastritis
- Chronic gastritis
- Peptic ulcer disease

Neoplastic

- Gastric adenocarcinoma
- MALT lymphoma

4.1 Pyloric Stenosis

Etiology Congenital; presents between two weeks and two months of life.

Pathogenesis

- Marked hypertrophy of the pyloric sphincter.
- Results in gastric outlet obstruction.

Clinical Pathology

- Males > females; more common in firstborn children.
- Causes projectile vomiting after feeding.
- *Often palpable "olive" on abdominal exam.*

4.2 Congenital Diaphragmatic Hernia

Etiology Congenital; presents at birth.

Pathogenesis

- Structural *defect of the diaphragm*, resulting in the protrusion of abdominal contents into the thoracic cavity.
- *Stomach is the most common herniated organ.*

Clinical Pathology Causes respiratory compromise, necessitating extracorporeal membrane oxygenation (ECMO) until surgical intervention.

Please visit us at www.Groupinsiders.com

© DeVry/Becker Educational Development Corp. All rights reserved.

4.3 Hypertrophic Gastropathy

- Common features:
  - Hypertrophy of gastric epithelial cells
  - Thickened rugal folds

ISM/Phototake, Inc.

▲ **Figure 14–4.3** Structural/ Functional Stomach Diseases

- Two Types:

1. *Ménétrier Disease*

- Hypertrophy of *mucus cells* replacing glands.
- Decreased acid production leading to protein-losing enteropathy and increased risk of gastric cancer.

2. *Zollinger-Ellison Syndrome*

- Gastrin-producing pancreatic adenoma.
- Hypertrophy of *gastric glands* (chief and parietal cells) leading to acid overproduction and intractable peptic ulcer disease.

Please visit us at www.Groupinsiders.com

© DeVry/Becker Educational Development Corp. All rights reserved.

5 Acute Erosive (Hemorrhagic) Gastritis

Etiology

- Chronic NSAID or aspirin use
- Alcohol
- Smoking
- *Extreme physiologic stress*
  - *Curling ulcers (burns)*
  - *Cushing ulcers (head injury)*

Pathogenesis

- Breakdown of mucosal barrier (inhibition of prostaglandins)

CNRI/Science Source

▲ **Figure 14–5.0** Hemorrhagic Gastritis

Morphology Small, round, superficial ulcers

Clinical Findings

- Presents with abdominal pain, nausea, vomiting.
- *Bleeding (melena, hematemesis) is the most serious complication.*

▼ **Table 14–5.0** Hemorrhagic Gastritis

	Fundic (type A) Hemorrhagic Gastritis	Antral (type B) Hemorrhagic Gastritis
Etiology	Anti-parietal cell Abs	*Helicobacter pylori*
Location	Fundus, body	Antrum, pylorus
Morphology	Mucosal atrophy with loss of parietal cells; chronic inflammation; intestinal metaplasia	Gastric and duodenal ulcers; chronic inflammation; intestinal metaplasia
Complications	Pernicious anemia; ↑ risk of gastric cancer	Bleeding; ↑ risk of gastric cancer, MALT lymphoma

Please visit us at www.Groupinsiders.com

© DeVry/Becker Educational Development Corp. All rights reserved.

5.1 Peptic Ulcer Disease

Ulcers of the *distal stomach and proximal duodenum*

Etiology

- Decreased mucosal barrier
  - *H. pylori*
  - *NSAIDS* (inhibiting prostaglandin production)
  - Steroids
- Increased acid production (duodenal ulcer only)
  - Idiopathic
  - Gastrin-secreting tumors (*MEN I/Zollinger-Ellison syndrome*)

Morphology

- Small (<3 cm) and round or oval
- Sharply demarcated—"punched out"
- Overhanging margins and radiating mucosal folds

Complications

- Bleeding

▼Table 14–5.1 Gastric and Duodenal Ulcers

	Gastric	Duodenal
Percentage of cases	25%	75%
Epidemiology	M:F = 1:1; ↑ risk with blood group A	M:F = 2:1; ↑ risk with blood group O
H. pylori	~80% of cases	90% to 95% of cases
Complications	Bleeding from left gastric artery perforation	Bleeding from gastroduodenal artery perforation, which appears radiographically as air under diaphragm
Location	Lesser curvature of antrum	Most commonly anterior portion of first part of duodenum, posteriorly (pancreatitis)
Clinical findings	Epigastric pain immediately after eating	Epigastric pain 1 to 3 hrs after eating; pain relieved by eating

Please visit us at www.Groupinsiders.com

© DeVry/Becker Educational Development Corp. All rights reserved.

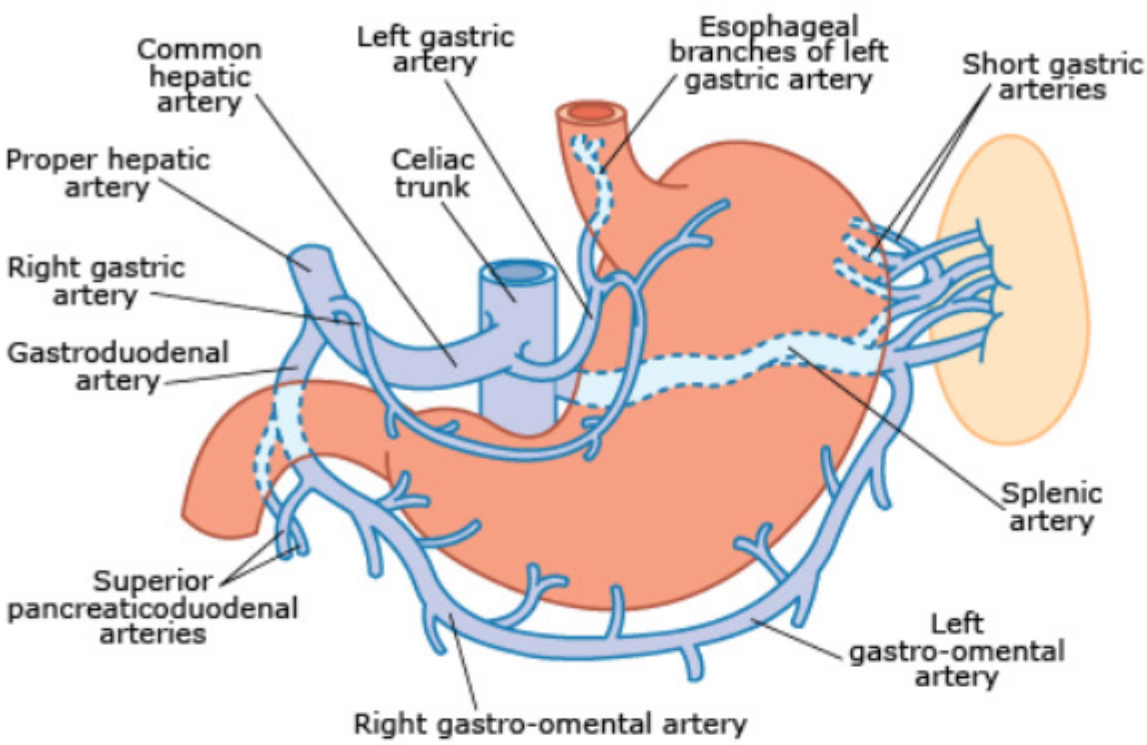

▲ **Figure 14–5.1** Anatomy of Gastric Blood Supply

5.2 Gastric Tumors

5.2.1 Leiomyoma

Most common benign tumor in the stomach that may ulcerate or bleed (upper GI bleed).

5.2.2 Primary Gastric Adenocarcinomas

Epidemiology and Etiology

- Decreasing incidence in the United States
- Increasing incidence in Japan due to consumption of nitrates of smoked foods
- Ménétrier disease
- Increased incidence in patients with blood group A.

Pathogenesis

- Two Types
  1. Intestinal type is the most common
     —Develops from intestinal metaplasia due to *H. pylori* commonly located in the lesser curvature of pylorus and antrum.
  2. Diffuse type
     —Not associated with *H. pylori*.
     —Poorly differentiated, *signet ring* forming.
     —Diffuse lateral invasion—*linitis plastica*

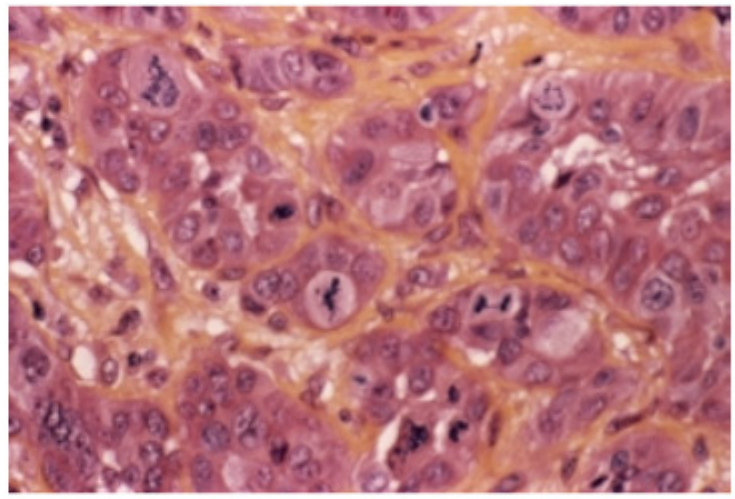

CNRI/Science Source

▲ **Figure 14–5.2A** Signet Ring-Type Gastric Adenocarcinoma

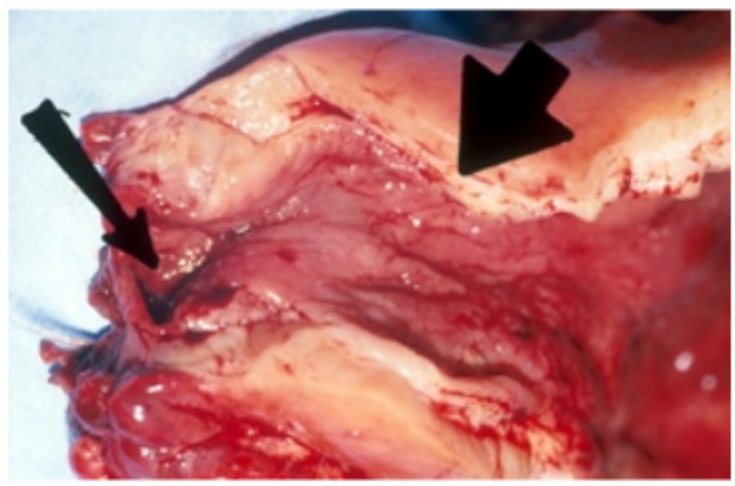

George Moore, MD, PhD/Custom Medical Stock Photo

▲ **Figure 14–5.2B** Linitis Plastica

Please visit us at www.Groupinsiders.com

© DeVry/Becker Educational Development Corp. All rights reserved.

Clinical Findings of Gastric Adenocarcinoma

- Commonly metastatic at presentation
  - Left supraclavicular lymph node: *Virchow node*
  - Ovaries: *Krukenberg tumor*
  - Umbilicus: *Sister Mary Joseph node*
  - Also liver and lungs
- Often asymptomatic until late in course.
- Presents with weight loss, anorexia, early satiety, and abdominal pain.
- May have occult bleeding, iron-deficiency anemia.
- Paraneoplastic skin lesions
  - Acanthosis nigracans
  - Multiple outcroppings of seborrheic keratosis (Leser-Trélat sign)

5.2.3 Primary Gastric Malignant Lymphoma

- The stomach is the most common site for primary GI malignant lymphoma.
  - Peyer patches is the second most common site.
  - *H. pylori*-related where treatment results in 50% cure rate of lymphoma.
    —Low-grade B-cell lymphoma
    —Mucosa-associated lymphoid tissue (MALToma)

5.3 Intestinal Diseases

Structural/Functional

- Duodenal atresia
- Intussusception
- Volvulus
- Meckel diverticulum
- Small bowel obstruction
- Diverticulosis
- Hirschsprung disease
- Diarrhea

Inflammatory

- Giardiasis
- Pseudomembranous colitis
- Appendicitis
- Inflammatory bowel disease

Vascular

- Hemorrhoids
- Bowel ischemia and infarction

Neoplastic

- Carcinoid
- Colon cancer

Please visit us at www.Groupinsiders.com

© DeVry/Becker Educational Development Corp. All rights reserved.

Please visit us at www.Groupinsiders.com

5.3.1 Duodenal Atresia

- Congenital narrowing or obstruction of the duodenal lumen.
- Associated with Down syndrome and maternal polyhydramnios.
- Causes bilious vomiting at birth.
- Characteristic *"double bubble" sign on x-ray*.

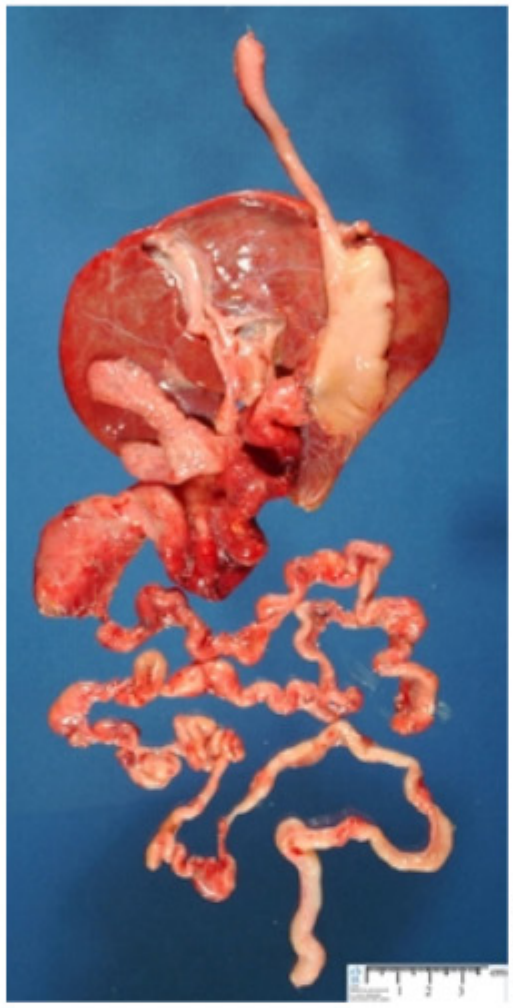

▲ **Figure 14–5.3A** Duodenal Artesia

5.3.2 Intussusception

- "Telescoping" of proximal segment of small bowel into distal segment.
- Leads to ischemia and obstruction.
- Most common in *infants and small children*, although it may be seen in adults with intestinal masses.
- Causes severe abdominal pain and GI bleeding ("currant jelly" stools).

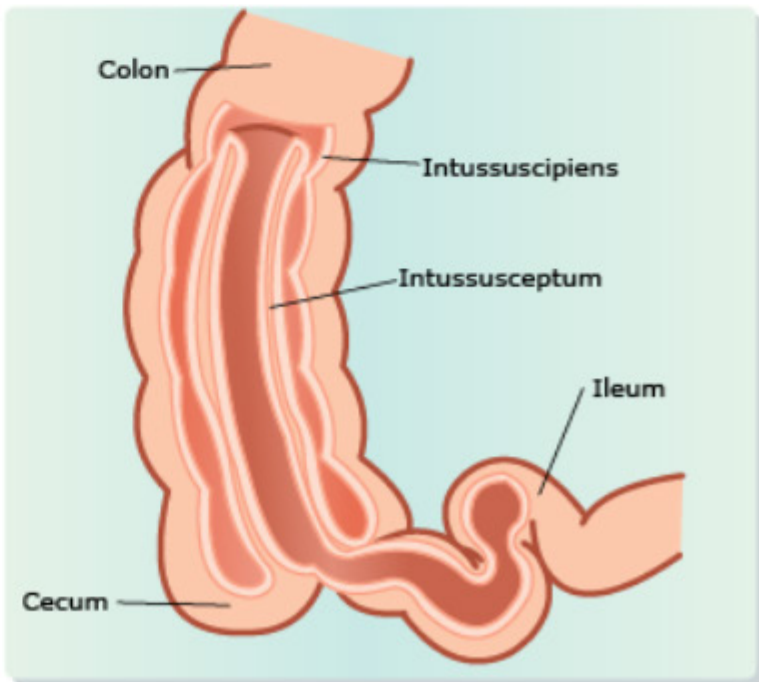

▶ **Figure 14–5.3B** Intussusception

© DeVry/Becker Educational Development Corp. All rights reserved.

5.3.3 Volvulus

- Twisting of an intestinal segment on its mesentery.
- Leads to ischemia and obstruction.
- Most often seen in sigmoid colon in the elderly, cecum in young adults.
- Complication sequence is obstruction and strangulation → *Bowel infarction*

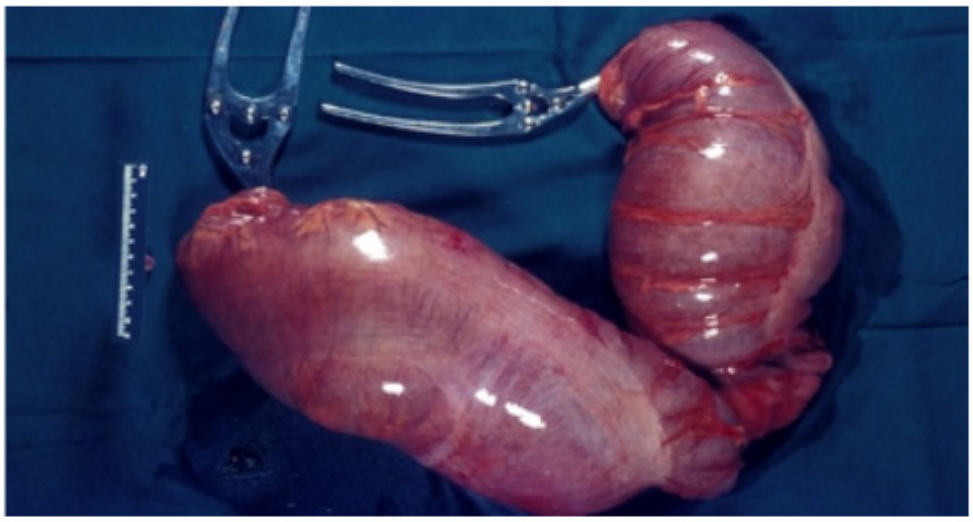

Dr. M.A. Ansary/Science Source

▲ **Figure 14–5.3C** Volvulus

5.3.4 Meckel Diverticulum

Etiology Remnant of an embryonic (vitelline) duct that persists in some children.

- *Rule of 2s*
  - 2 inches long, 2 feet from the ICV, 2% of the population are affected
  - 2% are symptomatic

Pathogenesis Usually benign, but may:

- Leakage of intestinal content in patient through the umbilicus.
- Have heterotopic gastric tissue that can develop bleeding ulcers.
- Develop diverticulitis with infection and inflammation.

O.J. Staats, MD/Custom Medical Stock Photo

▲ **Figure 14–5.3D** Meckel Diverticulum

Please visit us at www.Groupinsiders.com

© DeVry/Becker Educational Development Corp. All rights reserved.

5.3.5 Small Bowel Obstruction

▼ **Table 14–5.3** Small Bowel Obstruction vs. Small Bowel Infarction

Small Bowel Obstruction	Small Bowel Infarction
Small bowel is more likely to obstruct than large bowel **Etiology** • Most commonly caused by *post-surgical adhesions* • Incarcerated indirect inguinal hernia • Volvulus • Intussusception • Tumor **Clinical pathology** • Causes colicky abdominal pain, constipation/obstipation, bowel distention with air-fluid levels on x-ray • Distension of abdomen • No rebound tenderness • High-pitched tinkling sounds	Small bowel hemorrhagic infarction **Etiology** • Secondary to embolization or thrombosis of either artery or vein **Clinical findings** • Sudden onset of diffuse abdominal pain • Absent bowel sounds • No rebound tenderness initially • Bloody diarrhea • Often involves the superior mesenteric artery, which may necessitate resection, resulting in short gut syndrome and its associated complications

5.3.6 Diverticulosis

Etiology

- Often occurs after chronic constipation.
- Low-fiber diet increases risk.
- Most common in *sigmoid colon*, but also occurs in *duodenum*.

Pathogenesis

- Mucosa and submucosa pouch out through weak spot in muscularis.
- Usually occurs at a site of inherent weakness where vessels penetrate the muscularis.

Boilershot Photo/Science Source

▲ **Figure 14–5.3E** Diverticulosis

Clinical Pathology—Complications

- *Diverticulitis—inflammation* of diverticuli. May lead to ulceration, ischemia, abscess, or perforation.
- Ulceration may erode into vessels, causing *hematochezia* (bright red blood per rectum).
- *Fecalith*—impacted fecal material trapped in a diverticulum.

Please visit us at www.Groupinsiders.com

© DeVry/Becker Educational Development Corp. All rights reserved.

5.3.7 Hirschsprung Disease

Etiology

- Lack of enteric ganglion cells in distal colon and/or rectum
  - **Congenital:** Failure of *neural crest cells* to migrate to the bowel
  - **Acquired:** *Chagas disease*

Pathogenesis

- Affected segment has defect in motility—functional obstruction.
- Aganglionic segment is normal-appearing; proximal colon is dilated.

Barry Slaven, MD, PhD/Phototake, Inc.

▲ **Figure 14–5.3F** Hirschsprung Disease

Clinical Findings

- Present in neonatal period with delayed passage of meconium.
- Causes abdominal pain, distension, constipation, and vomiting.
- Complications include infection and perforation.
- *Diagnosed by rectal biopsy—absence of ganglion cells.*

Please visit us at www.Groupinsiders.com

© DeVry/Becker Educational Development Corp. All rights reserved.

6 Diarrhea

▼Table 14–6.0A Types and Characteristics of Diarrhea

Type	Characteristics	Causes	Screening Tests
Invasive	Pathogens invade enterocytes Low-volume diarrhea	*Shigella* spp. *Campylobacter jejuni*	Fecal smear for leukocytes: positive in most cases
	Diarrhea with blood and leukocytes (i.e., dysentery)	*Entamoeba histolytica*	Order stool culture and stool for O&P
Secretory	Loss of isotonic fluid High-volume diarrhea Mechanisms: • Laxatives • Enterotoxins stimulate Cl- channels regulated by cAMP and cGMP • Serotonin increases bowel motility No inflammation in bowel mucosa	Laxatives: Danger of melanosis coli (black bowel syndrome) with use of phenanthracene laxatives Production of enterotoxins: • *Vibrio cholerae* • Enterotoxigenic *E. coli* Increased serotonin: carcinoid syndrome	Fecal smear for leukocytes: negative Increased 5-HIAA: carcinoid syndrome Stool osmotic gap <50 mOsm/kg
Osmotic	Osmotically active substance is drawing hypotonic salt solution out of bowel High-volume diarrhea No inflammation in bowel mucosa	Disaccharidase deficiency Stunned gut in giardiasis Ingestion of poorly absorbable solutes (e.g., magnesium sulfate laxatives)	Fecal smear for leukocytes: negative Stool osmotic gap >100 mOsm/kg

▼Table 14–6.0B Pathogens and Diarrhea

Pathogen	Discussion
Viruses	
Cytomegalovirus	Common cause of diarrhea in AIDS when CD4 T_H cell count <50–100 cells/mm^3
	Treatment: ganciclovir
Norwalk virus	Most common cause of adult gastroenteritis
	Nausea, vomiting, diarrhea that resolves in 12–24 hours
	Can occasionally be fatal
	Fecal-oral transmission
	Common infection on cruise ships
	Treatment: supportive
Rotavirus	Most common cause of childhood diarrhea; particularly occurs in winter months Fecal-oral transmission
	Damages ion transport pump in small intestine; secretory diarrhea
	Rotazyme test on stool establishes diagnosis
	Rotavirus vaccine highly effective in prevention; oral vaccine
	Treatment: oral hydration; nitazoxanide

Please visit us at www.Groupinsiders.com

© DeVry/Becker Educational Development Corp. All rights reserved.

▼ **Table 14–6.0B Pathogens and Diarrhea** *(continued)*

Pathogen	Discussion
Bacteria	
Bacillus cereus	Gram-positive rod
	Food poisoning with preformed toxin
	Associated with reheated fried rice or tacos
	Self-limited
Campylobacter jejuni	Curved or S-shaped gram-negative rod
	Animal reservoirs: cattle, chicken, puppies (common source for children)
	Fecal-oral transmission via contaminated water, poultry, or unpasteurized milk
	Most common food-borne illness and invasive enterocolitis in U.S.
	Invasive and secretory enterocolitis: dysentery (bloody diarrhea) with crypt abscesses and ulcers resembling ulcerative colitis; high fever and cramping abdominal pain; organisms in stool with blood and leukocytes
	Complications: Guillain-Barré syndrome (antibodies cross-react with neurons); hemolytic uremic syndrome; HLA-B27 positive seronegative spondyloarthropathy
	Treatment: azithromycin
Clostridium botulinum	Gram-positive rod
	Adult food poisoning with preformed toxin (blocks release of acetylcholine release in presynaptic terminal of neuromuscular junction in autonomic nervous system; causes descending paralysis, mydriasis, dry mouth
	Treatment: trivalent antitoxin
	Infant food poisoning often contracted by eating spores in honey (lack protective bacteria); floppy baby with constipation
Clostridium difficile	Gram-positive rod Associated with pseudomembranous colitis; the most common cause of nosocomial diarrhea; secretory type of diarrhea
	Normally present in 3% of people; carrier rate increases to >20% in hospitalized patients (related to contact with spores in environment and fecal-oral contamination)
	Antibiotic-induced in 65%-90% of cases; antibiotics (e.g., ampicillin, quinolones, clindamycin) cause overgrowth of toxin-producing *C. difficile* in colon; toxins A and B release proinflammatory mediators and cytokines that attract neutrophils and stimulate excess fluid secretion (watery diarrhea)
	Pseudomembrane covers colon mucosa; composed of cellular debris, leukocytes, fibrin, and mucin
	Person-to-person induced in 30% of cases
	Nonspecific lab findings: neutrophilic leukocytosis with left shift; fecal leukocytes; and decreased serum albumin
	Cytotoxin assay of stool has greater specificity (75%–100%) than culture of stool (75%–80%) for securing the diagnosis
	Treatment: metronidazole; vancomycin produces resistant strains

Please visit us at www.Groupinsiders.com

© DeVry/Becker Educational Development Corp. All rights reserved.

▼Table 14–6.0B Pathogens and Diarrhea *(continued)*

Pathogen	Discussion
Bacteria ***(continued)***	
Escherichia coli	Gram-negative rod
	ETEC: certain strains produce toxin that activate adenylate or guanylate cyclase, causing secretory diarrhea (traveler's diarrhea; accounts for 60% of cases); other causes include *Campylobacter, Salmonella, Shigella*
	Treatment: levofloxacin
	STEC (O157:H7 serotype): contracted by eating undercooked beef
	Produces hemolytic uremic syndrome (refer to chapter 14)
	Antibiotics *not* recommended; may enhance toxin release
Mycobacterium avium-intracellulare complex (MAC)	Acid-fast rods Causes diarrhea with malabsorption in AIDS (CD4 count <50 cells/mm^3)
	Foamy macrophages in lamina propria simulate Whipple disease
Mycobacterium tuberculosis	Acid-fast organisms swallowed from primary focus in lung
	Invade Peyer patches
	Circumferential spread in lymphatics leads to stricture formation
Salmonella species	Gram-negative rod
	Pathogenic *Salmonella: S. typhi, S. paratyphi, S. enteritidis*
	Animal reservoirs: turtles, hamsters, lizards
	Salmonella enteritidis enterocolitis: Second most common food-borne illness in U.S.; contracted by eating raw or undercooked egg products and poultry, raw milk and milk products, or drinking contaminated water
	Treatment: ciprofloxacin or levofloxacin
	Typhoid fever caused by *S. typhi*: Week 1: invades Peyer patches and produces sepsis (blood culture best for diagnosis) Week 2: diarrhea (positive stool culture); classic triad of bradycardia, neutropenia, splenomegaly
	Treatment: treat if symptomatic with fluoroquinolone; antibiotics do *not* shorten the illness and may increase frequency of carrier states
	Chronic carrier state due to gallbladder disease: cholecystectomy
Shigella dysenteriae and Shigella sonnei	Gram-negative rod
	No animal reservoirs
	Highly infectious; children in day care centers; mental institutions
	Mucosal ulceration, pseudomembranous inflammation in rectosigmoid, dysentery
	Association with HLA-B27 positive seronegative spondyloarthropathy
	Treatment: treat if symptomatic with fluoroquinolone or azithromycin

Please visit us at www.Groupinsiders.com

© DeVry/Becker Educational Development Corp. All rights reserved.

▼ **Table 14–6.0B Pathogens and Diarrhea** *(continued)*

Pathogen	Discussion
Bacteria ***(continued)***	
Staphylococcus aureus	Gram-positive coccus
	Food poisoning with preformed toxin; culture food, *not* stool
	Gastroenteritis occurs in 1–6 hours after eating
	Self-limited
Vibrio cholerae	Gram-negative comma-shaped rod
	Enterotoxin stimulates adenylate cyclase in small bowel
	Contracted from drinking contaminated water or eating contaminated seafood, especially crustacea
	Treatment: fluid replacement; glucose and sodium required in oral supplements (cotransport system for reabsorption); doxycycline or fluoroquinolone
Yersinia enterocolitica	Gram-negative coccobacillus with bipolar staining
	Enterocolitis in children; mesenteric lymphadenitis (granulomatous microabscesses) that simulates acute appendicitis
	Association with HLA-B27 positive seronegative spondyloarthropathy
	Treatment: TMP-SMX
Protozoa	
Balantidium coli	Protozoan (ciliate); largest protozoan Transmitted by ingestion of cysts in food or water
	Produces colonic ulcers with bloody diarrhea
	Treatment: tetracycline
Cryptosporidium parvum	Protozoan (sporozoa)
	Transmitted by ingestion of oocysts in food or water
	Responsible for outbreaks of diarrhea in water supply (e.g., Milwaukee, WI, 1993)
	Most common cause of diarrhea in AIDS
	Diagnosis: stool antigen test (sensitivity/specificity 98%); oocysts partially acid-fast
	Treatment: if immunocompromised, nitazoxanide (less responsive to drug if immunodeficient)
Cyclospora, Microsporidia, Isospora belli	Protozoa (sporozoa) Fecal-oral transmission
	All are common pathogens in AIDS diarrhea
	Cyclospora can contaminate raspberries
	Microsporidia spores are *not* partially acid-fast
	Cyclospora oocysts partially acid-fast
	Isospora oocysts partially acid-fast
	Treatment: *Cyclospora*—TMP-SMX double strength; *Microsporidia*—albendazole; *Isospora*—TMP-SMX double strength

Please visit us at www.Groupinsiders.com

© DeVry/Becker Educational Development Corp. All rights reserved.

▼Table 14–6.0B Pathogens and Diarrhea *(continued)*

Pathogen	Discussion
Protozoa ***(continued)***	
Entamoeba histolytica	Protozoa (amoeba)
	Transmitted by ingestion of cysts in food and water
	Cysts are nonmotile and are present in formed stool; trophozoites are motile and are present in diarrhea
	Produces dysentery (bloody diarrhea); cysts exist in the cecum and become trophozoites in the cecum; trophozoites release powerful histolytic agents that produce flask-shaped ulcers; trophozoites can penetrate portal vein tributaries and drain to the liver to produce a liver abscess ("anchovy paste" abscess); trophozoites can penetrate hepatic vein tributaries and produce systemic disease
	Trophozoites characteristically phagocytose red blood cells
	Diagnosis: stool antigen test (sensitivity/specificity 100%)
	Treatment: metronidazole
Giardia lamblia	Protozoa (flagellate) Most common protozoal cause of diarrhea in U.S.
	Transmitted by ingestion of cysts in food and water
	Common in day care centers, mental hospitals, among hikers, water supplies (chlorination does *not* kill the cysts), men who have sex with men (anal-oral contact), IgA deficiency, common variable immunodeficiency
	Produces acute and chronic diarrhea with malabsorption (cysts in formed stool; trophozoites in loose stools)
	Diagnosis: stool antigen test (sensitivity/specificity 100%)
	Treatment: tinidazole or nitazoxanide
Helminths	
Anisakis simplex	Intestinal nematode
	Transmission: eating raw fish dishes (i.e., sushi, sashimi); eating pickled herring
	Larvae penetrate gastric and intestinal mucosa
	Produce cramping abdominal pain; epigastric distress with nausea, vomiting, and diarrhea within a few hours after eating
	Diagnosis: endoscopy; IgE antibody test
	Treatment: removal by endoscope or surgery

Please visit us at www.Groupinsiders.com

© DeVry/Becker Educational Development Corp. All rights reserved.

▼ **Table 14–6.0B** Pathogens and Diarrhea *(continued)*

Pathogen	Discussion
Helminths *(continued)*	
Enterobius vermicularis	Intestinal nematode Most common helminth in the U.S.
	Transmission: ingestion of eggs
	Eggs deposited in anus by adult worms cause pruritus ani
	Other infections: urethritis in girls; acute appendicitis
	No eosinophilia because adult worms are *not* invasive
	Treatment: albendazole or mebendazole
Trichuris trichiura	Intestinal nematode (whipworm)
	Transmitted by ingestion of eggs
	Produces diarrhea; can produce rectal prolapse in children
	Diagnosis: stool for ova and parasites; eosinophilia
	Treatment: albendazole
Ascaris lumbricoides	Intestinal nematode
	Largest intestinal nematode
	Transmitted by ingestion of eggs
	Larval phase through lungs: cough, pneumonitis, eosinophilia (invasion of tissue)
	Bowel obstruction in adult phase; no eosinophilia (no invasion of tissue)
	Treatment: albendazole and mebendazole
Necator americanus	Intestinal nematode (hookworm)
	Adults attach to villi, resulting in blood loss and iron deficiency
	Treatment: albendazole or mebendazole
Strongyloides stercoralis	Intestinal nematode
	Transmission: filariform larvae in soil penetrate the feet → larval phase through the lungs → swallowed and molt into adults that enter the intestinal mucosa and lay eggs → eggs hatch into rhabditiform larvae, which enter the intestinal lumen and are passed in the stool → develop into filariform larvae (infective form) in the soil
	Autoinfection may occur if filariform larvae in the intestine penetrate the mucosa and migrate to the lungs to repeat the cycle
	In immunocompromised patients (e.g., AIDS), massive reinfection occurs with dissemination throughout the body
	Produces abdominal pain and diarrhea
	Treatment: ivermectin
Diphyllobothrium latum	Intestinal cestode (tapeworm)
	Transmission: ingest larvae in lake trout (Great Lakes)
	Produce diarrhea with or without vitamin B12 deficiency; preferential uptake of vitamin B12 by the worm
	Diagnosis: eggs in the stool
	Treatment: praziquantel

Please visit us at www.Groupinsiders.com

© DeVry/Becker Educational Development Corp. All rights reserved.

7 Malabsorption Syndromes

7.1 Malabsorption as a Result of Diarrhea

Malabsorption syndromes are primarily *defects in the absorption of fat in the small intestine.*

▼**Table 14–7.0** Malabsorption Syndromes

Pathophysiology	Causes
No lipase to breakdown TG into monoglycerides and FAs	Chronic pancreatitis: alcohol, cystic fibrosis
Cannot micellarize (1μ-sized packages); micelles contain monoglycerides, FAs, CH, fat soluble vitamins	↓ Bile salts/acids: cirrhosis, bile duct obstruction, bacterial overgrowth, cholestyramine, terminal ileal disease (no recycling)
Not enough surface area to reabsorb micelles	Absent/blunted villi: celiac disease
Cannot transport chylo-microns (resynthesized from monoglycerides + FA) into lymphatics	Lymphatic obstruction in small bowel: Whipple disease (uncommon in U.S.)

	Celiac Disease	Whipple Disease
Etiology	Autoimmune-IgG/A antibodies against anti-gliadin, transglutaminase, endomysium antibodies	*Tropheryma whippelii* bacterium
Epidemiology	Mostly females; presents in infancy	Mostly males; 30–50 years old
Morphology	Blunting of intestinal villi in duodenum and jejunum	
Clinical Findings	Malabsorption, dermatitis herpetiformis, MALT lymphoma	Malabsorption, polyarthritis, lymphadenopathy, fever, increased skin pigmentation

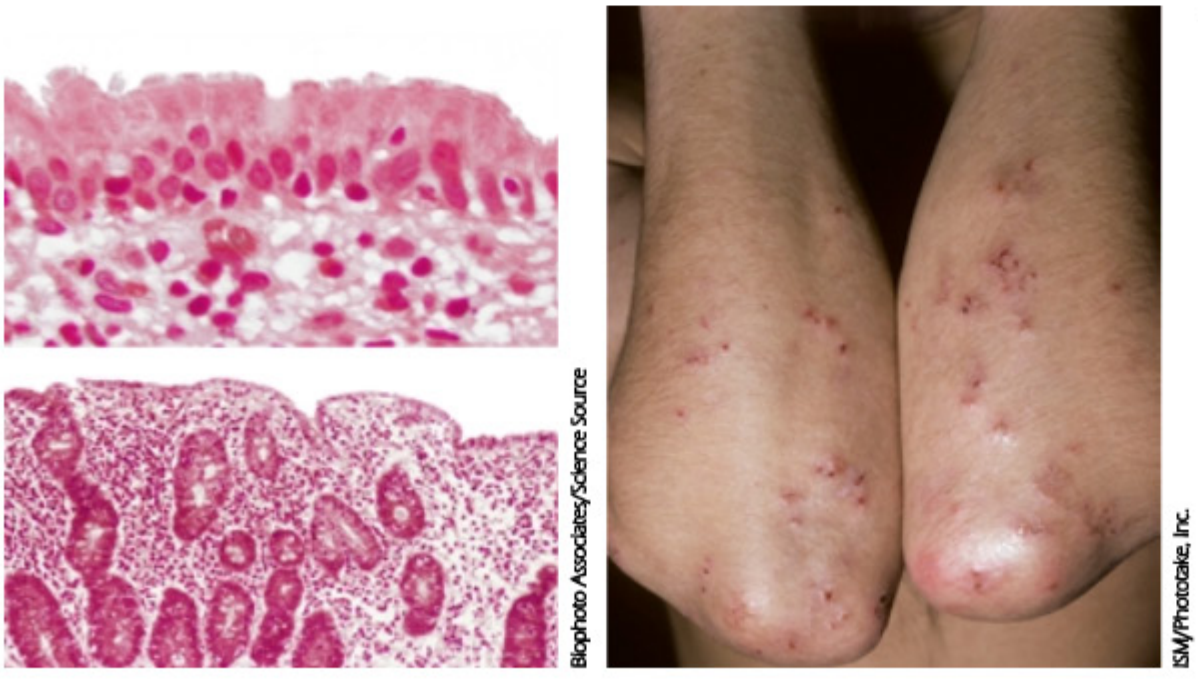
Biophoto Associates/Science Source
ISM/Phototake, Inc.

▲**Figure 14–7.0** Celiac Disease

Please visit us at www.Groupinsiders.com

© DeVry/Becker Educational Development Corp. All rights reserved.

8 Appendicitis

Etiology/Pathogenesis

- **Children:** Viruses such as measles, adenovirus-associated lymphoid hyperplasia
- **Adults:** Obstruction by fecalith (also seen in sigmoid diverticulosis) leading to mucosal injury and bacterial invasion

Clinical Findings

- Initial irritation of C fibers causes referral pain to the midline in the periumbilical region, which then shifts to the RLQ due to Aδ-fibers on parietal peritoneum causing localized peritonitis at the exact region of inflammation.
- *RUQ in late-term pregnant women*

Complications—perforation, periappendiceal abscess, peritonitis

Please visit us at www.Groupinsiders.com

© DeVry/Becker Educational Development Corp. All rights reserved.

9 Inflammatory Bowel Disease

▼ **Table 14–9.0** Ulcerative Colitis vs. Crohn Disease

Ulcerative Colitis	Crohn Disease
Mucosal and submucosal	Transmural involving the serosa to mucosa
Begins in rectum and has continuous proximal extension to ileocecal valve; called pancolitis	Discontinuous spread. Terminal ileum alone (30%); ileum plus colon (50%); colon alone (20%). May involve anus (fistulas).
Ulceration leaving inflamed mucosa (called pseudopolyps); crypt abscesses	Non-caseating granulomas (60%); strictures, fistulas
Recurrent LLQ abdominal cramping with bloody diarrhea and mucus	Recurrent RLQ colicky pain usually with diarrhea
Association with PSC and HLA-B27 plus arthritis	Less association with PSC than UC; HLA-B27 plus arthritis
Toxic megacolon Colon cancer > Crohn disease	Colon cancer, fistulas, small bowel obstruction. Terminal ileum disease: malabsorption syndrome with bile salt/ acid, vitamin B12.

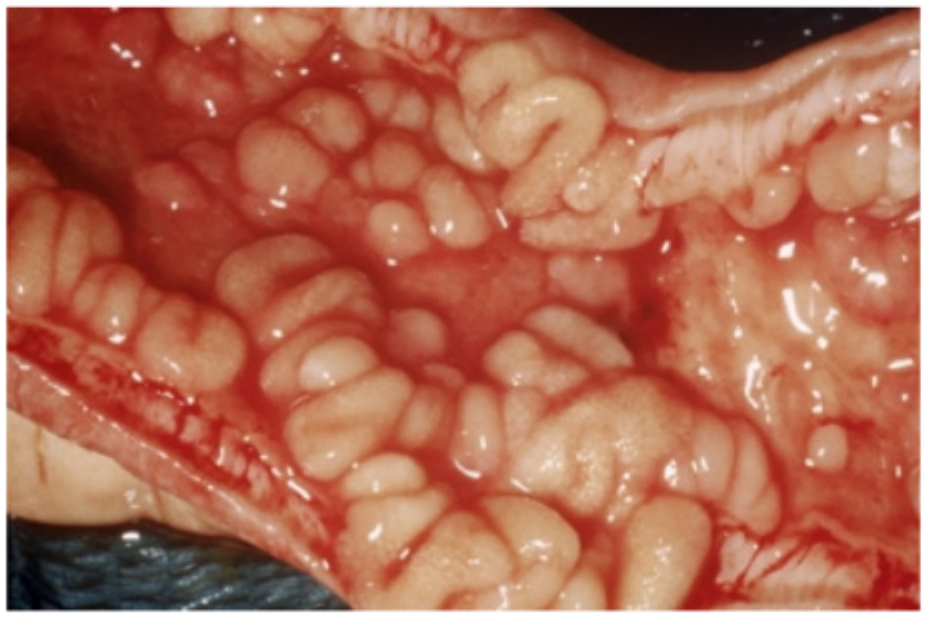

Biophoto Associates/Science Source

▲ **Figure 14-9.0** Crohn Disease

Looking Back

See chapter 12 "Pulmonary Pathology," topic 6.3.

Please visit us at www.Groupinsiders.com

© DeVry/Becker Educational Development Corp. All rights reserved.

10 Hemorrhoids—Two Types

General Pathogenesis

- All of these etiologies increase rectal venous blood pressure:
  - Straining physically occludes venous outlets.
  - Pregnancy is associated with increased venous volume.
  - Portal hypertension increases visceral venous pressures and causes increased flow to collateral sites (for example, rectal veins).
  - Increased pressure causes dilation of rectal veins.

10.1 Internal Hemorrhoids

- Dilated superior hemorrhoidal veins located above the pectinate line with *painless* bloody stools; anal pruritis from soiling.
- Commonly results in prolapse out of the rectum.
- This is an important differential with reference to pathogens that cause diarrhea, particularly the helminth *Enterobius vermicularis*.

Dr. Hercules Robinsory/Phototake, Inc.

▲ **Figure 14–10.1** Hemorrhoids

10.2 External Hemorrhoids

Dilated inferior hemorrhoidal veins located below the pectinate line associated with pain as a result of thrombosis.

Please visit us at www.Groupinsiders.com

© DeVry/Becker Educational Development Corp. All rights reserved.

11 Small and Large Bowel Polyps

Sigmoid colon is the most common site for gastrointestinal polyps, diverticula, and cancer.

11.1 Non-neoplastic (Hamartomatous) Polyps

- Hyperplastic polyp is the most common type found in adults.
- No malignant potential.
- Histologically have a "sawtooth" appearance.
- **Juvenile (retention) polyps** are the most common type with no malignant potential found in children; usually located in the rectum, which may prolapse and bleed.
  - Different from prolapse of the rectum; found in internal hemorrhoids.
- **Peutz-Jeghers Polyposis**
  - Autosomal dominant condition
  - *Hamartomatous* polyps predominant in the small bowel
  - **Clinical Findings**
    - —Buccal mucosal pigmentation (see Figure 14–2.2B).
    - —There is an increased association with colorectal, breast, and gynecological cancers; important in that these are *hamartomatous* polyps with malignant potential.

11.2 Neoplastic Polyps

- Tubular adenoma (adenomatous polyps) are the most common neoplastic type
  - Stalked (pedunculated) polyp
- Villous adenoma have no stalk (sessile) with secretory components

Clinical Findings

- Hypoalbuminemia and hypokalemia
- Malignant transformation risk increases with:
  - Villous component
  - >2 cm diameter has 40% potential
  - Multiple polyps
- Familial polyposis (see topic 12.1)

ISM/Phototake, Inc.

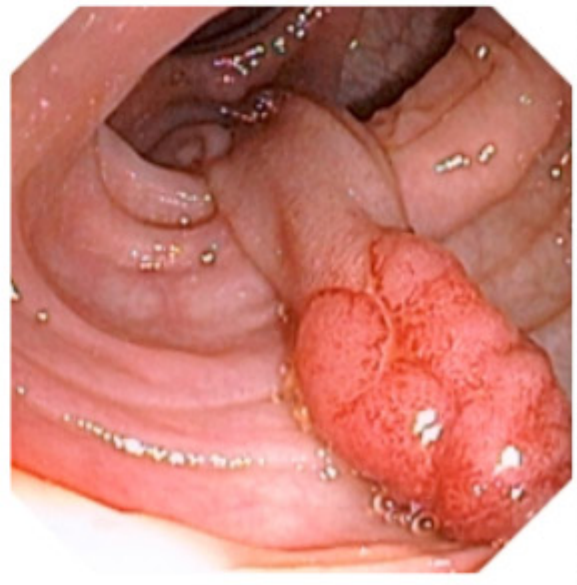

David M. Martin, MD/Science Source/Custom Medical Stock Photo

▶ **Figure 14–11.2**
Examples of Neoplastic Polyps

Please visit us at www.Groupinsiders.com

© DeVry/Becker Educational Development Corp. All rights reserved.

12 Intestinal Neoplasia

12.1 Adenocarcinoma

- Colorectal adenocarcinoma is the *third most common* cancer in incidence and mortality in men and women.
- Location (in order of frequency): rectosigmoid (50%), ascending colon, descending colon, transverse colon, cecum, small bowel.
- Right-sided colon cancers on the rise, which is why sigmoidoscopy alone isn't enough *anymore*.
- Risk factors
  - Older than 50 years of age
  - Low-fiber, high-fat diet
  - Cigarette smoking
  - Ulcerative colitis
- **Etiology-Genetics**
  - *Family history* is an important risk factor for colon cancer.
- **Genetic Syndromes**
  - **Familial Adenomatous Polyposis (FAP)**
    —*Autosomal dominant mutation in APC gene (5q21).*
    —Develop thousands of adenomatous polyps at an early age.
    —100% chance of invasive cancer by age 40.
    —*Gardner syndrome*—colon polyposis *plus* benign tumors, such as osteomas, fibromas, epidermal inclusion cysts.
    —*Turcot syndrome*—colon polyposis *plus* CNS tumors (gliomas).
  - **Hereditary Non-polyposis Colon Cancer (HNPCC)**
    —Also known as Lynch syndrome
    —Autosomal dominant defects in DNA repair genes
    —Increased risk of colon cancer, endometrial cancer, and ovarian cancer at a young age.
- **Peutz-Jeghers Syndrome** (see topic 11.1)
- **Molecular Pathogenesis**—sequential mutation of *APC, K-ras, DCC, and TP53*
- **Precursor Lesion**—adenoma. Overgrowth of dysplastic epithelium in one of three morphologies:
  - Tubular adenoma (60%)—pedunculated stalk
  - Villous adenoma—large, sessile
  - Tubulovillous—combination of the two morphologies
    —Metastasis occurs when tumor grows into lymph and blood vessels
  - Lymphatic spread to local and regional lymph nodes.
  - Hematogenous spread to distant sites (in order of frequency): liver, lungs, bone, brain.
    —**Prognosis**—dependent on stage
  - The deeper the invasion, the worse the prognosis.

Please visit us at www.Groupinsiders.com

© DeVry/Becker Educational Development Corp. All rights reserved.

Duke Classifications

▼ **Table 14–12.1A** Duke Classifications

Stage	Degree of Invasion
A/0	Mucosa and submucosa
B1/I	Into muscularis propria
B2-C1/II	Involves muscularis propria; + lymph nodes
C2/III	Through muscularis propria; + lymph nodes
D/IV	Distant metastasis

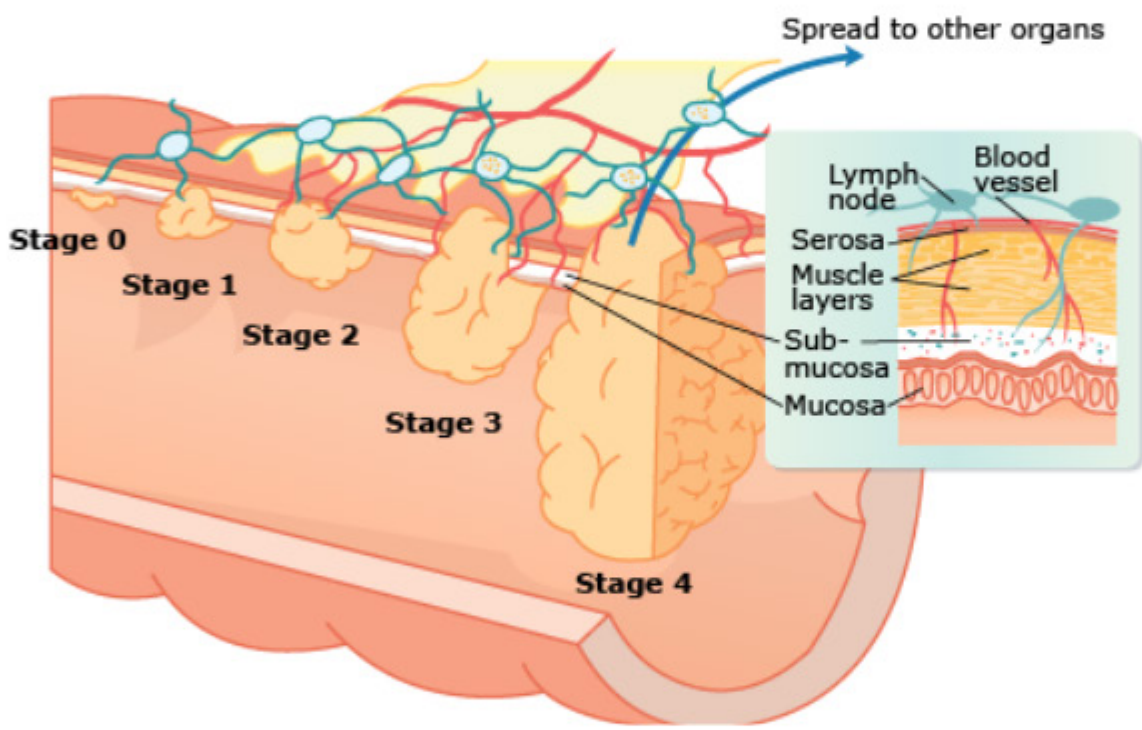

▲ **Figure 14–12.1A** Duke Stages

Please visit us at www.Groupinsiders.com

© DeVry/Becker Educational Development Corp. All rights reserved.

▼ **Table 14–12.1B** Right-Sided Colorectal Cancer vs. Left-Sided Colorectal Cancer

	Right-Sided Colorectal Cancer	Left-Sided Colorectal Cancer
Gross appearance	Polypoid mass	Circumferential mass Bright red blood coating of stool
Radiographic appearance (barium enema)	Polypoid mass	"Apple core" lesion
Presentation	Bleeding—occult blood, frank melena, iron deficiency anemia	Change in bowel habits—constipation, diarrhea, decreased caliber

Bolkershot Photo/Science Source

▲ **Figure 14–12.1B** Colorectal Cancer

Please visit us at www.Groupinsiders.com

© DeVry/Becker Educational Development Corp. All rights reserved.

12.2 Carcinoid Tumor (CT) and Carcinoid Syndrome

12.2.1 Carcinoid Tumor

A neuroendocrine tumor with neurosecretory granules found in the appendix most commonly and terminal ileum as the second most common site.

12.2.2 Carcinoid Syndrome

CT in the terminal ileum is the most common site of *liver metastasis*, where it secretes serotonin into the post-hepatic circulation:

- Cutaneous flushing
- Diarrhea
- Bronchospasm, wheezing
- Tricuspid regurgitation and pulmonic stenosis

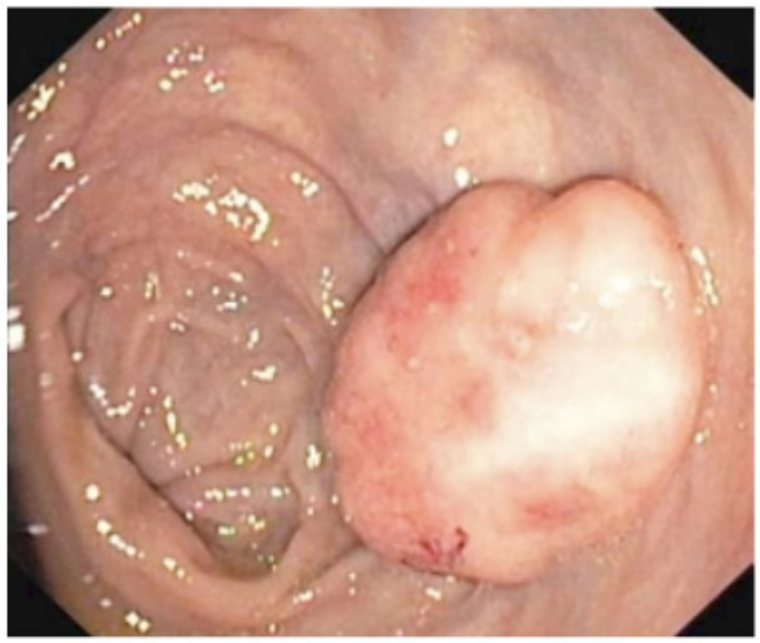

Gastrolab/Science Source

▲ **Figure 14–12.2** Carcinoid Tumors

Please visit us at www.Groupinsiders.com

© DeVry/Becker Educational Development Corp. All rights reserved.

Unit 7

Hepatobiliary Pathology/ Pancreas

Please visit us at www.Groupinsiders.com

Please visit us at www.Groupinsiders.com

1 Hepatic and Biliary Pathology

- Cirrhosis
- Cholestatic diseases
- Hepatic inflammatory diseases
- Hepatic vascular diseases
- Hepatic neoplasms

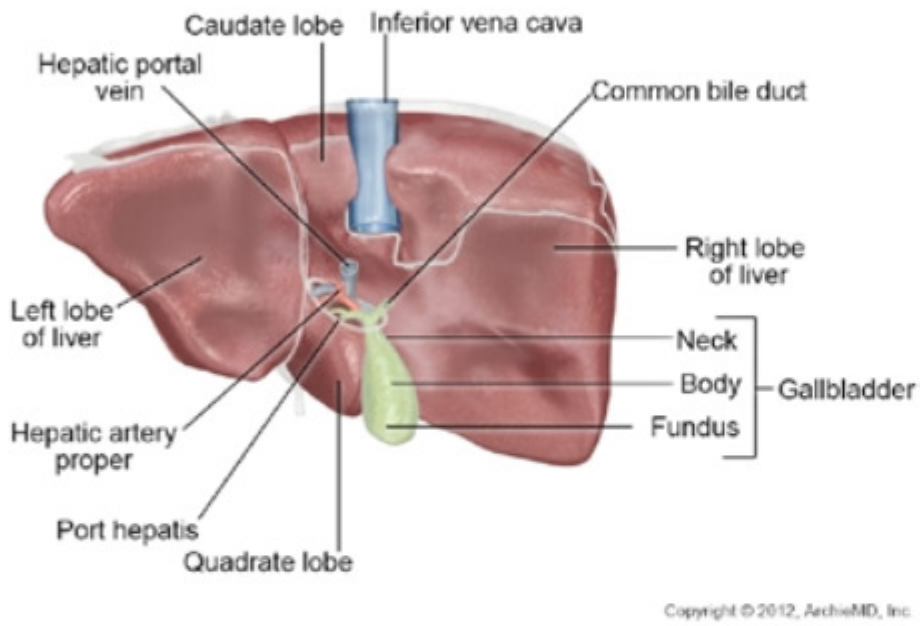

▲ **Figure 15–1.0A** The Liver

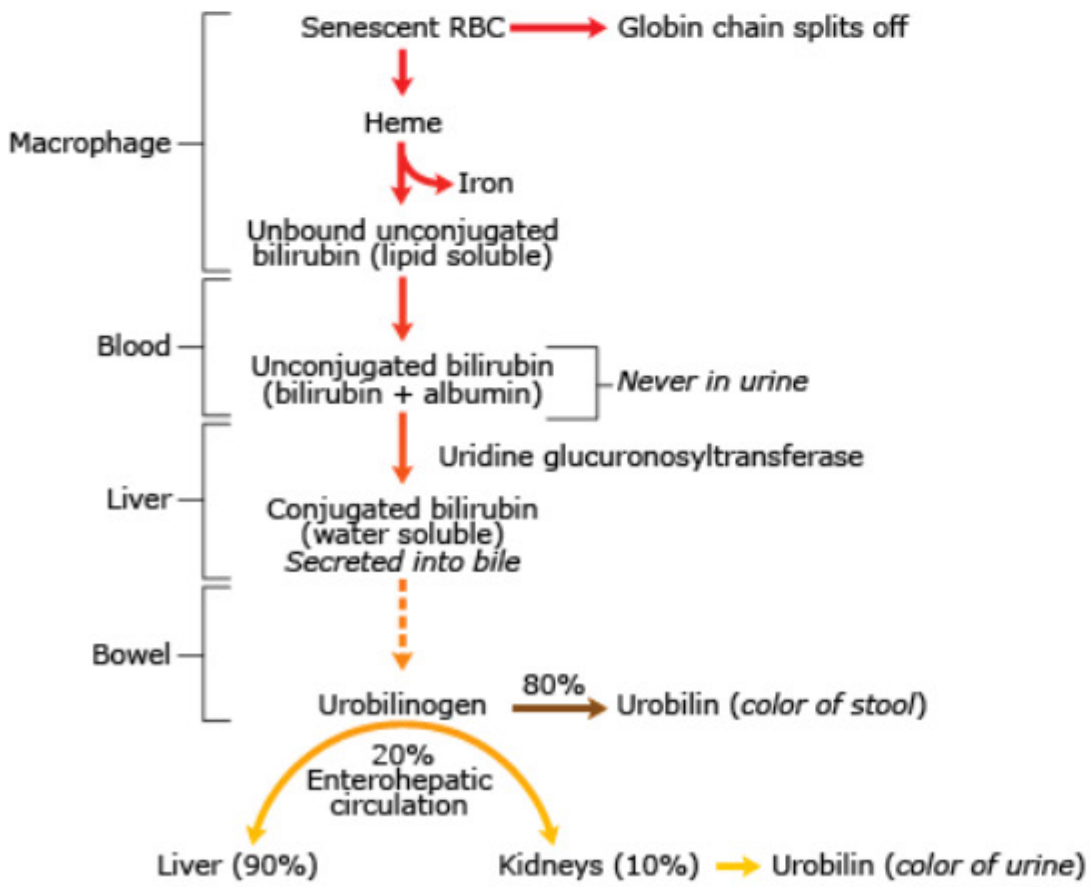

◀ **Figure 15–1.0B** Bilirubin Metabolism

USMLE® Key Concepts

For Step 1, you must be able to:

- Identify various types of histocytoses.
- Explain the difference between benign and chronic lymphadenopathy.
- Differentiate between Hodgkin and Non-Hodgkin lymphomas.
- Describe the various types of plasma cell neoplasms.

Please visit us at www.Groupinsiders.com

© DeVry/Becker Educational Development Corp. All rights reserved.

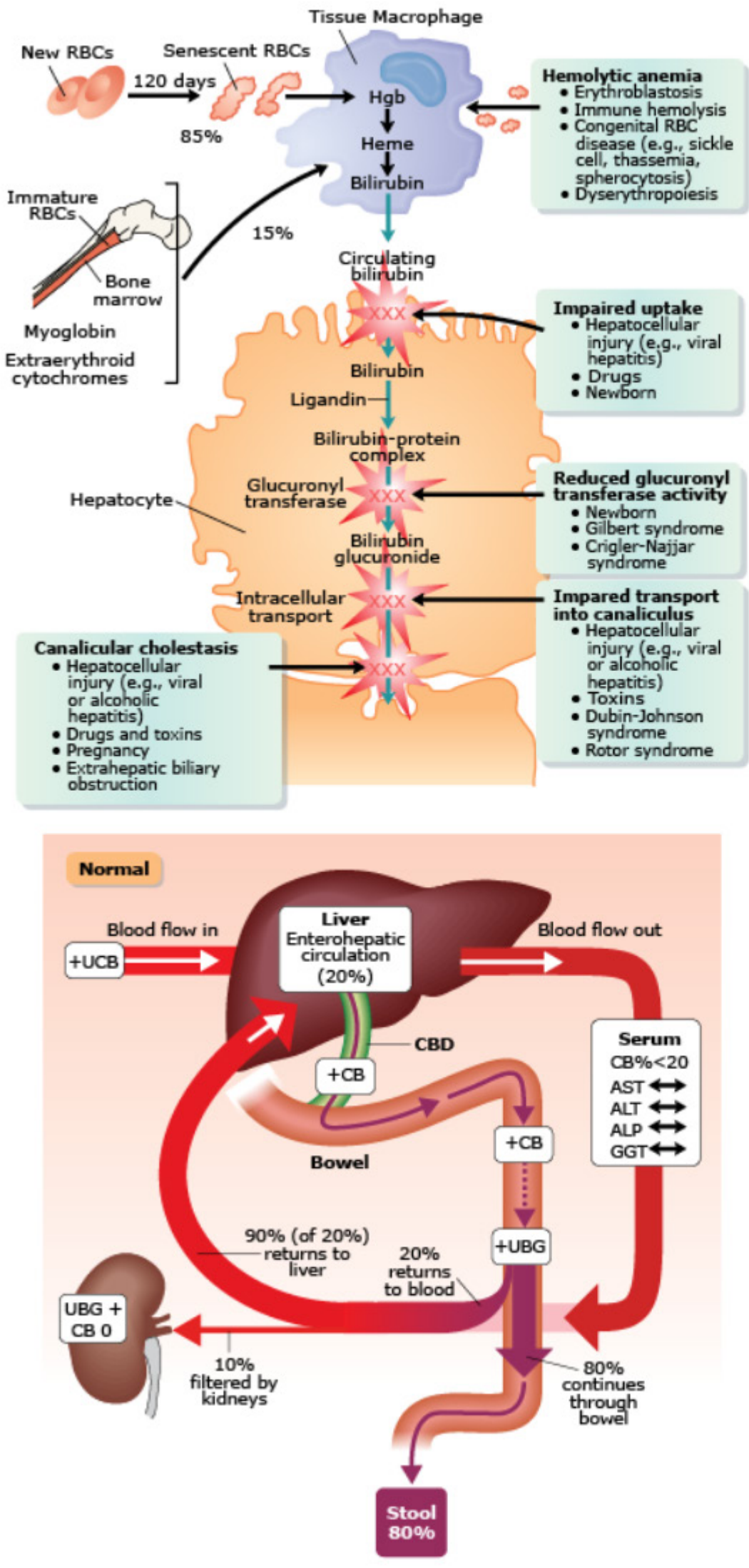

▲ **Figure 15–1.0C** Hepatic Handling of Bilirubin

Please visit us at www.Groupinsiders.com

© DeVry/Becker Educational Development Corp. All rights reserved.

1.1 Jaundice

Jaundice is identified by the conjugated bilirubin percentage shown in laboratory findings: *conjugated (CB) bilirubin percentage (%) = CB/ Total bilirubin (TB)*. Three types of jaundice high-yield for Step 1 are:

1. CB <20%
2. CB 20% to 50
3. CB >50%

1.1.1 CB <20%

- Interpretation: Unconjugated *Hyper*bilirubinemia *(UCB)*
- Differentials: Gilbert, ABO/Rh Hemolytic Disease of the Newborn

1.1.2 CB 20% to 50%

- Interpretation: *Mixed jaundice* of UCB and CB
- Differential: Hepatitis, hepatocellular carcinoma (HCC)

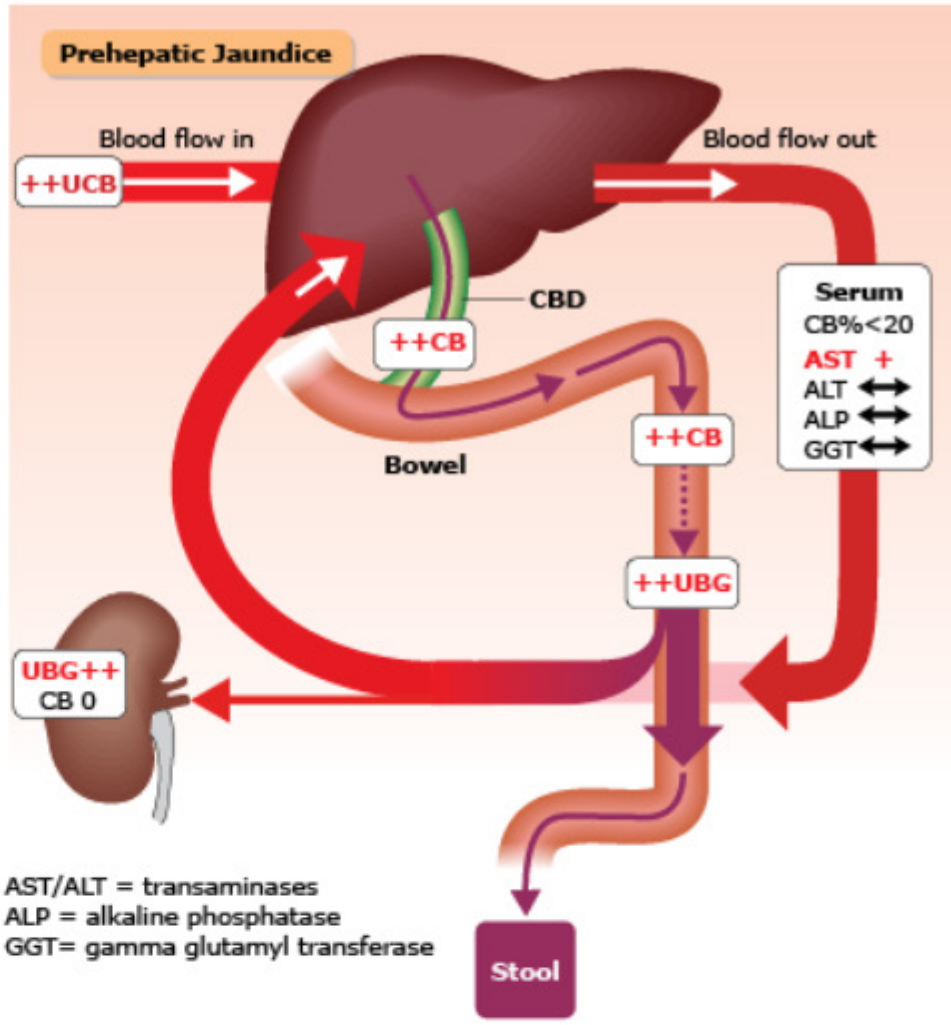

▲ **Figure 15–1.1A** Prehepatic Jaundice

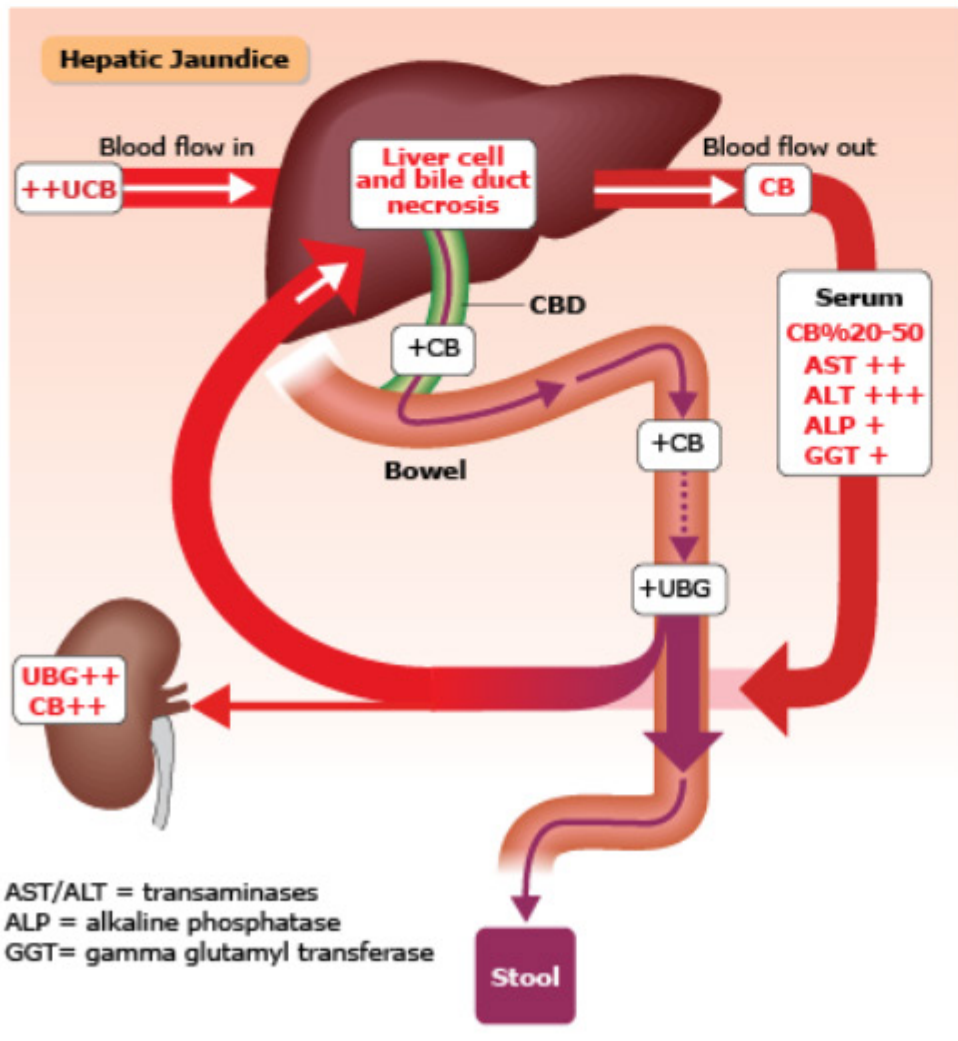

▲ **Figure 15–1.1B** Hepatic Jaundice

Please visit us at www.Groupinsiders.com

© DeVry/Becker Educational Development Corp. All rights reserved.

1.1.3 CB >50%

- Interpretation: Conjugated *hyper*bilirubinemia (*CB*)
- Differential: Bile duct obstruction (intrahepatic/extrahepatic)

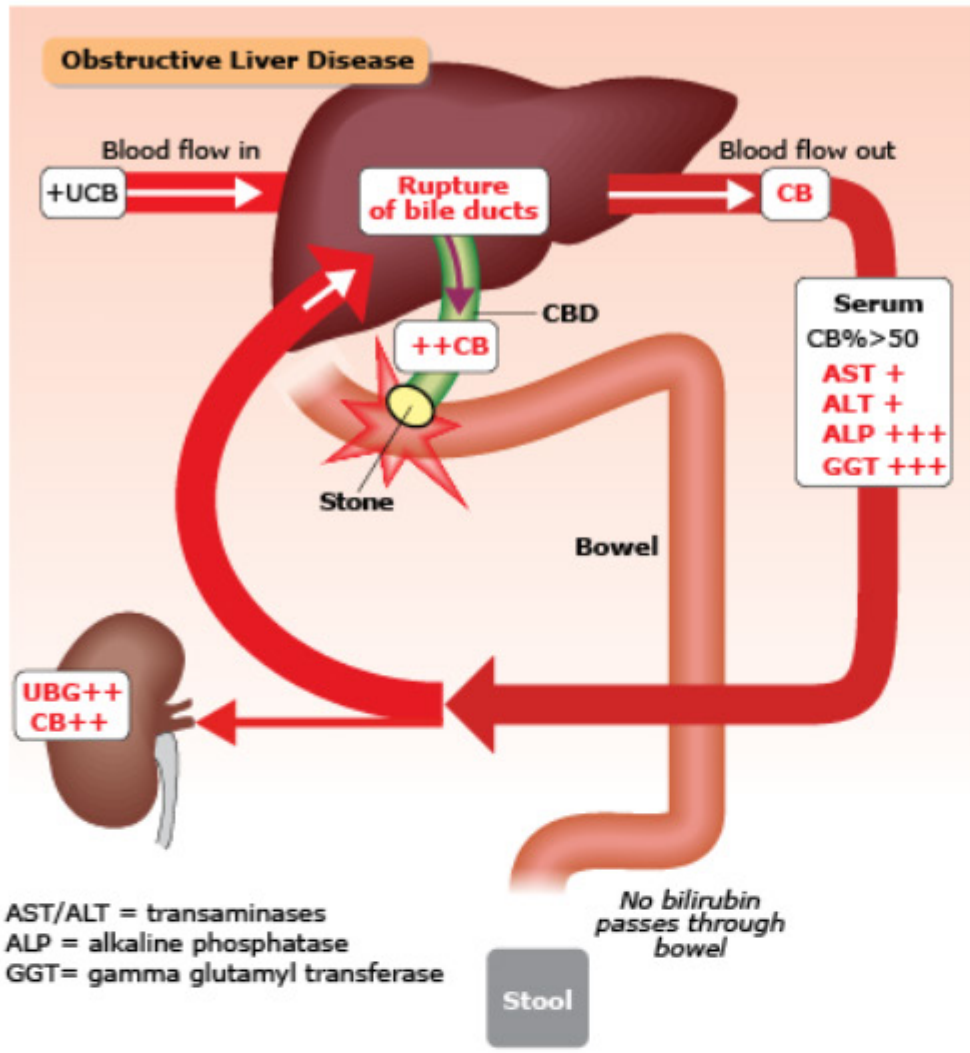

▲ **Figure 15–1.1C** Obstructive Liver Disease

▼ **Table 15–1.1** Liver Function Tests (LFTs)

Liver Function Tests (LFTs)	
Necrosis	Viral hepatitis ALT > AST Alcoholic hepatitis AST > ALT (ratio is 2:1)
Cholestasis	Serum ALP, GGT
Hepatocyte function	Serum albumin Prothrombin time (PT)
Immune function	Serum IgM (Primary Biliary Cirrhosis or PBC) Anti-mitochondrial antibody (PBC)
Tumor marker	α-Fetoprotein (AFP)
Bilirubin	Previous discussion

Please visit us at www.Groupinsiders.com

© DeVry/Becker Educational Development Corp. All rights reserved.

2 Cirrhosis

Cirrhosis is end-stage liver disease characterized by disruption of the normal hepatic architecture by fibrosis.

Etiology Cirrhosis is the endpoint of most chronic liver diseases.

- Cholestasis
- Chronic inflammatory diseases (hepatitis)
- Chronic hepatic vascular disease

Pathogenesis Fibrosis is stimulated by:

- Inflammation—cytokines signal collagen deposition
- Wound healing—fibrosis is part of the regenerative process after hepatocellular damage
- Direct stimulators of fibrosis, for example, HBV, carbon tetrachloride, etc.

2.1 Sequelae of Cirrhosis

2.1.1 Portal Hypertension

Tissue destruction causes loss of hepatic vascular volume, increasing pressure in the portal vein, resulting in:

- Increased congestion at portocaval anastomoses results in the following manifestations:
  - *Esophageal varices*
  - *Hemorrhoids*
  - *Caput medusae*
- *Splenomegaly* and *hypersplenism* with pancytopenia

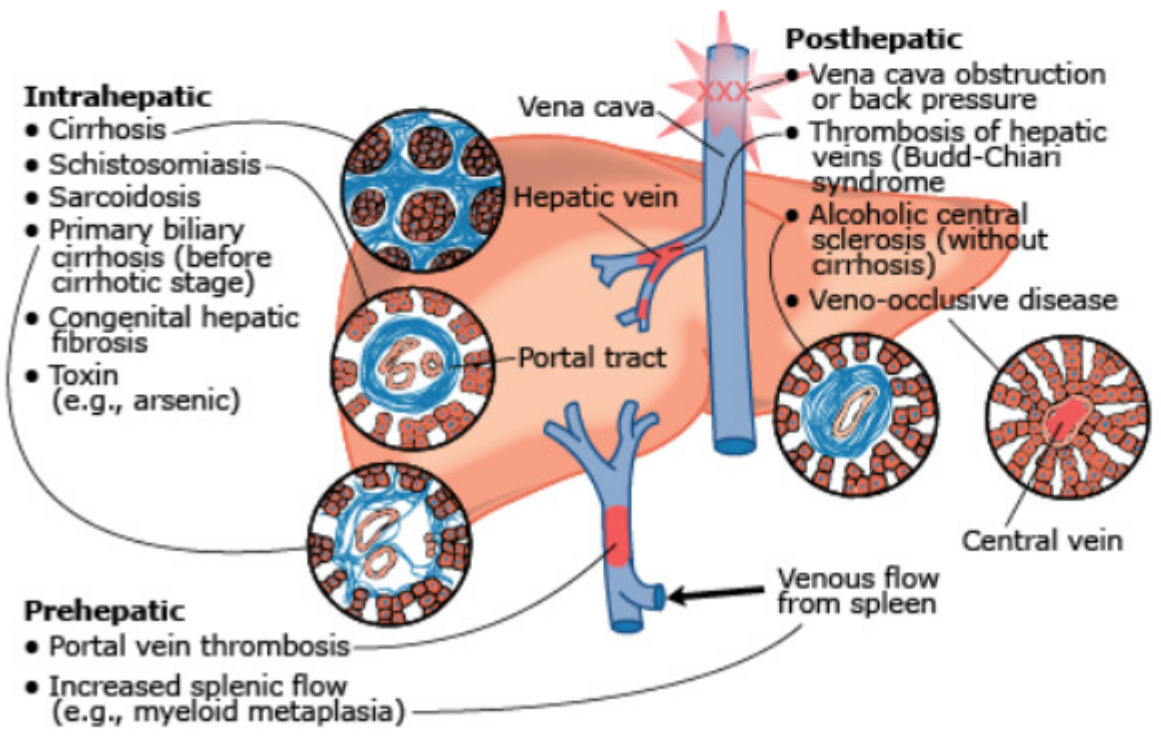

▲ **Figure 15–2.1A** Portal Hypertension

Please visit us at www.Groupinsiders.com

© DeVry/Becker Educational Development Corp. All rights reserved.

2.1.2 Decreased Detoxification

The liver is a primary site of detoxification.

- *Jaundice*—caused by decreased clearance of bilirubin.
- *Hepatic encephalopathy*—thought to be due to increased serum ammonia, which is normally eliminated by the urea cycle in the liver.
- *Estrogen excess*—decreased estrogen catabolism and increased peripheral aromatization of androgens, which are increased as well; causes spider angioma, palmar erythema, testicular atrophy, and gynecomastia.

2.1.3 Decreased Synthesis

Loss of hepatic tissue results in decreased synthesis of liver products.

- *Hypoalbuminemia*—results in decreased plasma oncotic pressure, causing peripheral edema.
- Decreased clotting factors *(all except factor VIII)* result in an increased tendency to bleed.
- Fasting hypoglycemia due to decreased gluconeogenesis.
- Hypocalcemia

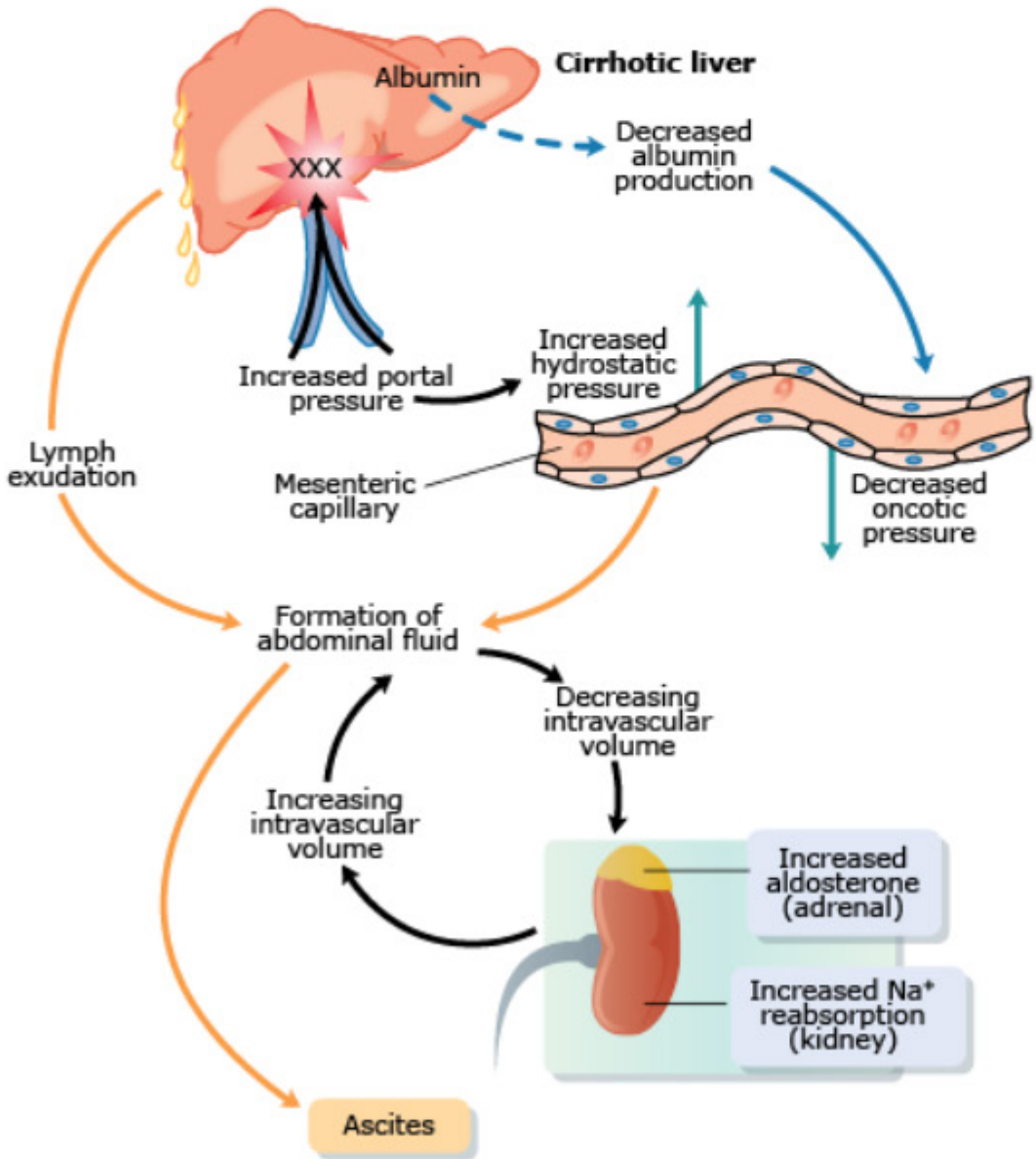

▲ **Figure 15–2.1B** Ascites

Please visit us at www.Groupinsiders.com

© DeVry/Becker Educational Development Corp. All rights reserved.

2.2 Micronodular Cirrhosis (Laennec Cirrhosis)

- Considered to be an *acute manifestation*
- <3 mm in diameter
- No landmarks of lobular architecture in the form of portal tracts or central vein
- Connective tissue is thin
- Alcoholic cirrhosis is the prototype
- Other causes: α1-AT deficiency, hemochromatosis, Wilson disease

2.3 Macronodular Cirrhosis (Chronic Hepatitis)

- Submassive confluent necrosis in which the liver is grossly misshapen.
- Connective tissues are characteristically broad and contain elements of portal tracts, mononuclear inflammatory cells, and proliferated ductules.
- Micronodular may be converted into a macro pattern by continued regeneration and expansion of existing nodules.
  - For example, it is true in alcoholics who are persuaded to abstain from drinking.
- Causes include postinfectious-HBV, HCV, and drug-induced.

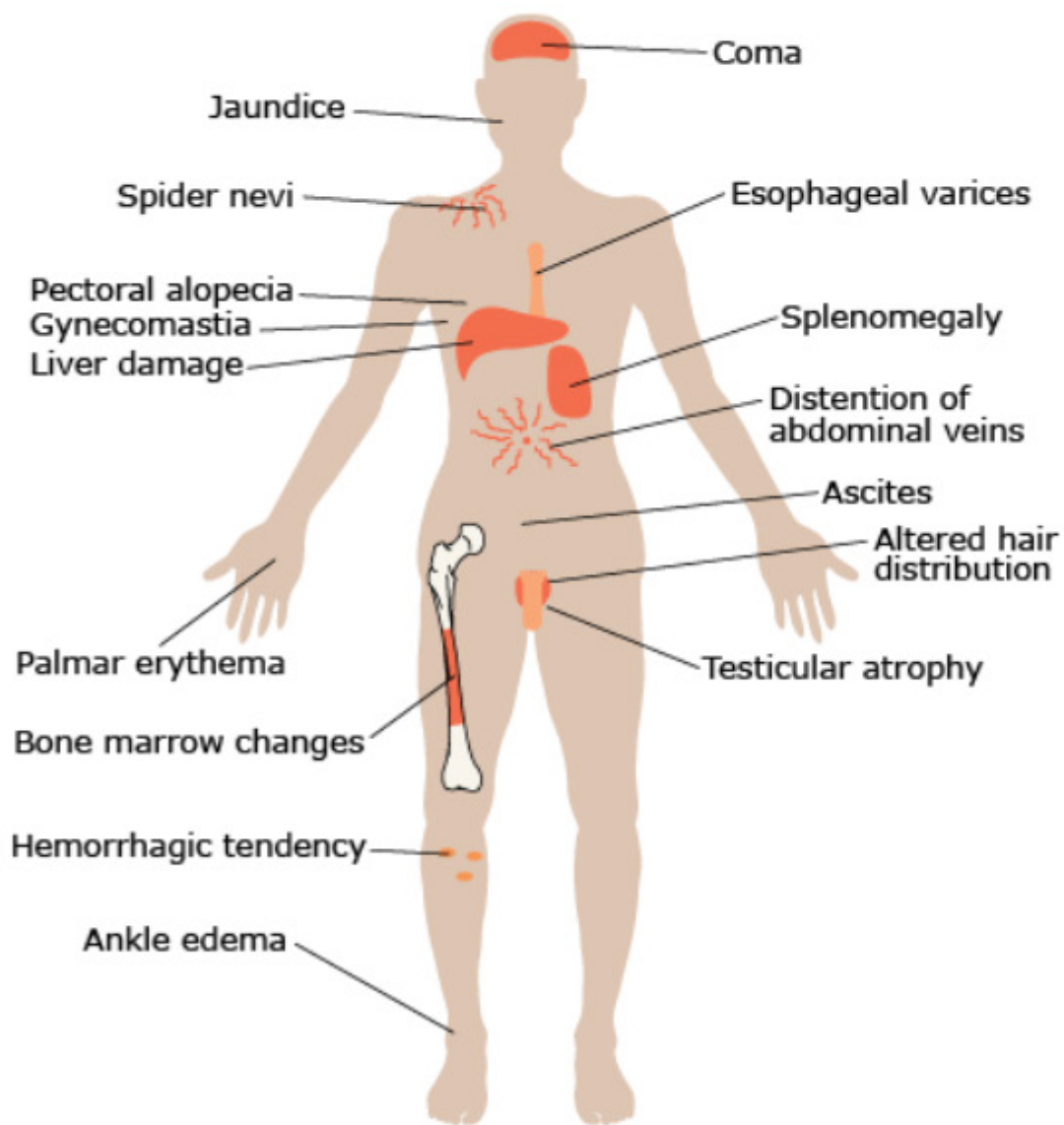

▲ **Figure 15–2.3A** Manifestations of Cirrhosis

Please visit us at www.Groupinsiders.com

© DeVry/Becker Educational Development Corp. All rights reserved.

Clinical Pathology

- Laboratory testing
- LFTs show elevated asparate aminotransferase (*AST*) and alanine aminotransferase (*ALT*)
- *AST:ALT ratio >2 indicates alcoholic hepatitis*
- Alkaline phosphatase (*ALP*) and gamma glutamyltransferase (*γGT*) are elevated in cholestasis; γGT is also elevated in alcoholic hepatitis
- Increased *direct (conjugated)* bilirubin indicates *defective excretion*
- Increased *indirect (unconjugated)* bilirubin indicates *defective conjugation*

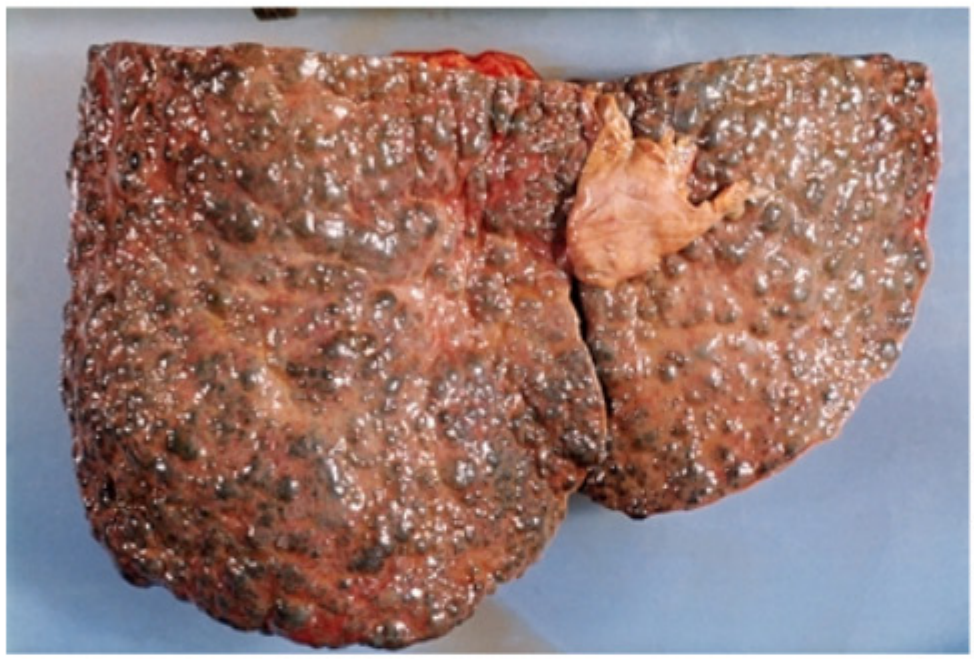

Biophoto Associates/Science Source

▲ **Figure 15–2.3B** Cirrhosis

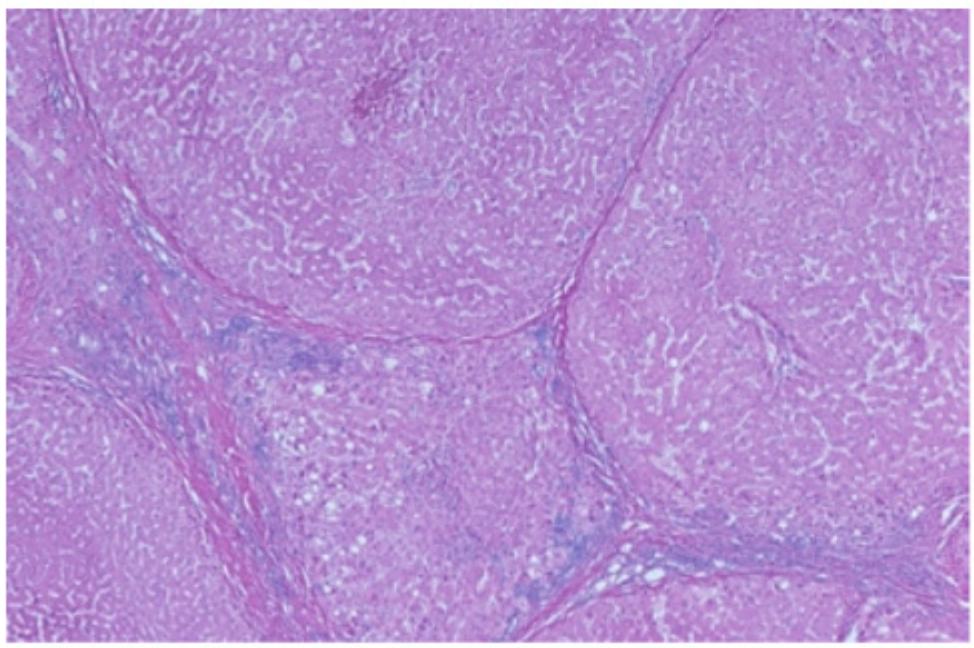

Carolina Biological Supply Co/Visuals Unlimited, Inc.

▲ **Figure 15–2.3C** Histology of Cirrhosis

Please visit us at www.Groupinsiders.com

© DeVry/Becker Educational Development Corp. All rights reserved.

3 Cholestatic Diseases

Cholestasis is obstruction of intra- or extrahepatic bile ducts, causing accumulation of bilirubin in the liver.

Etiology

- *Intrahepatic* cholestasis—blockage of intrahepatic bile ducts:
  - Drugs, *such as* oral contraceptives
  - Pregnancy, estrogen inhibition of bile secretion, benign
  - Primary biliary cirrhosis
- *Extrahepatic* cholestasis—blockage of common bile duct:
  - Extrahepatic biliary atresia
  - Primary sclerosing cholangitis (PSC)
  - Bile duct or head of the pancreas tumor
  - Choledocholithiasis

3.1 Intrahepatic Cholestatic Disease

3.1.1 Primary Biliary Cirrhosis

- Autoimmune disorder characterized by *antimitochondrial antibodies (AMAs).*
- Causes granulomatous destruction of intrahepatic bile ducts and portal hypertension. Figure 15–2.1A shows portal hypertension.
- Progresses from chronic inflammation to frank cirrhosis late in the disease course.
- Most common in *middle-aged women.*

3.2 Extrahepatic Cholestatic Diseases

3.2.1 Biliary Atresia

- Inflammatory destruction of extrahepatic bile ducts in newborns.
- Causes severe neonatal jaundice and liver failure.
- Leading cause of liver transplant in children.

3.2.2 Primary Sclerosing Cholangitis

- Obliterative fibrosis of intra- and extrahepatic bile ducts
- Causes cholestasis and leads to cirrhosis
- Most common in *young men*
- Associated with *ulcerative colitis* and increases risk of *cholangiocarcinoma*
- p-ANCA is frequently positive

Clinical Pathology

- Jaundice with pruritus
- Malabsorption syndrome
- Skin xanthomas
- Light-colored, chalky stools (decreased excretion of bilirubin metabolites)

Please visit us at www.Groupinsiders.com

© DeVry/Becker Educational Development Corp. All rights reserved.

Laboratory Findings

- Predominantly *conjugated (direct) hyperbilirubinemia*. Figure 15–1.1C shows obstructive liver disease.
- *Increased alkaline phosphatase*

Morphology

- Cholangiogram shows "beading" of extrahepatic bile ducts due to irregular strictures and resulting dilations.
- Histological findings show "onion skin" fibrosis.

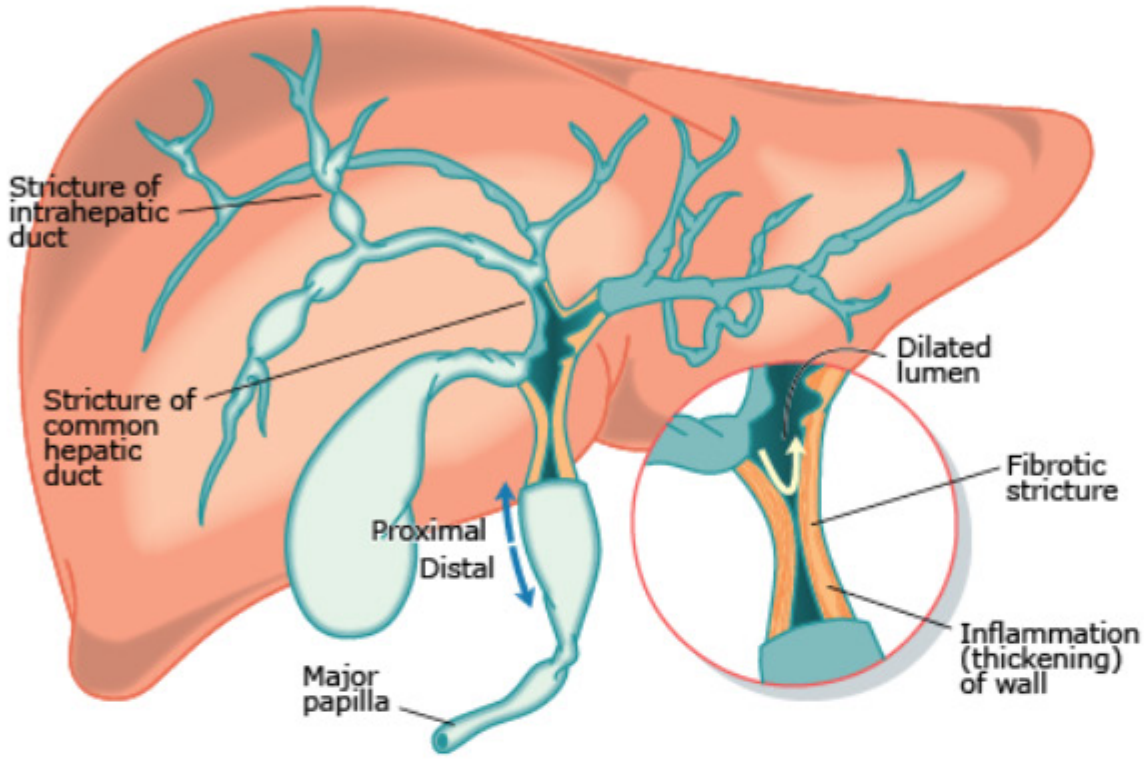

▲ **Figure 15–3.3A** Extrahepatic Cholestatic Diseases/ Primary Sclerosing Cholangitis

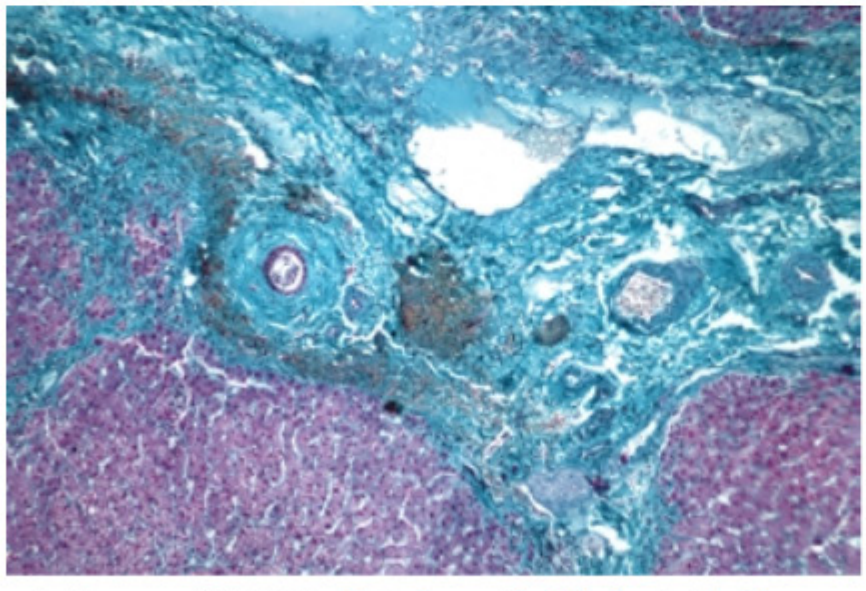

ISM/Phototake, Inc.

▲ **Figure 15–3.3B** Extrahepatic Cholestatic Diseases

Please visit us at www.Groupinsiders.com

© DeVry/Becker Educational Development Corp. All rights reserved.

3.4 Cholestatic Diseases—Hereditary Hyperbilirubinemias

See Figure 15–1.0B Bilirubin Metabolism

3.4.1 Defects in Bilirubin Conjugation

- Mutations in bilirubin uridine glucuronosyltransferase (UGT)
- Cause *unconjugated (indirect) hyperbilirubinemia*
- **Gilbert syndrome**—benign disorder with episodic jaundice under conditions of stress (fasting, illness, etc.)
- **Crigler-Najjar syndrome**—type I is a more severe, defect-causing fatal kernicterus

3.4.2 Defects in Bilirubin Transport

- Cause *conjugated (direct) hyperbilirubinemia*
- Dubin-Johnson syndrome—causes black pigmentation of the liver, but otherwise clinically benign
- *Rotor syndrome*—clinically benign without liver pigmentation

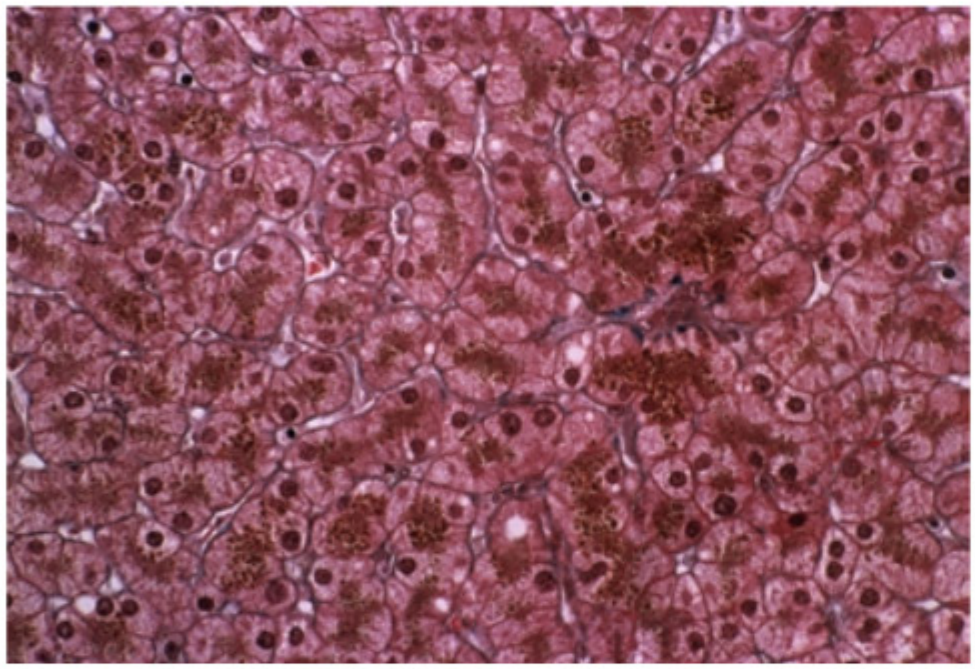

▲ **Figure 15–3.4** Cholestatic Diseases/ Dubin-Johnson Syndrome

Please visit us at www.Groupinsiders.com

© DeVry/Becker Educational Development Corp. All rights reserved.

4 Hepatic Inflammatory Diseases

Hepatic inflammation can be caused by:

- Viral hepatitis
- Autoimmune hepatitis
- Toxic exposure, including alcohol and drugs
- Metabolic diseases

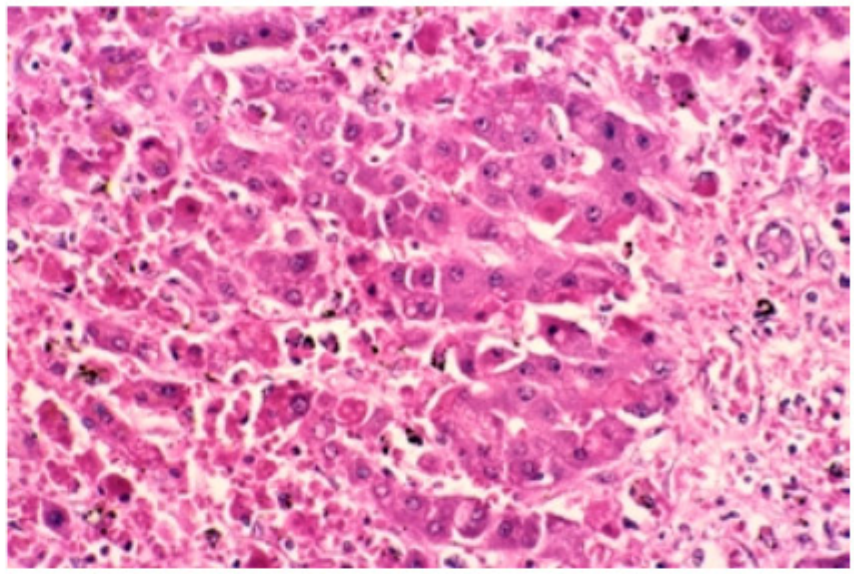

Dr. Frederick Skvara/Visuals Unlimited, Inc.

▲ **Figure 15–4.1A** "Councilman Bodies" in Viral Hepatitis

4.1 Viral Hepatitis

Pathogenesis

- Disease manifestations are due to viral infection of hepatocytes and necrosis.
- This also causes a brisk inflammatory response, which causes apoptosis of hepatocytes.
- The loss of functional hepatocytes causes hyperbilirubinemia (jaundice) and elevations of liver enzymes. Figure 15–1.1B illustrates the conseqeunce of viral hepatitis.

▼ **Table 15–4.1** Viral Hepatitis

Virus	Transmission	Acute Severity	Chronic	HCC
HAV	Fecal-oral	Mild	No	No
HBV	Parenteral, sexual, vertical	Most mild 1% to 4% fulminant hepatitis	5% to 10%	Yes
HCV	Parenteral, sexual	Usually subclinical; fulminant hepatitis rare	85%	20%
HDV	Parenteral, sexual	Fulminant hepatitis more common than HBV alone	Co-infect 5% Super- >80%	Yes
HEV	Fecal-oral, waterborne	Normally mild; 20% fulminant in pregnancy	No	No
HGV	Parenteral	Usually mild	No	No

Please visit us at www.Groupinsiders.com

© DeVry/Becker Educational Development Corp. All rights reserved.

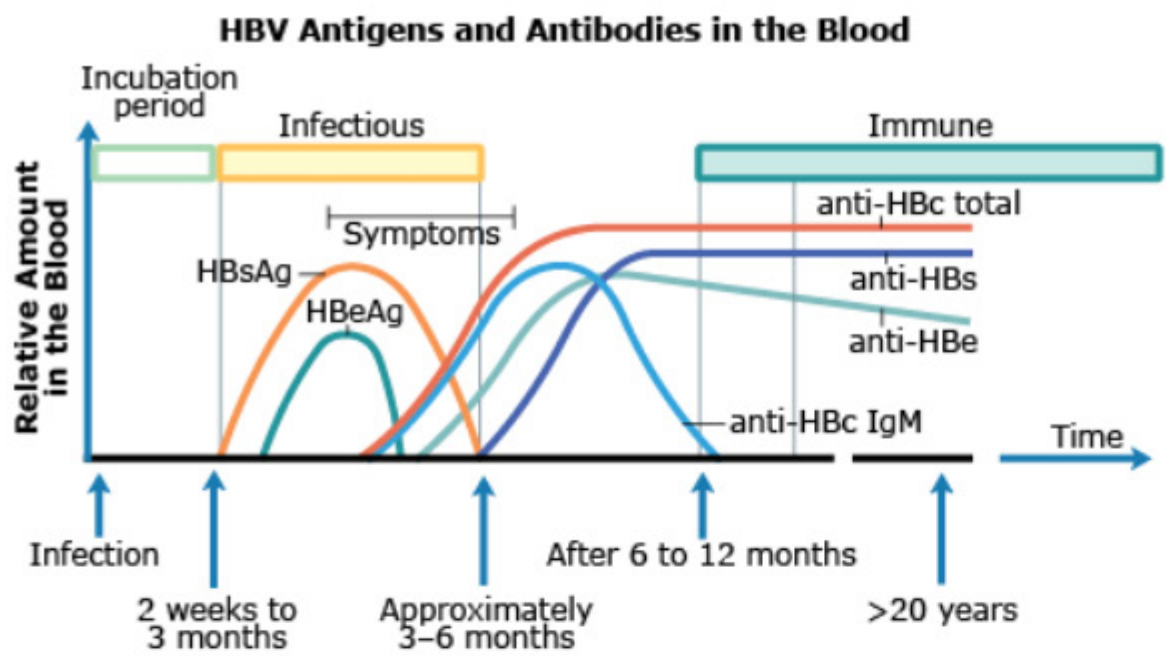

▲ **Figure 15–4.1B** Hepatitis B Virus Markers

4.2 Autoimmune Hepatitis

Etiology

- Caused by liver-specific autoantibodies
- *Associated with other autoimmune diseases*
  - Rheumatoid arthritis
  - Thyroiditis
  - Sjögren syndrome
  - Ulcerative colitis
- Associated with HLA-B8 and HLA-DRw3
- Patients are mostly *younger females*

Clinical Pathology

- Clinically indistinguishable from chronic viral hepatitis
- Course is variable from indolent to severe and progressive
- *80% have autoantibodies,* including
  - Antinuclear antibodies (ANA)
  - Anti-smooth muscle antibodies (SMA)
  - Anti-mitochondrial antibodies (AMA)
  - Anti-**L**iver and **K**idney **M**icrosome antibodies (LKM)
- Disease responds dramatically to immunosuppression
- Key finding on biopsy: Plasma cells in the portal tracts

Please visit us at www.Groupinsiders.com

© DeVry/Becker Educational Development Corp. All rights reserved.

4.3 Toxic Hepatitis

4.3.1 Alcohol Liver Disease

Pathogenesis/Morphology

Three stages:

1. **Hepatic Steatosis** (fatty change)
   - Alcohol is metabolized to triacylglycerol
   - *Liver is enlarged and may be tender*
   - Microscopic analysis shows fatty droplets in cells
   - Reversible with abstinence

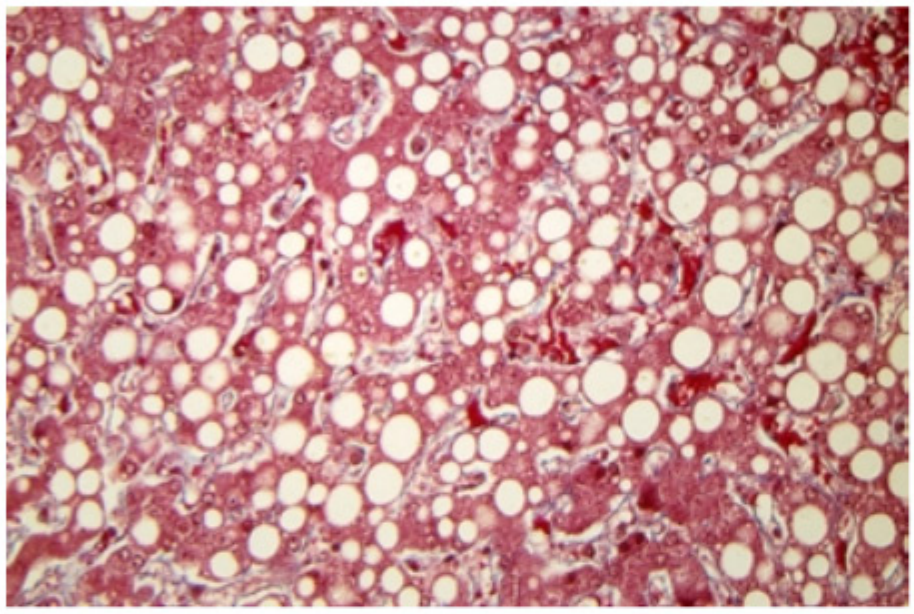

Custom Medical Stock Photo

▲ **Figure 15–4.3A** Hepatic Steatosis

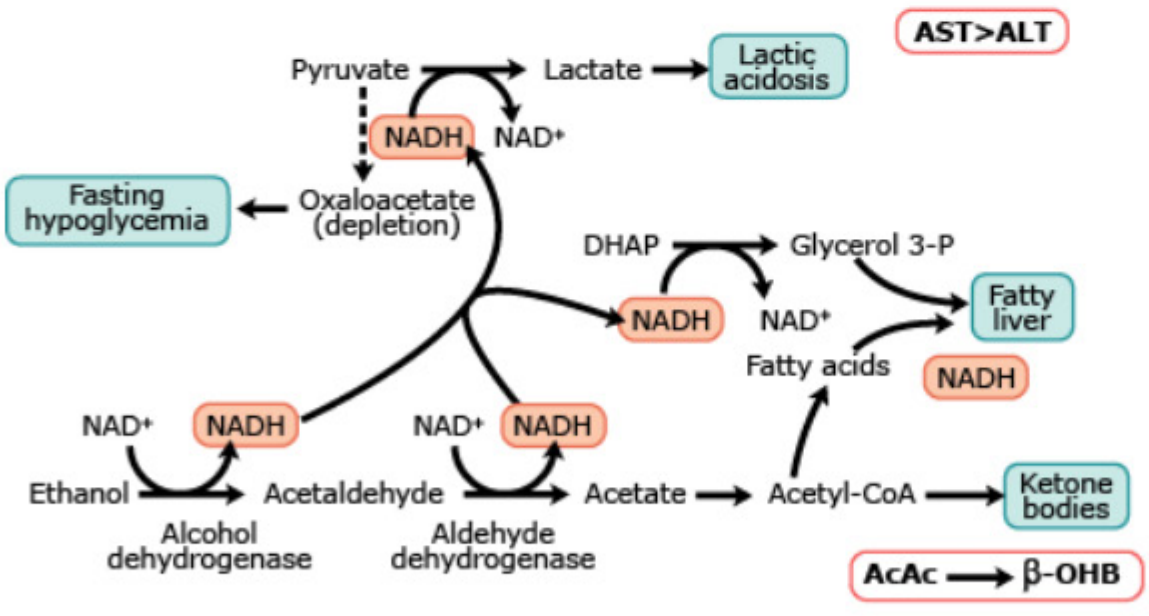

▲ **Figure 15–4.3B** Hypoglycemia

Please visit us at www.Groupinsiders.com

© DeVry/Becker Educational Development Corp. All rights reserved.

Clinical Application

Stage 2 of Alcohol Liver Disease

A 52-year-old man with a history of chronic alcoholic abuse was admitted with massive hematemesis. Endoscopy revealed esophageal varices and, in spite of resuscitative measures, he died a few hours later. What does the picture shown represent?

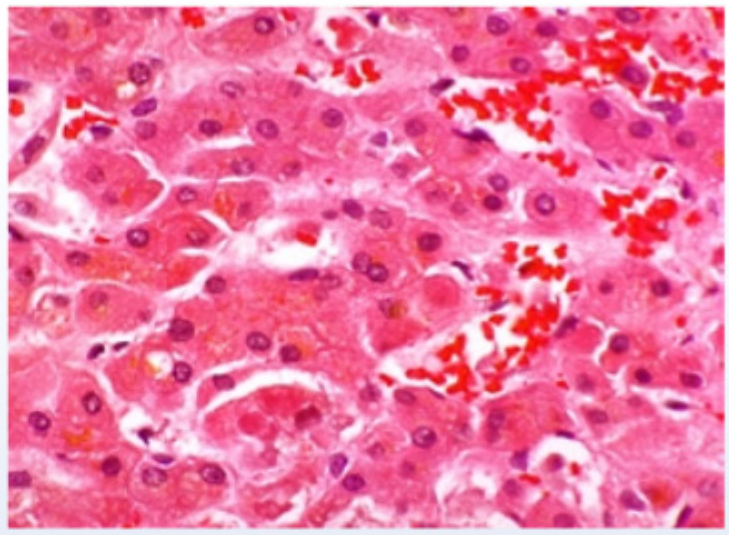

Courtesy of Dr. Edwin P. Ewing, Jr./CDC

▲ **Figure 15–4.3C** Alcoholic Liver Disease

2. Alcoholic Hepatitis

- Acute illness caused by acetaldehyde following binge drinking
- Clinically variable, from asymptomatic to fulminant hepatitis and liver failure
- Microscopically shows hepatocyte swelling, necrosis, inflammation, and hyaline *Mallory bodies*
  - —*Damaged intermediate filaments* predominantly composed of *keratin*
  - —Intermediate filaments: Keep organelles in position by providing a "scaffolding"
  - —They include *keratin, neurofilaments, glial filaments, vimentin, and desmin*

3. Alcoholic Cirrhosis

- Third stage of alcoholic liver disease
- Develops in 15% of alcoholics
- Mirconodular/macronodular cirrhosis

4.4 Reye Syndrome

Pathogenesis/Clinical Pathology

- Etiology unknown, but known to occur in children with viral illness treated with aspirin.
- Causes hepatic steatosis (fatty change) and cerebral edema/encephalopathy.
- 25% die or are left with permanent neurological deficits

See chapter 12, "Respiratory Pathology," for influenza virus causing viral pneumonia.

Please visit us at www.Groupinsiders.com

© DeVry/Becker Educational Development Corp. All rights reserved.

5 Metabolic Liver Diseases

- Wilson disease
- Hemachromatosis
- α1-antitrypsin deficiency

5.1 Wilson Disease

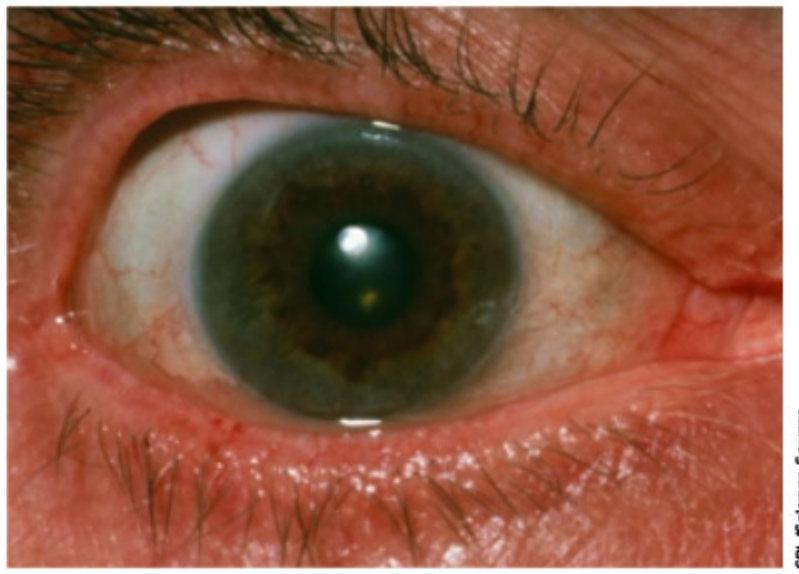

SPL/Science Source

▲ **Figure 15–5.1** Wilson Disease

Etiology

- Autosomal recessive
- Defect in *hepatic copper transport into bile*
- *Decreased incorporation of copper into ceruloplasmin* (copper binding protein) production

Pathogenesis

- Accumulation of free copper is toxic to many tissues, particularly the *liver*, where it causes acute hepatitis progressing to cirrhosis.
- **Brain**—particularly *basal ganglia* leading to movement disorders similar to Parkinson disease with additional psychiatric manifestations
- **Eye**—exam reveals Kayser-Fleischer rings around the iris

Laboratory Medicine

- Decreased *total* serum copper
- *Decreased serum ceruloplasmin*
- Liver biopsy—increased tissue copper and cirrhosis
- Increased serum/urine *free* copper

Clinical Application

Hemochromatosis

A 62-year-old white male presents to his physician with distended abdomen and complains that he has had a loss of appetite for the past six months. Physical examination reveals ascites, jaundice, and telangiectasia in the neck region. Further workup reveals fasting blood glucose of 134 mg/dL, and echocardiogram demonstrates a diastolic dysfunction. Tissue biopsy is stained, as shown at right. What is the most likely diagnosis of this patient?

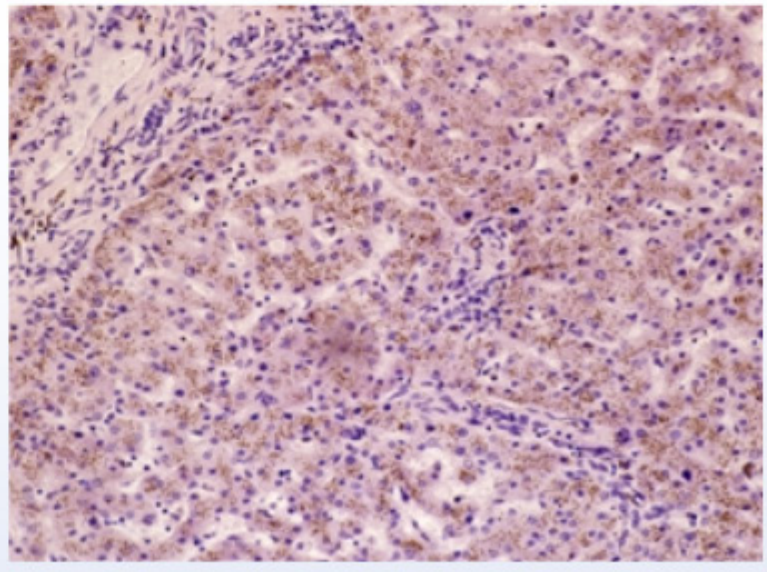

Astrid & Hanns-Frieder Michler/Science Source

▲ **Figure 15–5.2** Hemochromatosis

Please visit us at www.Groupinsiders.com

© DeVry/Becker Educational Development Corp. All rights reserved.

5.2 Hemochromatosis

- Defined as increased blood and tissue iron levels
- Hereditary (primary)—autosomal recessive mutation causing increased intestinal iron absorption
- More common in *males* (M:F = 5:1) with a 1 in 10 incidence
- Found primarily in those of *Northern European* descent
- C282Y mutation
- *Acquired (secondary)*—patients on chronic transfusion therapy for anemia

Pathogenesis

- Toxic iron deposits in multiple organs:
  - Liver—micronodular cirrhosis and increased risk of hepatocellular carcinoma
  - Heart—restrictive cardiomyopathy
  - Pancreas—acquired diabetes mellitus
  - Skin—causes bronze pigmentation *("bronze diabetes")*
  - Gonads—hypogonadism

5.3 α1-Antitrypsin Deficiency

Etiology

- Mutations in the gene encoding α1-antitrypsin (Pi):
  - PiM—normal
  - PiS—mildly decreased activity
  - PiZ—markedly decreased activity
  - *Homozygous PiZ mutants show disease*

Pathogenesis

- α1-Antitrypsin functions as a protease inhibitor, regulating the function of proteases, particularly neutrophil elastase, but also trypsin, chymotrypsin, and bacterial proteases.
- Normal inflammation causes considerable damage to normal tissues in the absence of this regulatory function.

Clinical Presentation

- Patients develop *micronodular cirrhosis* and are at increased risk for *hepatocellular carcinoma.*
- Patients also develop *COPD*, particularly smokers.

Please visit us at www.Groupinsiders.com

© DeVry/Becker Educational Development Corp. All rights reserved.

6 Hepatic Vascular Diseases

6.1 Hepatic Congestion

See chapter 10, "Cardiovascular Pathology," Figure 10–1.2B for an example of hepatic congestion.

6.2 Budd-Chiari Syndrome

Budd-Chiari syndrome is caused by thrombotic occlusion of the hepatic vein.

Etiology

- Idiopathic
- Polycythemia vera
- Pregnancy
- Oral contraceptives
- Paroxysmal nocturnal hemoglobinuria
- Hepatocellular carcinoma

Morphology

- Centrilobular congestion and necrosis

Clinical Presentation

- Painful hepatomegaly
- Portal hypertension and ascites
- Death from acute liver failure

Please visit us at www.Groupinsiders.com

© DeVry/Becker Educational Development Corp. All rights reserved.

7 Hepatic Neoplastic Diseases

7.1 Benign Tumors

7.1.1 Hemangioma

Benign vascular tumor, usually found incidentally on routine radiologic studies

7.1.2 Hepatic Adenoma

Benign tumor seen in young women taking oral contraceptives

7.2 Hepatocellular Carcinoma (Hepatoma)

Etiology

- Cirrhosis of any cause, particularly:
  - Hepatitis B and C viruses
  - Alcohol
  - Aflatoxin B1—found in *Aspergillus*-infested grain and peanuts
- Most hepatic tumors are metastatic from colon, breast, or lung

Morphology

- Focal, multifocal, or diffuse distribution
- Greenish hue from bile

Bollershot Photo/Science Source

▲ **Figure 15–7.2** Hepatocellular Carcinoma

Epidemiology

- More common in men
- Peaks about 60 years of age
- More common in *Asia*
- Causes *increased serum α-fetoprotein*
- Hematogenous metastasis via the portal and hepatic veins; *lung* is the most common site

Please visit us at www.Groupinsiders.com

© DeVry/Becker Educational Development Corp. All rights reserved.

7.3 Biliary Pathology

- Cholelithiasis
- Cholecystitis
- Cholangiocarcinoma

7.3.1 Cholelithiasis

Cholesterol Stones—Most Frequent (~80%)

Etiology

- Female over the age of 40
- Obesity
- Pregnancy
- Oral contraceptives/HRT

Pathogenesis

- Role of estrogen in cholesterol stones: Increase in uptake and synthesis of cholesterol in the liver; increase in HDL synthesis, which increases delivery of cholesterol to the liver; increase in the synthesis of HMG-CoA reductase, which increases cholesterol synthesis.
- Estrogen up-regulates LDL receptor synthesis in the liver, which then increases concentration of cholesterol in the bile.

Bilirubin Stones

Composed of unconjugated bilirubin and calcium salts.

Etiology

- Extravascular hemolytic anemia in which conjugated bilirubin is deconjugated to unconjugated bilirubin in the gallbladder. There is accumulation of pigmented stones composed of unconjugated bilirubin + Ca^{2+}.
- Cirrhosis
- Bacterial/parasitic infection

Clinical Presentation

- Usually asymptomatic
- Causes *postprandial biliary colic*—right upper quadrant (RUQ) pain that *radiates to the scapula*

Complications

- *Cholecystitis*—acute and chronic
- *Choledocholithiasis*—calculi obstructing the biliary tract
- May lead to *pancreatitis*
- *Cholangitis*—infection of the biliary tract

▲ **Figure 15–7.3A** Gallstones

Please visit us at www.Groupinsiders.com

© DeVry/Becker Educational Development Corp. All rights reserved.

7.3.2 Cholecystitis

Acute Cholecystitis

Acute inflammation of the gallbladder caused by cystic duct obstruction by gallstones.

Clinical Presentation

- RUQ pain with consumption of lipid-rich meals
- Nausea/vomiting
- Fever and leukocytosis

Diagnosis Ultrasound with HIDA scan for stone in cystic duct:

- Identifies stones in gallbladder and cystic duct.
- If dye does not empty into gallbladder, a stone in the cystic duct is indicated.
- If dye does not empty into the duodenum, a stone in the common bile duct is indicated.

Morphology Chronic inflammation, dystrophic *calcification (porcelain gallbladder)*, *Rokitansky-Aschoff* sinuses

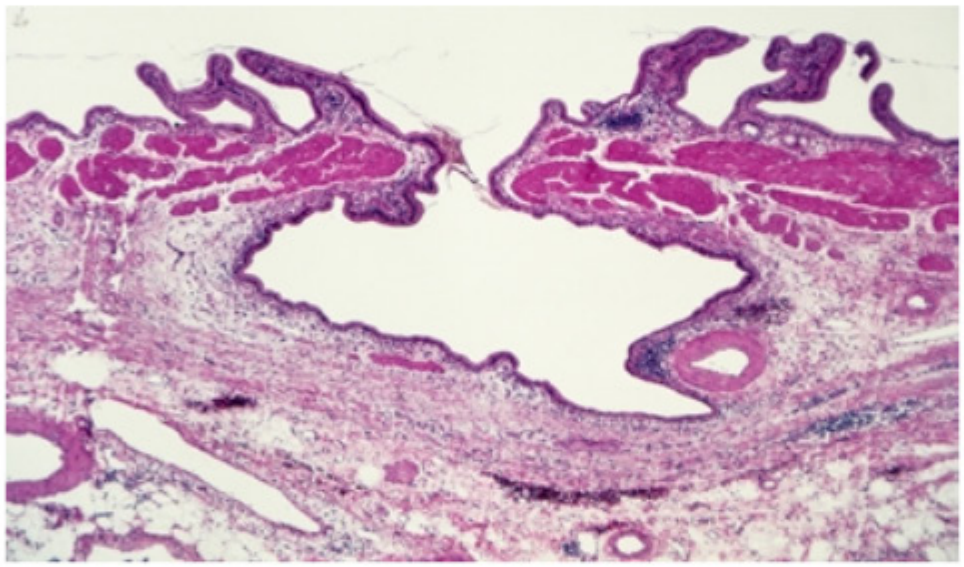

Dr. Gladden Willis/Visuals Unlimited, Inc.

▲ **Figure 15–7.3B** Cholecystitis

7.3.3 Cholangiocarcinoma

Adenocarcinoma—of the Extra- or Intrahepatic Bile Ducts

Etiology

- Primary sclerosing cholangitis
- Chinese liver fluke (*Clonorchis sinensis*)
- Thorium contrast dye

Clinical Presentation

- Elderly women
- Obstructive jaundice
- Palpable gallbladder (Courvoisier sign)
- Poor prognosis

Please visit us at www.Groupinsiders.com

© DeVry/Becker Educational Development Corp. All rights reserved.

Please visit us at www.Groupinsiders.com

1 Congenital Disorders

1.1 Annular Pancreas

The dorsal and ventral buds form a pancreatic ring around the duodenum, leading to its obstruction.

1.2 Pancreatic Agenesis

No exocrine or endocrine function.

1.3 Pancreas Divisum

- Incomplete fusion of the two primordial pancreatic bodies.
- At risk for recurrent pancreatitis.

1.4 Ectopic Pancreas

Pancreatic tissue in the stomach or duodenum.

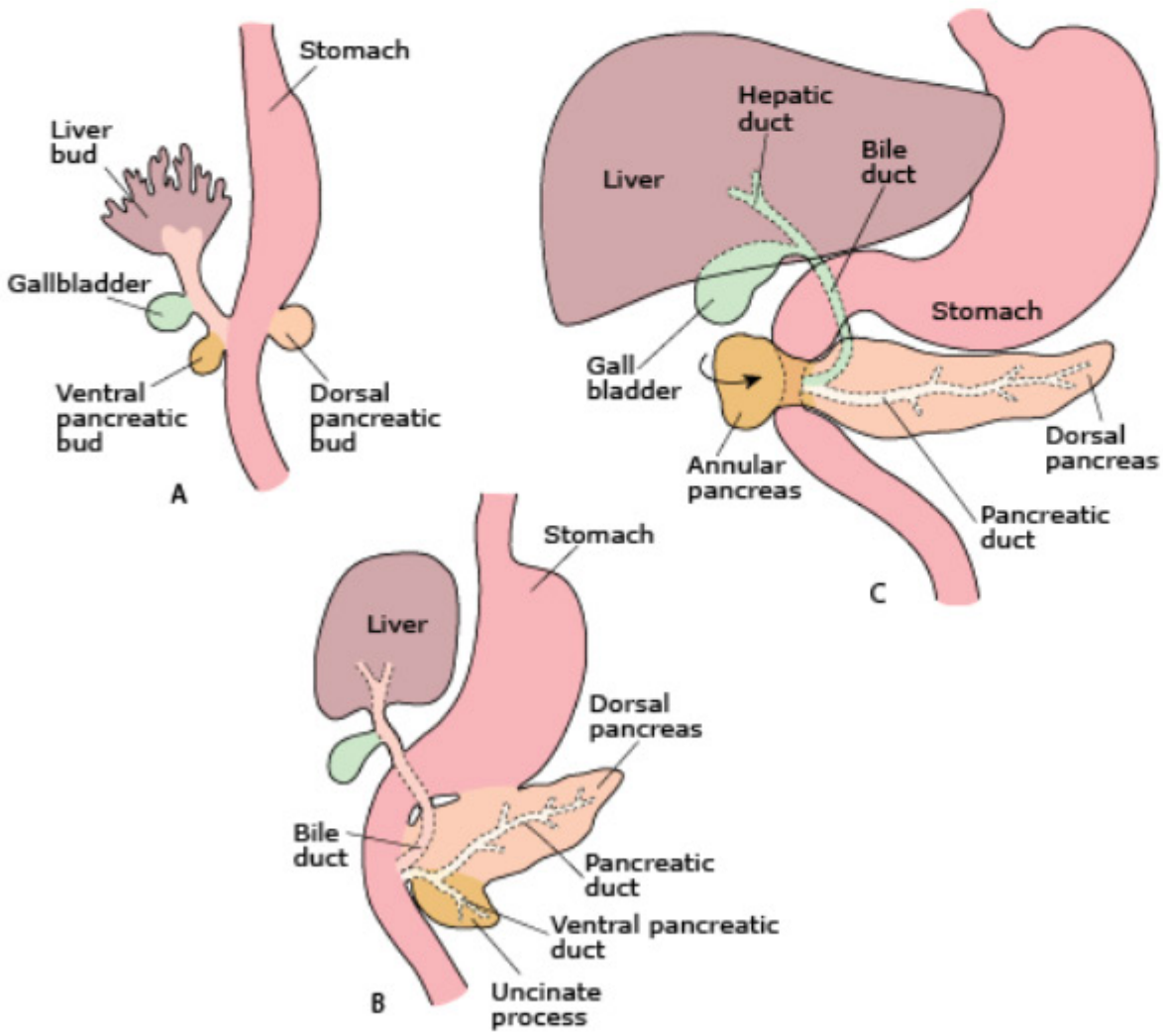

▲ **Figure 16–1.4** Congenital Disorders

USMLE® Key Concepts

For Step 1, you must be able to:

- Differentiate among various types of congenital pancreatic disorders.
- Differentiate among acute and chronic pancreatitis utilizing signs, symptoms, and labs.
- Identify neoplasia of the exocrine pancreas.

Important Concept

Pancreatic pathology includes:

- Congenital disorders
- Inflammation
  - Acute pancreatitis
  - Chronic pancreatitis
- Neoplastic disorders
  - Islet cell tumors
  - Adenocarcinoma

Please visit us at www.Groupinsiders.com

© DeVry/Becker Educational Development Corp. All rights reserved.

2 Inflammation

2.1 Acute Pancreatitis

- Methods by which pancreatic proenzymes lead to autodigestion of the pancreas:
  - Alcohol abuse causes increased permeability of the pancreatic duct to the pancreatic digestive enzymes. Alcohol has the following effects on the pancreatic duct:
    - —Increased obstruction by increasing mucus concentration and therefore behaving like a plug.
    - —Increases permeability of the duct so that the enzymes may escape the duct and cause harm to the pancreas.
  - Gallstones are also a major cause.
  - Acinar cellular injury by chemicals, infections, mechanical injury, and metabolic activation.
  - Trypsin is the most important pancreatic enzyme that activates proenzymes.

Clinical Findings

- Mid-epigastric pain with retroperitoneal radiation
- Fever, nausea, and vomiting
- Third spacing as a result of peripancreatic autodigestion leads to hypovolemia.
- Acute respiratory distress syndrome (ARDS) may take place due to circulating pancreatic phospholipase destroying surfactant, causing atelectasis and intrapulmonary shunting.
- Tetany occurs due to decreased ionized calcium as a result of dystrophic calcification.

CNRI/Science Source

▲ **Figure 16–2.1A** Acute Pancreatitis

Important Concept

Examples of each type of injury to ACINAR cells:

1. Chemical injury to acinar cells:
   —Thiazides, alcohol, TAG >1,000 mg/dL
2. Infectious injury to acinar cells:
   —CMV, mumps, Coxsackievirus
3. Mechanical injury to acinar cells:
   —Seat belt trauma, posterior penetration of perforated duodenal peptic ulcer disease
4. Metabolic activation of proenzymes:
   —Hypercalcemia, ischemia, shock

Important Concept

Trypsin will activate each of these important enzymes thereby causing specific injury to the pancreas and presentation of the patient.

1. Elastase will cause damage to the pancreatic blood vessels resulting in hemorrhage-type of issues as seen in the figure.
2. Lipases and phospholipase will hydrolyse triacylglycerides resulting in enzymatic fat necrosis.
3. Protease damage acinar cellular structure.

Please visit us at www.Groupinsiders.com

© DeVry/Becker Educational Development Corp. All rights reserved.

2.1.1 Complications

Pancreatic Necrosis

- Systemic signs occur earlier than usual.
- Higher fever than usual.
- Greater degree of neutrophilic leukocytosis.
- Peripancreatic infections occur in a large percentage of patients.

Pancreatic Pseudocyst

- Collection of digested pancreatic tissue around pancreas.
- Abdominal mass with persistence of serum amylase >10 days.
- Treatment is based on the size of the fluid of <5 or >5 cm.

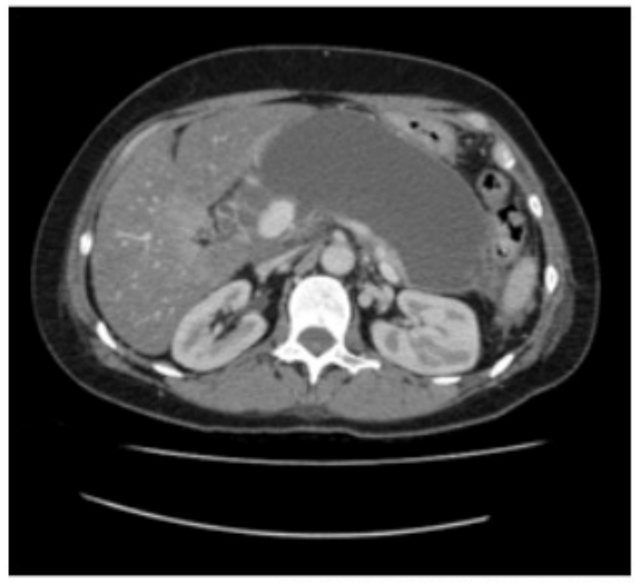

B. Slaven MD/Custom Medical Stock Photo

▲ **Figure 16–2.1B** Pancreatic Pseudocyst

Pancreatic Abscess

- Presents with high fever due to gram-negative sepsis with increased amylase. CT will show multiple radiolucent bubbles in the retroperitoneum.

2.1.2 Laboratory Findings

Serum Amylase

- Not specific for pancreatitis due to presence in the salivary glands.
  - Amylase in acute pancreatitis: Sensitivity is 85%; specificity is 70%.
- Persistent increase in serum amylase for more than seven days suggests pseudocyst.

Serum Lipase

- More specific for pancreatitis and is not excreted in the urine.
- Use of lipase in chronic pancreatitis is not clinically useful.

Serum Immunoreactive Trypsin

- Trypsin is more specific for the pancreas.
- It is an excellent newborn screen for cystic fibrosis.
- Serum immunoreactive trypsin in acute pancreatitis is increased dramatically.
- Serum immunoreactive trypsin in chronic pancreatitis is decreased.

2.1.3 Imaging Studies

- CT scan is the gold standard.
- Plain abdominal radiograph
  - Sentinel loop in subjacent duodenum or transvers colon (cutoff sign)
    - —Localized ileus, where the bowel does not demonstrate peristalsis
    - —Left-sided pleural effusion, which contains amylase
- Ranson criteria is used for diagnosing acute pancreatitis.

Please visit us at www.Groupinsiders.com

© DeVry/Becker Educational Development Corp. All rights reserved.

2.1.4 Chronic Pancreatitis

This is mostly an idiopathic condition that affects men more than women.

Etiology

- Alcohol is the most common known cause.
- Cystic fibrosis is the most common cause in children.
- Malnutrition is the most common cause in developing countries.

Pathogenesis

- Repeated attacks of acute pancreatitis produce duct obstruction.
- Radiographic studies reveal a calcified "chain of lakes" appearance.

Clinical Findings

- Malabsorption as a result of dysfunction of exocrine pancreas. This would indicate more than 90% damage destruction to exocrine pancreas.
- Type 1 diabetes mellitus, often referred at "Brittle" Diabetes.
- Lack of pancreatic extract leads to an inability to cleave R-factor from vitamin B12.
- Pancreatic pseudocysts may be found in both acute and chronic pancreatitis.

Laboratory and Radiographic Findings

- Increased amylase and lipase, which may be unreliable.
- Increased serum immunoreactive trypsin.
- Tests for pancreatic insufficiency:
  - CT scan shows dystrophic calcification.
  - Functional tests: *Secretin stimulation* test and *bentiromide test*. Bentiromide tests the ability of pancreatic chymotrypsin to cleave orally administered bentiromide to PABA.
- Treatment is symptomatically based.
- Approximately 50% of patients die within 10 years.

Please visit us at www.Groupinsiders.com

© DeVry/Becker Educational Development Corp. All rights reserved.

3 Neoplastic Disorders

3.1 Islet Cell Tumors

Refer to chapter 19, "Endocrine Pathology," for discussion of this topic.

3.2 Exocrine Pancreatic Cancer

Epidemiology

- Slightly more common in men than women, with the same rate of incidence in both genders.
- Adenocarcinoma of the pancreas tends to occur in the seventh and eighth decades of life.

Etiology

- Smoking is the most common cause.
- Chronic pancreatitis is secondary to alcoholism or cirrhosis.
- Hereditary or diabetes mellitus.
- Diets with a high consumption of lipids.

Pathogenesis

- Associated with K-RAS gene mutation leading to mutation of TP16 and TP53.

Laboratory and Clinical Findings

- Most commonly found in the pancreatic head, leading to signs of common bile duct obstruction. See chapter 15, "Hepatobiliary," Figure 15–1.0F, for an illustration of obstructive jaundice.
- Superficial migratory thrombophlebitis, known as Trousseau sign.
- Retroperitoneal hemorrhage leads to purplish appearance of the skin, called Grey Turner sign.
- Periumbilical hemorrhagic discoloration due to pancreatic necrotic tissue around the falciform and umbilical ligaments, known as Cullen sign.
- Metastasis to left supraclavicular node is known as Virchow node, and periumbilical metastasis is known as Sister Mary Joseph sign, both of which may also be found as a manifestation of gastric cancer.
- Tumor marker: CA 19-9 is the gold standard.
- Helical CT scan shows "C" sign of the head of the pancreas.

Welcome Images/Custom Medical Stock Photo

▲ **Figure 16–3.2** Grey Turner and Cullen Signs

Please visit us at www.Groupinsiders.com

© DeVry/Becker Educational Development Corp. All rights reserved.

Please visit us at www.Groupinsiders.com

Unit 8

Reproductive Pathology

Please visit us at www.Groupinsiders.com

Please visit us at www.Groupinsiders.com

1 Congenital Abnormalities

Hypospadias

- Most common malformation of the urethral groove, resulting from an abnormal folding of the urethral folds on the ventral (lower) surface of the penis.
- Urethral defects may cause urinary tract obstruction and increased risk for infection.

Epispadias

- Inadequate ectodermal-mesenchymal interactions during development of the genital tubercle, resulting in an abnormal opening on the dorsal (top) surface of the penis.
- Associated with urinary bladder exstrophy.
- Less common than hypospadias.

Phimosis

- Orifice of the prepuce too small to permit normal retraction over the glans penis.
- May result from abnormal development, but is also secondary to scarring from repeated infections.

USMLE® Key Concepts

For Step 1, you must be able to:

- Describe various male congenital disorders.
- Identify various esophageal pathologies.
- Explain various gastric pathologies.

Please visit us at www.Groupinsiders.com

© DeVry/Becker Educational Development Corp. All rights reserved.

2 Penile Pathology

2.1 Peyronie Disease

A subcutaneous fibramatosis causing contracture of the penis laterally that may result in infertility.

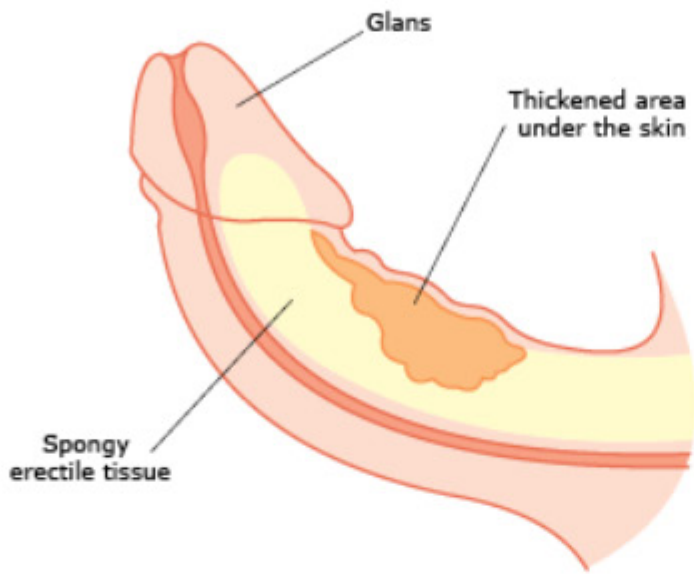

▲ **Figure 17–2.1** Peyronie Disease

2.2 Priapism

- An intractable, often painful erection lasting four hours or more.
- Considered a medical emergency.
- Associated with trazodone and erectile dysfunction medications.
- Also associated with sickle cell disease.
- Patients sometimes present with venous thrombosis of the corpora cavernosa.

2.3 Intraepithelial Neoplasia—Carcinoma in Situ of the Penis

Bowen Disease

- Leukoplakia involving the shaft of the penis or on the scrotum.
- Predominantly affects men over age 35.
- Precursor for invasive squamous cell carcinoma.

Erythroplasia of Queyrat

- Erythroplakia located on the mucosal surface of the glans penis and prepuce.
- Precursor for invasive squamous cell carcinoma.

Bowenoid Papulosis

- Multiple pigmented reddish brown papules on the external genitalia.
- Association with *HPV type 16*.
- Does *not* develop into invasive carcinoma.

Please visit us at www.Groupinsiders.com

© DeVry/Becker Educational Development Corp. All rights reserved.

2.4 Neoplasia of the Penis—Squamous Cell Carcinoma

Epidemiology and Pathogenesis

- Most common cancer of the penis, usually affecting men 40 to 70 years of age.
- The most common sites are the glans or the mucosal surface of the prepuce. Metastasizes to the inguinal and iliac nodes.
- HPV types 16 and 18 are associated with two thirds of the cases that may share cocarcinogenesis with HPV.

Risk Factors

- Lack of circumcision is the greatest risk factor.
- Carcinoma-in-situ conditions, such as Bowen disease and erythroplasia of Queyrat, as mentioned in topic 2.3, are also precursors.

Please visit us at www.Groupinsiders.com

© DeVry/Becker Educational Development Corp. All rights reserved.

3 Abnormalities of the Testes, Epididymis, and Scrotal Sac

3.1 Cryptorchidism

- Complete or incomplete failure of intra-abdominal testes to descend into the scrotal sac.
- It is the most common genitourinary disorder in male children.
- Its occurrence is 30% in premature infants.
- Inguinal canal is the most common site of a unilateral palpable mass.
- May result in atrophy and thus infertility.
- Increased risk of developing germ cell tumors, especially seminoma and embryonal carcinoma, with risk elevated even if treated.
- Treatment with orchiopexy should be performed by 2 years of age.

3.2 Testicular Torsion

Epidemiology and Pathogenesis

- Predisposing factors include violent movement or physical trauma.
- Twisting of spermatic cord, which disrupts arterial and venous blood supply to testes.
- Thick-walled arteries remain patent so that intense vascular engorgement and venous infarction follow.
- Ranges from intense congestion to widespread extravasation of blood into interstitial tissue of testes and epididymis.
- Testes is enlarged and converted into sac of soft, necrotic, and hemorrhagic tissue.

Clinical Findings

- Absent cremasteric reflex is the most important finding.
- Testes are found to be placed high in the inguinal canal.

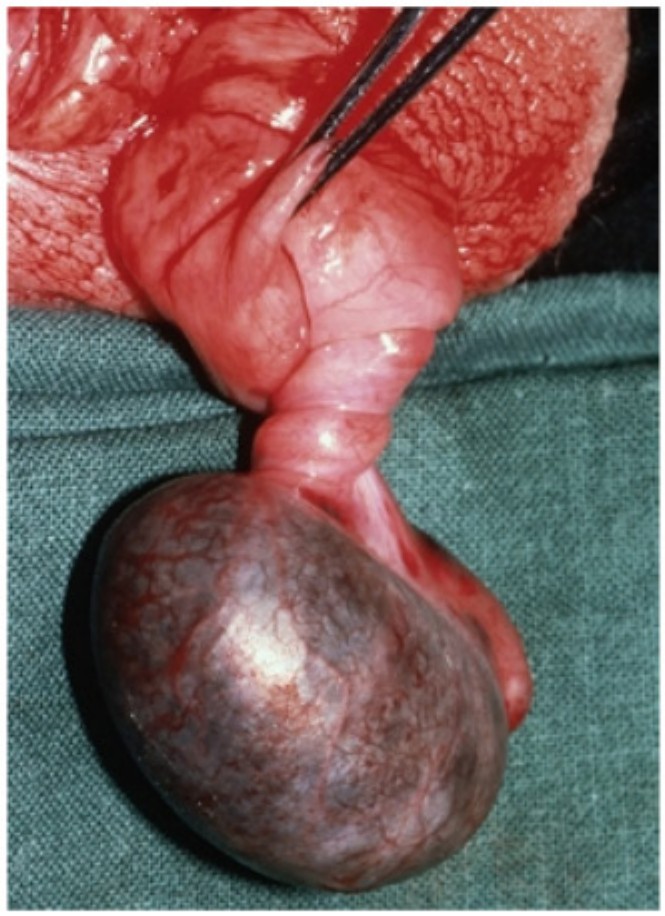

Wellcome Images/Custom Medical Stock Photo

▶ **Figure 17–3.2**
Testicular Torsion

Connection to Microbiology

Causes of infection of the epididymis are called *epididymitis*.

Important Concept

Patient usually presents with scrotal pain with epididymitis due to inflammation of the structure itself. This is characterized by a diagnostic finding called Prehn sign, whereupon lifting the scrotal sac relieves the pain.

Please visit us at www.Groupinsiders.com

© DeVry/Becker Educational Development Corp. All rights reserved.

3.3 Varicocele

Epidemiology, Pathogenesis, and Clinical Examples

- Occurs in 15% to 20% of all males and occurs in 40% of infertile males.
- Most common cause of left-sided scrotal enlargement in an adult:
  - Incompetent valves in left spermatic vein.
- Blockage of the left spermatic vein also may occur due to blockage of renal vein.
- Right-sided scrotal enlargement in an adult.

Clinical Findings

- Aching pain in scrotum
- Visible "bag of worms"
- Diagnosis by ultrasound

Medicimage/Phototake, Inc.

▲ **Figure 17–3.3** Varicocele

3.4 Hydrocele

Epidemiology and Pathogenesis

- Most common cause of scrotal enlargement.
- In hydrocele, there is failure of closure of the tunica vaginalis, which then manifests as fluid accumulation in the serous space between the layers.

Diagnosis Ultrasound distinguishes fluid versus a testicular mass causing scrotal enlargement.

Connection to Anatomy

Review left and right spermatic veins:

1. Left spermatic vein drains into the left renal vein, which then drains into the inferior vena cava (IVC). This more tortuous route of the left spermatic vein results in an increased resistance to blood flow.
2. Right spermatic vein drains directly into the inferior vena cava.

Clinical Application

A male smoker with sudden onset of left varicocele needs to be investigated for renal cell carcinoma with hematogenous spread through the left renal vein.

Clinical Application

Thrombosis of the inferior vena cava may cause right-sided spermatic vein blockage.

Please visit us at www.Groupinsiders.com

© DeVry/Becker Educational Development Corp. All rights reserved.

4 Testicular Tumors—Major Categories

4.1 Germ Cell Tumors (90%)

- Seminoma
- Embryonal carcinoma
- Yolk sac tumor
- Polyembryoma
- Choriocarcinoma
- Teratomas:
  - Mature
  - Immature

4.2 Nongerminal Tumors

- Leydig cell tumor
- Sertoli cell tumor
- Granulosa cell tumor

▼**Table 17–4.0A** Testicular Tumors: Germ Cell Tumors

Tumor	Age	Morphologic/Clinical Findings	Tumor Marker(s)	Prognosis
Seminoma	30–35; >65	Most common germ cell tumor (40%). Gray tumor without hemorrhage or necrosis. Large cells with centrally located nucleus containing prominent nucleoli. Lymphocytic infiltrate. Metastasis: *Lymphatic (para-aortic lymph nodes) before hematogenous (lungs).* Spermatocytic variant occurs in older individuals and rarely metastasizes.	↑ hCG in 10%	Excellent; extremely radiosensitive.
Embryonal carcinoma	20–25	Bulky tumor with hemorrhage and necrosis. Metastasis: *Hematogenous before lymphatic.*	↑ AFP and/or hCG in 90%	Intermediate; less radiosensitive than seminomas.
Yolk sac (endodermal sinus) tumor	Most common testicular tumor in children under 4 years old	Characteristic Schiller-Duval bodies resemble primitive glomeruli.	↑ AFP in all cases	Good

Credits: (top to bottom) Dr. E Walker/Science Source; Javier Domingo/Phototake, Inc.

Please visit us at www.Groupinsiders.com

© DeVry/Becker Educational Development Corp. All rights reserved.

▼ Table 17–4.0A Testicular Tumors: Germ Cell Tumors *(continued)*

Tumor	Age	Morphologic/Clinical Findings	Tumor Marker(s)	Prognosis
Choriocarcinoma	20–30	Most commonly mixed with other tumor types. Contains trophoblastic tissue (syncytiotrophoblast and cytotrophoblast). May produce gynecomastia (hCG is an LH analogue).	↑ hCG in all cases	Poor; most aggressive tumor; hematogenous spread to lungs.
Teratoma	Affects males of all ages	Contains derivatives from ectoderm, endoderm, and mesoderm. Mixed with embryonal carcinoma (teratocarcinoma).	↑ AFP and/or hCG in 50%	Good; usually benign in children and malignant in adults (usually squamous cell carcinoma).

Credit: Mediscan/Visuals Unlimited, Inc.

▼ Table 17–4.0B Comparison Features

Seminoma	Nonseminomatous Germ Cell Tumors
Tend to remain localized to testis for long time	Painless enlargement of the testis
Metastases tend to involve lymph nodes	Metastasizes early and hematogenously
Radiosensitive	Radioresistant

Yolk Sac Tumors	Choriocarcinomas
Tumor marker: α-fetoprotein elevated	Human chorionic gonadotropin (hCG) elevated

▼ Table 17–4.0C Non-Germ Cell Tumors

Leydig Cell Tumors	Sertoli Cell Tumors
Tumor derived from testicular stroma (look for Reinke crystals)	Derived from sex-cord stroma
Similar to Sertoli-Leydig cell tumor of the ovary	Similar to Sertoli-Leydig cell tumor of the ovary
Most often benign	Most are benign in nature
May elaborate both androgens and estrogens	
Arise at any age Circumscribed nodules	Firm, small nodule with homogenous gray-white to yellow cut surface

Credit: CNRI/Science Source

Please visit us at www.Groupinsiders.com

© DeVry/Becker Educational Development Corp. All rights reserved.

5 Prostate

5.1 Inflammation of the Prostate

5.1.1 Acute Bacterial Prostatitis

- Acute focal or diffuse suppurative inflammation in prostatic substance.

Pathogenesis

- Intraprostatic reflux of urine from posterior urethra or from urinary bladder.
- Possibly lymphohematogenous routes from distant foci of infection.
- Sometimes surgical manipulation of urethra or prostate.

Clinical Presentation

- Fever, chills, and dysuria.
- Prostate is tender and boggy.

Etiology

- Pathogens in patients <35 years of age:
  - *Chlamydia trachomatis*
  - *Neisseria gonorrhoeae*
- Pathogens in patients >35 years old
  - *E. coli*
  - *Pseudomonas aeruginosa*
  - *Klebsiella pneumoniae*

5.1.2 Chronic Bacterial Prostatitis

- May present with low back pain, dysuria, and perineal and suprapubic discomfort.
- Recurrent urinary tract infections caused by same organism.
- Diagnosis is by documentation of leukocytosis and positive bacterial cultures in expressed prostatic secretions.
- Aggregation of lymphocytes, plasma cells, and macrophages, or neutrophils in prostatic substance.

5.1.3 Chronic Abacterial Prostatitis

- Most common form of prostatitis.
- Clinically indistinguishable from chronic bacterial prostatitis.
- No history of recurrent urinary tract infection.
- Pyuria, but negative cultures.
- Possibly *C trachomatis, Ureaplasma urealyticum, or Mycoplasma hominis.*

Please visit us at www.Groupinsiders.com

© DeVry/Becker Educational Development Corp. All rights reserved.

5.2 Benign Prostatic Hyperplasia (BPH)

- Incidence: 20% at age 40 years, 90% by age 70

Pathogenesis Dihydrotestosterone (DHT) is the ultimate mediator of prostatic growth:

- Converted from testosterone by 5-α reductase.
- DHT can act in an autocrine fashion on stromal cells or in paracrine fashion by diffusing into nearby epithelial cells.
- Inhibition of 5-α reductase can reduce DHT content in prostate and decrease prostatic volume and urinary obstruction.
- *No relation to prostatic cancer.*

Clinical Findings

- Well-defined nodules bulge from the cut surface.
- The proximity of the nodules to the urethra accounts for the *urinary obstruction* associated with the lesion.
- Urinary bladder diverticulum, bilateral post-renal azotemia are long-term complications of BPH.
- BPH is usually in *periurethral* and *transitional* zones.

Javier Domingo/Phototake, Inc.

▲ **Figure 17–5.2** Benign Prostatic Hyperplasia (BPH)

5.3 Prostatic Carcinoma

- Incidence: 69 per 100,000

Risk Factors

- Age
- African-American
- Family history

Connection to Pharmology

5-α reductase is the primary target for drugs to combat BPH and alopecia in men. The enzyme inhibition is identical for both conditions but the trade name is different.

Please visit us at www.Groupinsiders.com

© DeVry/Becker Educational Development Corp. All rights reserved.

Pathogenesis

- 70% arise in peripheral zone of gland in *peripheral location* (thus somewhat detectable by rectal exam).
- Neoplastic tissue is gritty and firm.
- Spread occurs by direct local invasion and through *blood* and *lymph*.
- *Local extension* most commonly involves seminal vesicles and base of the urinary bladder.
- Hematogenous spread to especially axial skeleton.
- Most are adenocarcinomas.
- Grading is of particular importance in prostatic cancer because there is good correlation between prognosis and degree of differentiation.

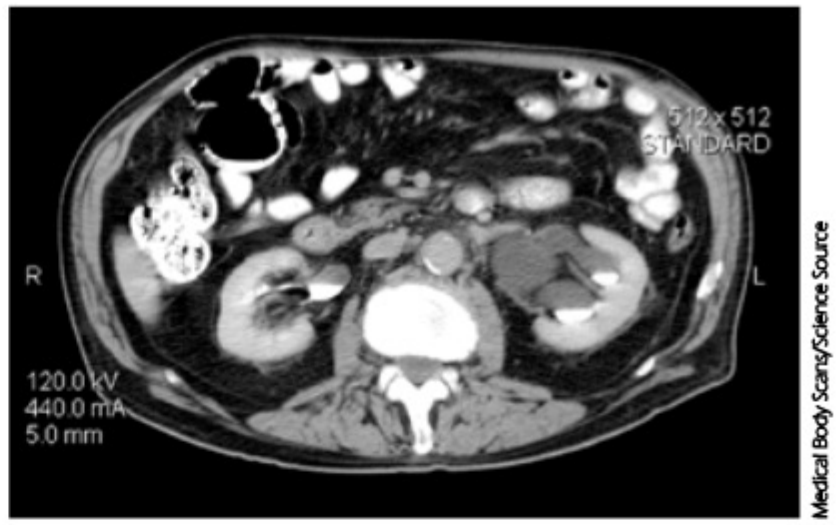

Medical Body Scans/Science Source

▲ **Figure 17–5.3A** Prostate Cancer

Gleason Grading System

Pathologic Findings Glandular differentiation is much less obvious in some higher-grade lesions.

Clinical Features

- Increase in PSA (bound form).
- Prostatic acid phosphatase increased when the tumor invades and metastasizes.
- Used for follow-up of disseminated disease.
- Alkaline phosphatase increased with bony metastasis (lumbar spine).

Zephyr/Science Source

▲ **Figure 17–5.3B** Prostate Cancer: Osteoblastic Metastasis to the Vertebrae

Please visit us at www.Groupinsiders.com

© DeVry/Becker Educational Development Corp. All rights reserved.

6 Common Male Chromosomal Abnormalities

6.1 Klinefelter Syndrome

Pathogenesis

- One per 1,000 live births.
- Nondisjunction meiosis XXY karyotype.
- Seminiferous tubules fibrosed: azoospermia, ↓ inhibin (no Sertoli cells) leads to ↑ FSH.
- Leydig cells prominent: ↑ FSH ↑ aromatase synthesis. Feminization due to testosterone conversion into estrogen by aromatase in Leydig cells/adipose. In addition, testosterone does not interact with androgen receptors (feminization).

Clinical Findings

- May be asymptomatic until puberty.
- Eunichoid proportions where arm span is greater than height of the individual.
- Intellect may be subnormal.
- Physical exam: Gynecomastia; variable secondary sexual characteristics; small, firm testes as adult.
- Infertile
- Increased risk of breast cancer, autoimmune disease, germ cell neoplasms.

Note the female secondary sex characteristics, including gynecomastia and a female distribution of pubic hair. Even though the "legs" are disproportionately longer than normal, the arm span being longer than the length of the individual is a more noteworthy diagnostic feature in Klinefelter syndrome.

Diagnosis

- ↑ FSH, ↑ estradiol, ↑ LH, ↓ testosterone, ↓ inhibin
- Karyotype to confirm diagnosis.
  - Treat with androgen replacement.

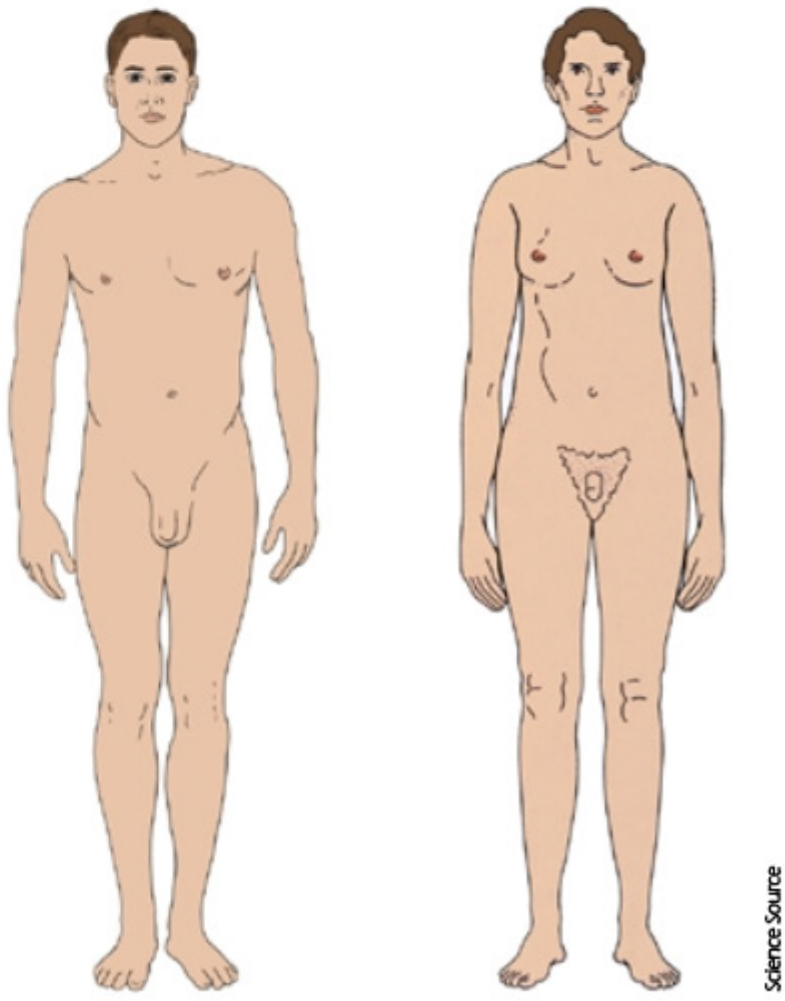

▶ **Figure 17–6.1** Klinefelter Syndrome

Please visit us at www.Groupinsiders.com

© DeVry/Becker Educational Development Corp. All rights reserved.

6.2 Androgen Insensitivity Syndrome (Testicular Feminization Syndrome)

Pathogenesis

- Male pseudohermaphrodite
- Absent androgen receptors
- Testosterone has an influence on the internal male reproductive structures. In AIS, because the receptors are resistant to the actions of testosterone, these internal male structures, which include seminal vesicles, vas deferens, and epididymis, do not develop, and remain absent upon birth.
- No dihydrotestosterone (DHT) effect on male fetus: DHT normally converts clitoris into penis and labia into scrotum, and develops the prostate. In AIS, external genitalia remain female in appearance and lower two thirds of the vagina ends blindly because it develops from the urogenital sinus.
- Müllerian inhibitory factor is functional in male fetus. No müllerian structures (fallopian tubes, uterus, cervix, upper third of vagina).
- Estrogen is unopposed; breast development is female.
- Usually reared as a female; testicles are removed to prevent seminoma.

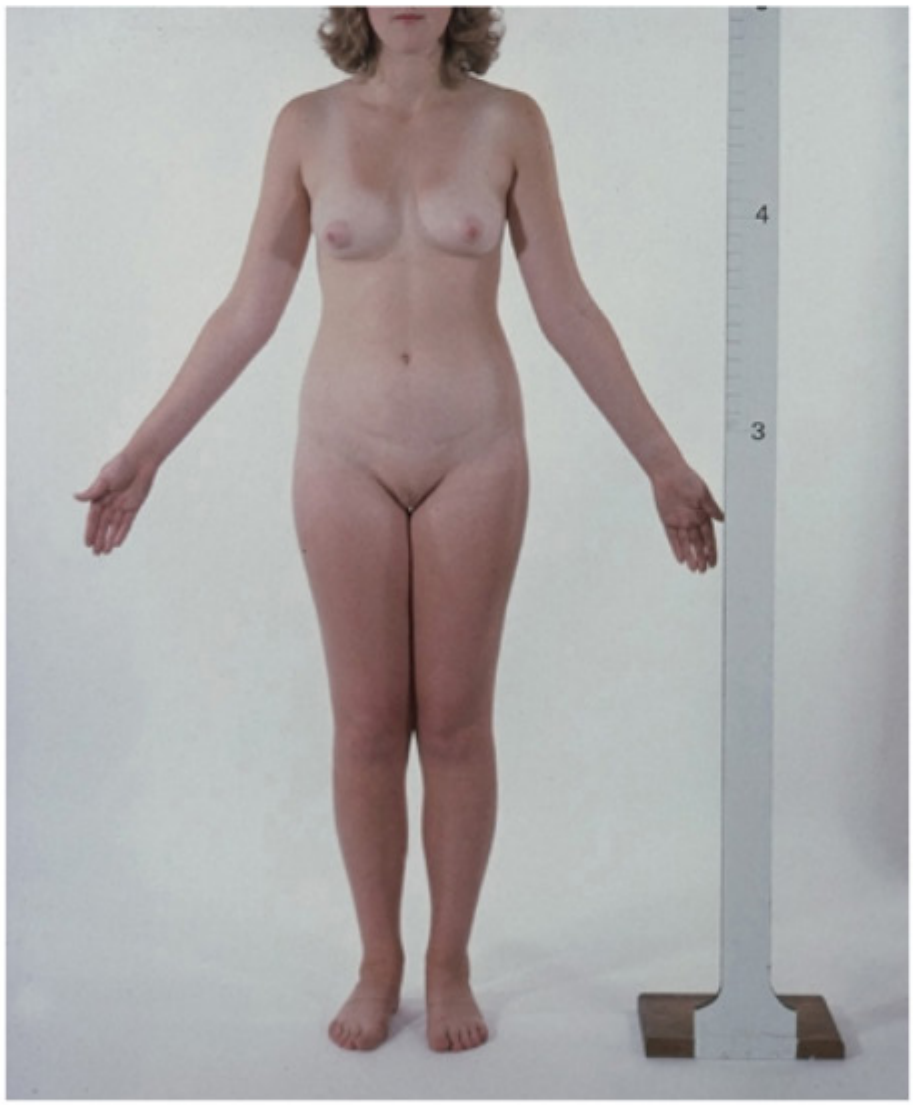

Wellcome Images/Custom Medical Stock Photo

▲ **Figure 17–6.2** Androgen Insensitivity Syndrome (AIS)

Please visit us at www.Groupinsiders.com

© DeVry/Becker Educational Development Corp. All rights reserved.

▼Table 17–6.2 Common Abnormalities

Klinefelter Syndrome	Androgen Insensitivity Syndrome	Premature Ovarian Failure	Polycystic Ovarian Syndrome
XXY Eunichoid Features	**XY Phenotypic "Female" Presents With Amenorrhea**	**Female <40 Years Old Presents With Amenorrhea**	**Female Presents With Amenorrhea and Hirsutism**
• Loss of Seroli cells results in loss of inhibin and thus increased FSH • The increased FSH stimulates aromatase activity in male gonads and adipocytes, resulting in increased estrogen production • Estrogen will bring about female secondary sexual characteristics	• Loss of testosterone receptor activity • This then leads to complete loss of testosterone activity and therefore no development of internal male reproductive structures, including vas deferens, epididymis, seminal vesicles • No conversion of testosterone into DHT and therefore no development of external male reproductive structures • XY results in inherent presence of MIF, which inhibits the production of internal female reproductive structures, which include fallopian tubes, uterus, cervix, and proximal $^{1}/_{3}$ portion of the vagina • Distal $^{2}/_{3}$ portion of the vagina develops because of the influence of estrogen	• Loss of entire ovarian function • Decreased estrogen and inhibin results in feedback stimulation of LH and FSH • Progesterone withdrawal test is negative for bleeding	• Increased production of LH with intact ovary • Increased LH increases production of testosterone (T) • Increased T causes increased male pattern of hair distribution → hirsutism • Increase T is then converted to estrogen (E) by aromatase • Increased E: —Increases LH as it would with LH surge —Inhibits FSH and therefore no further folicle development takes place • This inadequately developed follicle then accumulates fluid and is transformed into a cyst • Progesterone withdrawal test is positive for bleeding

Please visit us at www.Groupinsiders.com

© DeVry/Becker Educational Development Corp. All rights reserved.

Please visit us at www.Groupinsiders.com

1 Vulva Disorders

1.1 Non-neoplastic Dermatoses

Lichen Sclerosis

- Usually occurs in postmenopausal women.
- Thinning of the epidermis: Parchment-like appearance of skin
- Small risk for developing squamous cell carcinoma.

Lichen Simplex Chronicus

- White plaque-like lesion (leukoplakia): Due to squamous cell hyperplasia
- Small risk for developing squamous cell carcinoma.

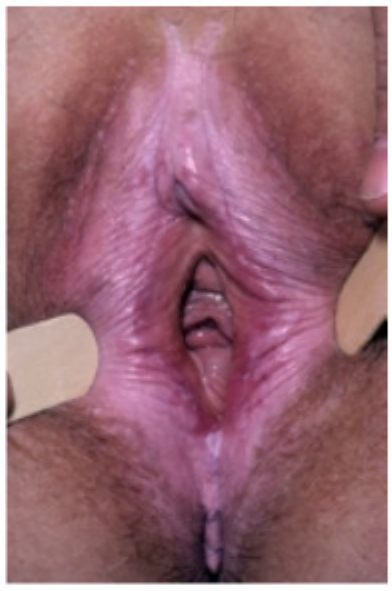

ISM/Phototake, Inc.

▲ **Figure 18–1.1**
Lichen Sclerosis

1.2 Malignancies of the Vulva

Squamous Cell Carcinoma The most common cancer of the vulva.

- Risk factors include:
  - HPV type 16
  - Smoking cigarettes
  - Immunodeficiency
- Metastasizes first to the inguinal nodes.

Paget Disease of the Vulva

- Red, crusted vulvar lesion
- Intraepithelial adenocarcinoma
  - Tumor derives from primitive epithelial progenitor cells.
  - Malignant Paget cells contain mucin, which stains positive for periodic acid-Schiff (PAS).

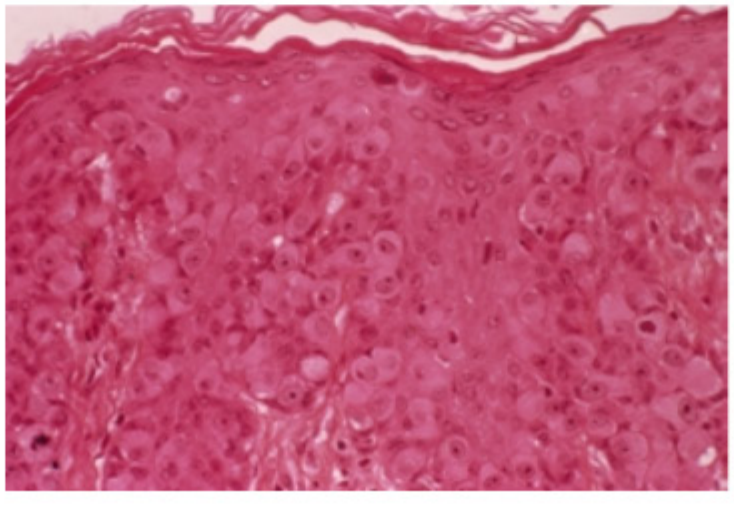

CNRI/Science Source

▶ **Figure 18–1.2**
Paget Disease

USMLE® Key Concepts

For Step 1, you must be able to:

- Identify vulvar, vaginal, cervical, uterine, fallopian, and ovarian pathologies.
- Differentiate among the various physiological and pathological bleeding conditions of the female reproductive tract.
- Explain the pathologies that can take place during pregnancy.
- Identify microbiological organisms causing pathologies of the female reproductive system.
- Differentiate among the various types of female breast pathologies.

Important Concept

Differential

Malignant melanoma of the vulva and Paget disease have similar histologic findings; however, PAS is negative for malignant melanoma.

Please visit us at www.Groupinsiders.com

© DeVry/Becker Educational Development Corp. All rights reserved.

2 Vaginal Disorders

2.1 Congenital Disorders of the Female Reproductive Tract

2.1.1 Rokitansky-Kuster-Hauser (RKH) Syndrome

- Absence of the upper vagina and uterus
- Anatomic cause of primary amenorrhea

2.1.2 Gartner Duct Cyst

- Remnant of the wolffian (mesonephric) duct
- Presents as a cyst on the lateral wall of the vagina

2.1.3 Vaginal Adenosis

- Remnants of müllerian glands
- Produces red, superficial ulcerations in the upper portion of the vagina
- Precursor lesion for clear cell adenocarcinoma

2.2 Malignancies of the Vagina

2.2.1 Embryonal Rhabdomyosarcoma

Occurs in girls less than 5 years old, with appearance of necrotic, grape-like mass protruding from the vagina.

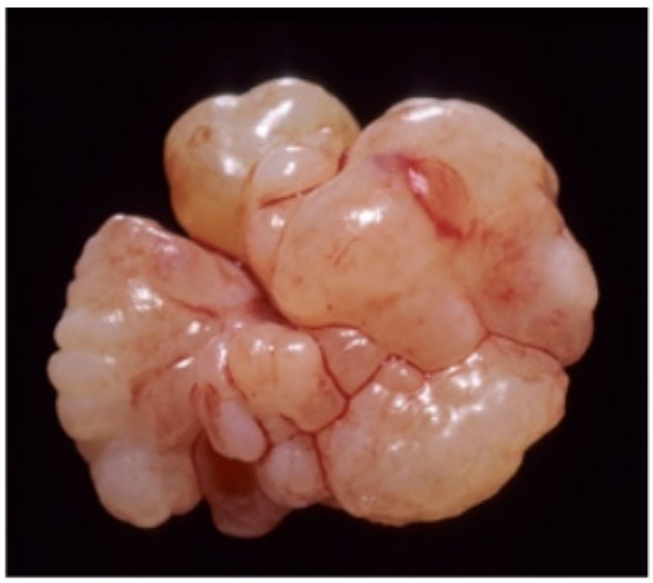

Custom Medical Stock Photo

▲ **Figure 18–2.2** Embryonal Rhabdomyosarcoma

2.2.2 Clear Cell Adenocarcinoma of the Vagina

Epidemiology

- Classically occurs in daughters of mothers who were exposed to diethylstilbestrol (DES).
- DES inhibits müllerian differentiation.

Connection to Pharmacology

See *Pharmacology*, chapter 9, "Endocrinology Drugs," topic 3.5 to read about diethylstilbestrol used to prevent miscarriages.

Please visit us at www.Groupinsiders.com

© DeVry/Becker Educational Development Corp. All rights reserved.

3 Cervical Disorders

- Cervix includes the endocervix and exocervix.
- Exocervix is normally lined by squamous epithelium.
- The endocervix is lined by mucus-secreting columnar epithelium, which normally migrates down to the exocervix.
- Exposure to the acid pH of the vagina produces squamous metaplasia.
- The area undergoing metaplasia is called the transformation zone, where squamous dysplasia and cancer develop. Metaplastic squamous cells block the endocervical gland orifice, which quite commonly produces nabothian cysts in adult women.

3.1 Cervical Intraepithelial Neoplasia (CIN)

Epidemiology

Majority of cases are associated with HPV.

- Low-risk types 6, 11.
- High-risk types 16, 18.
- HPV produces koilocytosis in squamous cells.
  - Clear halo containing a wrinkled, central pyknotic nucleus surrounded by a clear halo.
  - Peak incidence is 35 years of age.

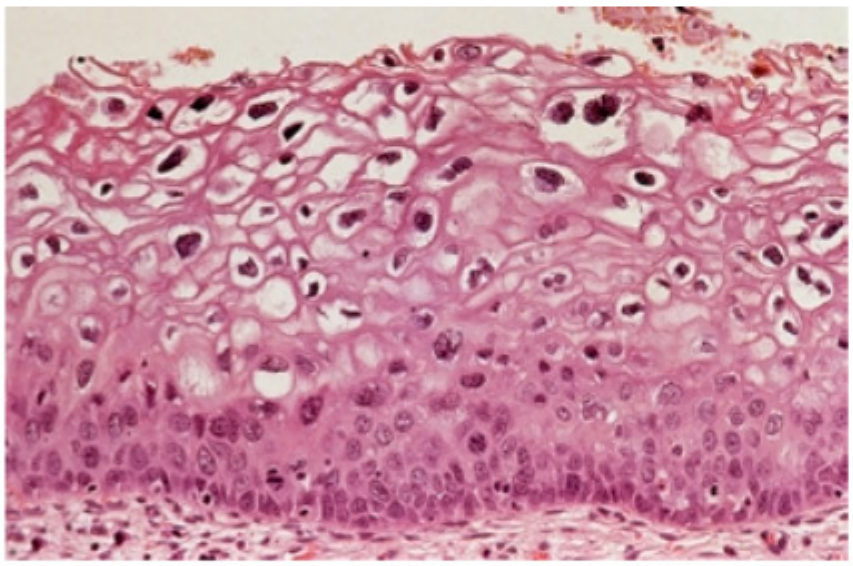

Wellcome Images

▲ **Figure 18–3.1** Koilocytosis in CIN

Risk Factors

- Early age of onset of sexual intercourse
- Multiple, high-risk partners
- High-risk types of HPV in a biopsy
- Smoking, oral contraceptive pills (OCPs)
- Immunodeficiency

Important Concept

Cervical Pap Smear

Purpose

- Screening test to rule out squamous dysplasia and cancer.
- To evaluate the hormone status of the patient.
- Sample sites include the vagina, exocervix, and transformation zone.

Interpretation of the Pap Smear

- *Superficial squamous cells* indicate adequate estrogen.
- *Intermediate squamous cells* indicate adequate progesterone.
- *Parabasal cells* indicate a lack of both estrogen and progesterone.

Clinical Scenarios

- *Normal, nonpregnant adult woman:* 70% superficial squamous cells, 30% intermediate squamous cells.
- *Pregnant woman:* 100% intermediate squamous cells from progesterone effect.
- *Elderly woman with lack of estrogen and progesterone:* Atrophic smear with parabasal cells and inflammation.
- *Woman with continuous exposure to estrogen without progesterone:* 100% superficial squamous cells.

Please visit us at www.Groupinsiders.com

© DeVry/Becker Educational Development Corp. All rights reserved.

Cervical Intraepithelial Neoplasia Type I Mild dysplasia involving the lower third of the epithelium.

Cervical Intraepithelial Neoplasia Type II Moderate dysplasia involving the lower two thirds of the epithelium.

Cervical Intraepithelial Neoplasia Type III Severe dysplasia to carcinoma in situ (CIS) involving the full thickness of the epithelium.

Progression from CIN I to CIN III is *not* inevitable.

- Reversal to normal is more likely in CIN I.
- Requires ~10 years to progress from CIN I to CIN III.
- Requires ~10 years to progress from CIN III to invasive cancer.

Clinical Findings

- Dysplasia is not usually visible to the naked eye; colposcopy is required.
- Occasionally, flat- to warty-appearing condyloma acuminata are visible.

3.2 Cervical Cancer

Epidemiology

- Least common gynecologic cancer due to early detection of CIN with Pap smears.
- In U.S. population, incidence is highest among the Hispanic population.
- Majority of cases are squamous cell carcinoma (75% to 80%).

Clinical Findings

- Includes abnormal vaginal bleeding originating from the cervical os.
- Malodorous discharge and may present with postcoital bleeding.
- Extends out into the lateral wall of the cervix and vagina, infiltrating the bladder wall and causing postrenal azotemia, leading to renal failure.

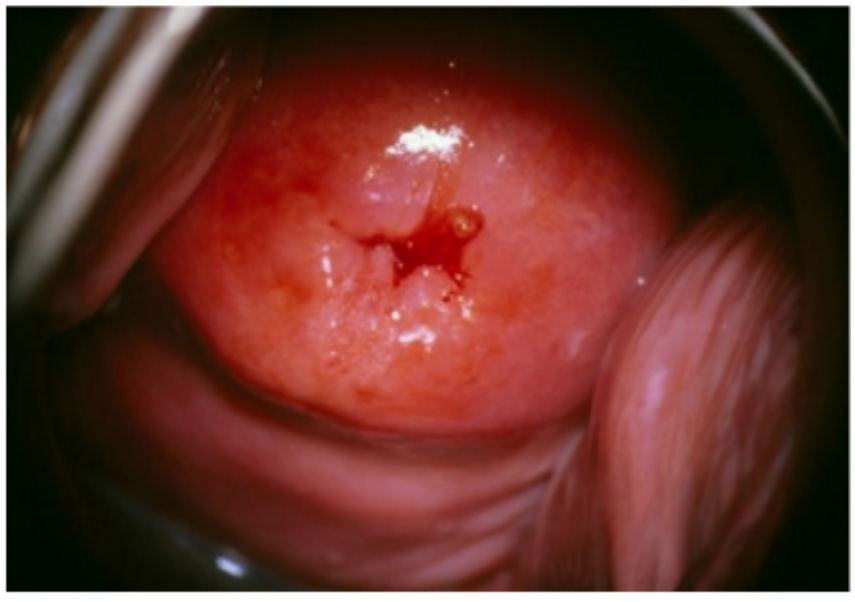

SPL/Science Source

▲ **Figure 18–3.2** Cervical Cancer

Please visit us at www.Groupinsiders.com

© DeVry/Becker Educational Development Corp. All rights reserved.

4 Reproductive Physiology

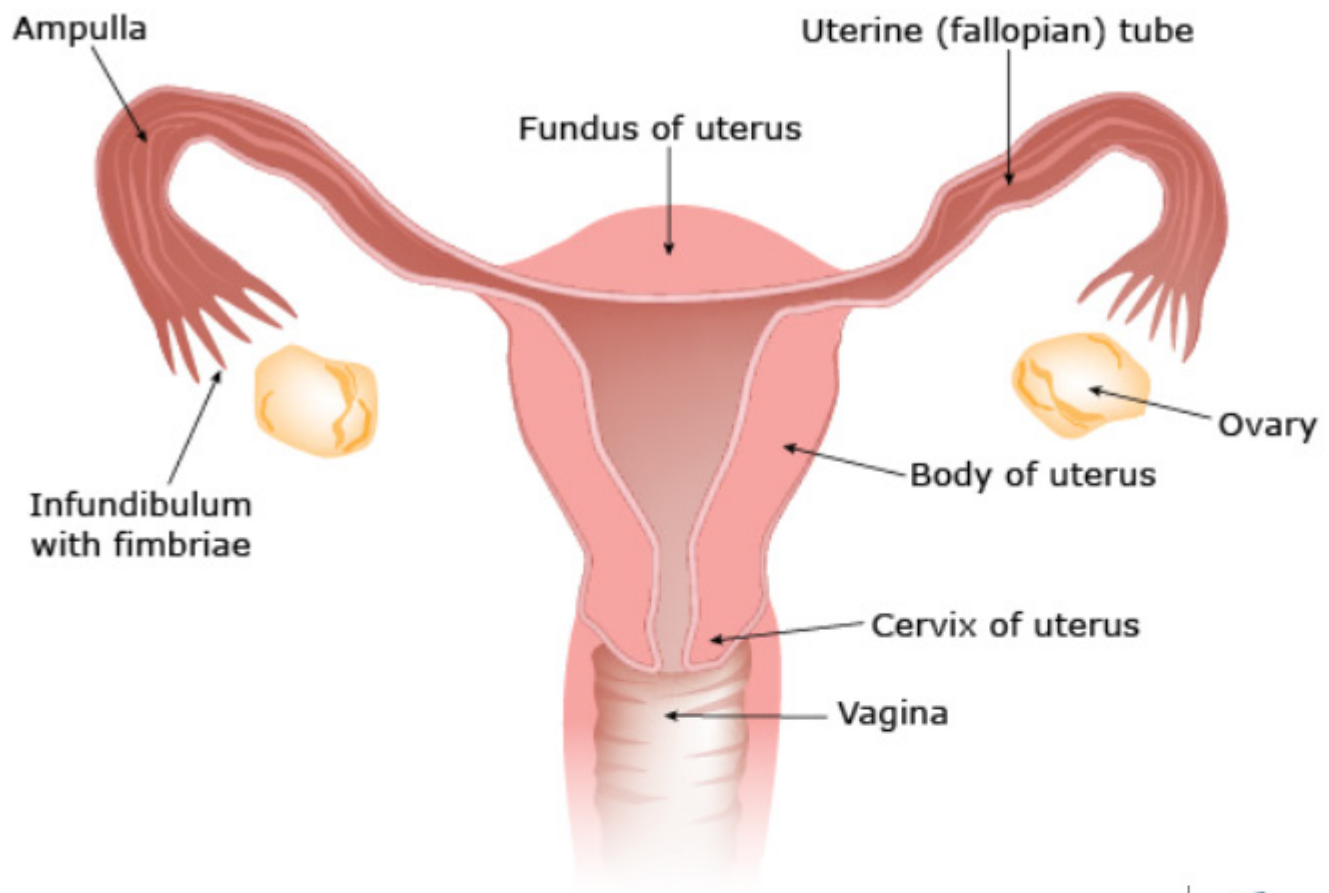

▲ **Figure 18–4.0A** Ovarian-Uterine System

Important Concept

Arias-Stella Phenomenon

Exaggerated secretory phase that occurs in pregnancy.

Please visit us at www.Groupinsiders.com

© DeVry/Becker Educational Development Corp. All rights reserved.

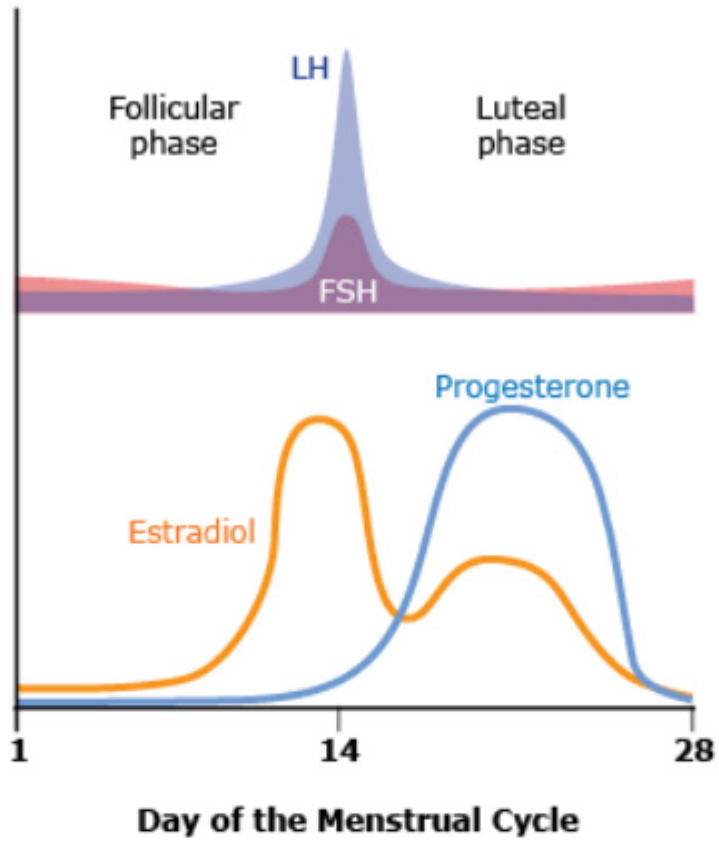

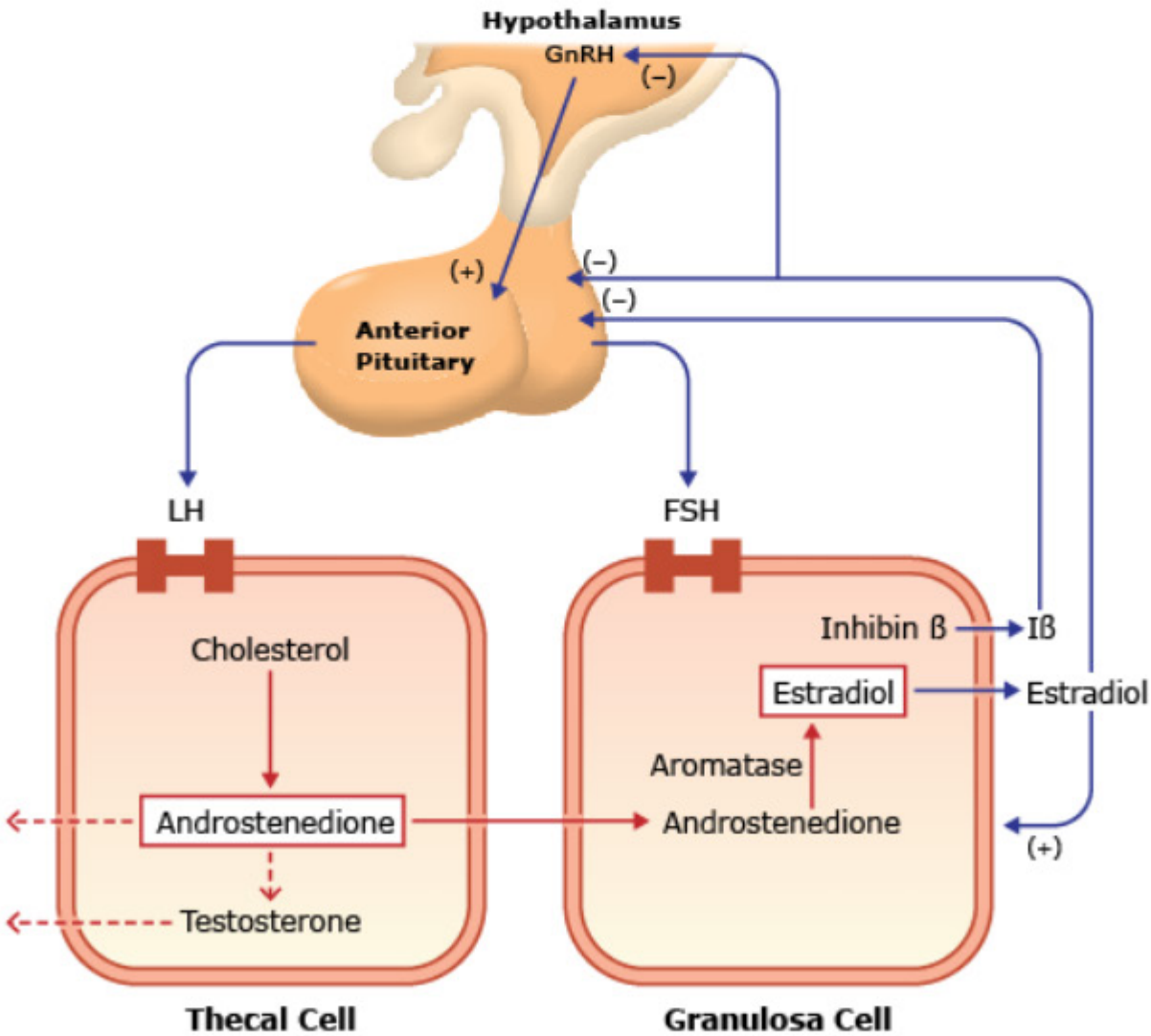

▲ **Figure 18–4.0B** Hormone Secretions of the Follicular Phase

Please visit us at www.Groupinsiders.com

© DeVry/Becker Educational Development Corp. All rights reserved.

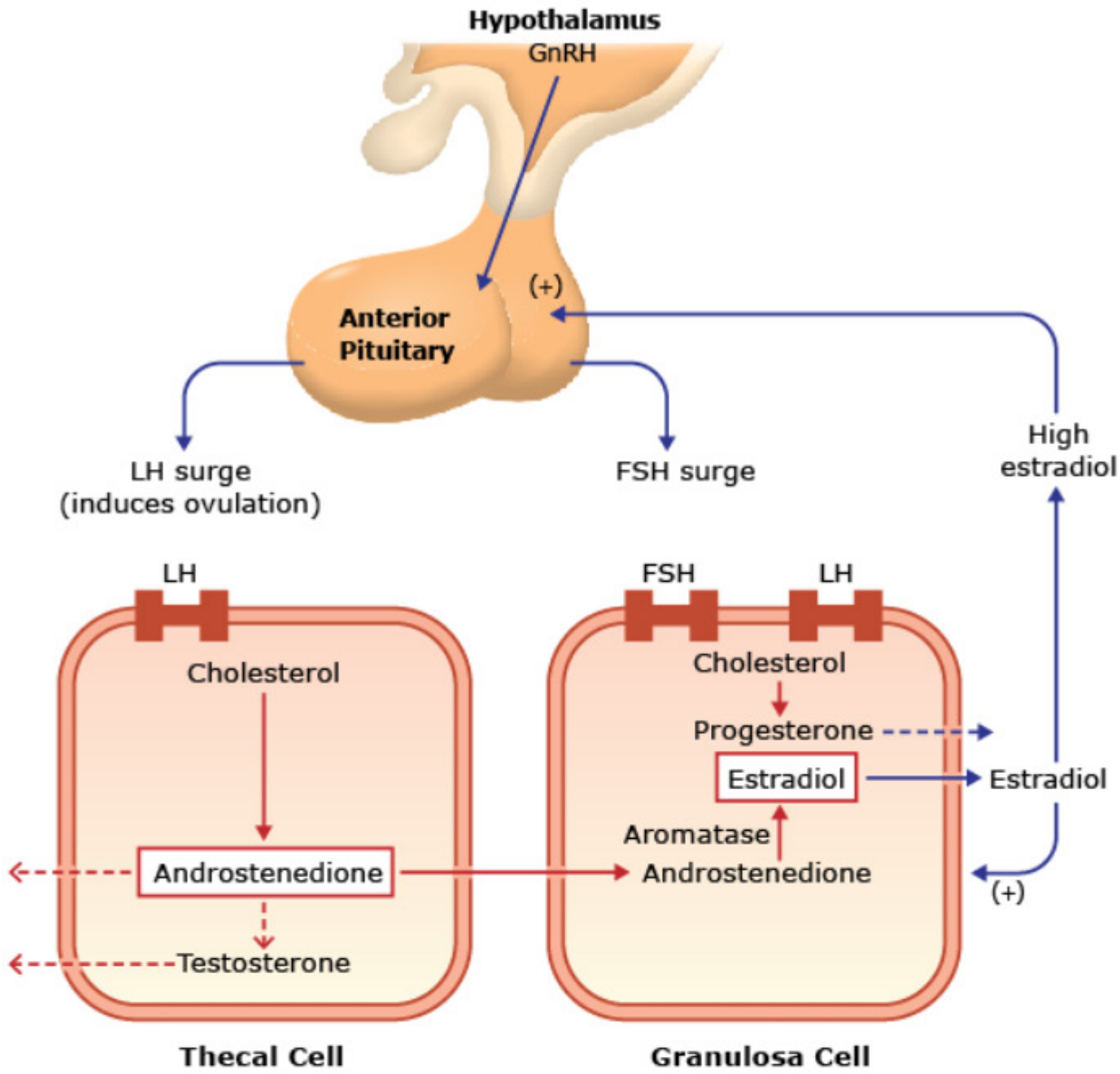

▲ **Figure 18–4.0C** Hormone Secretions and Ovulation

Please visit us at www.Groupinsiders.com

© DeVry/Becker Educational Development Corp. All rights reserved.

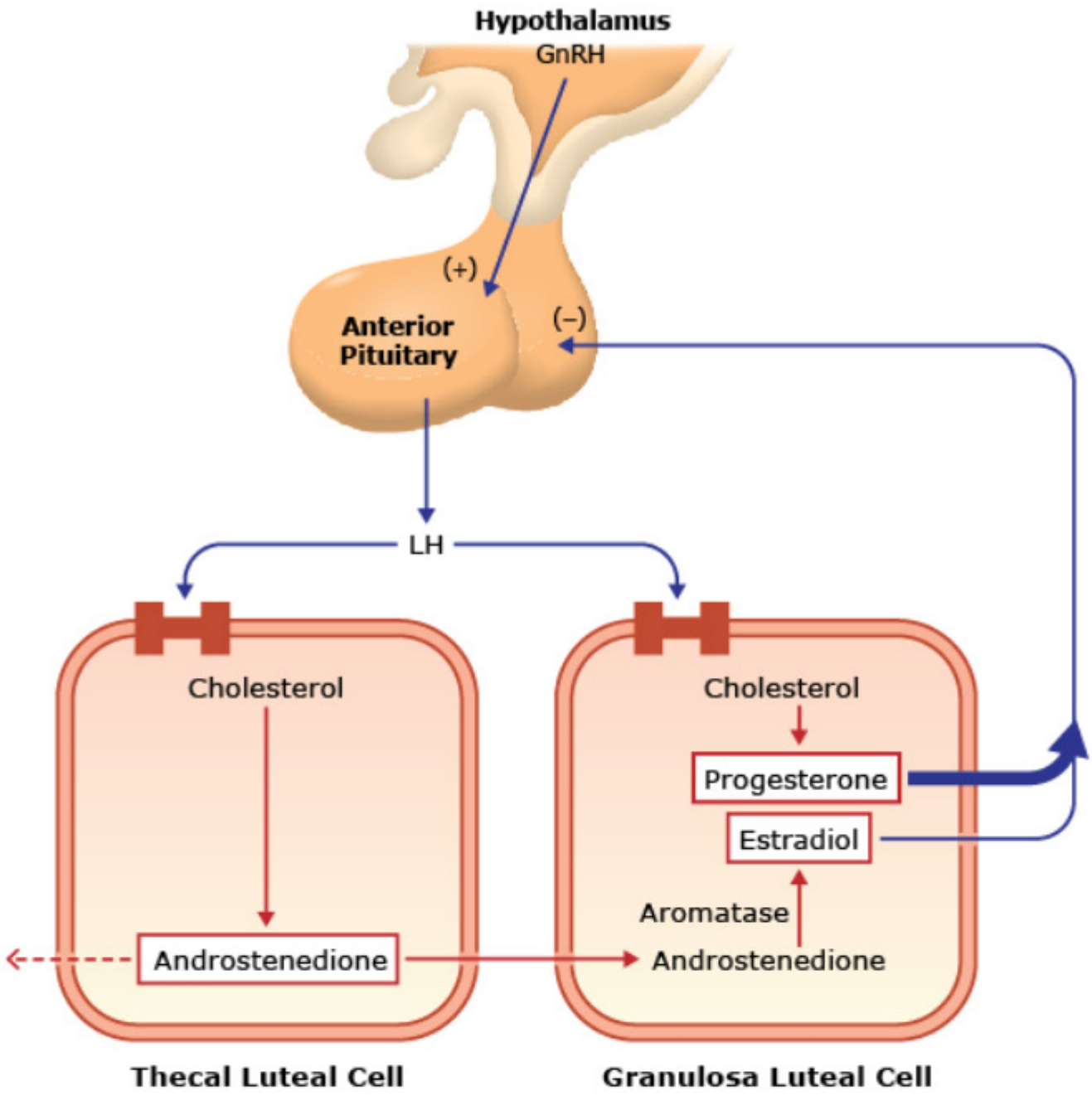

▲ **Figure 18–4.0D** Hormone Secretions of the Luteal Phase

Please visit us at www.Groupinsiders.com

© DeVry/Becker Educational Development Corp. All rights reserved.

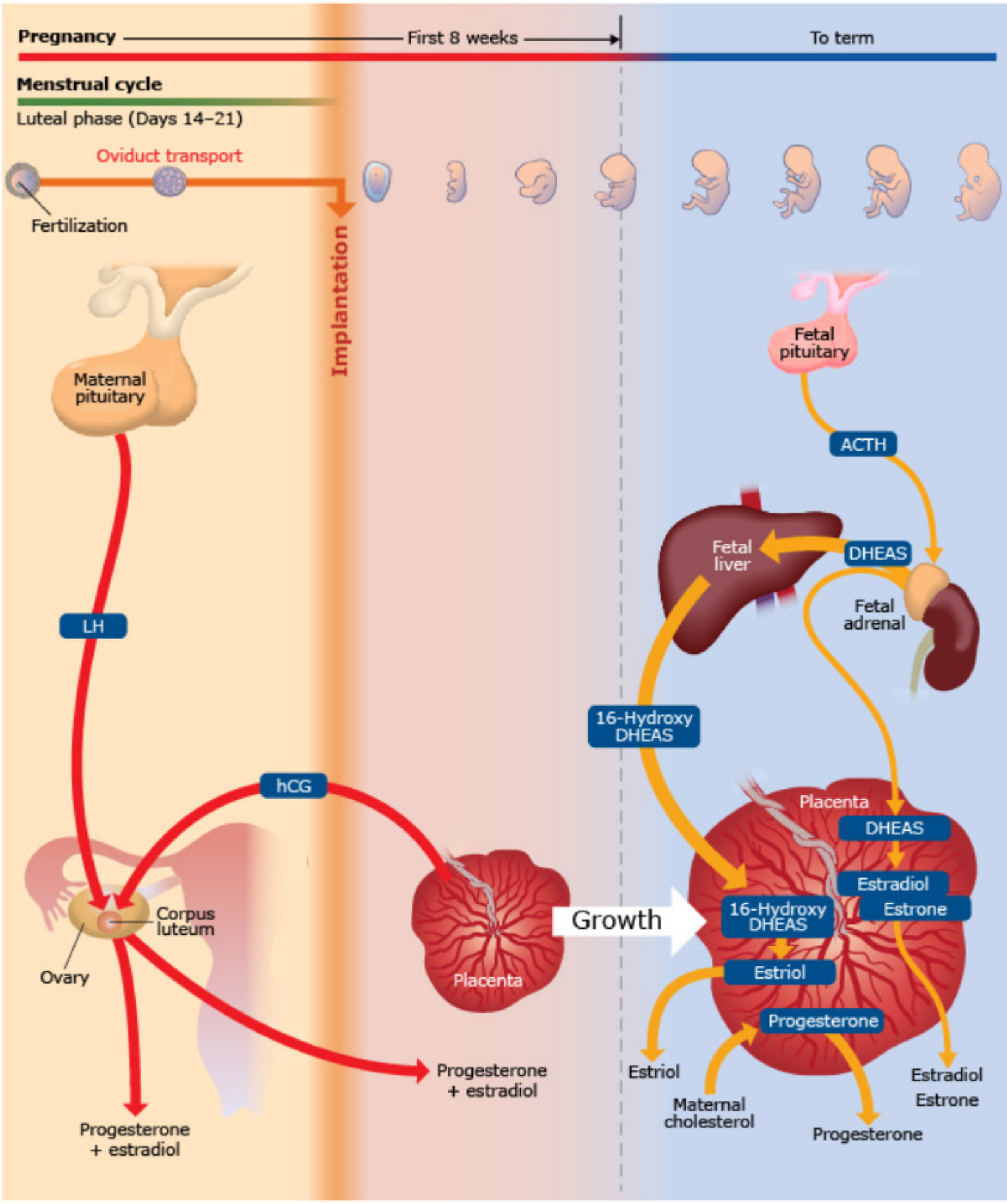

▲ **Figure 18–4.0E** Hormonal Maintenance of Pregnancy

Please visit us at www.Groupinsiders.com

© DeVry/Becker Educational Development Corp. All rights reserved.

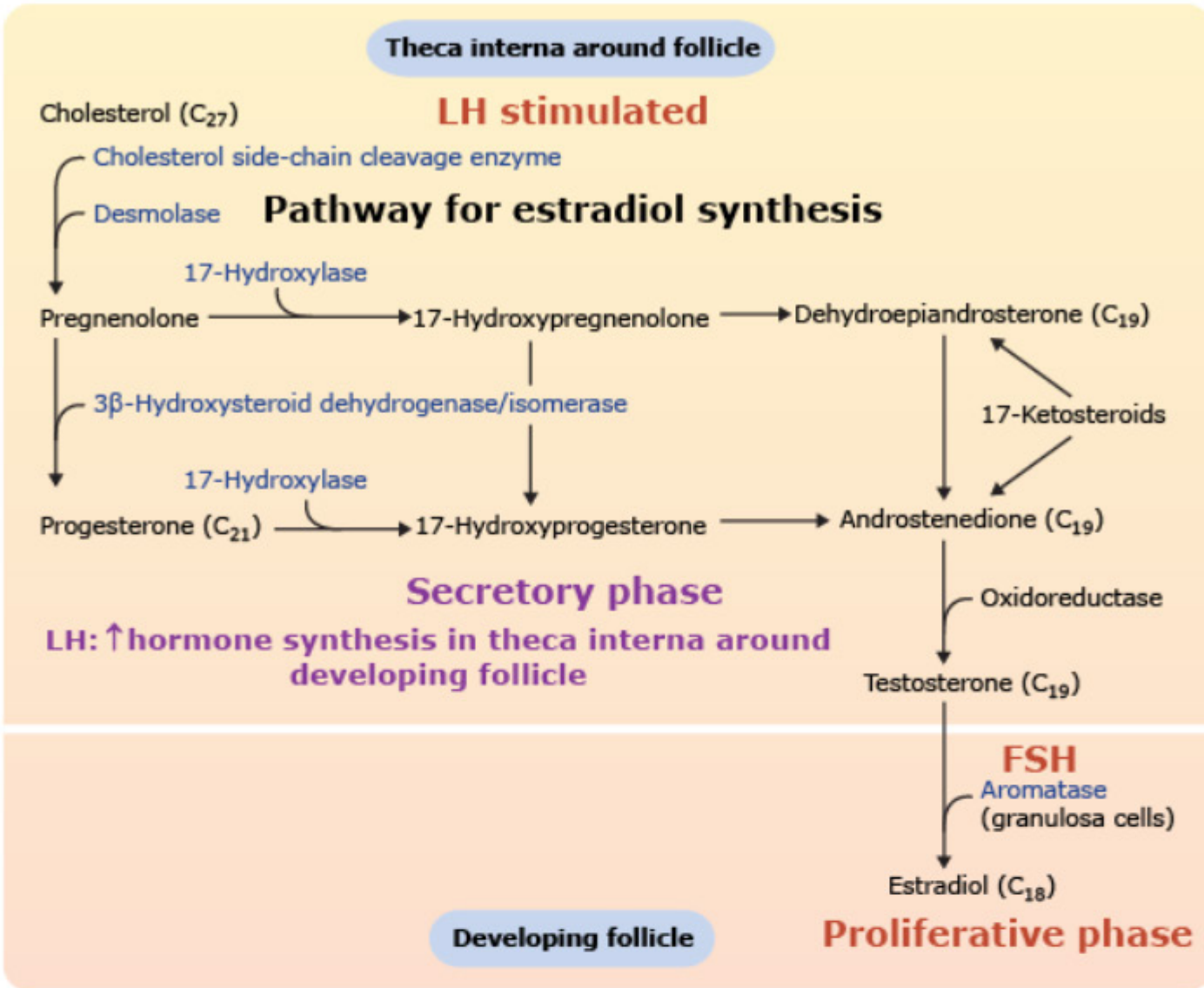

▲ **Figure 18–4.0F** Theca Interna Around Developing Follicle

Please visit us at www.Groupinsiders.com

© DeVry/Becker Educational Development Corp. All rights reserved.

5 Effects of Pregnancy

- Greater increase in plasma volume to RBC mass ratio causes a dilutional effect on hemoglobin and RBC count and causes an increased GFR.
- ↑ serum T_4/cortisol; due to increase in binding proteins.

6 Menopause

Epidemiology Defined as no menses for one year, after age 40.

Causes

- Physiologic
- Decreased ovarian function; waning levels of estrogen levels; depletion of granulosa and thecal cells; lack of response to gonadotropins.
- Surgical removal/radiation of ovaries
- Turner syndrome

Clinical Findings Secondary Amenorrhea

- Hot flushes, night sweats
- Atrophic vaginitis
- Pruritus, burning, bleeding, dyspareunia
- Mood swings, anxiety, depression, insomnia, decreased libido
- Increased risk for osteoporosis

Laboratory Findings

- Serum FSH is the best marker.
  - Decreased serum estradiol

Please visit us at www.Groupinsiders.com

© DeVry/Becker Educational Development Corp. All rights reserved.

7 Hirsutism and Virilization

- *Hirsutism* is excess hair in normal hair-bearing areas.
- *Virilization* is hirsutism plus male secondary sex characteristics. Male secondary sex characteristics:
  1. Increased muscle mass
  2. Acne
  3. Clitoromegaly is the most important finding.
- Both conditions are due to increased androgens of ovarian or adrenal origin.

▼**Table 18–7.0** Hirsutism vs. Virilization

	Testosterone/FT	DHEA-S
Ovary	Increased	Normal
Adrenal	Increased	Increased

Dr. P. Marazzi/Science Source/Custom Medical Stock Photo

▲**Figure 18–7.0A** Hirsutism

Please visit us at www.Groupinsiders.com

© DeVry/Becker Educational Development Corp. All rights reserved.

Polycystic Ovary Syndrome (PCO)

PCO is the primary cause of hirsutism and virilization.

Epidemiology

- Occurs in 3% of adolescents and adults.
- Symptoms begin around menarche.
- Increased risk of endometrial cancer.

Pathogenesis

- Increased pituitary synthesis of LH along with decreased synthesis of FSH, therefore increasing androgen synthesis.
- Hirsutism occurs more often than virilization.
- Androgens are aromatized to estrogen in the adipose cells, thus increasing the risk for endometrial carcinoma.
- Increased estrogen has a positive feedback on LH and negative feedback on FSH.
- Suppression of FSH causes follicle degeneration.
- Fluid accumulation produces subcortical cysts that enlarge the ovaries.

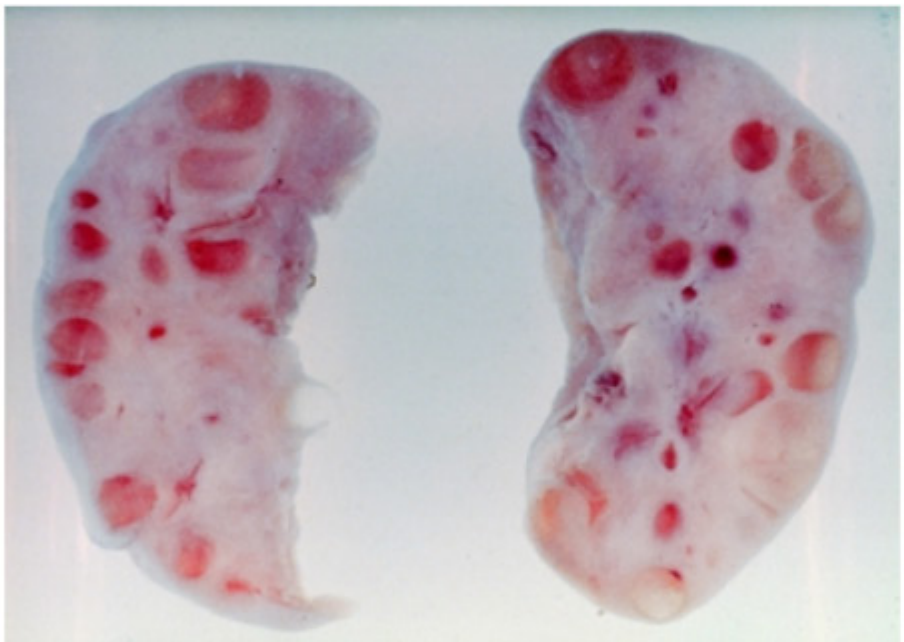

Biophoto Associates/Science Source

▲ **Figure 18–7.0B** Polycystic Ovarian Syndrome

Clinical Findings

- Oligomenorrhea is the most common complaint.
- Hirsutism, infertility, obesity (40% to 50%)

Laboratory Findings

- LH: FSH ratio >2
- Increased serum testosterone (free and total) and androstenedione
- Increased serum estrogen

Connection to Pharmacology

The goal is to reduce the effects of testosterone and estrogen:

- Weight loss
- Low-dose OCP to suppress the gonadotropin axis
- Spirnolactone
- LH-releasing analogues

Please visit us at www.Groupinsiders.com

© DeVry/Becker Educational Development Corp. All rights reserved.

8 Menstrual Dysfunction

8.1 Dysmenorrhea

Refers to painful menses.

Epidemiology

- Approximately 50% of women have dysmenorrhea.
- Approximately 10% are incapacitated for one to three days.

8.1.1 Primary Type

- Only occurs in ovulatory cycles.
- Primary dysmenorrhea is due to presence of $PGF_{2\alpha}$ resulting in increased uterine contractions.

8.1.2 Secondary Type

- Endometriosis is the most common cause.
- Adenomyosis
- Leiomyomas

8.2 Dysfunctional Uterine Bleeding (DUB)

- Abnormal uterine bleeding *unrelated* to an anatomic cause.
- *Diagnosis of exclusion*.

8.2.1 Anovulatory DUB

Majority of the cases are anovulatory, with most cases occurring at extremes of reproductive life, including postmenarche/perimenopausal.

- Unopposed estrogen action is the cause in these patients.

8.2.2 Two Types of Ovulatory DUB

1. Inadequate development of the corpus luteum results in decreased progesterone and thus luteal (secretory) phase.
2. Irregular shedding of endometrium results from persistent luteal phase.

Important Concept

Treatment is based on the proper development of the follicle seen on the ultrasound, which would then determine the need for either *progesterone* or *clomiphene sulfate*.

Please visit us at www.Groupinsiders.com

© DeVry/Becker Educational Development Corp. All rights reserved.

8.3 Types of Abnormal Bleeding in DUB

- **Menorrhagia** refers to losing greater than 80 mL of blood per period with excessive passage of clots.
  - Clinical findings include staining of sheets at night even with protection.
- **Hypomenorrhea** decreased amount of bleeding during normal cycle
- **Metrorrhagia** excessive flow and duration at irregular intervals
- **Menometrorrhagia** combination of menorrhagia and metrorrhagia
- **Oligomenorrhea** intervals >35 days
- **Polymenorrhea** includes short intervals <21 days

Important Concept

For Step 1, you must know that passage of excessive clots should indicate *plasmin does not* have sufficient time to completely dissolve the clot.

▼Table 18–8.3 Causes of Abnormal Bleeding by Age

Age Bracket	Causes of Bleeding
Prepubertal	Vulvovaginitis
	Embryonal rhabdomyosarcoma
Menarche to 20 years	Anovulatory DUB (most common cause)
	Von Willebrand disease
20–40 years	Pregnancy and its complications (most common cause)
	Both types of ovulatory DUB
	PID, hypothyroidism, submucosal leiomyomas, adenomyosis, endometrial polyp, endometriosis
≥40 years	Anovulatory DUB (most common cause in perimenopausal period)
	Endometrial hyperplasia/cancer (most common cause in menopause)

8.4 Amenorrhea

8.4.1 Primary Amenorrhea

- Absence of menses by 16 years of age.
- Most cases are due to constitutional delay; family history of delayed onset of menses.

8.4.2 Secondary Amenorrhea

- Absence of menses for three months.
- Most cases are due to pregnancy.

Please visit us at www.Groupinsiders.com

© DeVry/Becker Educational Development Corp. All rights reserved.

▼Table 18–8.4 Differentials of Amenorrhea

Disorder	FSH/LH	Estrogen	Pathogenesis	Comments	Examples
Hypothalamic/ pituitary disorder	↓	↓	Hypogonadotropic hypogonadism	No withdrawal bleeding after receiving progesterone.	Hypopituitarism, anorexia nervosa, prolactinoma
Ovarian disorder	↑	↓	Hypergonadotropic hypogonadism	No withdrawal bleeding after receiving progesterone.	Turner syndrome
End-organ defect	N	N	Normal gonadotropic axis	Most likely a primary amenorrhea cause. No withdrawal bleeding after receiving progesterone.	Imperforate hymen, Asherman syndrome, Rokitansky-Küster-Hauser syndrome
Constitutional delay	N	N	Family history of delayed onset of menses.		

Credit: Wellcome Images/Custom Medical Stock Photo

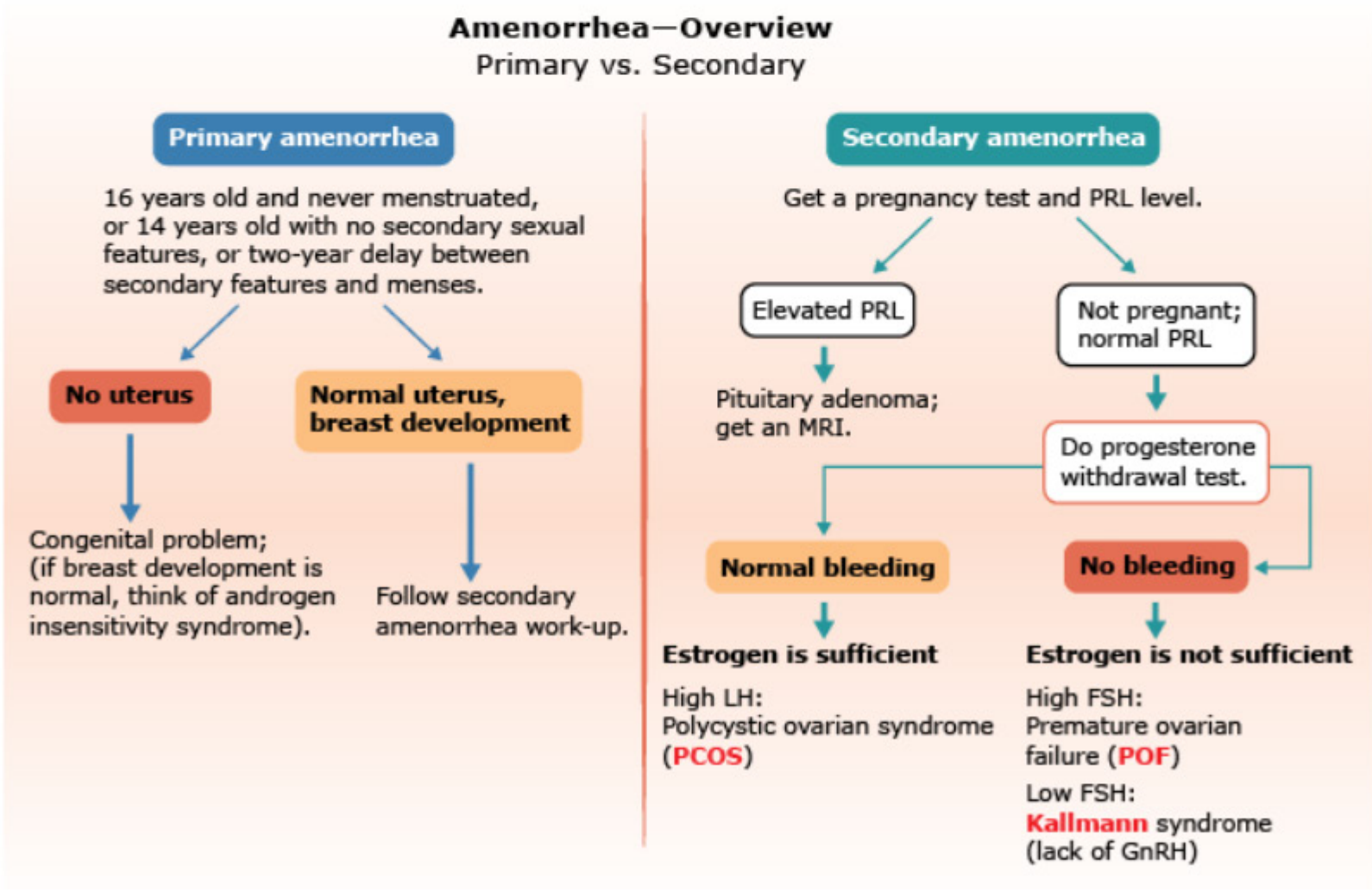

▲Figure 18–8.4 Amenorrhea

Please visit us at www.Groupinsiders.com

© DeVry/Becker Educational Development Corp. All rights reserved.

9 Uterine Disorders

9.1 Adenomyosis

Pathogenesis

- Invagination of the stratum basalis into the myometrium.
- Glands and stroma thicken myometrial tissue.
- Produces uterine enlargement.
- Highest incidence in women in mid-to-late 40s.
- Common finding in hysterectomy specimens.

Clinical Findings

- Menorrhagia, dysmenorrhea, pelvic pain
- Definitive diagnosis with myometrial biopsy.
- Treatment is hysterectomy.

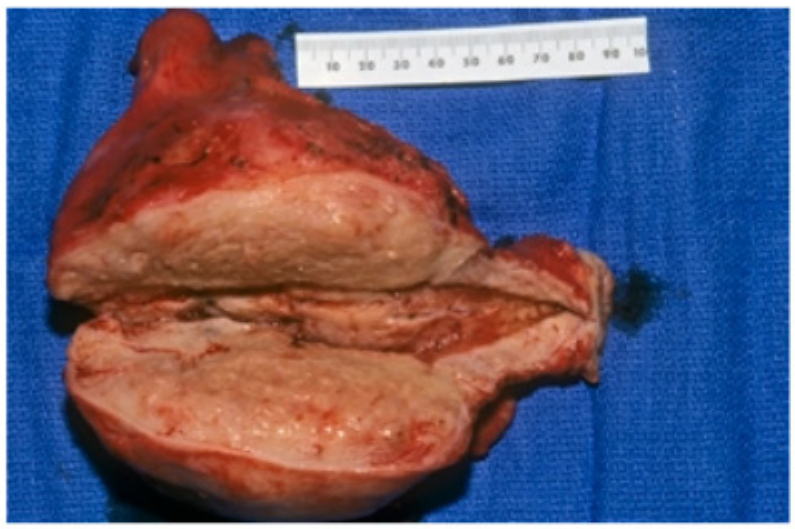

Dr. Daniel Logery/Visuals Unlimited, Inc.

▲ **Figure 18–9.1** Adenomyosis

9.2 Endometriosis

Epidemiology

- Functioning glands and stroma are located *outside* the uterus.
- Cyclic bleeding of gland and stromal implants.
- Prevalence is highest in women with dysmenorrhea (40% to 60%).
- Average age at time of diagnosis is 25 to 29 years old.
- Multifactorial inheritance has been implicated.

Pathogenesis

- Reverse menses through fallopian tubes
- Implantation of viable endometrial cells
- *Coelomic metaplasia*
- Common sites include the ovaries (most frequently), rectal pouch, fallopian tubes, intestine.

Please visit us at www.Groupinsiders.com

© DeVry/Becker Educational Development Corp. All rights reserved.

Clinical Findings

- Dysmenorrhea (most common), dyspareunia, and infertility
- Abnormal bleeding
- Premenstrual spotting, menorrhagia
- Painful stooling during menses
  - Implants located in rectal pouch
- Intestinal obstruction and bleeding during menses
- Increased risk for ectopic pregnancy
- Enlargement of ovaries

Diagnosis

- Laparoscopy useful for diagnosis and treatment
- Increased serum cancer antigen 125 (CA125)
  - Increased false positive results

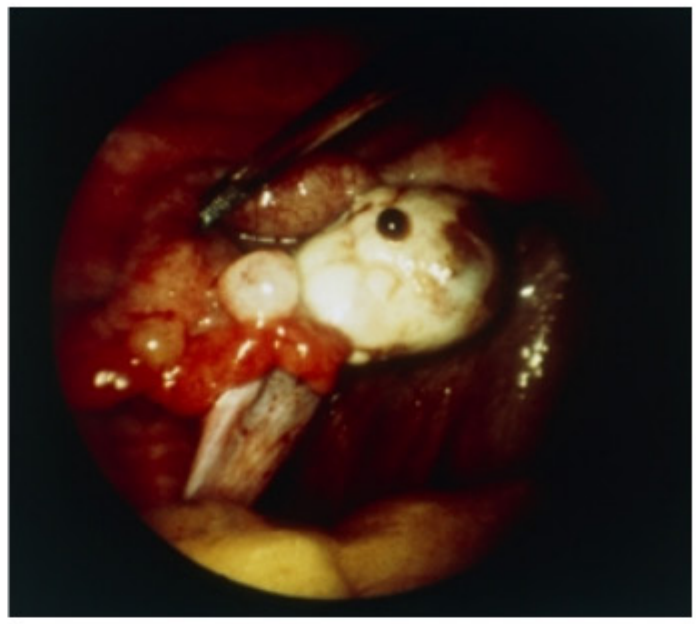

CNRI/Science Source

▲ **Figure 18–9.2** Intestinal Obstruction Found With Endometriosis

9.3 Endometrial Hyperplasia

Epidemiology and Pathogenesis Prolonged estrogen stimulation

Risk Factors

- Early menarche or late menopause
- Nulliparity with increased number of menstrual cycles
- Obesity
- Polycystic ovary syndrome
- Taking estrogen without progesterone
- Anovulatory menstrual cycles
- Hereditary nonpolyposis colon cancer (Lynch syndrome)

Classification

- Simple hyperplasia
- Increased number of cystically dilated glands
- *No* glandular crowding

Clinical Findings

- Menorrhagia, metrorrhagia, menometrorrhagia
- Postmenopausal bleeding

Please visit us at www.Groupinsiders.com

© DeVry/Becker Educational Development Corp. All rights reserved.

9.4 Endometrial Carcinoma

Epidemiology and Pathogenesis

- Most common gynecologic tumor
- Median age at onset, 60 years old
- Prolonged estrogen stimulation
- Same risk factors as endometrial hyperplasia
- Oral contraceptives and pregnancy decrease risk.
- Well-differentiated adenocarcinoma is the most common type of endometrial carcinoma.

Cancer Characteristics

- Spreads down into the endocervix.
- Spreads out into the uterine wall.
- Lungs are the most common site of metastasis.

Clinical Findings Postmenopausal bleeding (90%)

9.5 Leiomyoma

Epidemiology

- Most common benign connective tissue tumor in women.
- Most frequently diagnosed gynecologic tumor.
- Occurs in 20% to 50% of women >30 years old with greater prevalence in African-American women.
- Estrogen-sensitive tumors.
- May become larger during pregnancy.

▲ **Figure 18–9.5** Leiomyoma

Tumor Characteristics Commonly undergo the following degeneration leading to dystrophic calcification, followed by hyalinization, designating its name as "fibroids."

Please visit us at www.Groupinsiders.com

© DeVry/Becker Educational Development Corp. All rights reserved.

10 Fallopian Tube Disorders

10.1 Ectopic Pregnancy

Epidemiology and Pathogenesis

- Implantation of a fetus outside the normal uterine location
- Occurs in 1% to 2% of pregnancies
- Accounts for 13% of maternal deaths

Risk Factors

- The most common cause of ectopic pregnancy is scarring from previous PID.
- Endometriosis
- Sites of implantation
  - Majority occur within the tubes.
  - Most are in the broad ampullary portion below the fimbriae.

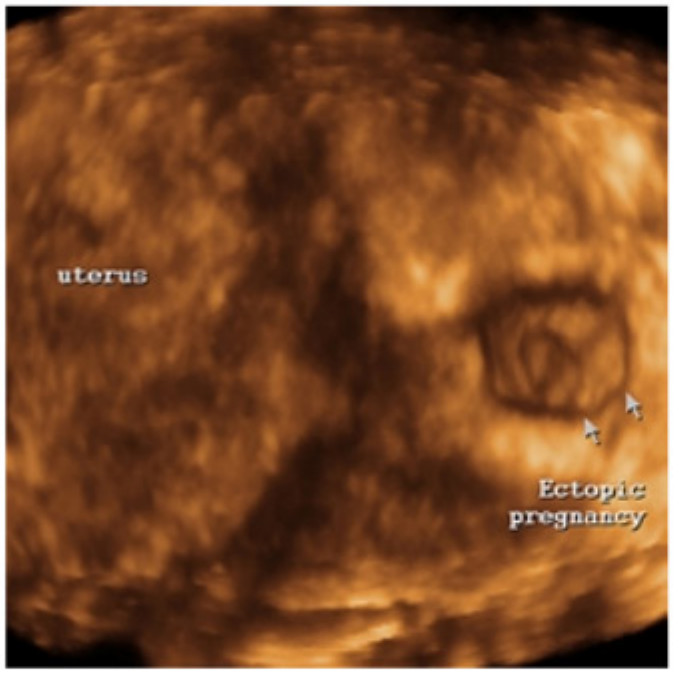

Dr. Najeeb Layyous/Science Source

▲ **Figure 18–10.1** Ectopic Pregnancy

Clinical Findings

- Classic triad—vaginal bleeding, pelvic pain, adnexal tenderness
- Sudden onset of lower abdominal pain and tenderness (95%)
  - Usually approximately six weeks after a previous normal menstrual period
- Adnexal tenderness
- Rebound tenderness indicating peritoneal sign
- Abnormal uterine bleeding
- The most common cause of death from an ectopic pregnancy is intraperitoneal bleeding from a rupture.

Diagnosis

- β-hCG is the best screening test.
- Vaginal ultrasound is the confirmatory test.

Please visit us at www.Groupinsiders.com

© DeVry/Becker Educational Development Corp. All rights reserved.

11 Ovarian Disorders

11.1 Ovarian Tumors

Epidemiology and Pathogenesis

- Tumors are more likely benign in women <45 years of age.
- Risk increases with age.
- Median age of presentation is 61 years of age.
- Peaks in the late 70s.
- Approximately 60% present with advanced disease.

Risk Factors

- **Nulliparity**
  - Increased number of ovulatory cycles increases risk.
  - Increased risk for surface-derived ovarian tumors.
- **Genetic Factors**
  - Mutations of *BRCA1* and *BRCA2* suppressor genes.
  - Lynch syndrome
  - Turner syndrome
    —Increased risk for dysgerminoma.
  - Peutz-Jeghers syndrome
    —Increased incidence of sex cord tumors with annular tubules.
- Increased risk in postmenopausal women on HRT estrogen therapy.
- Increased risk in obese women.
- OCPs/pregnancy decrease risk for surface-derived ovarian cancers due to decreased number of ovulatory cycles.

11.2 Classification of Ovarian Tumors

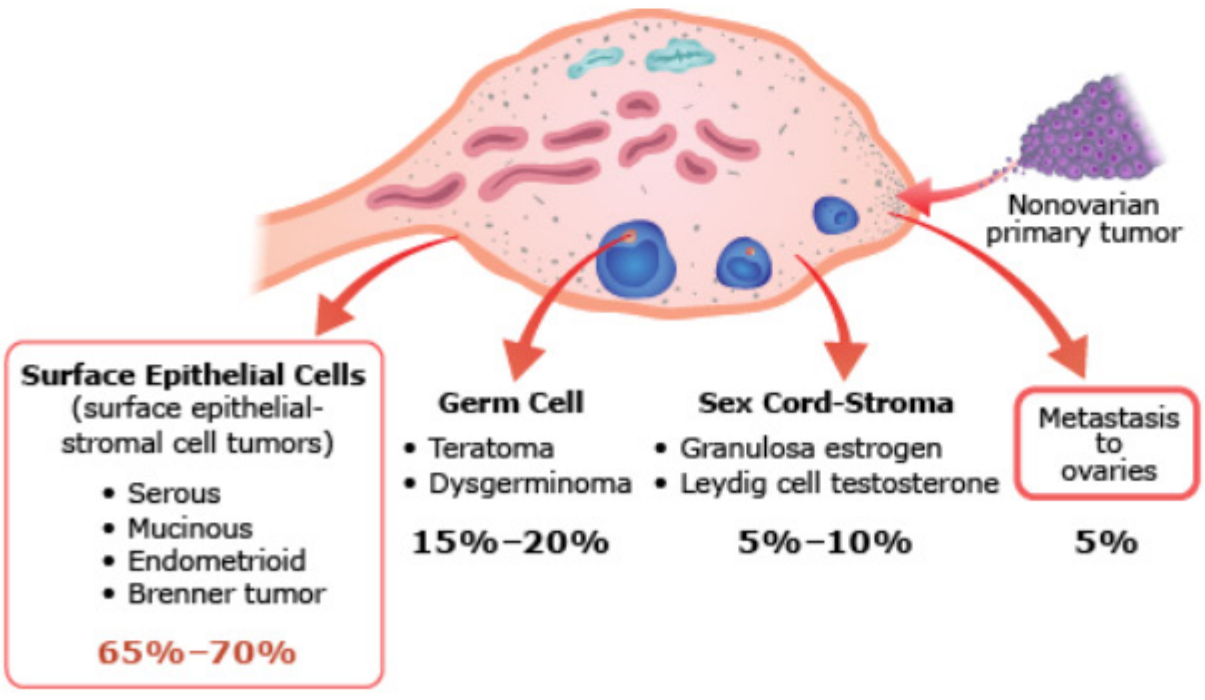

▲ **Figure 18–11.2** Classification of Ovarian Tumors

Please visit us at www.Groupinsiders.com

© DeVry/Becker Educational Development Corp. All rights reserved.

▼Table 18–11.2 Classification of Ovarian Tumors

A. Surface-Derived Tumors	
Serous tumors	• Most common group of primary benign and malignant tumors
	• Most common group of tumors that can be bilateral
	• Cysts are lined by ciliated cells (similar to fallopian tube)
	• Serous cystadenoma is the most common benign ovarian tumor • Serous cystadenocarcinoma is the most common malignant tumor that is bilateral and contains psammoma bodies
Mucinous tumors	• Cysts lined by mucus-secreting cells
	• Seeding produces pseudomyxoma peritonei
	• Mucinous cystadenoma that may be associated with Brenner tumors
Endometrioid	• Malignant tumors associated with endometrial carcinoma
	• Commonly bilateral
Brenner tumor	• Usually benign
	• Contain Walthard rests containing transitional-like epithelium
B. Germ Cell Tumors	
Cystic teratoma	• Most common benign germ cell tumor
	• Less than 1% become malignant (usually squamous cancer)
	• Ectodermal, mesodermal, and endodermal differentiation
	• Most of these derivatives are found in a nipple-like structure in the cyst wall called Rokitansky tubercle
	• Struma ovarii type has functioning thyroid tissue
Dysgerminoma	• Most common malignant germ cell tumor; characteristic increase in serum LDH; same histologic picture as seminoma of testis
	• Associated with streak gonads of Turner syndrome
Yolk sac tumor	• Malignant tumor; most common ovarian cancer in girls <4 years old
	• Contain Schiller-Duval bodies (resemble yolk sac)
	• Increased α-fetoprotein
C. Sex-Cord Stromal Tumors	
Thecoma-fibroma	• Benign tumor associated with Meigs syndrome —Ascites, right-sided pleural effusion —Regression of effusion follows removal of tumor
Granulosa-theca cell tumor	• Low-grade malignant tumor
	• Feminizing tumor (produces estrogen) that contains Call-Exner bodies
Sertoli-Leydig cell	• Benign masculinizing tumor (produces androgens)
	• Pure Leydig cell tumors contain cells with crystals of Reinke
Gonadoblastoma	Malignant tumor with mixture of germ cell tumor (dysgerminoma) and sex-cord stromal tumor; associated with abnormal sexual development in 80% of cases
D. Tumors Metastatic to Ovary	
Krukenberg tumor	May affect both ovaries; contains signet-ring cells from hematogenous spread of a gastric cancer

Please visit us at www.Groupinsiders.com

© DeVry/Becker Educational Development Corp. All rights reserved.

12 Gestational Disorders

12.1 Placental Overview

Fetal Surface

- Entirely covered by the chorionic plate.
- Chorionic villi vessels converge with the umbilical cord.
- Chorion is covered by the amnion.

Maternal Surface

- Contains cotyledons covered by a layer of decidua basalis.
- Chorionic villi project in the intervillous space enabling them to extract oxygen that is supplied by maternal blood.
- Outside layer is composed of syncytiotrophoblast, which synthesizes human chorionic gonadotropin (hCG) and also human placental lactogen (hPL) exerting anti-insulin activity.

12.2 Placental Abnormalities

12.2.1 Placenta Previa

Epidemiology

- Implantation of placenta over the cervical os.
- Risk factor includes previous cesarean section.

Clinical Findings

- Mother presents with painless vaginal bleeding.
- Usually in second or third trimester.
- Uterus soft and nontender.
- Fetal distress usually not present.

Diagnosis

- Pelvic examination should *not* be performed.
- Transvaginal ultrasound confirms placenta previa.

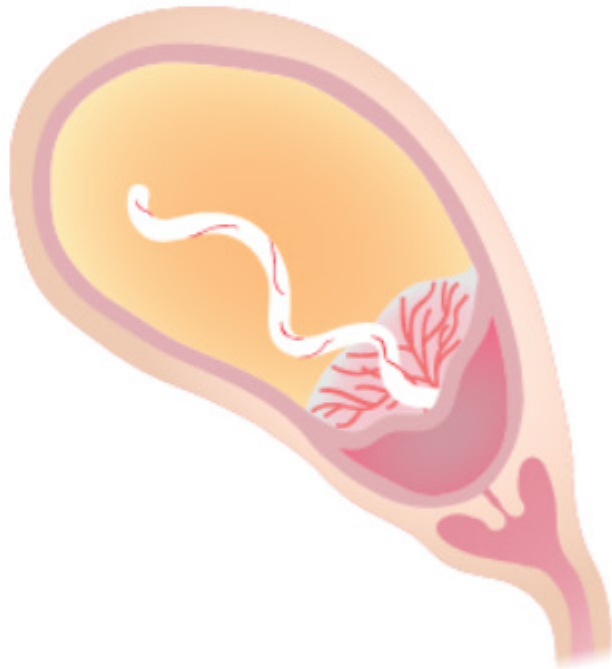

▲ **Figure 18–12.2A** Placenta Previa

Please visit us at www.Groupinsiders.com

© DeVry/Becker Educational Development Corp. All rights reserved.

12.2.2 Abruptio Placentae

Epidemiology

- Premature separation of placenta due to formation of a retroplacental clot.
- Most common cause of *late* pregnancy bleeding.
- Occurs in 1 in 830 pregnancies.
- Fetal mortality rate is 20% to 40%.

Risk Factors

- Hypertension is the greatest risk factor in 40% to 50% of cases.
- Smoking cigarettes
- Cocaine addiction; advanced maternal age
- Trauma; chorioamnionitis

Clinical Findings

Abruptio placentae triad: painful vaginal bleeding, tetanic contractions, fetal compromise.

Diagnosis

- Pelvic examination should *not* be done.
- Ultrasound

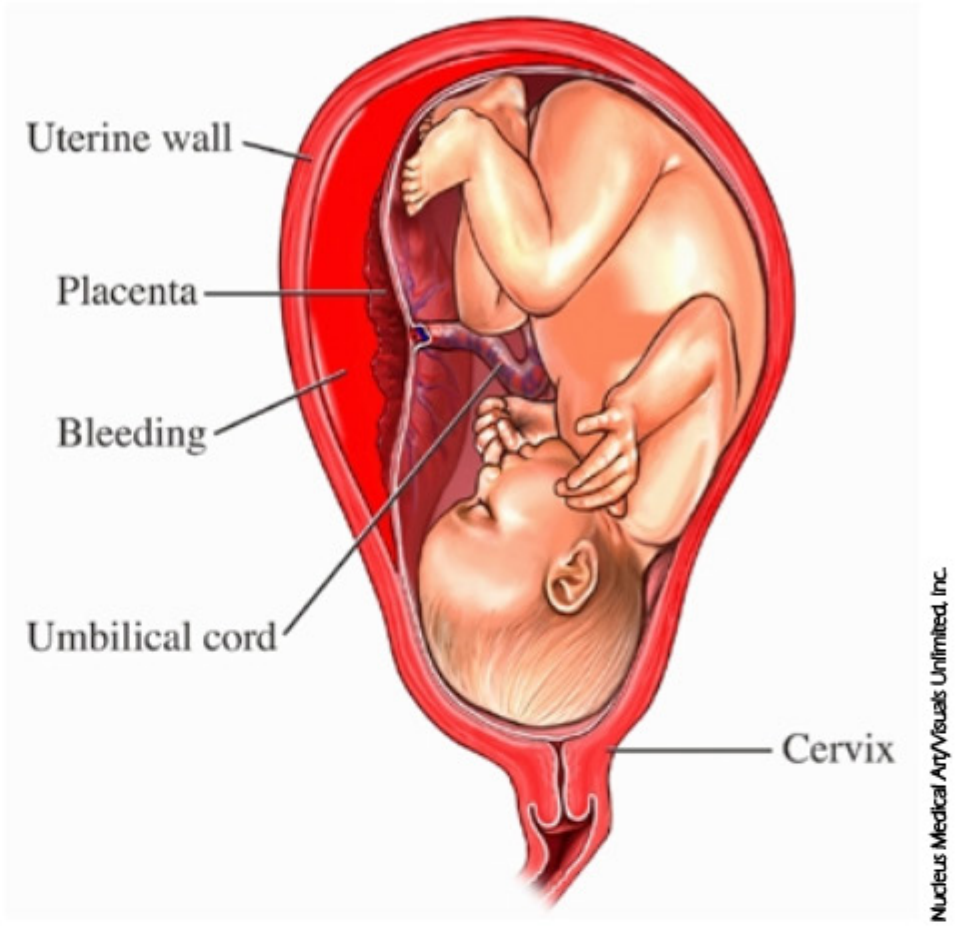

▲ **Figure 18–12.2B** Abruptio Placentae

12.2.3 Placenta Accreta

- Direct implantation into muscle *without* intervening decidua.
- Occurs in 1 in 2,500 pregnancies.
- Great risk for hemorrhage during delivery.

12.2.4 Preeclampsia/Eclampsia

Toxemia of pregnancy that usually occurs in the third trimester (24th to 25th weeks).

Risk Factors

- More common in women <20 years of age and >35 years of age.
- History of previous preeclampsia.
- Positive family history and African-American women
- Multiple gestations
- May be associated with hydatidiform moles.

Pathogenesis

- Abnormal placentation that results in mechanical or functional obstruction of spiral arteries.
- Substances such as PGE_2 and nitric oxide are decreased, therefore favoring vasoconstriction resulting in net effect of placental hypoperfusion.

Please visit us at www.Groupinsiders.com

© DeVry/Becker Educational Development Corp. All rights reserved.

Clinical Findings

- Premature aging of the placenta
- Multiple placental infarctions with spiral arteries show intimal atherosclerosis.
- The increased vasoconstriction results in hypertension ranging from just below 140/90 mmHg to >160/110 mmHg.
- Proteinuria in nephrotic range (>3.5 g/24 hours)
- Dependent pitting edema
- Weight gain >4 pounds a week
- *When generalized seizures are presented with preeclampsia the condition is referred to as eclampsia.*
- **HELLP syndrome:**
  - **H**emolytic anemia and disseminated intravascular coagulation
  - **EL**evated transaminases
  - **L**ow **P**latelet count

Treatment

- Delivery is the treatment of choice and the only cure for the disease.
- Magnesium sulfate is given for seizures.

12.2.5 Gestational Trophoblastic Neoplasms

Hydatidiform Moles: Two Types

- Benign tumors of the chorionic villus.
- More common at the extremes of age.
- Occurs in 1 in 1,200 pregnancies in the United States.

1. Complete Mole

- Most common type
- The entire placenta is neoplastic.
- Dilated, swollen villi without fetal blood vessels.
- *No* embryo is present.
- 46,XX (90% of cases)
- *Chromosomes are paternally derived, creating two scenarios:*
  - *Two sperms with 23, X sperms*
  - *One sperm that duplicates 23, X*
- Increased risk for developing choriocarcinoma.

Clinical Findings

- Painless vaginal bleeding in fourth or fifth month of pregnancy.
- Severe vomiting
- Ultrasound with "snowstorm" appearance
- Uterus is too large for gestational age
- Increased hCG for the gestational age
- *Preeclampsia in first trimester may be found in these patients (nonspecific).*

Please visit us at www.Groupinsiders.com

© DeVry/Becker Educational Development Corp. All rights reserved.

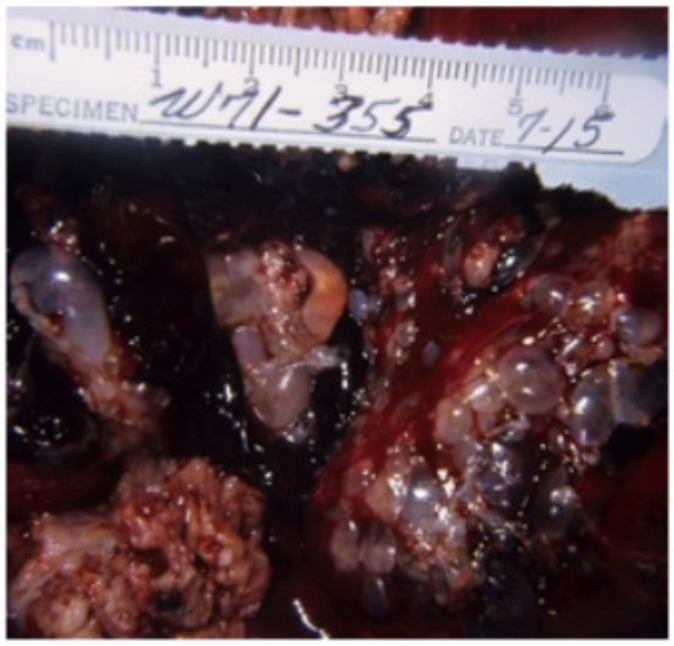

O.J. Staats MD/Custom Medical Stock Photo

▲ **Figure 18–12.2C** Complete Mole

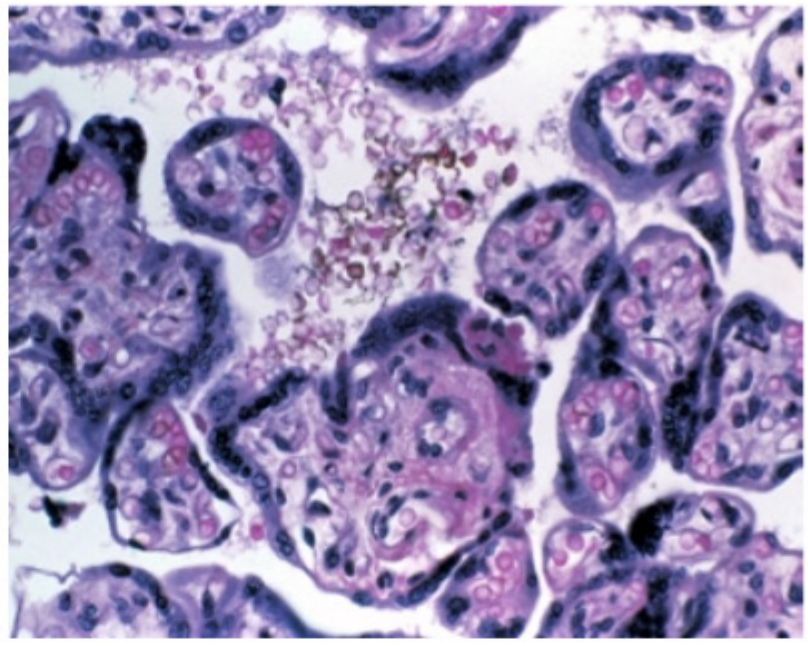

CNRI/Science Source

▲ **Figure 18–12.2D** Normal Chorionic Villi

Treatment Dilation and Curettage

2. Partial Mole

- Not all villi are neoplastic or dilated.
- Normal embryo is present with no chromosome abnormality.
- Triploid (69,XXY)
- Egg with 23,X is fertilized by a 23,X and a 23,Y sperm.
- *Preeclampsia in first trimester may be found in these patients (nonspecific).*
- Low risk for developing a choriocarcinoma.

Choriocarcinoma

- Malignant tumor composed of syncytiotrophoblast and cytotrophoblast
- Chorionic villi are *not* present.
- The greatest risk factor is complete mole (50% of cases) followed by spontaneous abortion, full-term pregnancy, and ectopic pregnancy.
- Common sites of metastasis: Lungs and vagina
- Tissue is hemorrhagic without dilated villi.

Please visit us at www.Groupinsiders.com

© DeVry/Becker Educational Development Corp. All rights reserved.

13 Sexually Transmitted Diseases and Genital Infections

▼ **Table 18–13.0** Sexually Transmitted Diseases and Genital Infections

Pathogen	Description and Treatment
Calymmatobacterium granulomatis	STD; gram-negative coccobacillus that causes **granuloma inguinale**
	Organism phagocytized by macrophages (**Donovan bodies**)
	Creeping, raised sore that heals by scarring; **no lymphadenopathy**
	Treatment: doxycycline or trimethoprim-sulfamethoxazole
Candida albicans 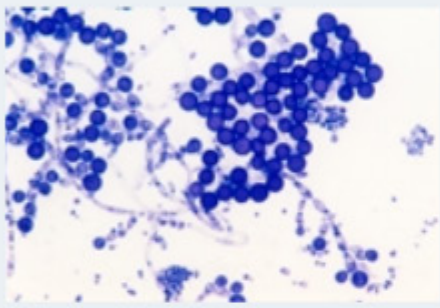	Yeasts and pseudohyphae (elongated yeasts); part of normal vaginal flora
	Second most common vaginitis in the U.S.
	Risk factors: diabetes, antibiotics, pregnancy, OCP
	Pruritic vaginitis with a **white discharge and fiery red mucosa**
	Treatment: fluconazole (single dose)
Chlamydia trachomatis	STD; often **coexists with Neisseria gonorrhoeae (45% of cases)**
	Incubation period 7–12 days after exposure; red inclusions (**reticulate bodies**) in infected **metaplastic squamous cells**; reticulate bodies divide to form **elementary bodies, which are the infective** bodies producing infection
	Infections in males: NSU (sterile pyuria), epididymitis, proctitis
	Infections in females: urethritis (sterile pyuria), cervicitis, PID, perihepatitis (**Fitz-Hugh-Curtis syndrome** scar tissue between peritoneum and surface of liver from pus from PID), proctitis, Bartholin gland abscess
	Infections in newborns: conjunctivitis (ophthalmia neonatorum), pneumonia
	DNA probe test for quick diagnosis
	Treatment: azithromycin 1 g (single dose); doxycycline
***C. Trachomatis* subspecies**	STD; **lymphogranuloma venereum**
	Papules with **no ulceration; inguinal lymphadenitis** with granulomatous microabscesses and draining sinuses
	Lymphedema of scrotum or vulva; women also may develop rectal strictures
	Treatment: doxycycline

Credit: Dr. Edward Chan/Visuals Unlimited, Inc.

Please visit us at www.Groupinsiders.com

© DeVry/Becker Educational Development Corp. All rights reserved.

▼ **Table 18–13.0** Sexually Transmitted Diseases and Genital Infections *(continued)*

Pathogen	Description and Treatment
Gardnerella vaginalis	Gram-negative rod that causes bacterial vaginosis
	Most common vaginitis
	Malodorous vaginal discharge; vaginal pH >4.5
	Organisms adhere to squamous cells producing **"clue cells"**
	Increased incidence of preterm delivery and low-birth-weight newborns
	Treatment: metronidazole; same treatment in pregnancy
Haemophilus ducreyi	STD; gram-negative rod that causes **chancroid**
	Male dominant disease (10:1); high incidence of HIV
	Incubation 4–7 days
	Painful genital and perianal ulcers with suppurative inguinal nodes
	Diagnosis with Gram stain (**"school of fish"** appearance) and culture
	Treatment: ceftriaxone or azithromycin 1 g (single dose)
HSV-2	STD; virus remains latent in sensory ganglia
	Recurrent vesicles that ulcerate; locations—penis, vulva, cervix, perianal area
	Tzanck preparation: Scrapings removed from the base of an ulcer; see multinucleated squamous cells with eosinophilic intranuclear inclusions
	Pregnancy: If virus is shedding, baby is delivered by **cesarean section**
	Treatment: acyclovir (decreases recurrences)

Credits: (top to bottom) SPL/Science Source; Biophoto Associates/Science Source; Carolina Biological Supply Co./Visuals Unlimited, Inc.

Please visit us at www.Groupinsiders.com

© DeVry/Becker Educational Development Corp. All rights reserved.

▼ **Table 18–13.0** Sexually Transmitted Diseases and Genital Infections *(continued)*

Pathogen	Description and Treatment
HPV	STD; **types 6 and 11** (90%; low-risk types) associated with **condyloma acuminata** (venereal warts); **fernlike** or flat lesions in genital area (e.g., penis, vulva, cervix, perianal)
	Most common overall STD; 80% of sexually active women will have acquired HPV by age 50
	Types 16 and 18 (high-risk types) associated with **dysplasia and squamous cancer**
	Virus produces **koilocytic** change in squamous epithelium
	Cells have wrinkled pyknotic nuclei surrounded by a clear halo
	Approximately 90% spontaneously clear within two years (most within eight months); older women will more often have persistent disease
	Vaccine decreases risk for developing cervical cancer
	Treatment: topical podophyllin; α-IFN injection; imiquimod cream
Neisseria gonorrhoeae	STD; gram-negative diplococcus that infects glandular or transitional epithelium; symptoms appear two to seven days after sexual exposure
	Infection sites similar to *C. trachomatis*
	Complications: ectopic pregnancy, male sterility, disseminated gonococcemia **(C6–C9 deficiency risk factor)**, septic arthritis, Fitz-Hugh-Curtis syndrome association
	Disseminated gonococcemia: septic arthritis (knee), tenosynovitis (hands, feet), pustules (hands, feet); more common in women than in men
	DNA probe test for quick diagnosis
	Treatment: ceftriaxone

Credits: (top to bottom) Dr. Ken Greer/Visuals Unlimited, Inc.; Leon J. LeBeau/Custom Medical Stock Photo

Please visit us at www.Groupinsiders.com

© DeVry/Becker Educational Development Corp. All rights reserved.

▼Table 18–13.0 Sexually Transmitted Diseases and Genital Infections *(continued)*

Pathogen	Description and Treatment
Treponema pallidum	STD; **gram-negative spirochete** that causes syphilis **Primary syphilis:** solitary **painless, indurated chancre;** locations—penis, labia, mouth
	Secondary syphilis: maculopapular rash on trunk, palms, soles; generalized lymphadenopathy; **condyloma lata,** which are flat lesions in the same area as condyloma acuminata; alopecia
	Tertiary syphilis: neurosyphilis, aortitis, **gummas**
	Congenital syphilis
	Nonspecific screening tests: RPR or VDRL; titers decrease after treatment
	Confirmatory treponemal test: FTA-ABS; positive with or without treatment
	Jarisch-Herxheimer reaction: intensification of rash in primary or secondary syphilis may occur due to proteins released from dead organisms after treatment with **penicillin**
	Treatment: penicillin
Trichomonas vaginalis	STD; **flagellated protozoan** with jerky motility
	Produces vaginitis, cervicitis, and urethritis; **strawberry-colored cervix and fiery red vaginal mucosa; greenish, frothy discharge**
	Treatment: metronidazole (both partners)

Credits: (top to bottom) Biophoto Associates/Science Source; Collection CNRI/Phototake, Inc.; Dr. M.A. Ansary/Science Source

Please visit us at www.Groupinsiders.com

© DeVry/Becker Educational Development Corp. All rights reserved.

14 Breast Anatomy

- The upper outer quadrant is an area of high-density locations of breast tissue, thus the most common location for cancer and drainage into the axillary lymph nodes, whereas inner-quadrant cancers drain into the internal mammary lymph nodes.
- Hormone effects on the breast during the menstrual cycle:
  - Estrogen stimulates ductal and alveolar growth.
  - Progesterone stimulates alveolar differentiation.

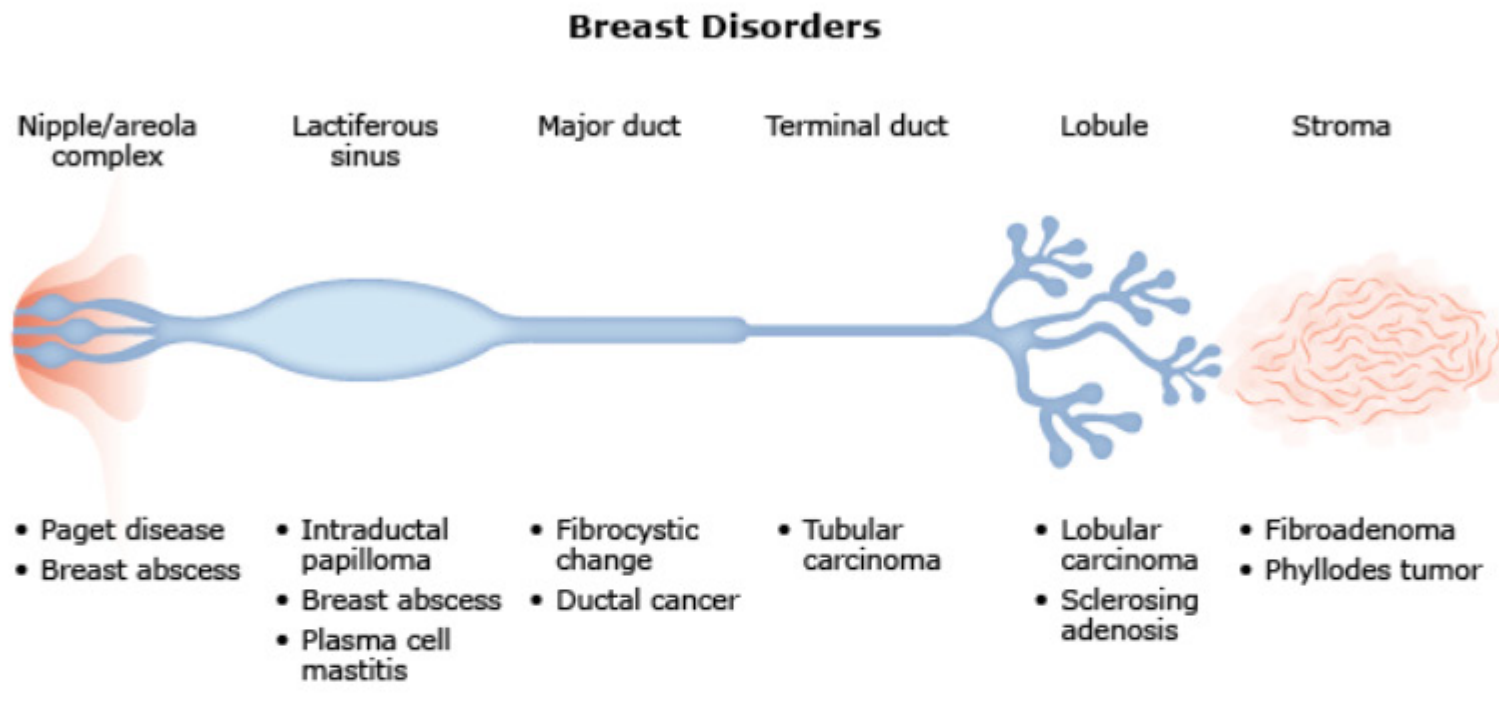

▲ **Figure 18–14.0** Breast Nirvana

Please visit us at www.Groupinsiders.com

© DeVry/Becker Educational Development Corp. All rights reserved.

15 Nipple Discharge

15.1 Galactorrhea

- Mechanical stimulation of the nipple is the most common physiologic cause.
- Prolactinoma: Most common pathologic cause of galactorrhea.
  - Primary hypothyroidism is the most common nonpituitary endocrine disease causing galactorrhea.
  - Decreased serum thyroxine increases thyrotropin-releasing hormone (TRH), which in turn stimulates prolactin release.
  - Drugs: dopamine antagonists

▼Table 18–15.1 Nipple Discharge Type

Nipple Discharge Type	Example of Condition
Bloody	Intraductal papilloma, ductal cancer
Purulent	Acute mastitis due to *Staphylococcus aureus*
Greenish-brown	Mammary duct ectasia (plasma cell mastitis)

Connection to Pharmacology

See *Pharmacology*, chapter 9, "Edocrinology Drugs," topic 1.

Please visit us at www.Groupinsiders.com

© DeVry/Becker Educational Development Corp. All rights reserved.

16 Fibrocystic Change

16.1 Distortion of Normal Cyclic Breast Changes

Epidemiology and Pathogenesis

- Most common painful breast mass in women under 50 years old.
- Occurs in more than 50% of women in the reproductive period of life.
- Small and large cysts with fibrosis, often referred to as "lumpy-bumpy" feeling on breast examination.

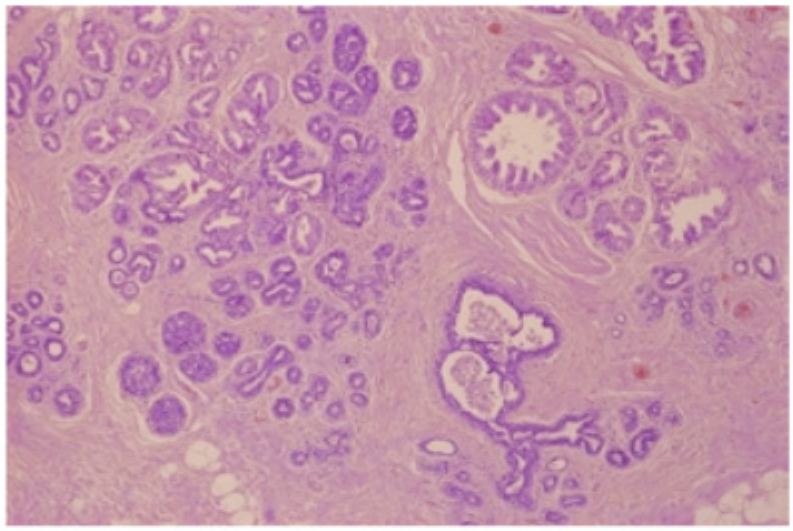

Biophoto Associates/Science Source

▲ **Figure 18–16.1** Fibrocystic Change

- There may be hemorrhaging into these cysts, giving a "blue-domed" cyst appearance.
- Vary in size with the menstrual cycle.
- *No* malignant potential.

16.2 Types of Fibrocystic Change

- Sclerosing adenosis often contain microcalcifications seen on mammogram.
- Ductal hyperplasia, which are estrogen-sensitive.
- Atypical ductal hyperplasia has an increased risk for developing cancer.

Please visit us at www.Groupinsiders.com

© DeVry/Becker Educational Development Corp. All rights reserved.

17 Benign Breast Tumors

17.1 Fibroadenoma

Epidemiology

- Most common breast tumor in women under 40 years old.
- Most commonly diagnosed breast tumor derived from stroma.
- Develop in 50% of women who receive cyclosporine after renal transplantation.
- Discrete movable, painless, *or* painful mass.
- Multiple lesions may be present (10% to 15%).
- Increases in size during pregnancy due to increased sensitivity to estrogen.
- May spontaneously disappear or involute during menopause.
- Do *not* progress into cancer; however, breast cancer may secondarily develop within duct epithelial cells as a separate event.

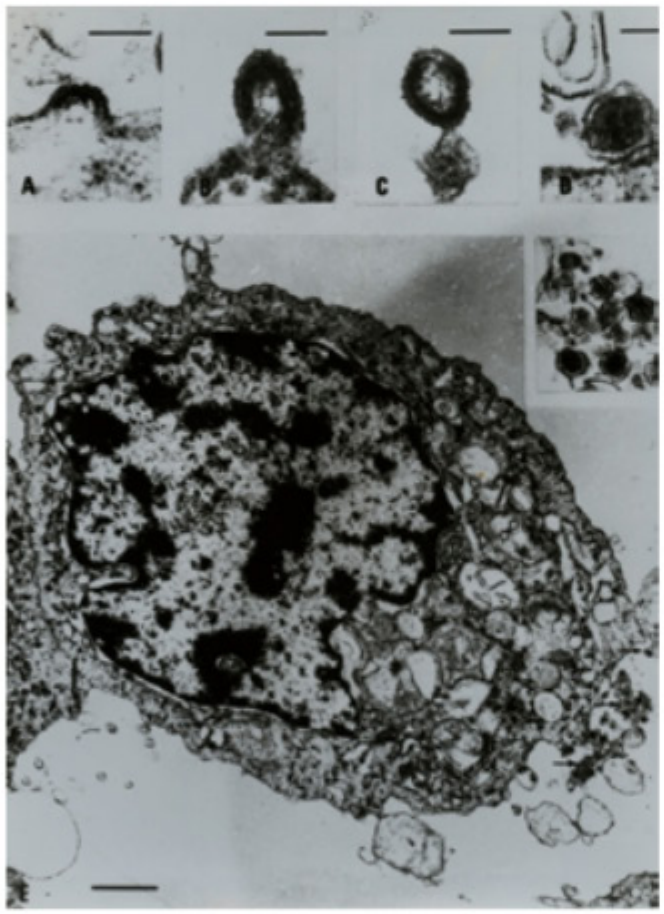

▲ **Figure 18–17.1** Fibroadenoma

17.2 Phyllodes Tumor

Can be benign, borderline, or malignant; depends on stromal cellularity.

17.3 Intraductal Papilloma

The most common cause of bloody nipple discharge in women under 50 years old.

Please visit us at www.Groupinsiders.com

© DeVry/Becker Educational Development Corp. All rights reserved.

18 Types of Breast Cancer

▼Table 18–18.0 Types of Breast Cancer

Noninvasive	
Ductal carcinoma in situ (DCIS) 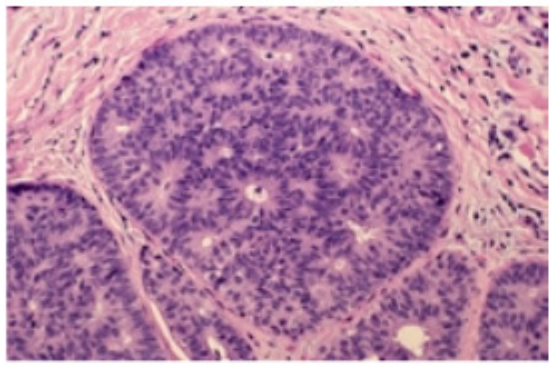	Nonpalpable patterns: cribriform (sieve-like), comedo (necrotic center)
	Commonly contain **microcalcifications;** cannot be detected by mammogram unless microcalcifications are present
	One third eventually invade
	Treated with "lumpectomy"
Lobular carcinoma in situ 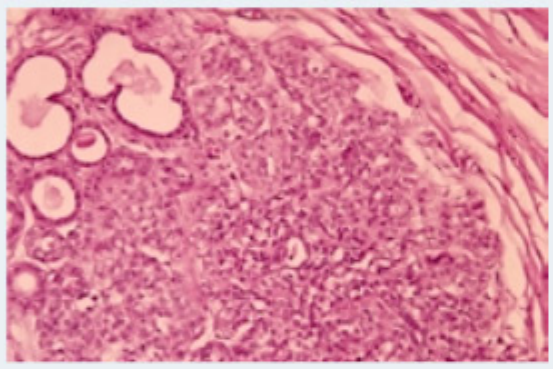 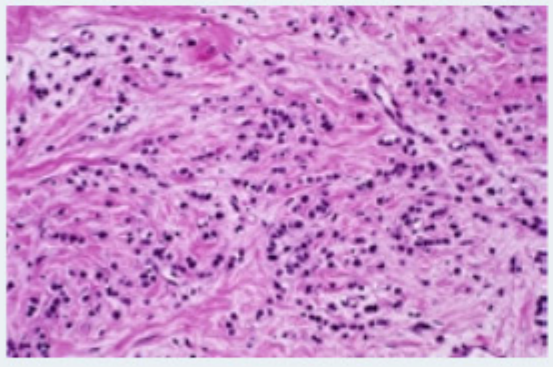	Nonpalpable; virtually always an incidental finding in a breast biopsy for other reasons; cannot be identified by mammography
	Lobules distended with bland neoplastic cells; one third eventually invade; usually **estrogen and progesterone receptor positive**
	Increased incidence of cancer in the **opposite breast** (50% to 75%); does **not** have to be a lobular cancer

Credits (top to bottom): Dr. Gladden Willis/Visuals Unlimited, Inc.; Custom Medical Stock Photo; Dr. Gladden Willis/Visuals Unlimited, Inc.

Please visit us at www.Groupinsiders.com

© DeVry/Becker Educational Development Corp. All rights reserved.

▼Table 18–18.0 Types of Breast Cancer *(continued)*

Invasive	
Infiltrating ductal carcinoma 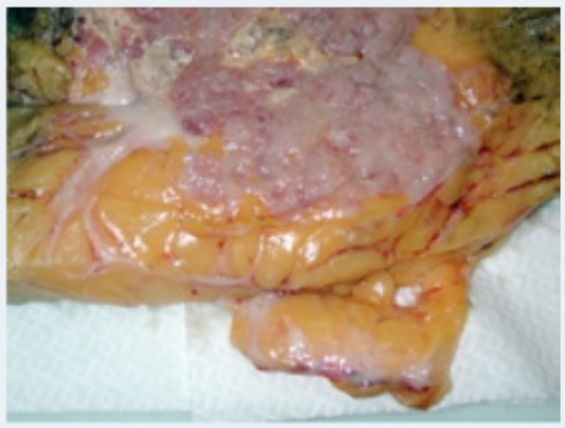	Stellate morphology, indurated, gray-white tumor One third have amplification of **ERBB2 oncogene**
	Gritty on cut section
	Induration caused by reactive fibroplasia (desmoplasia)
Paget disease of nipple 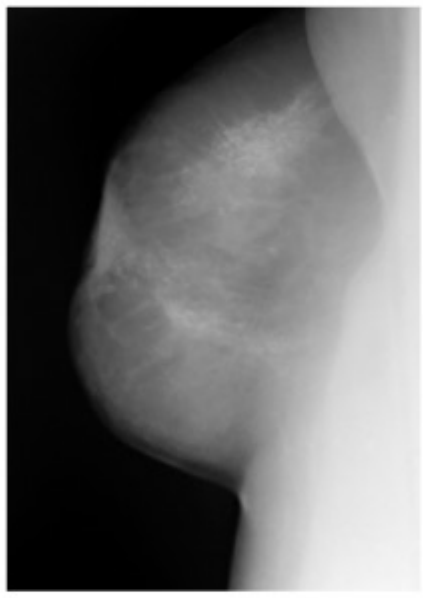	**Extension of DCIS into lactiferous ducts and skin of nipple, producing a rash with or without nipple retraction**
	Paget cells are present
	Palpable mass present in 50% to 60%
Inflammatory carcinoma	Erythematous breast with dimpling like an orange (peau d'orange) due to fixed opening of the sweat glands, which cannot expand with lymphedema
	Plugs of tumor blocking lumen of dermal lymphatics cause localized lymphedema
	Very poor prognosis
	Combination chemotherapy followed by surgery and irradiation

Credits (top to bottom): Boilershot Photo/Science Source; Wellcome Images; B. Slaven, MD/Custom Medical Stock Photo

Please visit us at www.Groupinsiders.com

© DeVry/Becker Educational Development Corp. All rights reserved.

Unit 9

Endocrine Pathology

Please visit us at www.Groupinsiders.com

Please visit us at www.Groupinsiders.com

1 Overview of Pathology

Endocrine is the subdiscipline of medicine involving the study of biochemical messengers, or hormones, possessing an overarching influence on multiorgan systems. Hormones can be classified as:

- **Peptide:** Pituitary hormones, IGFs, insulin, glucagon
- **Amino acid derivative**
  - **Tyrosine derivatives:** Catecholamines, thyroid hormone
  - **Tryptophan derivatives:** Serotonin, melatonin
- **Lipid:** Cholesterol-derived steroid hormones, such as adrenal cortical hormones, progesterone, vitamin D

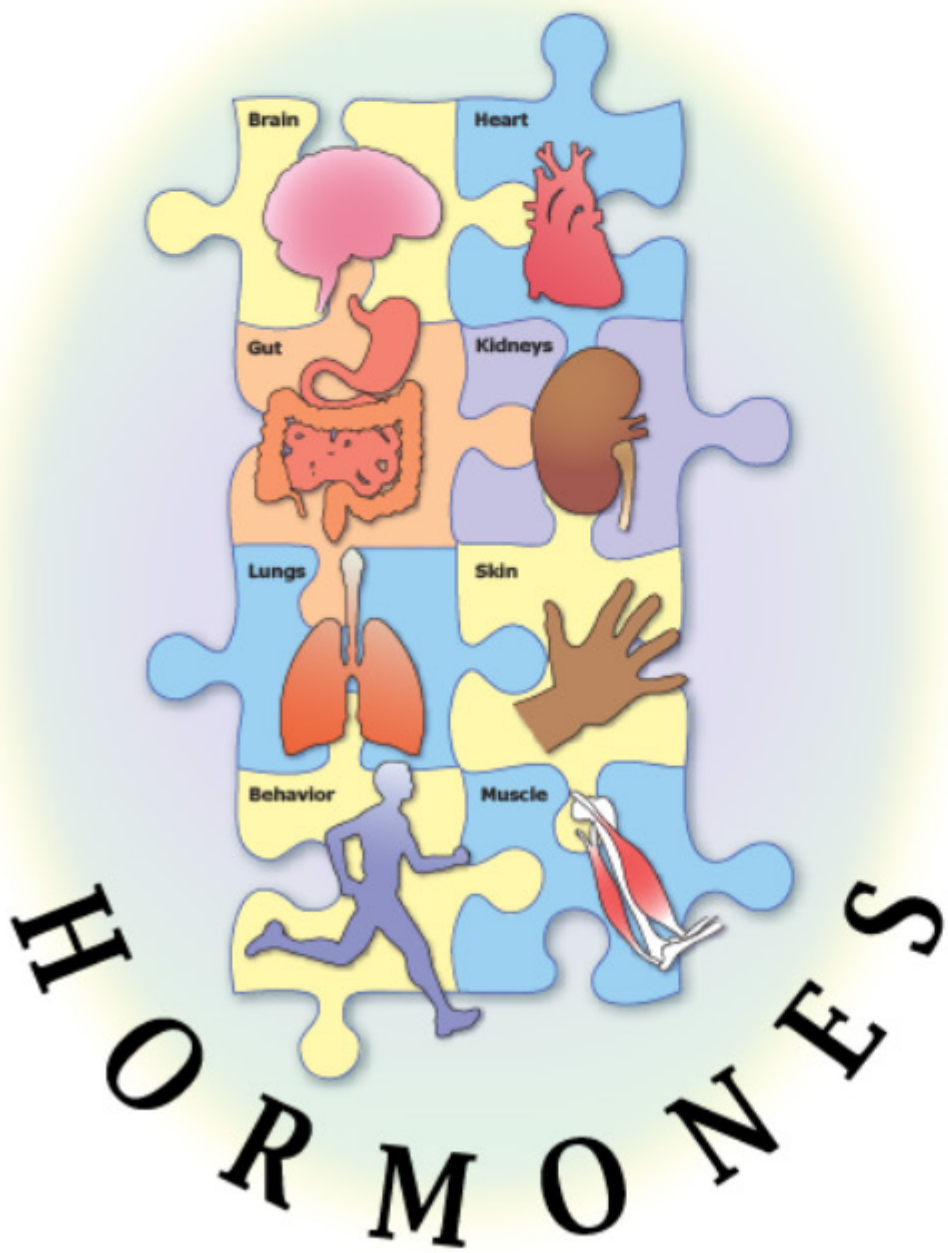

▲ **Figure 19–1.0** Hormones Regulate and Maintain the "Milieu Interior"

USMLE® Key Concepts

For Step 1, you must be able to:

- Identify pathologies of hypothalamo-pituitary axis, the hypothalamo-pituitary-thyroid axis, and the hypothalamo-pituitary-adrenal axis.
- Explain the pathologies of the pancreas.
- Describe pathologies caused by calcium imbalances, both hypercalcemia and hypocalcemia.

Connection to
Endocrine Physiology

See *Physiology*, chapter 30, topic 2.2, "Urine Sampling."

Please visit us at www.Groupinsiders.com

© DeVry/Becker Educational Development Corp. All rights reserved.

▼Table 19–1.0A Cell Surface Receptors: Downstream Mechanisms

Tyrosine Kinase	G_s (↑ cAMP)	G_i (↓ cAMP)	G_q (↑ IP_3, DAG)
Insulin	ACTH	Somatostatin	Oxytocin
Growth Factors	TSH	ACh (M_2, M_4)	Vasopressin
IGF-1	FSH		TRH
PDGF	LH		GnRH
FGF	PTH		ACh (M_1, M_3, M_5)
	Glucagon		Gastrin

▼Table 19–1.0B Steroid Hormone Receptors

Predominantly Cytoplasmic	Predominantly Nuclear
Glucocorticoid receptor	Estrogen receptor
Mineralocorticoid receptor	Thyroid hormone receptor
Androgen receptor	Vitamin D receptor
	Retinoic acid receptor

Connection to

Endocrine Physiology

See *Physiology*, chapter 30, topic 1.3 to review lipid-soluble hormones and topic 4 to review hormonal feedback.

Please visit us at www.Groupinsiders.com

© DeVry/Becker Educational Development Corp. All rights reserved.

2 The Hypothalamus and Pituitary

2.1 Pituitary Actions of Antidiuretic Hormone (ADH)

2.1.1 Diabetes Insipidus (DI)

Diagnosis

1. **Water Deprivation Test:** Water deprivation test is performed to rule in or out conditions that may exhibit an osmotic imbalance in either the plasma or urinary tubular compartment.
2. **ADH Challenge:** Performed after water deprivation test.

- In both central and nephrogenic DI, the plasma osmolarity in the presenting patient will be increased to approximately >295 mOsm/kg.
- **Central**
  - Responds to ADH
  - Urine output decreases
  - Urine osmolality increases
- **Nephrogenic**
  - Does not respond to ADH because kidneys are resistant to ADH
  - Administration of ADH does not change urine osmolality

Connection to
Endocrine Physiology

See *Physiology*, chapter 33, topic 3, "Actions of ADH on the Kidney," to review the posterior pituitary.

Connection to
Endocrine Physiology

See *Physiology*, chapter 33, topic 4 for more information about diabetes insipidus.

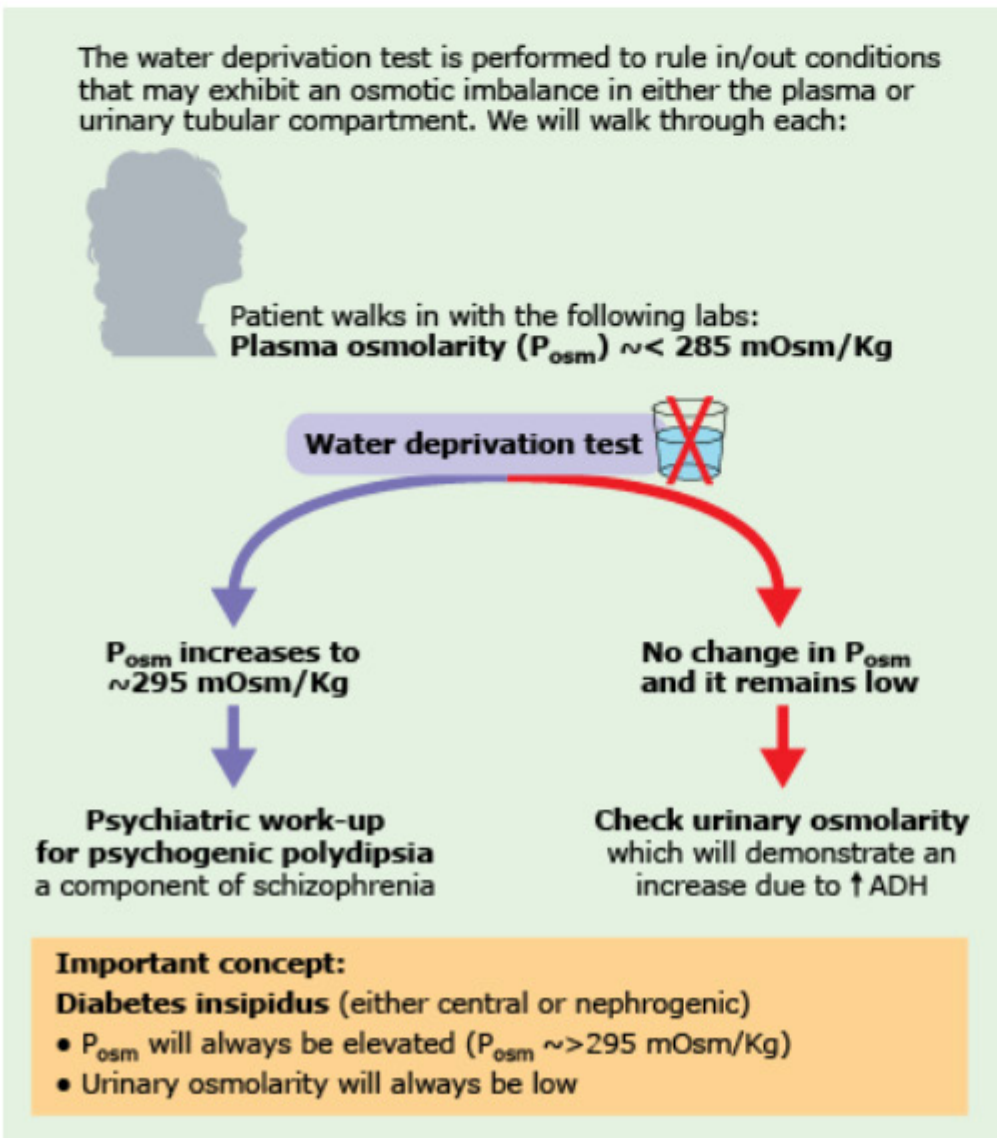

◀ **Figure 19–2.1** Osmolarity Imbalance

Please visit us at www.Groupinsiders.com

© DeVry/Becker Educational Development Corp. All rights reserved.

2.1.2 Syndrome of Inappropriate Antidiuretic Hormone (SIADH)

Etiology

- **CNS**
  - Stroke
  - Head trauma
- **Thoracic disease**
  - Trauma
  - Pneumonia
  - Major thoracic/abdominal surgery
- **Drugs**
  - SSRIs
  - Chlorpropramide
  - Carbamazepine
- **Ectopic ADH production (paraneoplastic syndromes):** Most often by small cell lung cancer.

Clinical Features

- Patients present with hyponatremia due to increased water retention diluting the serum.
- Most appear asymptomatic.
- Symptoms of severe hyponatremia include:
  - Lethargy
  - Seizures
  - Coma
- Usually seen with acute reductions in serum sodium.

Laboratory Findings

- Euvolemic patient
- Serum sodium levels and plasma osmolarity are low
- Urine osmolarity is inappropriately high (>100 mOsmol/kg and usually >300 mOsmol/kg) $U_{Osm} > P_{Osm}$
- Urine sodium >20 mEq/L
- Low BUN and serum uric acid
- *SIADH cannot be diagnosed without excluding hypothyroidism and adrenal insufficiency (AI)*
- Treatment of SIADH

Connection to
Endocrine Physiology

See *Physiology*, chapter 33, topic 5 for additional information about syndrome of inappropriate secretion of ADH.

Connection to
Pharmacology

In the management of SIADH, special attention should be paid to a pathological condition that can manifest with the rapid correction with hypertonic saline, resulting in central pontine myelinolysis.

Please visit us at www.Groupinsiders.com

© DeVry/Becker Educational Development Corp. All rights reserved.

3 The Hypothalamus and Pituitary: Anterior Pituitary

3.1 Anterior Pituitary Pathophysiology

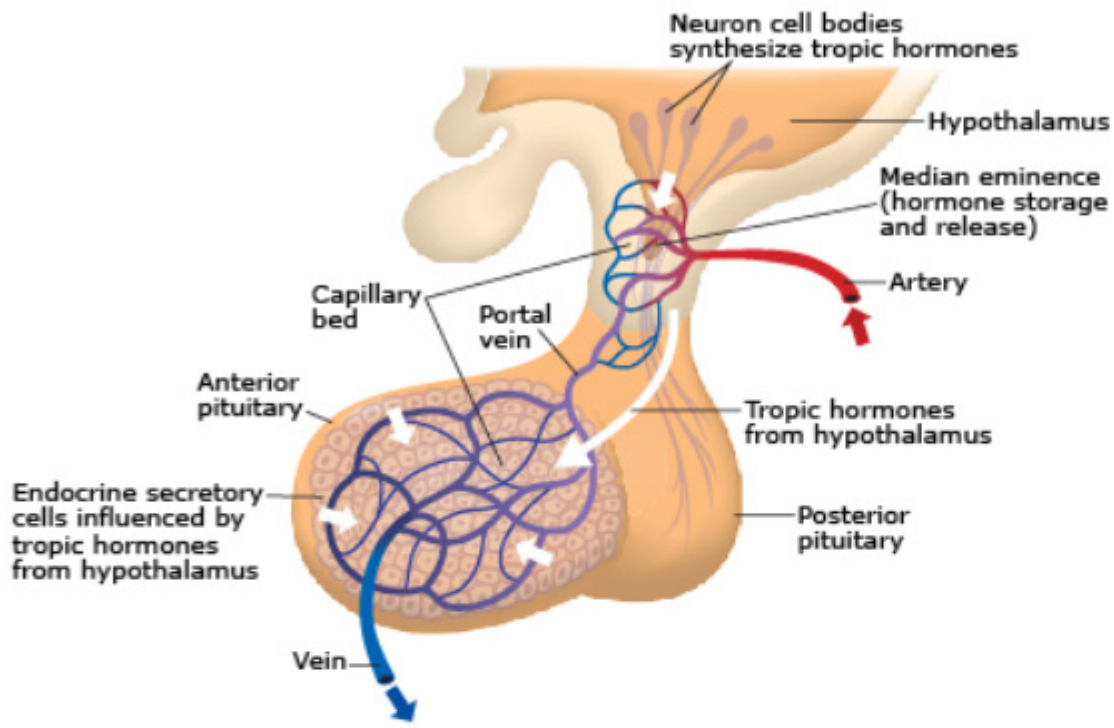

▲ **Figure 19–3.1A** Hypothalamic-Anterior Pituitary System

Anterior pituitary cell types include:

- Corticotorpes (C) are at the posterior tip.
- Thyrocytes (Tr) are at the opposite corner.
- Most ventral cells are the gonadotropes (G), followed by the main thyrotropes (T), the somatotropes and lactotropes (S/L), and melanotropes (M).
- *After compartmentalized cell-type specification, the cells become mixed.*
- **Pink Acidophils**
  - Growth hormone (GH): Somatotropes
  - Prolactin (PRL): Lactotropes
- **Dark Purple Basophils**
  - Adrenocorticotropic hormone (ACTH): Corticotropes
  - Thyroid-stimulating hormone (TSH): Thyrotropes
  - Follicle-stimulating hormone/luteinizing hormone (FSH/LH): Gonadotropes

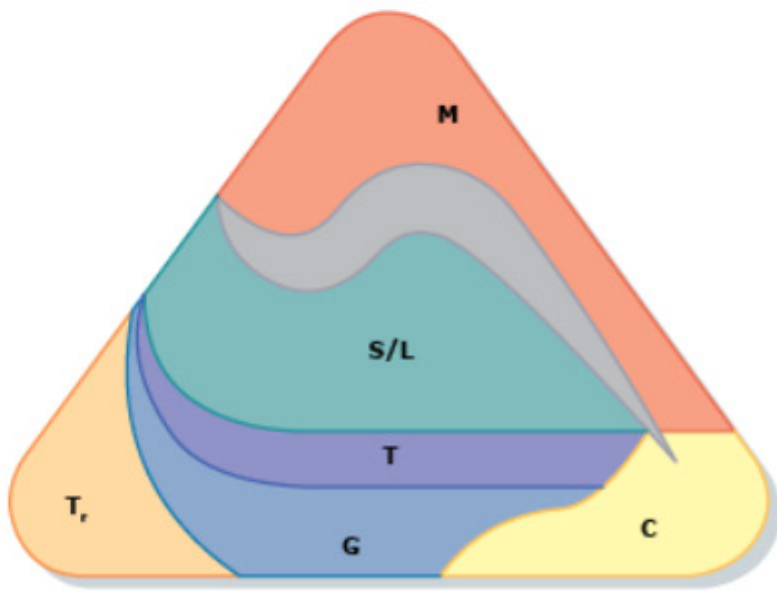

▲ **Figure 19–3.1B** Rathke Pouch

Please visit us at www.Groupinsiders.com

© DeVry/Becker Educational Development Corp. All rights reserved.

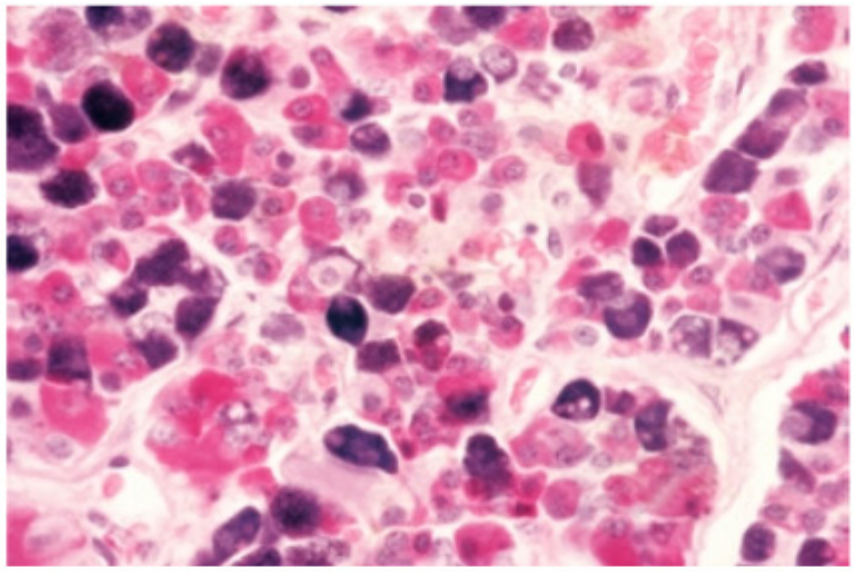

▲ **Figure 19–3.1C** Pink Acidophils and Dark Purple Basophils

3.2 Hypothalamic-Anterior-Pituitary Hormones

Three structural types of anterior pituitary peptide hormones are:

- Glycoproteins (gonadotropins)
- Somatomammotropins
- Proopiomelanocortin (POMC)

3.2.1 Glycoproteins (Gonadotropins)

In females, FSH directs follicle development, and FSH and LH together regulate ovarian steroid production. In males, FSH regulates spermatogenesis, and LH stimulates testosterone production in testicles.

- **Human chorionic gonadotropin (hCG):** Structure is nearly identical to LH and activates LH receptors.
- **Lutropin:** Synthetic form of LH.
- **Menotropins:** Human gonadotropins extracted from the urine of postmenopausal women. They contain a combination of FSH and LH.
- **Urofollitropin:** From urine and synthetic *follitropin*; activates FSH receptors.

3.2.2 Somatomammotropins

Growth hormone and human placental lactogen released from fetal placenta may contribute to increased siphoning of glucose to the fetus, resulting in greater-than-normal levels of maternal blood glucose.

Please visit us at www.Groupinsiders.com

© DeVry/Becker Educational Development Corp. All rights reserved.

3.2.3 Proopiomelanocortin (POMC)

POMC is the precursor substance that gives rise to ACTH and *melanocyte-stimulating hormone (MSH)*, which play an important role in differentiating between Addison disease and secondary hypocortisolism (discussed in topic 5, "The Hypothalamus and Pituitary: Adrenals").

- **ACTH:** Acts on adrenal cortex and stimulates primarily the secretion of cortisol.
- **MSH:** Acts on melanocytes; three forms made from POMC→ α-, β-, and γ-MSH; *α-MSH also may be an appetite suppressor.*
- **β-Endorphin/MET-ENK:** Opioid peptides.

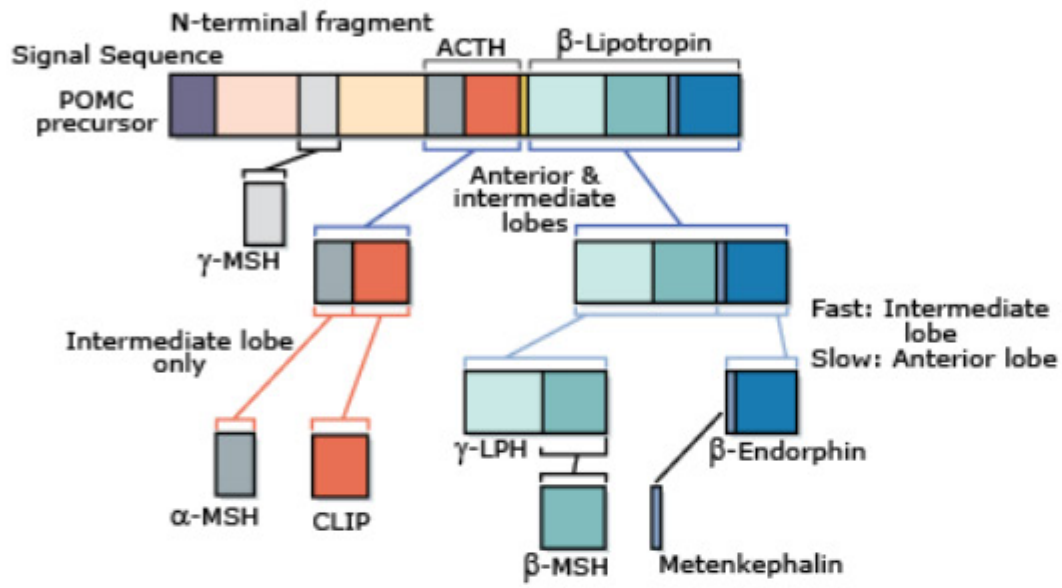

▲ **Figure 19–3.2** Proteolytic Cleavage of the POMC Gene

3.3 Pituitary Insufficiency

- **Insufficiency in growth hormone**
  - Dwarfism in children
  - Hypoglycemia in adults
- **Insufficiency in gonadotropins**
  - Retarded sexual maturation in children
  - Impotence and loss of libido, muscle, and facial hair in men
  - Amenhorrhea in women
- **Insufficiency in TSH:** Secondary hypothyroidism
- **Insufficiency in ACTH**
  - Secondary adrenal failure (lack hyperpigmentation of the skin, compared with Addison)
  - Sudden death

Important Concept

Manifestations of generalized pituitary insufficiency:

- Adenoma: All the problems of primary Addison disease (except dark skin).
- Infarct: All the problems of primary hypothyroidism.
- "Empty Sella"—The following may also be present:
  - —Failure of lactation.
  - —Diabetes insipidus.
  - —Growth failure in children.

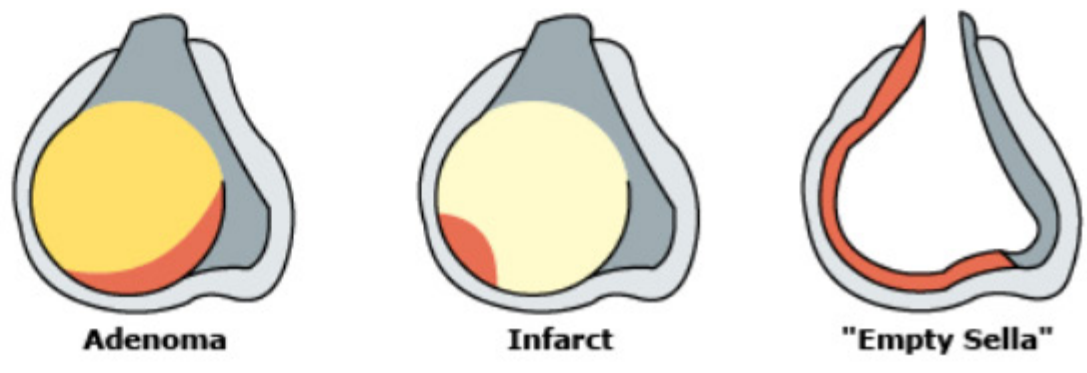

▶ **Figure 19–3.3A** Hypopituitarism

Please visit us at www.Groupinsiders.com

© DeVry/Becker Educational Development Corp. All rights reserved.



▲ **Figure 19–3.3B** Sellar Mass

▼ **Table 19-3.3** Pituitary Apoplexy and Sheehan Syndrome

Pituitary Apoplexy	Sheehan Syndrome
• Acute hemorrhage into pituitary tumor • May have *sudden headache*, visual deficit, *ophthalmoplegia* (CN III, IV, VI), and altered mental status • Most dangerous result is lack of ACTH with acute secondary adrenal insufficiency • Treat acutely with stress dose glucocorticoids; may require immediate surgical decompression	• Pituitary infarction caused by blood loss during childbirth • May present shortly after or up to a week post-delivery • Classic presentation is a new mother unable to produce milk

3.4 Pituitary Adenomas

3.4.1 Types

- Prolactinoma (lactotrophic adenoma)
- Somatotrophic adenoma
- Corticotrophic adenoma
- Gonadotrophic adenoma
- Thyrotrophic adenoma
- Null cell adenoma

3.4.2 Prolactinoma

Etiology

- Functional pituitary adenoma (prolactinoma)
- Primary hypothyroidism (↑ TRH)
- Drugs (neuroleptics, metoclopramide, estrogens)
- Nipple stimulation

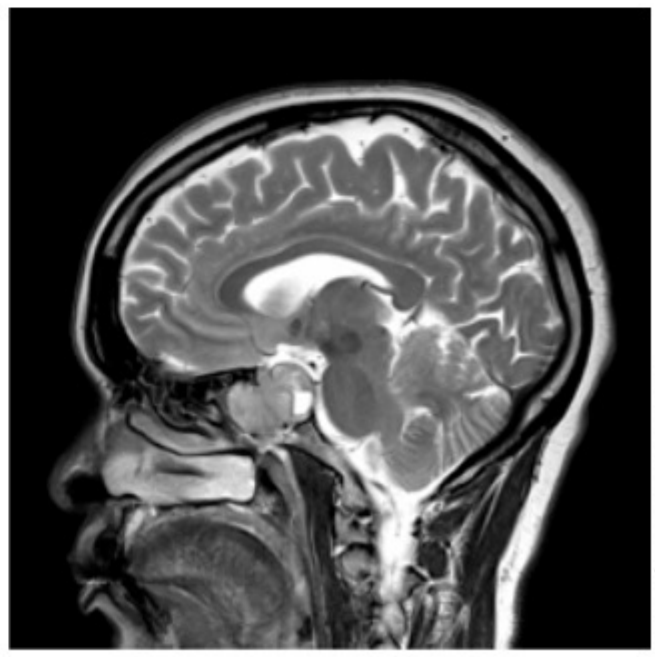
Nuada Medical/Wellcome Images

▲ **Figure 19–3.4** Pituitary Adenoma

Please visit us at www.Groupinsiders.com

© DeVry/Becker Educational Development Corp. All rights reserved.

- Chest wall trauma
- Renal failure
- Stress, exercise

Clinical Features

- Inhibits the release and action of FSH/LH.
- Females: Galactorrhea and amenorrhea; infertility.
- Males: Gynecomastia, erectile dysfunction, decreased libido, and vision loss.

Diagnosis

- Elevated serum PRL level.
- Need to rule out primary hypothyroidism because TSH increases PRL.
- MRI of the pituitary may reveal an adenoma.
- Large, nonsecreting adenoma can elevate PRL via stalk compression, inhibiting dopamine regulation of prolactin, i.e., *stalk effect.*
- Suspect prolactinoma if macroadenoma is seen with only moderate prolactin elevation (i.e., <100 ng/mL).
- Prolactin levels >200 are usually due to prolactinoma.

▼Table 19–3.4 Prolactin Pharmacology

Prolactin Secretion From the Pituitary Is Controlled By:	
PRL Releasing Factor	**PRL Inhibiting Factor**
• Increase the synthesis and release of PRL from the pituitary • Hormones: —TRH —TSH • Drugs that *inhibit* dopaminergic activity (DA-antagonists): —Antipsychotics (chlorpromazine and haloperidol) —Metoclopramide —Antidepressants (imipramine) —Antianxiety agents	• Decrease the synthesis and release of PRL from the pituitary • Drugs that *increase* dopaminergic activity (DA-agonists): —Bromocriptine: Agonist of domaine D2-R→↓serum [PRL] —Cabergolin: Potent D2-R agonist with greater D2-R selectivity. More effective in reducing hyperprolactinemia than bromocriptine and has longer half-life that permits twice-weekly dosing

3.5 Growth Hormone (GH) Pathology

- Acromegaly versus gigantisim
- Direct versus indirect effects of growth hormone
- Lab diagnosis
  - Increased serum levels of IGF-1
  - Lack of suppression of GH with administration of an oral bolus of glucose

Please visit us at www.Groupinsiders.com

© DeVry/Becker Educational Development Corp. All rights reserved.

4 The Hypothalamus and Pituitary: Thyroid Hormone

4.1 Overview of Thyroid Disease

- Thyroid hormone regulation (feedback mechanisms)
- Thyroid hormone synthesis
- Thyroid hormone function tests (TFTs)

Clinical Application

Euthyroid Sickness Syndrome (ESS)

This condition demonstrates the significance of the *three forms of monodeiodonases*. Clinical features of ESS include:

- Patients have ↓ active T_3 and ↑ *reverse T_3* (inactive) because of decreased hormone processing.
- You can distinguish ESS from true hypothyroidism by measuring TSH.
- In ESS, TSH is not usually increased (will be low or "normal").
- In primary hypothyroidism, TSH is almost always increased.

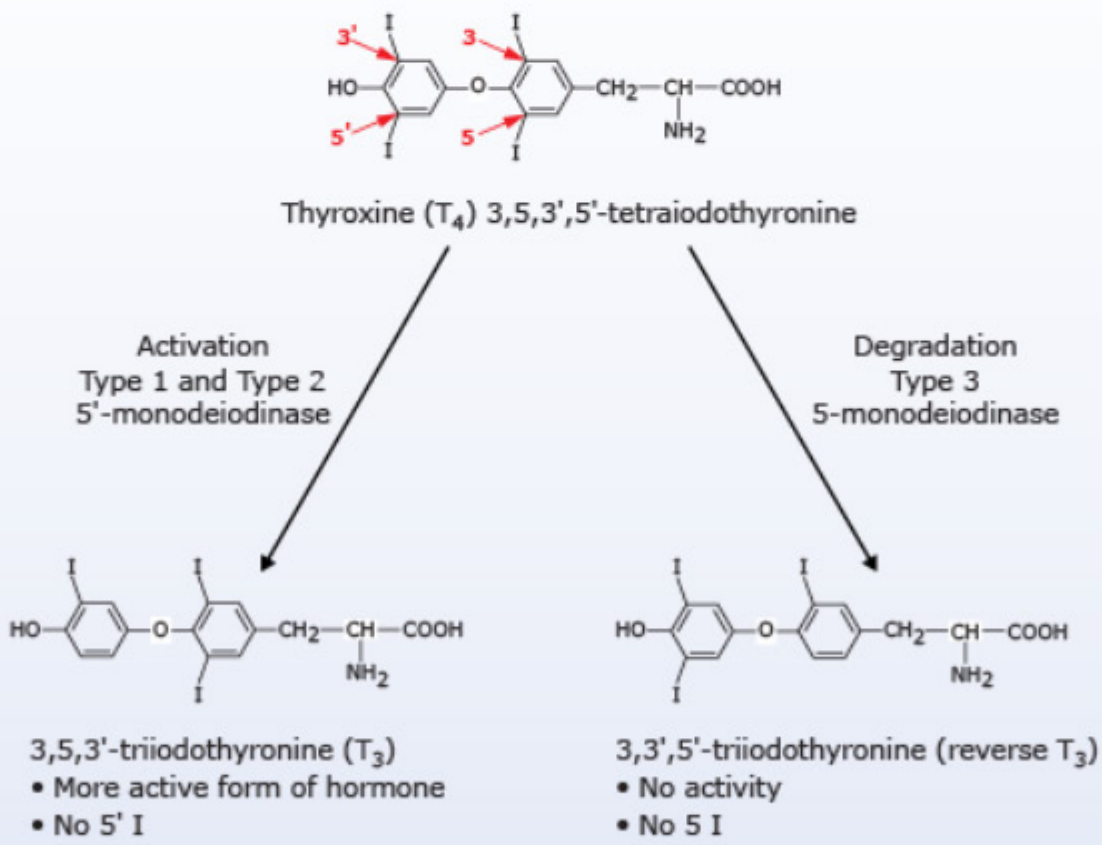

▲ **Figure 19–4.1** Three Forms of Monodeiodonases

Please visit us at www.Groupinsiders.com

© DeVry/Becker Educational Development Corp. All rights reserved.

4.2 Types of Thyroid Disease

4.2.1 Congenital Thyroid Disease

- Thyroglossal duct cysts
- Remnant of thyroglossal duct
- Ectopic thyroid tissue can be found anywhere along path
- *Does not* alter thyroid function but *can* give rise to ectopic thyroid cancers
- Thyroid aplasia → congenital hypothyroidism

Biophoto Associates/Science Source

▲ **Figure 19–4.2** Congenital Thyroid Disease

4.2.2 Functional Thyroid Disease

- Hyperthyroidism
- Hypothyroidism

4.2.3 Anatomic Thyroid Disease

- Goiters
- Thyroid nodules
- Thyroid cancer

4.3 Functional Thyroid Disease: Hyperthyroidism

- Graves disease
- Thyroiditis
- Choriocarcinoma
- Pituitary tumor
- Struma ovarii
- Exogenous ingestion of thyroid hormones

Please visit us at www.Groupinsiders.com

© DeVry/Becker Educational Development Corp. All rights reserved.

4.3.1 Graves Disease

- Stimulates greater production and release of T_4.
- Increased T_4 suppresses TSH.
- Increased T_4 leads to "hyper" metabolism (palpitations, atrial arrhythmias, sweating, loss of appetite, weight loss, anxiety, tremor, heat intolerance, amenorrhea).
- Graves disease only: Autoimmune complex deposition in eyes leads to exopthalmos ("bug" eyes), pretibial myxedema, thyroid acropachy, thyroid bruit.
- Elderly hyperthyroid patients commonly lack these signs and symptoms, presenting with weight loss, depression, and/or atrial fibrillation: "apathetic hyperthyroidism."

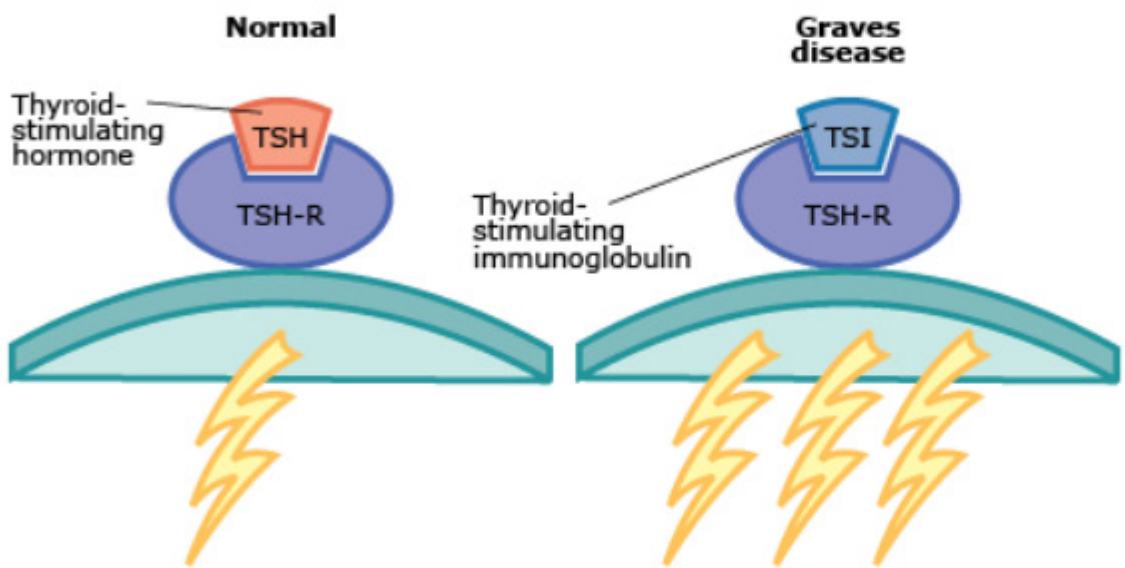

▲ **Figure 19–4.3A** Graves Disease

Biophoto Associates/Science Source

▲ **Figure 19–4.3B** Pretibial Myxedema

Dr. P. Marazzi/Science Source

▲ **Figure 19–4.3C** Graves Exopthalmos

Connection to Pharmacology

See *Pharmacology*, chapter 9, topic 7.3 for more about Graves disease.

Important Concept

Toxic multinodular goiter and solitary toxic adenomas (Plummer disease) are less frequently seen than Graves but represent a higher proportion of hyperthyroidism in the elderly.

Please visit us at www.Groupinsiders.com

© DeVry/Becker Educational Development Corp. All rights reserved.

4.3.2 Thyroiditis

- Group of diseases characterized by thyroid inflammation
- Types
  - Chronic lymphocytic (Hashimoto) thyroiditis
  - Subacute thyroiditis (de Quervain, granulomatous thyroiditis)
  - Amiodarone-induced thyroiditis

Chronic Lymphocytic (Hashimoto) Thyroiditis

- Most common cause of hypothyroidism in areas of the world where iodine levels are sufficient.
- Early in the course, presents as hyperthyroidism—"hashitoxicosis"—due to disruption of thyroid follicles allowing for significant release of thyroid hormones, which is then followed by the prototypical presentation of hypothyroidism.
- Characterized by gradual thyroid failure because of autoimmune destruction of the thyroid gland.
- Most prevalent in ages 45 to 65.
- Women to men ratio of 20:1.
- Associated w/HLA-DR5 and HLA-B5.

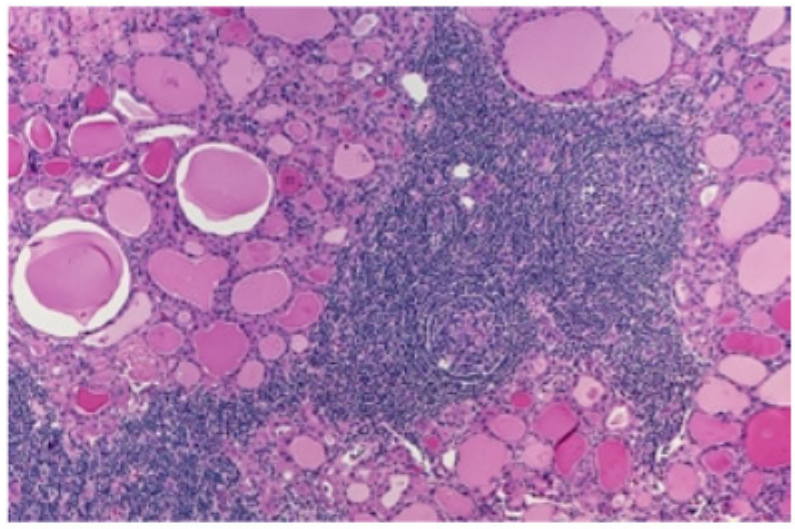

Dr. Gladden Willis/Visuals Unlimited, Inc.

▲ **Figure 19–4.3D** Hashimoto Thyroiditis: Hurthle Cells

Pathogenesis Involves antibodies targeted at any point of thyroid hormone production:

- Thyroglobulin
- Thyroid peroxidase (TPO)
- TSH receptor
- Iodine receptor

Morphology

- Diffuse enlargement of thyroid
- Firm, non-tender goiter
- Gland eventually becomes shrunken
- The thyroid parenchyma contains a dense lymphocytic infiltrate with germinal centers
- Residual thyroid follicles lined with deeply eosinophilic Hürthle cells

Subacute Thyroiditis (de Quervain, Granulomatous Thyroiditis)

- Caused by viral infections (mumps; Coxsackie), often preceding URI.
- Limited, self-resolving course with flu-like symptoms; painful, tender, irregular thyroid.
- More common in women. Typically three to six weeks of pain and thyrotoxicosis followed by several months of eurthyroid, then hypothyroidism.
- Treated with aspirin or NSAIDs; glucocorticoids if severe; beta blockade for symptomatic thyrotoxicosis.
- Focal destruction of thyroid tissue by granulomatous inflammation.

Important Concept

The pathogenic course of subacute thyroiditis can also be seen in silent (painless, postpartum) thyroiditis.

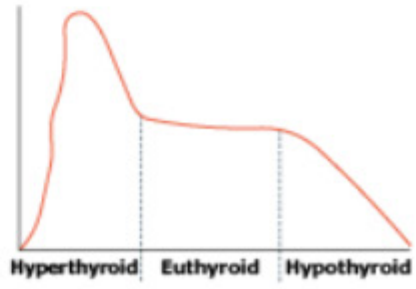

Please visit us at www.Groupinsiders.com

© DeVry/Becker Educational Development Corp. All rights reserved.

Amiodarone-Induced Thyroiditis

- Amiodarone structurally resembles thyroid hormone and contains iodine.
- Seen in ~3% of patients on amiodarone, usually after one to three years of therapy.
- Thyroid is not enlarged or tender.
- Can cause both hypo- and hyperthyroidism:
  - Blockage of conversion of T_4 to T_3 results in hypothyroidism.
  - Leakage of thyroid hormone into the circulation results in hyperthyroidism.

4.3.3 General Diagnosis of Hyperthyroidism

- History and physical exam.
- Thyroid exam may show goiter with or without nodules.

Laboratory Findings

- TSH will be low, at times undetectable, with the rare exception of TSH-producing adenoma.
- Increased free T_4.
- Elevated T_3 with normal free T_4 in 5% of patients (T_3 thyrotoxicosis).
- Thyroid-stimulating immunoglobulin (TSI).
  - Not necessary for diagnosis of Graves.
  - Helpful to measure in pregnancy and in euthyroid patients with Graves eye disease.
- Radioactive iodine (RAI) uptake and scan.

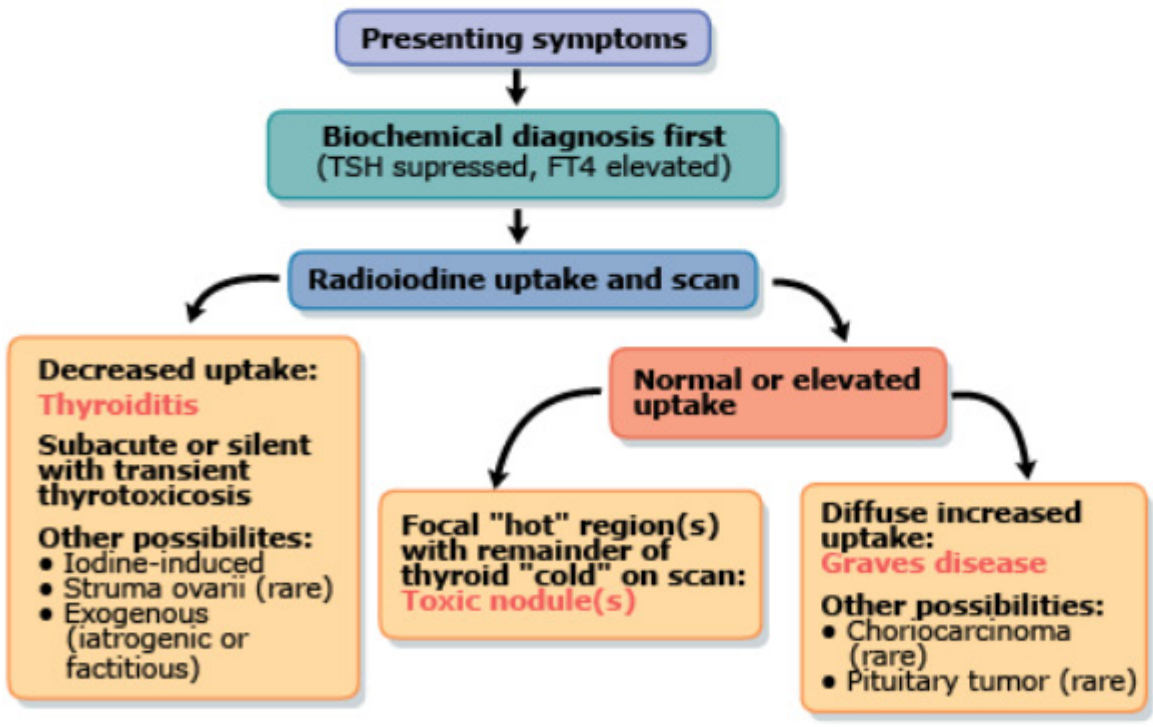

▲ **Figure 19–4.3E** Work-up for Hyperthyroidism

Please visit us at www.Groupinsiders.com

© DeVry/Becker Educational Development Corp. All rights reserved.

▼ **Table 19–4.3** Summary of Thyroid Disorders

Cause	Mechanism	Thyroid Exam	RAI
Graves disease	Stimulatory TSH-R antibodies (TSI)	Diffuse goiter	↑ (diffuse)
Toxic multinodular goiter or single toxic adenoma	Activating gene mutations	Nodule(s), usually >2.5 cm	↑ (focal)
Thyroiditis (subacute, silent, drug-induced)	Destruction with release of stored hormone	Tender in subacute thyroiditis; non-tender in silent	↓
Iodine-induced	Iodine surplus (Jod-Basedow)	Nodular or diffuse goiter	↓
Choriocarcinoma	hCG stimulates thyroid	Minimal goiter	↑
Pituitary tumor	↑ TSH	Minimal goiter	↑
Struma ovarii	Ectopic thyroid tissue	Normal	↓ (over thyroid)
Exogenous	Ingestion of T_4/T_3	Normal	↓

4.4 Functional Thyroid Disease: Hypothyroidism

- Defined by insufficient circulating TH levels for normal cellular function.
- Extremely common, especially in women.

Clinical Features

Generally, there are no pathognomonic signs or symptoms of hypothyroidism. The typical patient notes lethargy, fatigue, mild constipation, cold intolerance, and weight gain. Other signs and symptoms include:

- Dry skin
- Dulled facial expression, facial puffiness
- Myxedema (e.g. puffy hands, face, and eyelids) usually found in adults
- Coarse hair
- Hyperprolactinemia (e.g., galactorrhea)
- Yellow complexion from carotene accumulation
- Loss of lateral eyebrows



Dr. Koshy/Phototake, Inc.

Dr. Koshy/Phototake, Inc.

▲ **Figure 19–4.4A** Adult Hypothyroidism untreated (top), and treated (bottom)

Please visit us at www.Groupinsiders.com

© DeVry/Becker Educational Development Corp. All rights reserved.

Please visit us at www.Groupinsiders.com

Myxedema

This condition is marked by an accumulation of glycosaminoglycans (GAGs) and hyaluronic acid in various tissues. Myxedema coma occurs in patients with long-standing, untreated severe hypothyroidism. It is often precipitated by stress, such as systemic illness or surgery, and by sedative drugs. Myxedema presents as hypothyroidism with mental status changes, hypoventilation, and hypothermia with 50% mortality rate.

Etiology

Hypothyroidism is commonly due to chronic lymphocytic (Hashimoto) thyroiditis. Other causes include:

- Drugs such as lithium, amiodarone, PTU
- Acquired as seen with post-thyroidectomy
- Post-ablative therapy (^{131}I)

4.4.1 Hypothyroidism During Fetal Development

Thyroid hormone is crucial for brain development in the baby. Children born with congenital hypothyroidism can have severe developmental abnormalities if the condition is not recognized and treated promptly. These abnormalities can be prevented if treated immediately after birth. Hence, all newborns in the United States are screened for congenital hypothyroidism. If untreated, a baby can experience permanent intellectual disability and stunted growth, a disorder called *cretinism*.

Cretinism

- **Causes**
  - Iodine deficiency
  - Enzymatic deficiency
  - Failure of organ descent
  - Anti-thyroid antibodies from mother
- **Clinical Features**
  - Severe intellectual disability
  - Short stature
  - Coarse facial features
  - Large tongue
  - Protuberant abdomen with umbilical hernia

Wellcome Images

▲ **Figure 19–4.4B** Hyperthyroidism: Childhood Cretinism

© DeVry/Becker Educational Development Corp. All rights reserved.

▼ **Table 19–4.4A** Thyroid Function Tests During Pregnancy*

Thyroid Hormones	1st Trimester	2nd Trimester	3rd Trimester
TSH	Slightly Decreased	Normal	Normal
Free T_4 **Free T_3**	Normal Normal	Normal Normal	Normal Normal
Total T_4 **Total T_3**	High High	High High	High High

*Laboratory tests of thyroid function must be interpreted with caution during pregnancy.

4.4.2 Hypothyroidism Diagnostic Tests

- Free T_4 will be low in all forms.
- TSH increased in primary hypothyroidism due to lack of negative feedback by THs.
- Anti-thyroperoxidase (anti-TPO) and anti-thyroglobulin are frequently positive, but not needed to make the diagnosis.
- Hypothalamic or pituitary disease.
- Low or inappropriately normal TSH despite low circulating T_4.

▼ **Table 19–4.4B** Diagnostic Tests

Syndrome	FT4	TSH	Other
1° Hyperthyroidism	↑	↓	TSI Aby (Graves) • High RAIU (Graves) • Low RAIU (thyroiditis)
2° Hyperthyroidism	↑	↑	TSHoma (pituitary MRI)
1° Hypothyroidism (Hashimoto)	↓	↑	Anti-peroxidase Aby
2° Hypothyroidism	↓	↓	Pituitary failure (MRI)

Please visit us at www.Groupinsiders.com

© DeVry/Becker Educational Development Corp. All rights reserved.

4.5 Anatomic Thyroid Disease

4.5.1 Goiter

Clinical definition of goiter is a large thyroid (>25 grams).

Types

- Does not describe the functional state of the thyroid
- Nontoxic = euthyroid
- Toxic = hyperthyroid
- Nodular = multiple nodules that are "hot" or "cold"
  - Hot is almost always benign
  - Cold may be benign or malignant
  - Only a biopsy can tell definitively whether malignant or benign

Etiology

- Physiologic
- Lack of hormone production (driven by TSH)
  - Iodine lacking in the diet in developing countries
  - Goitrogens: Foods or drugs that suppress synthesis of thyroid hormones
  - Enzyme deficiencies of hormone synthesis

Goiter vs. Thyroid Nodule

- Goiter = chronic enlargement of thyroid.
- Nodule = discrete lump in thyroid.
- Frequency of small thyroid nodules detected by ultrasound is greater than 50%.
- 5% to 10% of nodules may contain thyroid cancer.
- Most patients are asymptomatic:
  - *Large goiter or nodules* may cause discomfort, *dysphagia*, *hoarseness*, and *dyspnea*.
  - *Substernal goiter* can be nonpalpable but cause airway obstruction or *thoracic inlet obstruction*.

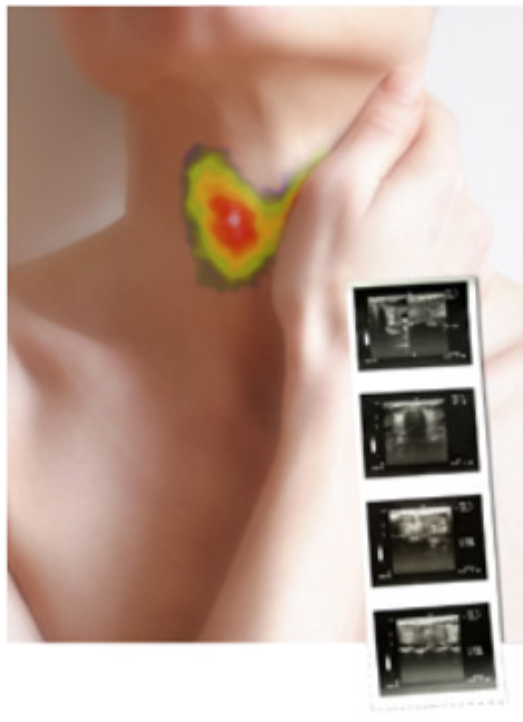

▲ **Figure 19–4.5A**
Benign "Hot" Nodule

Miriam Masto/Science Source

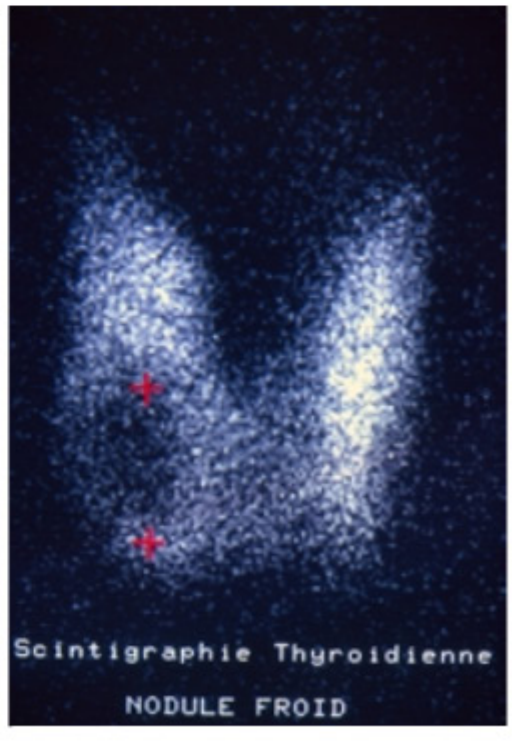

Frédéric Astier/Science Source

▲ **Figure 19–4.5B**
"Cold" Nodules

Please visit us at www.Groupinsiders.com

© DeVry/Becker Educational Development Corp. All rights reserved.

4.5.2 Thyroid Nodules

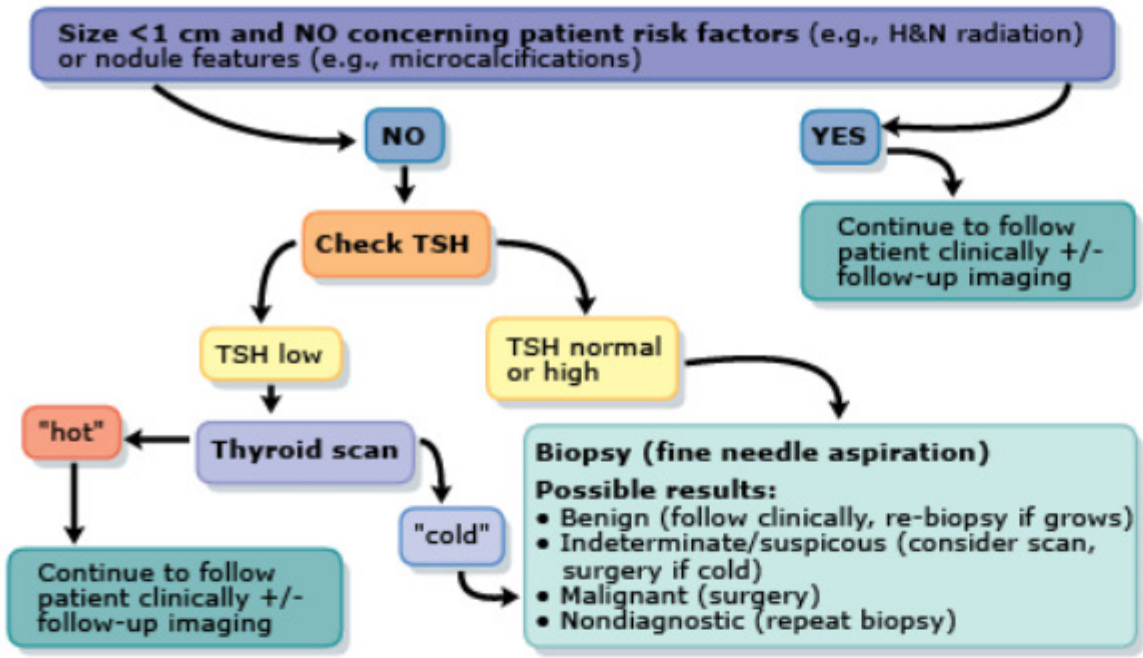

▲ **Figure 19–4.5C** Approach to Thyroid Nodule

4.5.3 Thyroid Neoplasia

Thyroid Carcinomas Signs and symptoms can include:

- Solitary nodules
- Nodules in younger patients
- Nodules in males
- Radiation exposure
- Nodules that do not take up iodine (cold nodules); hot nodules usually are benign

Thyroid Adenomas

- Discrete, solitary masses
- Variety of histologic patterns; however, the key feature is a *well-circumscribed capsule with no invasion*
- Clinical Features
  - Present as painless mass
  - Usually nonfunctional

4.5.4 Thyroid Carcinoma

- Most cases occur in adults
- Female predominance
- Subtypes
  - Papillary (75% to 85%)
  - Follicular (10% to 20%)
  - Medullary (5%)
  - Anaplastic (<5%)
  - Lymphoma
- Risk Factors: Ionizing radiation
- Pathogenesis: *RET protooncogene* plays a role in papillary and medullary thyroid carcinomas, and encodes the *tyrosine kinase receptor*

Please visit us at www.Groupinsiders.com

© DeVry/Becker Educational Development Corp. All rights reserved.

Papillary Carcinoma of the Thyroid

- Most common form of thyroid cancer:
  - Occurs at any age, most often 20 to 40 years old
  - High incidence in patients with Gardner syndrome
- Clinical Features
  - Presents with asymptomatic thyroid nodules
  - Hoarseness, dysphagia, cough, or dyspnea
  - Most papillary lesions are cold masses on scintiscans
- Prognosis: Excellent even if lymph nodes are involved

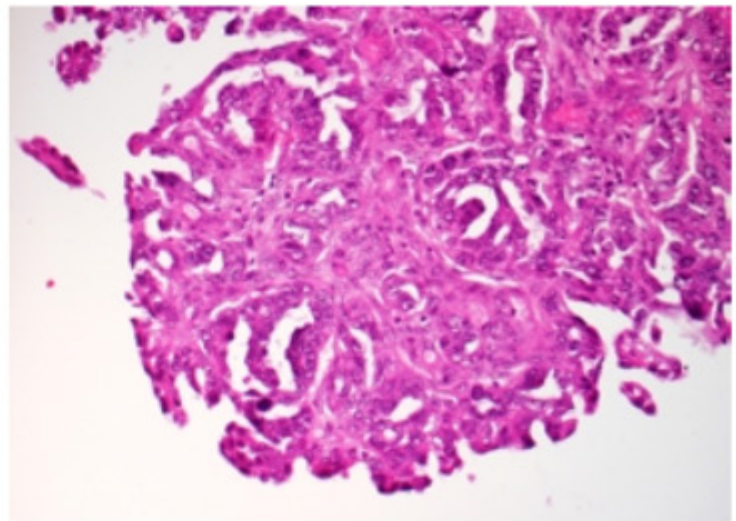
J.L. Carsory/Custom Medical Stock Photo

▲ **Figure 19–4.5D** Psammoma Bodies

Follicular Carcinoma of the Thyroid

- Second most common form of thyroid cancer
- Clinical Features
  - Slowly enlarging painless nodules
  - Cold nodules on thyroid scan
  - *Invades capsule and vascular system*
- Treated with lobectomy or subtotal thyroidectomy

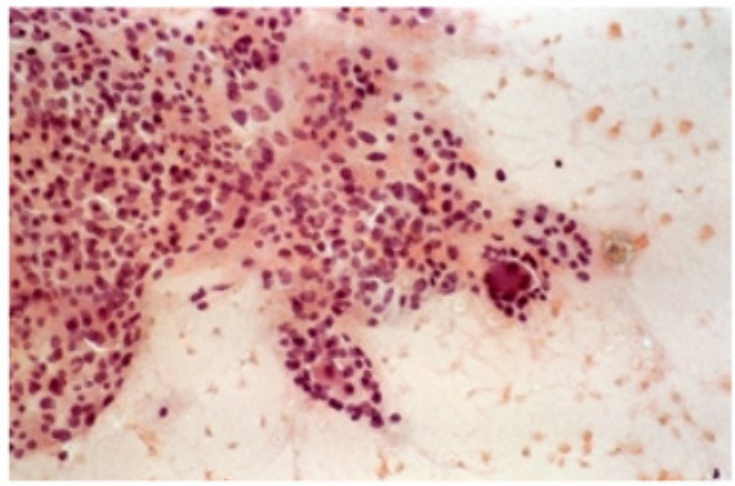
Wellcome Images

▲ **Figure 19–4.5E** Follicular Carcinoma

Medullary Carcinoma of the Thyroid

- Neuroendocrine thyroid tumor derived from parafollicular cells (C cells)
- Secrete calcitonin causing hypocalcemia
- Sheets and nests of tumor cells in an amyloid stroma
- May occur in MEN *IIA or IIB*
- *RET* protooncogene important in pathogenesis
- Peak incidence ages 40 to 50
- Clinical Features
  - Paraneoplastic syndromes
  - Diarrhea due to secretion of VIP

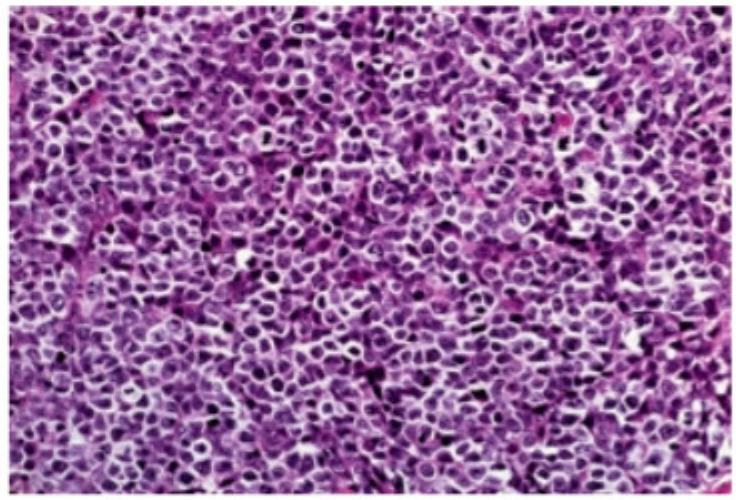
Biophoto Associates/Science Source

▲ **Figure 19–4.5F** Anaplastic Carcinoma

Anaplastic Carcinoma

- Undifferentiated tumor of follicular epithelium
- Aggressive
- Mortality approaches 100%
- Mean age is 65 years
- Pathogenesis may be related to loss of p53 tumor suppressor gene
- Clinical Features
  - Rapidly enlarging bulky neck mass
  - Dyspnea, dysphagia, hoarseness, and cough common

Please visit us at www.Groupinsiders.com

© DeVry/Becker Educational Development Corp. All rights reserved.

5 The Hypothalamus and Pituitary: Adrenals

5.1 Overview of Adrenals

- Biosynthesis of steroid hormone in the adrenal cortex
- Layers of the adrenal cortex with their respective release of hormones and functions

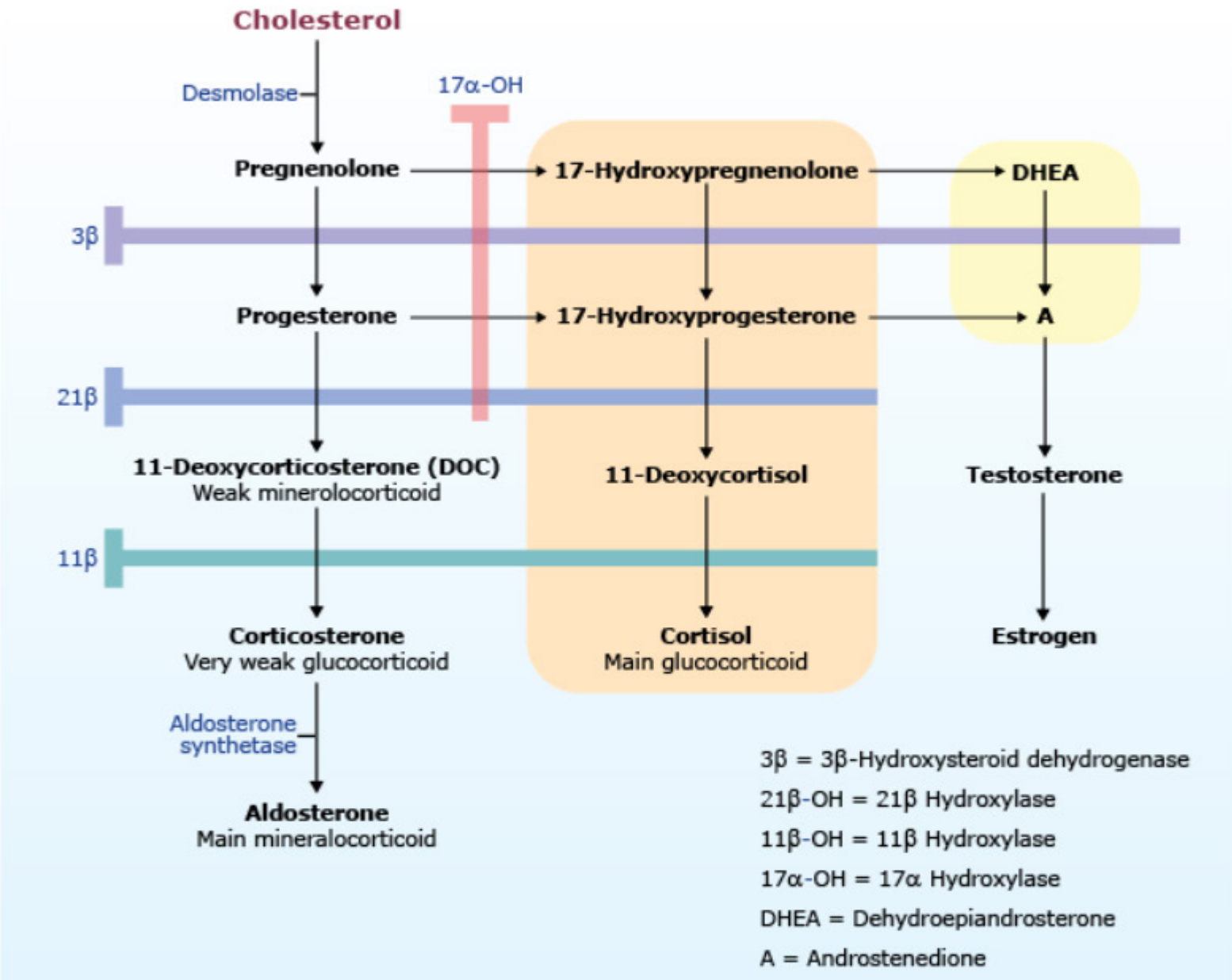

▲ **Figure 19–5.1A** Pathways of Steroid Hormones Synthesis

Please visit us at www.Groupinsiders.com

© DeVry/Becker Educational Development Corp. All rights reserved.

5.1.1 Hyperaldosteronism

Hyperaldosteronism can be subdivided into *primary* and *secondary* forms depending on what is "driving" the pathology.

Primary

- *Adrenal gland itself* is inappropriately overproducing aldosterone without extra-adrenal clues.
- Causes
  - Aldosterone producing adenoma (Conn syndrome)
  - Bilateral adrenal hyperplasia
  - Adrenal carcinoma (rare)
- ↑ ALDO → ↓ RENIN
- HTN (Na retention), low K^+ (K^+ secretion), alkalosis (H^+ secretion)

Secondary

- Adrenal glands are acting in response to overstimulation of the RAAS (e.g., CHF, renal ischema).
- ↑ RENIN → ↑ ALDO
- Edema, HTN, low K^+, alkalosis

5.1.2 Hypoaldosteronism

Hypoaldosteronism results in type 4 renal tubular acidosis. It is characterized by hyperkalemia, a mild metabolic acidosis which may be due to suppression of ammonia excretion.

Causes

- Hyporeninemic: Common in chronic kidney disease and diabetic nephropathy
- Also seen with NSAIDs, cyclosporine, HIV
- Hyperreninemic: ACE inhibitor therapy, heparin, primary adrenal insufficiency, K-sparing diuretics, congenital adrenal hyperplasia

Diagnosis Observe patient in upright position for three hours, check plasma renin activity (PRA), serum aldosterone, and serum cortisol. Note that PRA and aldosterone will be low in hypoaldosteronism secondary to hyporeninemia. PRA will be high in primary adrenal insufficiency.

Connection to Physiology

For more on hyperaldosteronism, see *Physiology*, chapter 34, topics 9.7 through 9.10.

Please visit us at www.Groupinsiders.com

© DeVry/Becker Educational Development Corp. All rights reserved.

5.2 Cortisol Overview

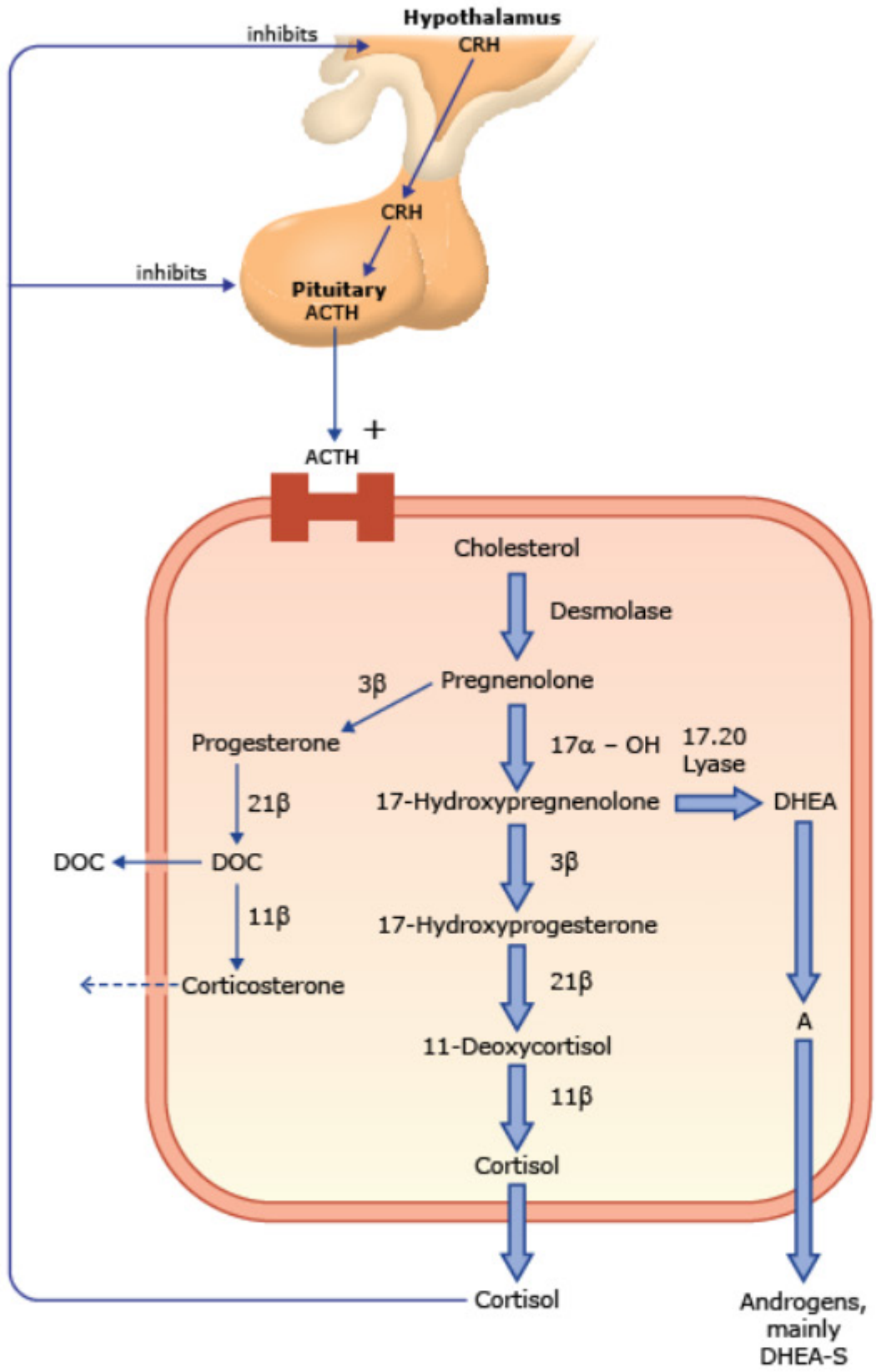

▲ **Figure 19–5.2A** Synthesis in Zona Fasciculata and Zona Reticularis

Please visit us at www.Groupinsiders.com

© DeVry/Becker Educational Development Corp. All rights reserved.

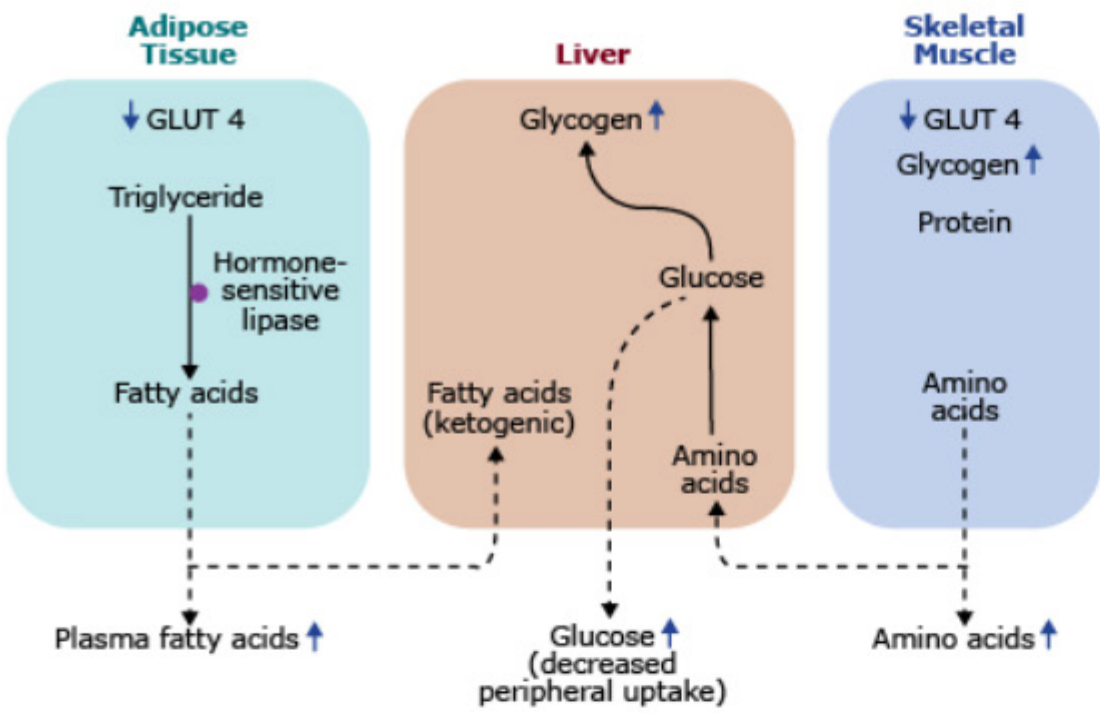

▲ **Figure 19–5.2B** Metabolic Actions of Cortisol

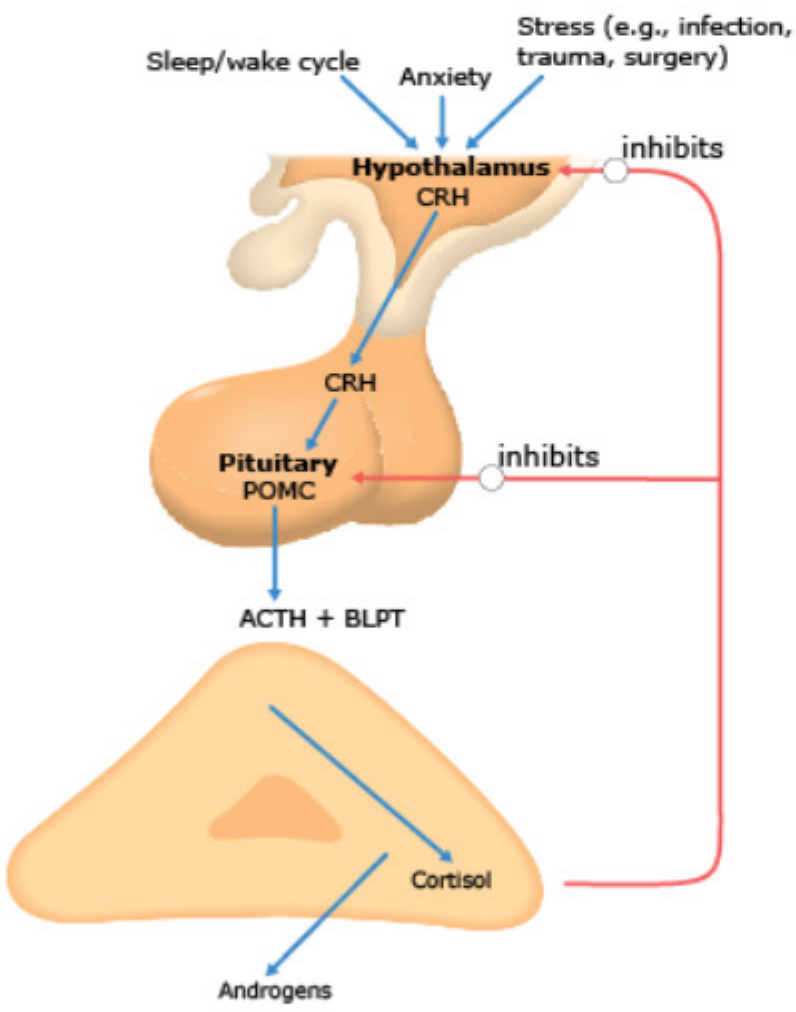

▲ **Figure 19–5.2C** Control of Cortisol Secretion

Please visit us at www.Groupinsiders.com

© DeVry/Becker Educational Development Corp. All rights reserved.

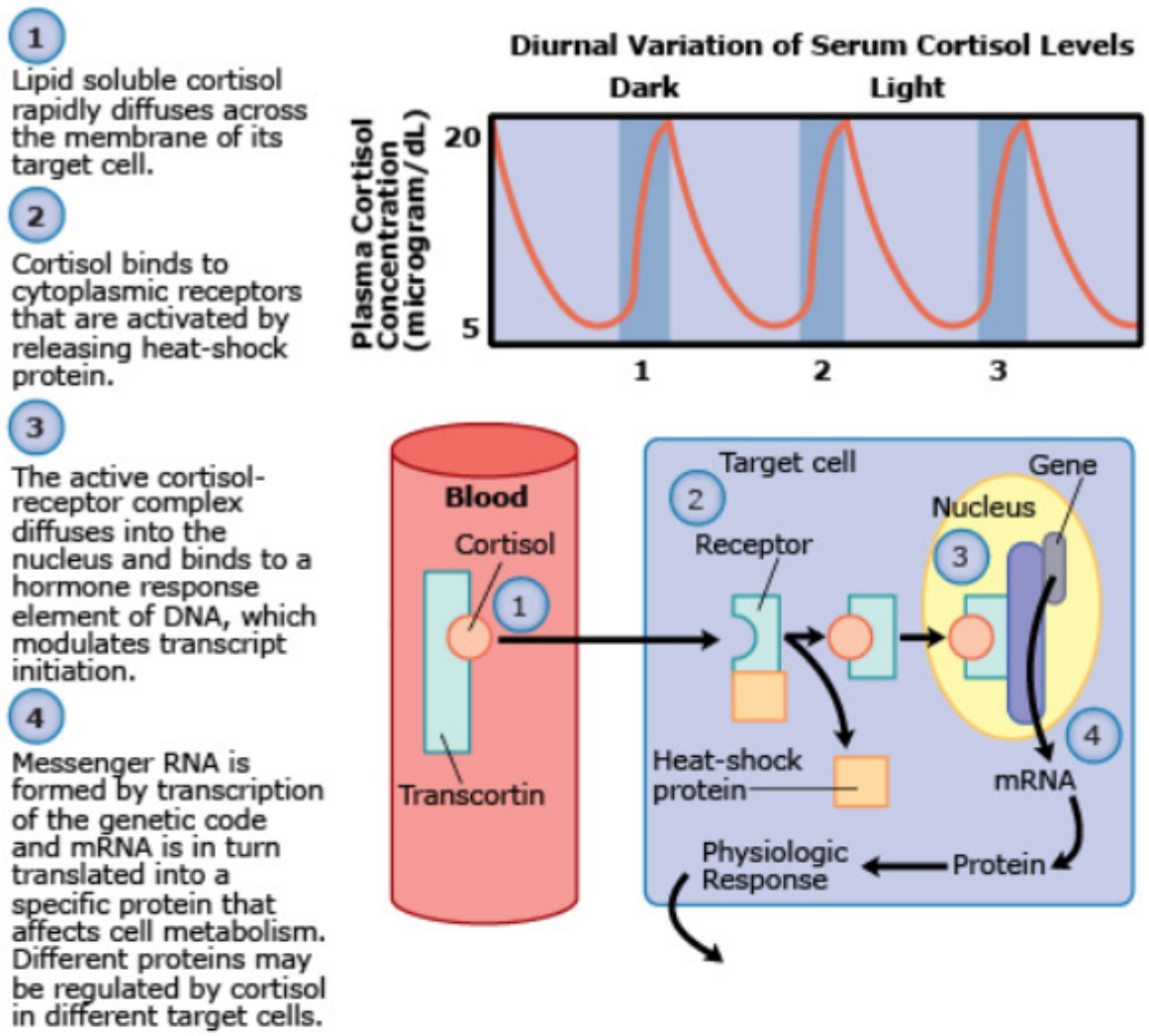

▲ **Figure 19–5.2D** Cortisol Secretion and Action

5.3 Cortisol Disorders

5.3.1 Adrenal Insufficiency: Addison Disease (Primary Adrenal Insufficiency)

- Autoimmune, as part of a polyglandular autoimmune endocrinopathy (hypothyroidism, type 1 diabetes, etc.).
- Infection (mycobacteria).
- Waterhouse-Friderichsen syndrome: Acute adrenal hemorrhage; can be secondary to meningococcemia, anticoagulation, in the setting of lupus anticoagulant, in association with DIC.
  - AIDS
  - Amyloidosis, sarcoidosis, hemochromatosis

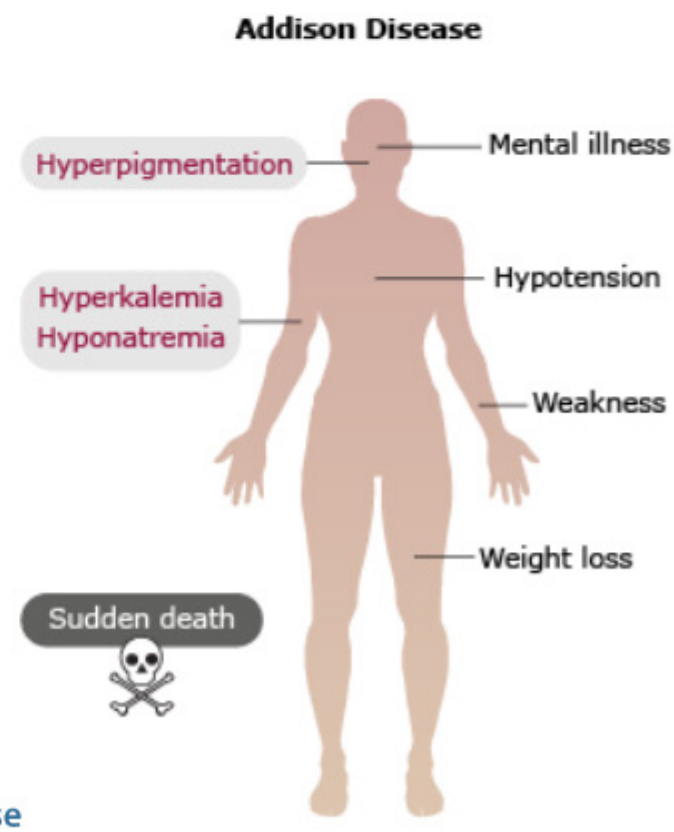

▶ **Figure 19–5.3A** Addison Disease

Please visit us at www.Groupinsiders.com

© DeVry/Becker Educational Development Corp. All rights reserved.

Wellcome Images/Custom Medical Stock Photo

▲ **Figure 19–5.3B**
Waterhouse-Friderichsen Syndrome

Biophoto Associates/Science Source

▲ **Figure 19–5.3C**
Adrenal Insufficiency: Hyperpigmentation

5.3.2 Secondary Adrenal Insufficiency (2° Hypocortisolism)

- Pituitary disease (hypofunction, tumor, trauma)
- Long-term exogenous steroid administration
- Clinical presentation of both 1° and 2° adrenal insufficiency
- Weakness, weight loss, anorexia, nausea, vomiting
- Hypotension (more pronounced in primary)
- Hyponatremia (less common in secondary)

5.3.3 Acute Adrenal Insufficiency (Addisonian Crisis)

Can be precipitated by severe physiologic stress (surgery, sepsis), patients with rapid development of adrenal insufficiency (e.g., adrenal hemorrhage, pituitary apoplexy).

5.3.4 Diagnosis of Adrenal Insufficiency

- Gold standard: Insulin tolerance test (ITT)
- Peak cortisol <18 mcg/dL after insulin-induced hypoglycemia
- Metyrapone testing
- If AI (low cortisol) is diagnosed based on any of the above tests:
  - High ACTH suggests *primary AI*; adrenal imaging to evaluate further.
  - Low or inappropriately normal ACTH suggests *secondary AI.*

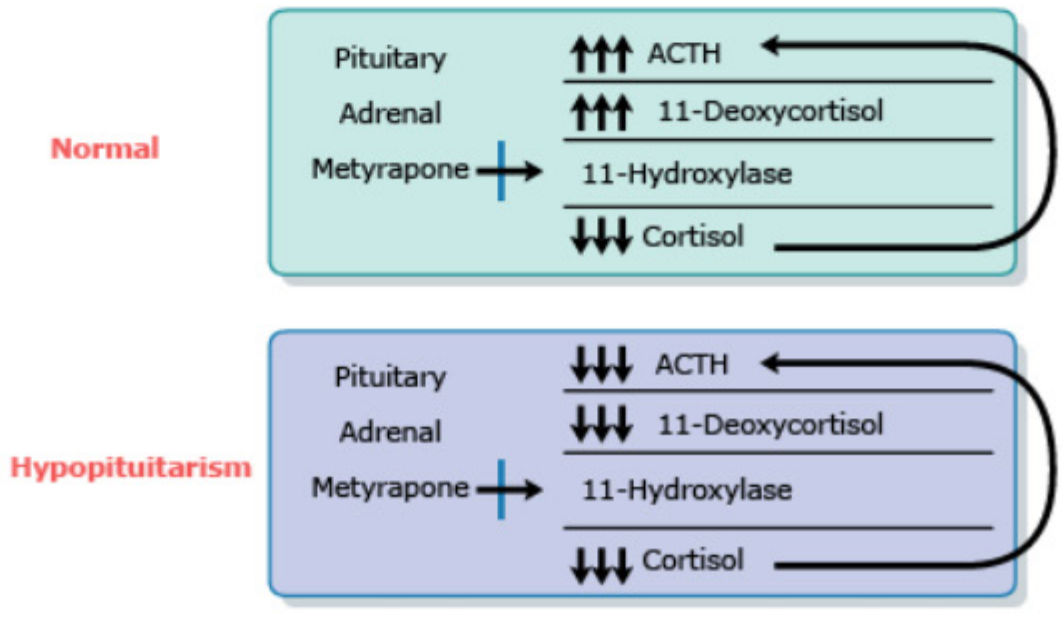

▶ **Figure 19–5.3D**
Metyrapone Test

Please visit us at www.Groupinsiders.com

© DeVry/Becker Educational Development Corp. All rights reserved.

5.3.5 Cushing Syndrome

- Caused by excess glucocorticoids, especially cortisol
- Sources include:
  - Iatrogenic: Exogenous administration of glucocorticoids (most common)
  - ACTH-independent: Adrenal hypersecretion of cortisol (adrenal adenoma, carcinoma, or hyperplasia)
  - ACTH-dependent
    - Pituitary hypersecretion of ACTH (Cushing disease)
    - Ectopic hypersecretion of ACTH: Bronchial carcinoids; small cell carcinoma of the lung

Clinical Features

- Central obesity
- Moon facies; facial plethora
- Acne; hirsutism
- Cervico-dorsal fat accumulation ("buffalo hump")
- Easy bruising (thinned skin)
- Muscle wasting
- Hypertension
- Glucose intolerance or diabetes
- Osteoporosis
- Immunosuppression
- Proximal weakness (specific compared with other signs/symptoms)
- Abdominal striae (specific if violaceous and broader than 1 cm)
- Psychological symptoms

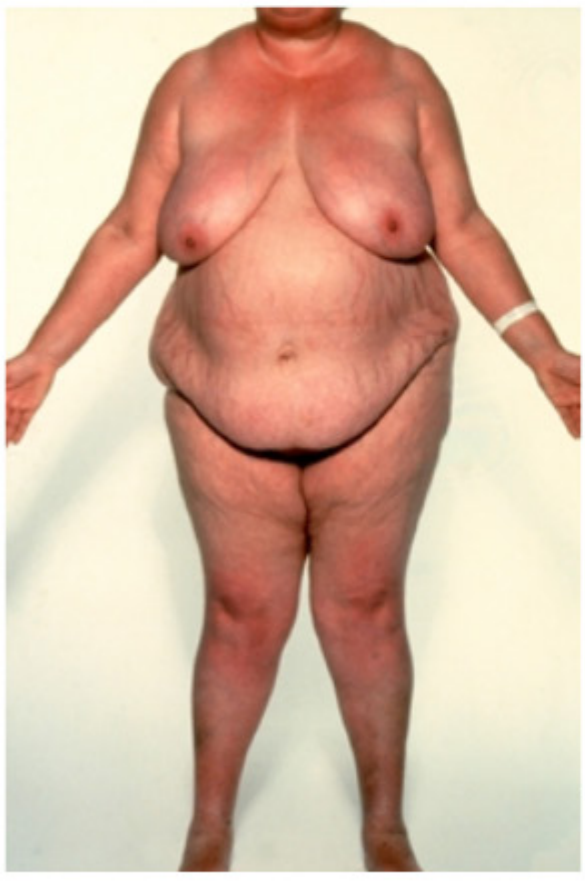

▲ **Figure 19–5.3E** Cushing Syndrome

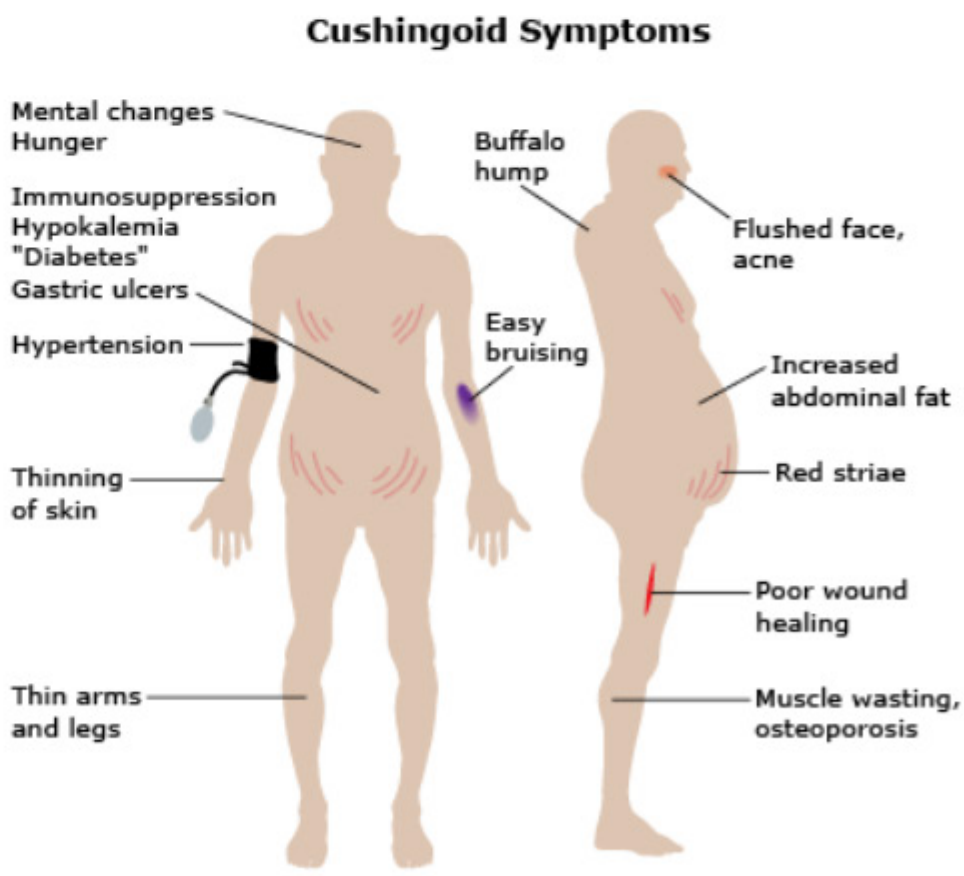

▲ **Figure 19–5.3F** Cushing Symptoms

Please visit us at www.Groupinsiders.com

© DeVry/Becker Educational Development Corp. All rights reserved.

Clinical Application

Cushing Syndrome

- Before diagnosing Cushing syndrome, one must exclude iatrogenic glucocorticoid administration then screen for endogenous hypercortisolism.
- Never proceed with work-up until after biochemical diagnosis of hypercortisolism is first firmly established.

Diagnosis

- **Step 1: Is there hypercortisolism?**
  - Dexamethasone is administered at night.
  - Normal individuals will have suppressed cortisol the following morning.
  - Patients with Cushing syndrome will *not* have suppressed levels of cortisol in the morning.
  - Positive test if suppressed cortisol is:
  - >5 ug/dL (more specific, better positive predictive value)
  - >1.8 ug/dL (more sensitive, better negative predictive value)
- **Step 2: Where is the excess cortisol coming from (adrenal vs. pituitary vs. ectopic)?**
  - After confirming the hypercortisolism, obtain plasma ACTH level.
  - If the source of the hypercortisolism is the adrenal cortex (ACTH independent), ACTH will be depressed and confirmation by imaging studies of the adrenals must be performed.
- **Step 3: Are ACTH levels elevated?**
  - Perform a high-dose (8 mg) overnight DST to distinguish between the two ACTH-dependent (pituitary vs. ectopic) conditions of hypercortisolism.
  - The first type of ACTH-dependent hypercortisolism is secreted by the anterior pituitary and known as Cushing disease (vs. syndrome).
  - The second type of ACTH-dependent hypercortisolism is secreted from an ectopic source, most commonly small cell (oat cell) cancer of the lung, in which the underlying cause must be immediately addressed.

Please visit us at www.Groupinsiders.com

© DeVry/Becker Educational Development Corp. All rights reserved.

5.3.6 Congenital Adrenal Hyperplasia

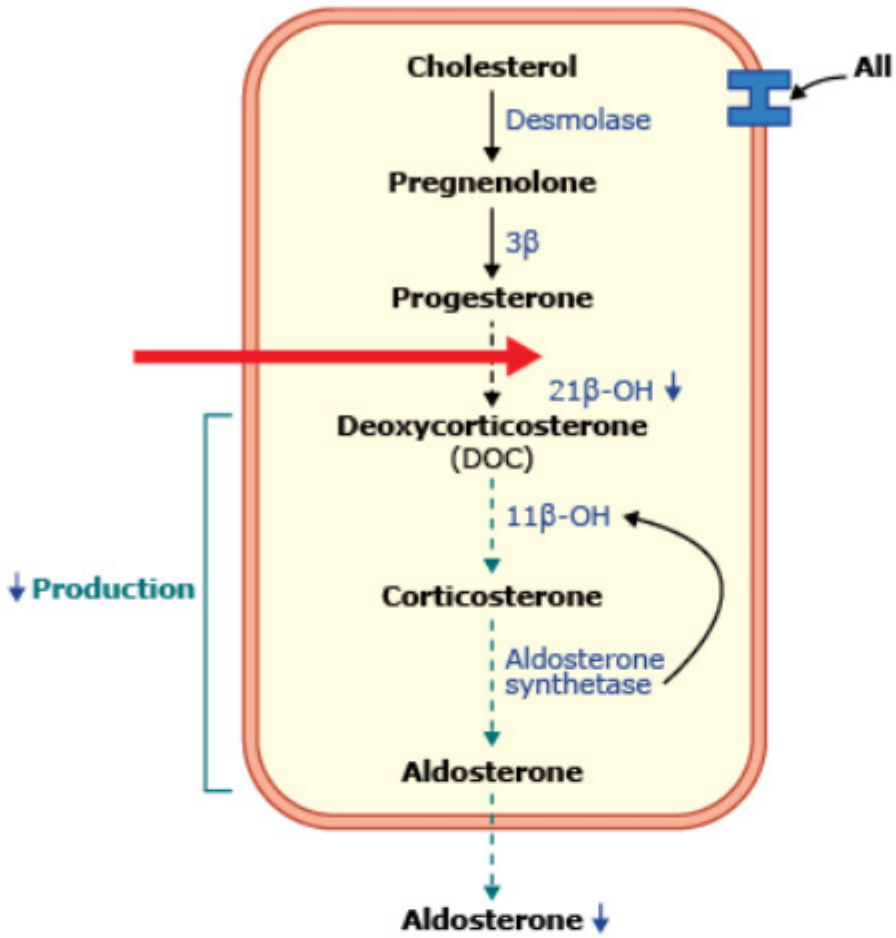

▲ **Figure 19–5.3G** 21β-Hydroxylase Deficiency—Zona Glomerulosa

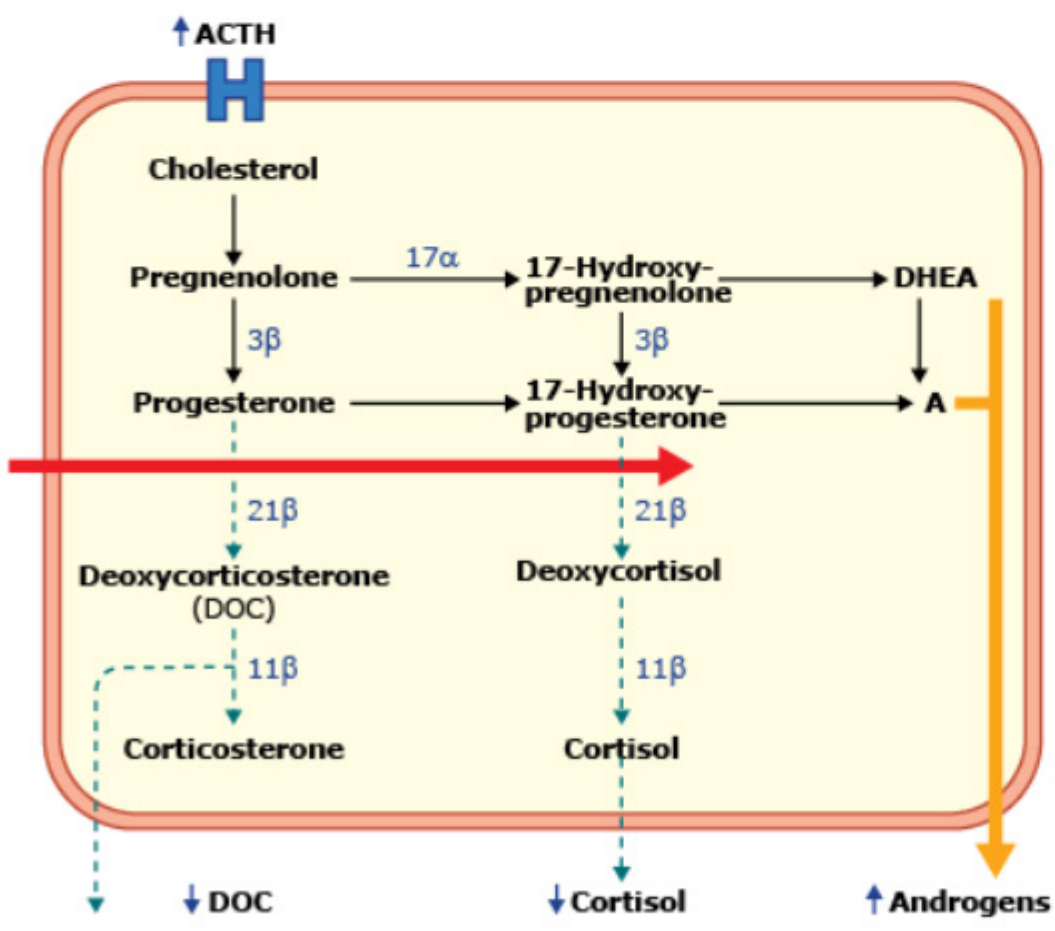

▲ **Figure 19–5.3H** 21β-Hydroxylase Deficiency—Zona Fasciculata, Zona Reticularis

Please visit us at www.Groupinsiders.com

© DeVry/Becker Educational Development Corp. All rights reserved.

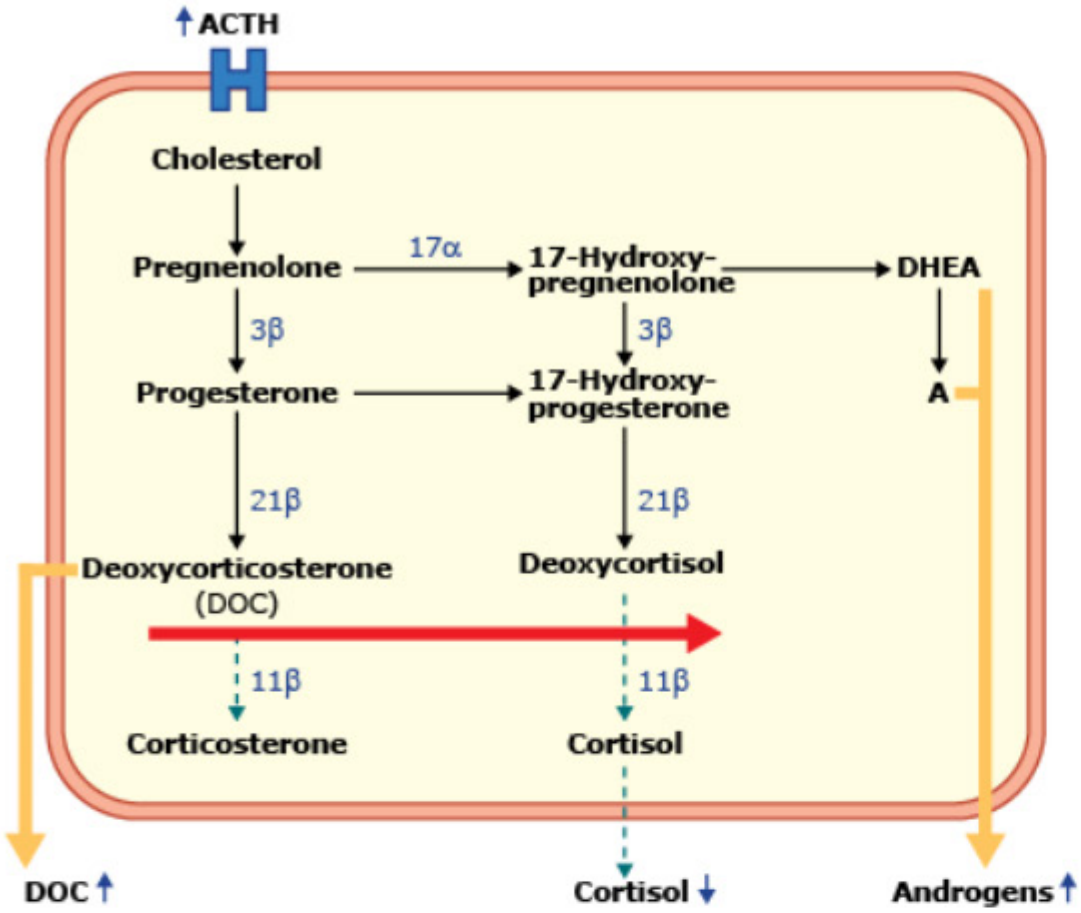

▲ **Figure 19–5.3I** 11β-Hydroxylase Deficiency—Zona Fasciculata, Zona Reticularis

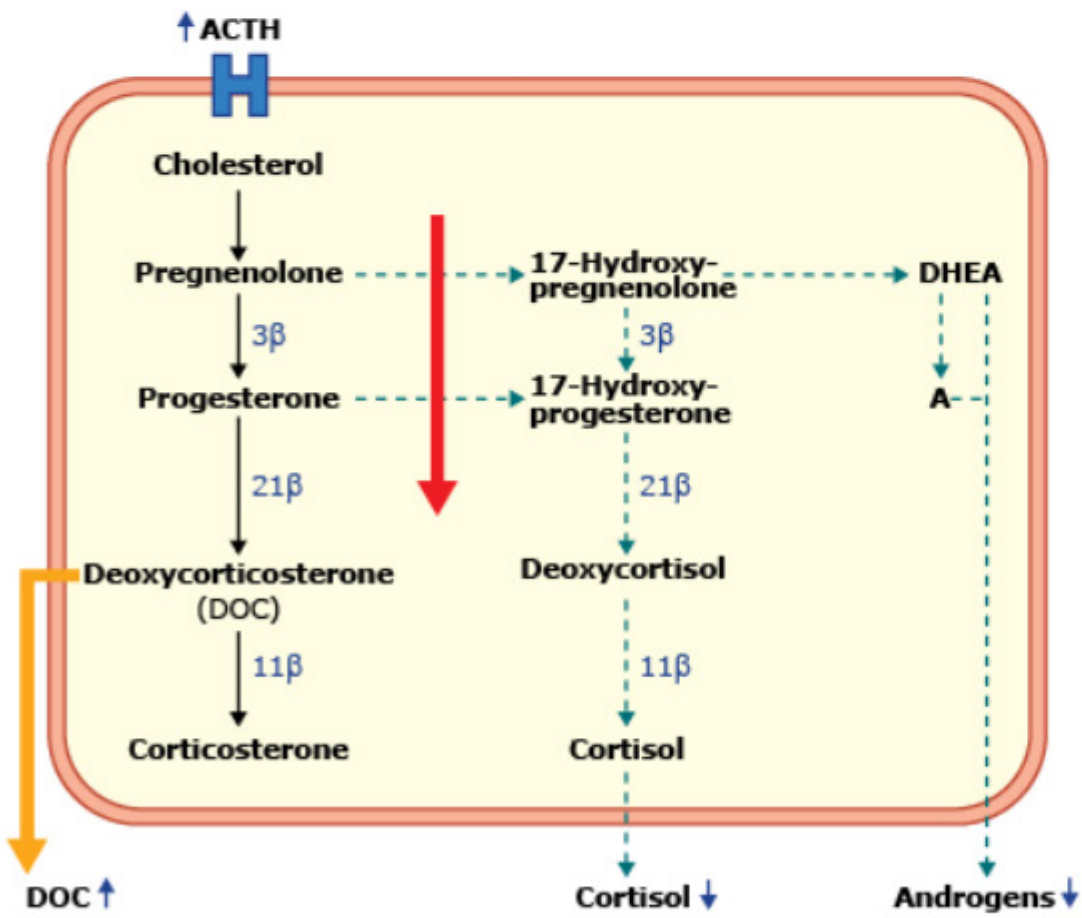

▲ **Figure 19–5.3J** 17α-Hydroxylase Deficiency—Zona Fasciculata, Zona Reticularis

Please visit us at www.Groupinsiders.com

© DeVry/Becker Educational Development Corp. All rights reserved.

▼ **Table 19–5.3** Congenital Adrenal Hyperplasia

Type	Clinical Features	Diagnostic Studies	Treatment
21b-Hydroxylase Deficiency (90% of cases)	Virilization of female infants. In some patients, *salt-wasting* is seen: hyponatremia, *hyperkalemia*, hypotension.	*High 17-OH progesterone.* Elevated serum DHEA, androstenedione.	Glucocorticoid therapy to reduce ACTH. Mineralocorticoid replacement.
11b-Hydroxylase Deficiency (5% of cases)	Virilization of female infants. *Hypertension* and hypokalemia.	*High 11-deoxycorticosterone.* Elevated serum DHEA, androstenedione.	Glucocorticoid therapy.
17a-Hydroxylase Deficiency (rare)	Hypogonadism, *hypertension*, and hypokalemia.	High 11-deoxycorticosterone, progesterone, FSH, LH. *Decreased levels of DHEA, estrogen, testosterone.*	Glucocorticoid therapy. Sex hormone replacement.
3b-Hydroxysteroid Dehydrogenase Deficiency (rare)	Virilization of female infants. *Male pseudohermaphroditism.* Salt wasting.	High ratio of δ-5-pregnenolone to progesterone.	Glucocorticoid, mineralocorticoid, sex hormone.

5.3.7 Adrenal Medulla: Pheochromocytomas

Uncommon cause of correctable *episodic hypertension* due to overproduction of epinephrine and norepinephrine.

- May be sporadic or associated with inherited syndromes.
- *Sporadic Form (90%)*
  - Ages 40 to 60, female predominance
  - 10% bilateral, 10% malignant
- *Hereditary Forms (10%)*
  - Onset in childhood, male predominance
  - 70% bilateral
  - Von Hippel-Lindau syndrome
  - Sturge-Weber syndrome
  - Neuroblastoma
  - Multiple endocrine neoplasia IIA (MEN IIA) and MEN IIB
  - Neurofibromatosis type 1

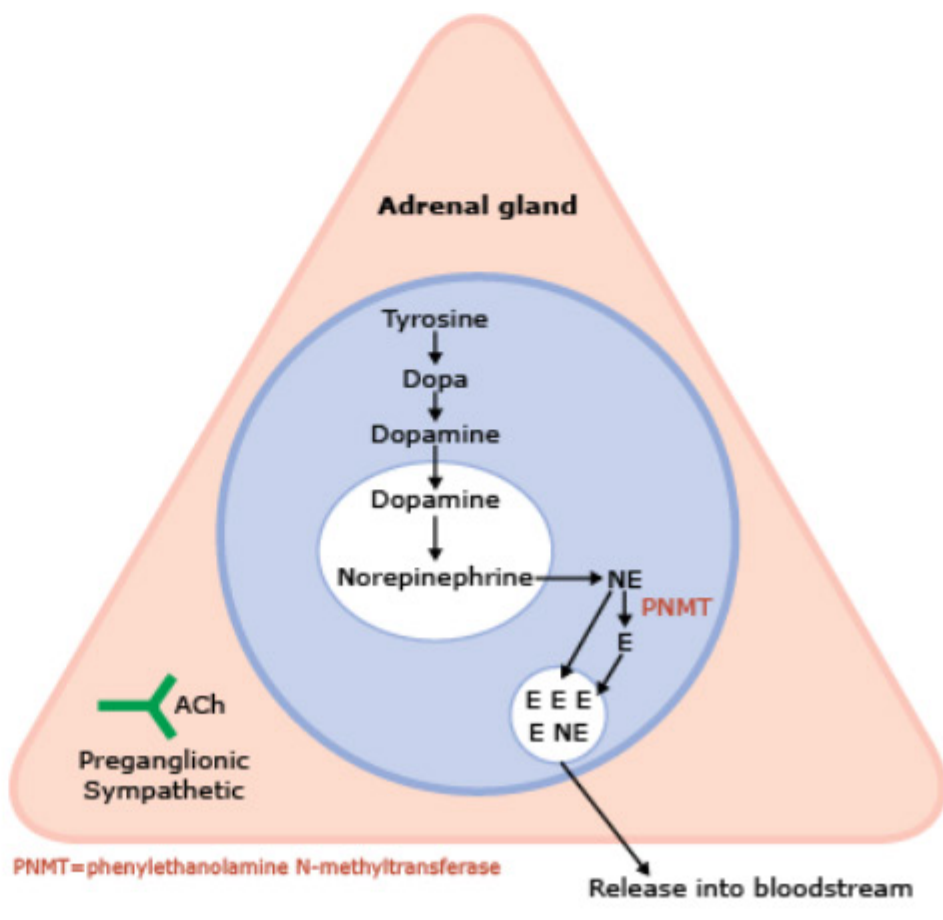

▲ **Figure 19–5.3K** Adrenal Medulla

Please visit us at www.Groupinsiders.com

© DeVry/Becker Educational Development Corp. All rights reserved.

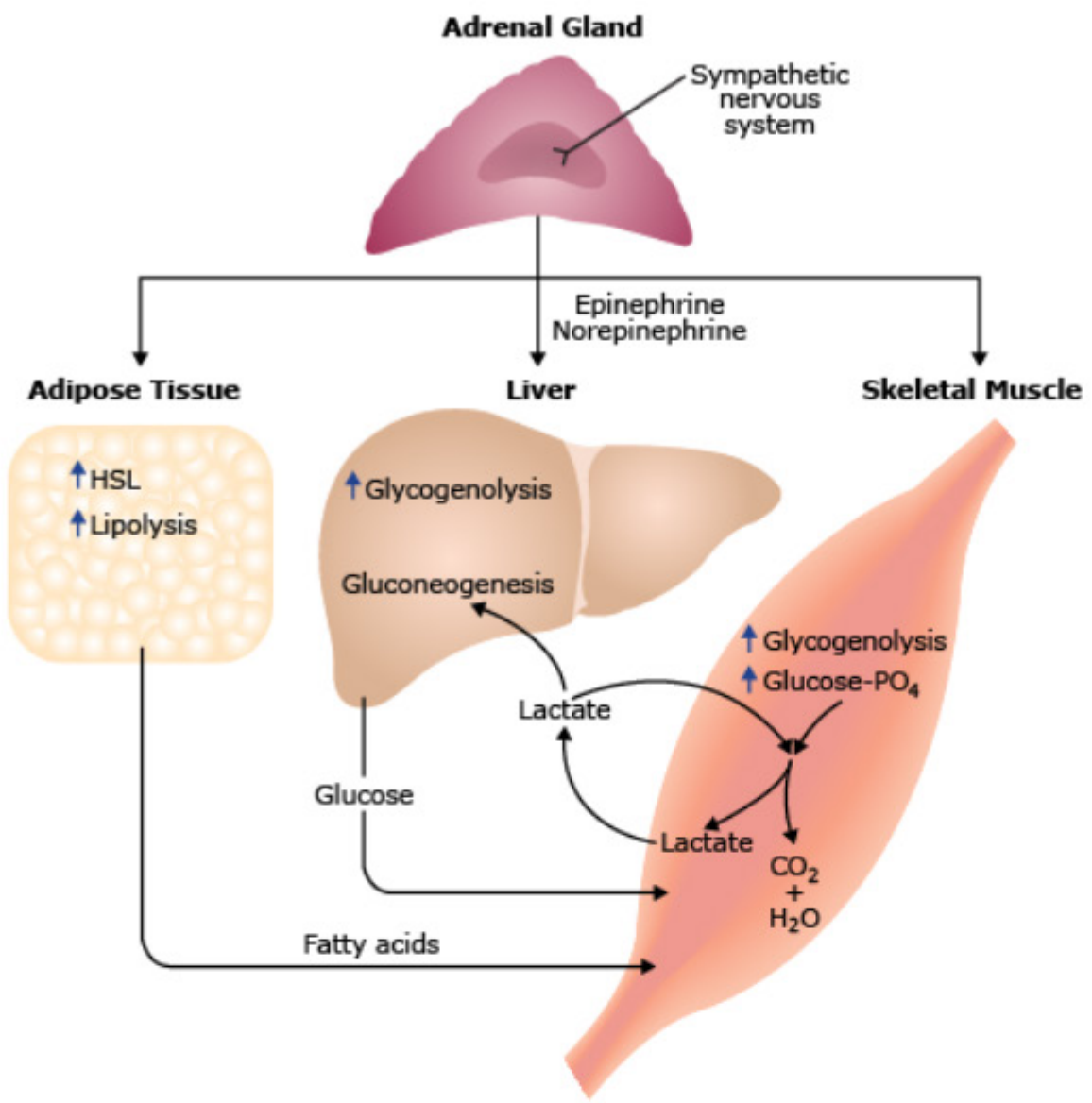

▲ **Figure 19–5.3L** Metabolic Actions of Epinephrine and Norepinephrine

Diagnosis

- No single "best" test.
- Most common approach: 24-hour urine for fractionated metanephrines (NMN +MN) or plasma-free metanephrines.
- Metabolites are more sensitive than parent catecholamines.
- Always confirm with biochemical tests before doing imaging tests.
- Magnetic resonance imaging preferred.

Important Concept

The "10% Rule" of pheochromocytomas:

- 10% malignant
- 10% bilateral
- 10% extra-adrenal (paragangliomas)
- 10% in children
- 10% familial
- 10% associated with MEN syndromes
- 10% recurrent

Please visit us at www.Groupinsiders.com

© DeVry/Becker Educational Development Corp. All rights reserved.

6 Endocrine Pancreas

6.1 Overview

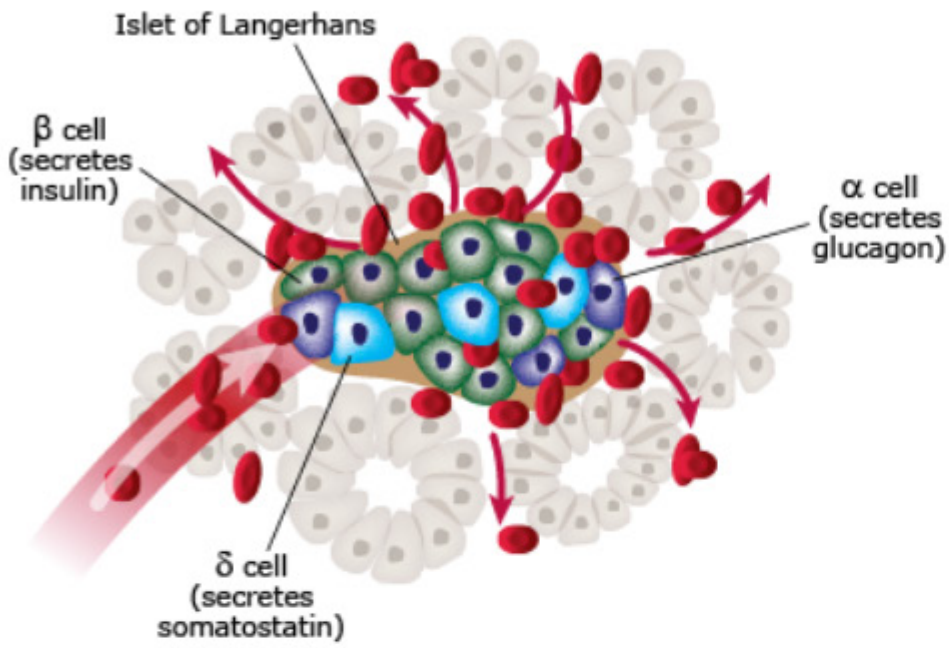

▲ **Figure 19–6.1A** Pancreatic Islets

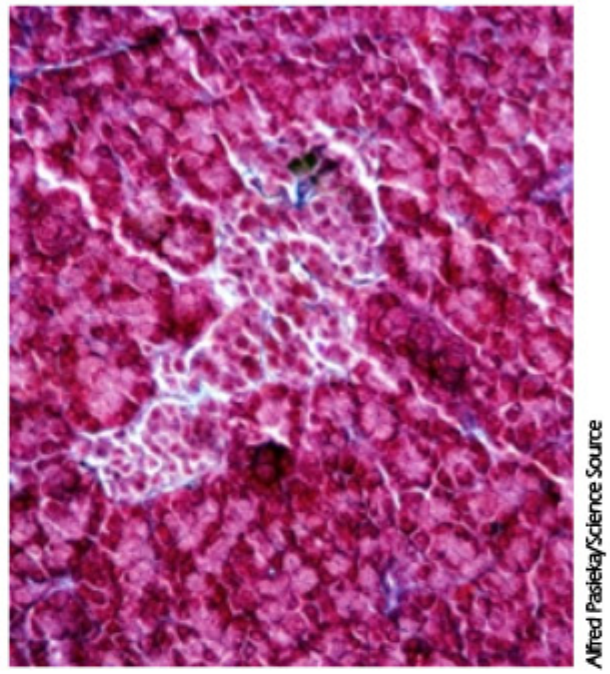
Alfred Pasieka/Science Source

▲ **Figure 19-6.1B** Pancreatic Islet Cell

▼ **Table 19–6.1** Pancreatic Islet Cells

Cell Types	Approximate Percentage of Islet Volume		Secretory Products
	Dorsally Derived (Anterior Head, Body, Tail)	Ventrally Derived (Posterior Portion of Head)	
A cell (α)	10%	<0.5%	Glucagon, proglucagon, glucagon-like peptides (GLP-1 and GLP-2)
B cell (β)	70%–80%	15%–20%	Insulin, C peptides, proinsulin, amylin, γ-aminobutyric acid (GABA)
D cell (δ)	3%–5%	<1%	Somatostatin
F cell (PP cell)	<2%	80%–85%	Pancreatic polypeptide

Clinical Application

Preproinsulin Processing in β Cells

Measuring C-peptide can be useful clinically in distinguishing between endogenously produced insulin (insulinoma) and recombinant (therapeutic) insulin.

Please visit us at www.Groupinsiders.com

© DeVry/Becker Educational Development Corp. All rights reserved.

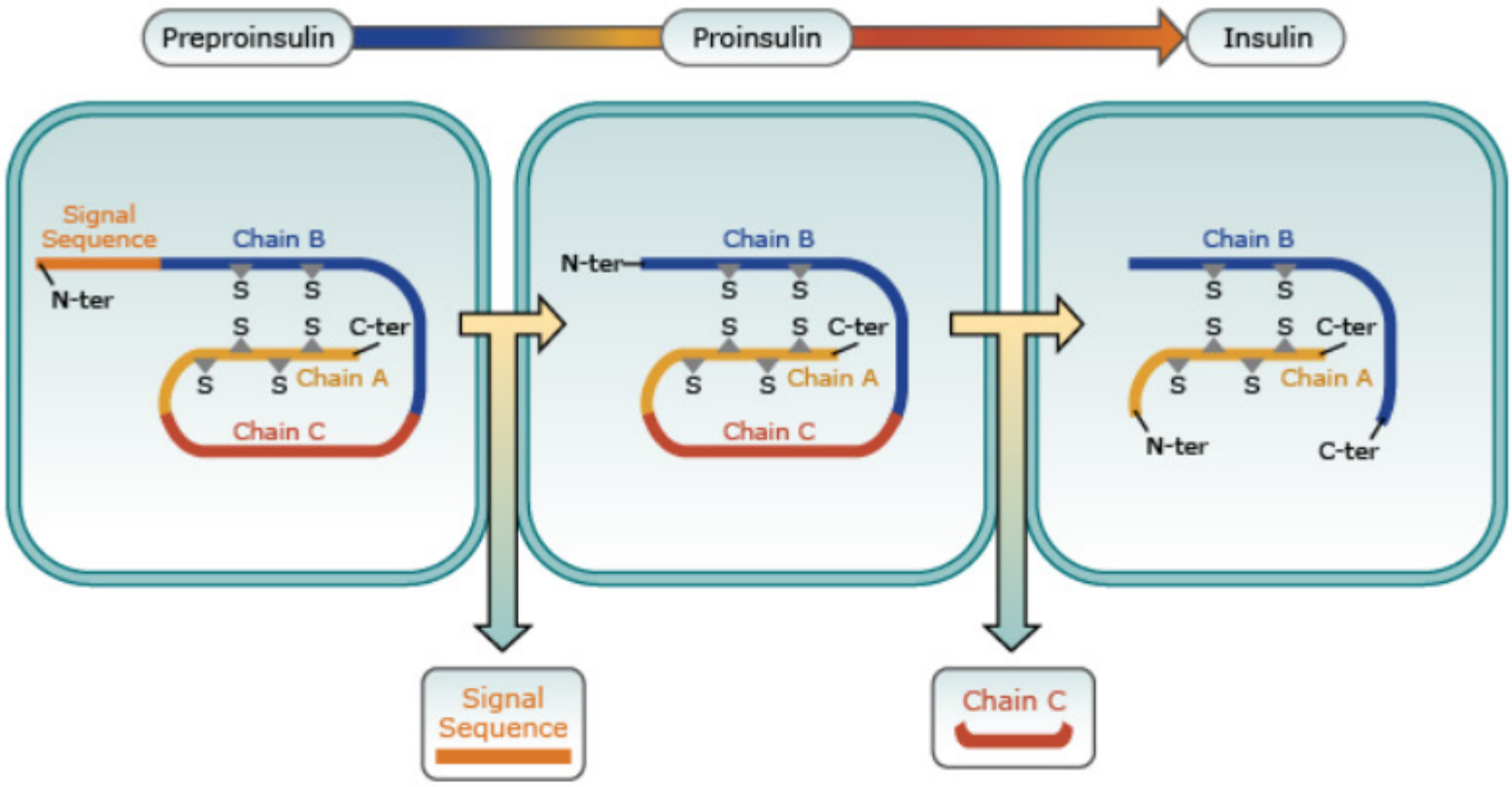

▲ **Figure 19–6.1C** Preproinsulin, Proinsulin, and Insulin

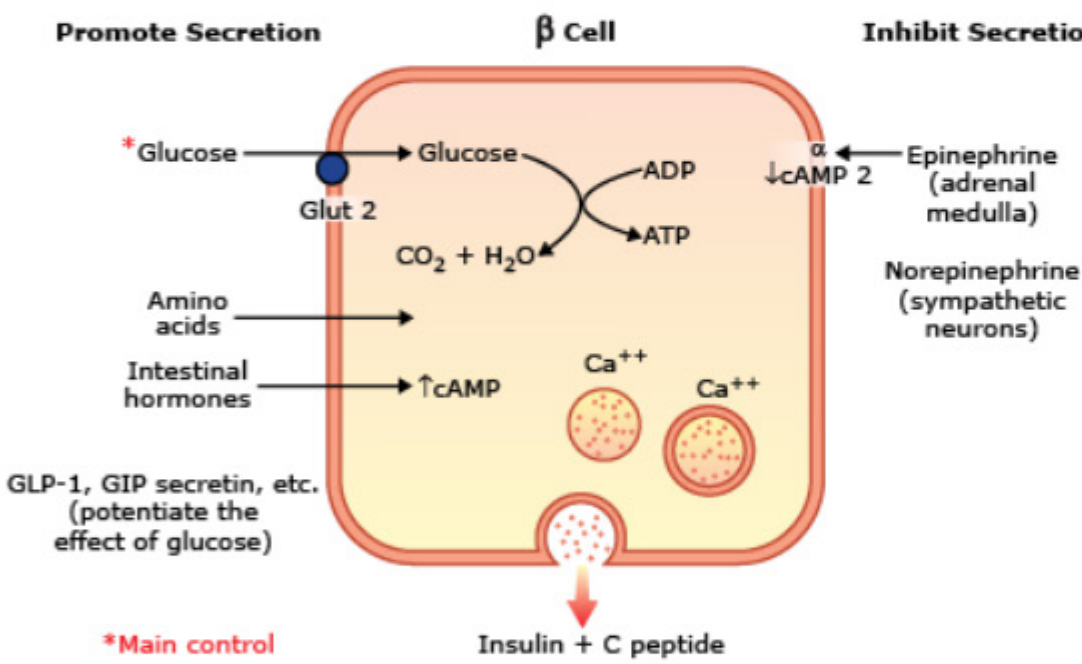

▲ **Figure 19–6.1D** Control of Insulin Secretion

Please visit us at www.Groupinsiders.com

© DeVry/Becker Educational Development Corp. All rights reserved.

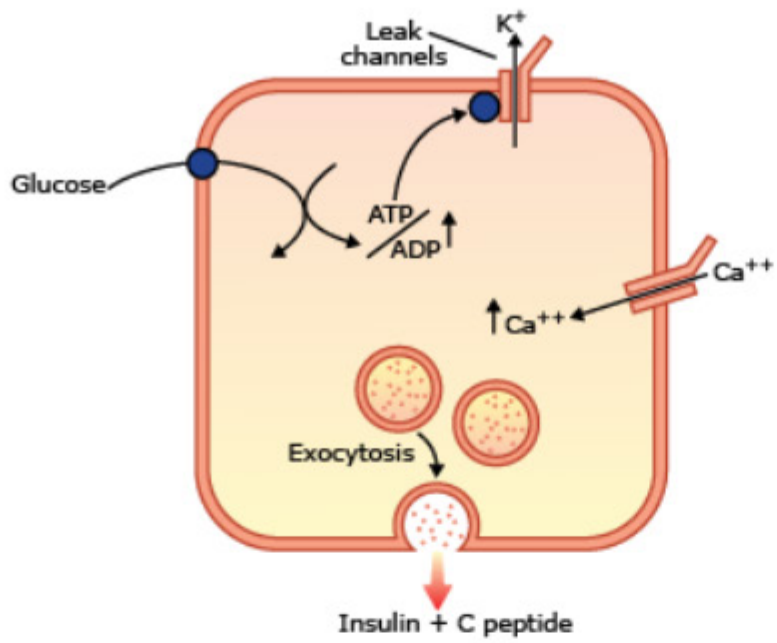

▲ **Figure 19–6.1E** β Cell Insulin Release

Connection to

Endocrine Physiology

For information on glucose homeostasis, see *Physiology*, chapter 31, topic 3.

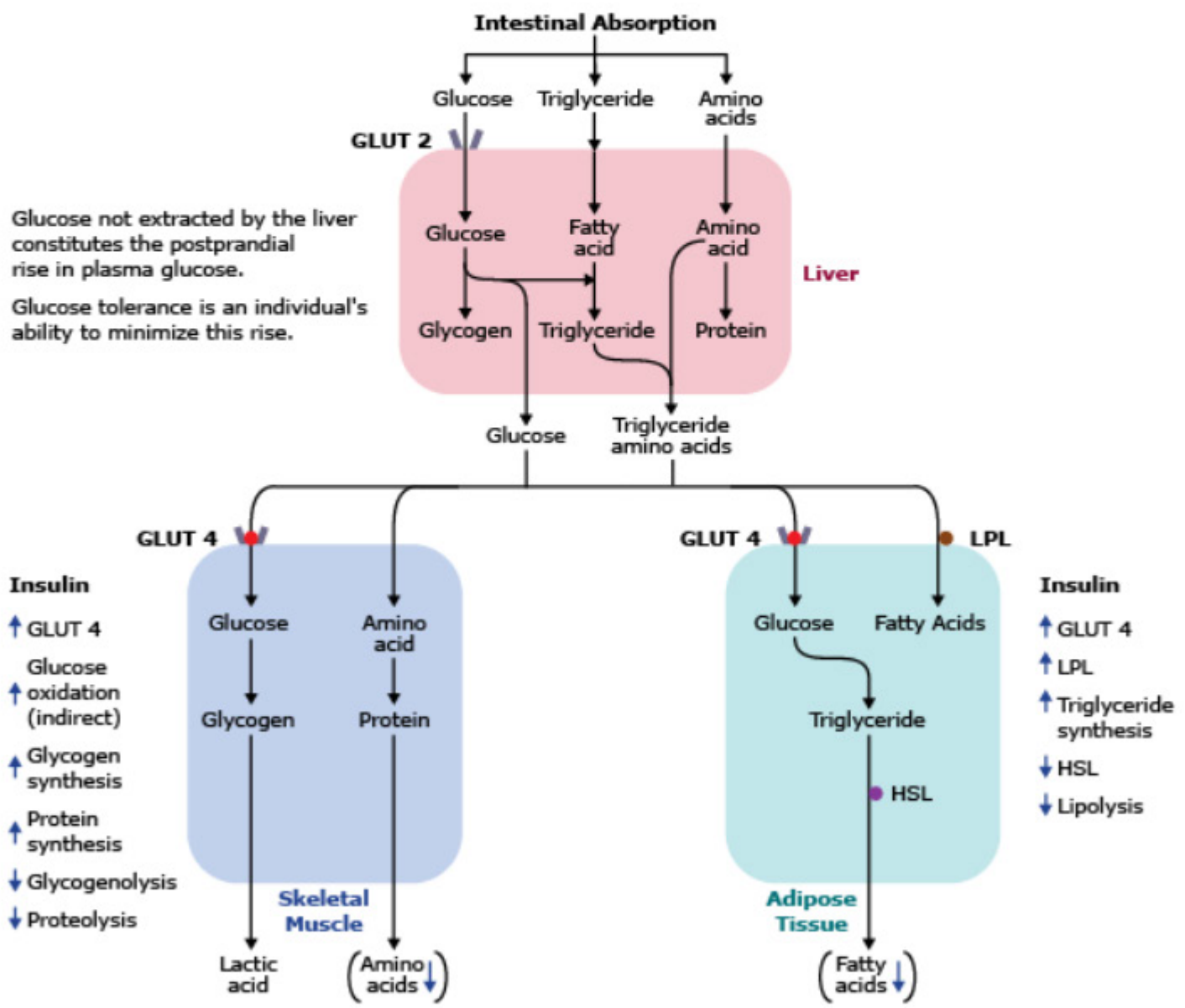

LPL—lipoprotein lipase—an extracellular lipase that clears triglyceride from the circulation.

HSL—hormone-sensitive lipase—an intracellular lipase that promotes lipolysis inhibited by insulin, activated by all stress hormones.

▲ **Figure 19–6.1F** Peripheral Actions of Insulin

Please visit us at www.Groupinsiders.com

© DeVry/Becker Educational Development Corp. All rights reserved.

6.2 Pancreatic Islet Cell Tumors

- Insulinoma
- Zollinger-Ellison syndrome, a gastrinoma
- Glucagonoma
- VIPoma

6.2.1 Insulinoma

- Most common islet cell tumor.
- Benign tumor of β-islet cells (all other pancreatic endocrine tumors are usually malignant).
- Approximately 80% have an association with multiple endocrine neoplasia type I (MEN I) syndrome.
- Whipple triad
  - Episodic hypoglycemia with glucose <50 mg/dL
  - CNS manifestations: Confusion, stupor
  - Hypoglycemia relieved with glucose intake

▼ **Table 19-6.2** Endogenous vs. Exogenous Insulin

	Insulinoma	Factitious	Sulfonylurea Overdose
Serum insulin level	Inappropriately high	Inappropriately high	Inappropriately high
Serum C-peptide level	Inappropriately high	Low	Inappropriately high
Serum/urine sufonylurea	Negative	Negative	Positive

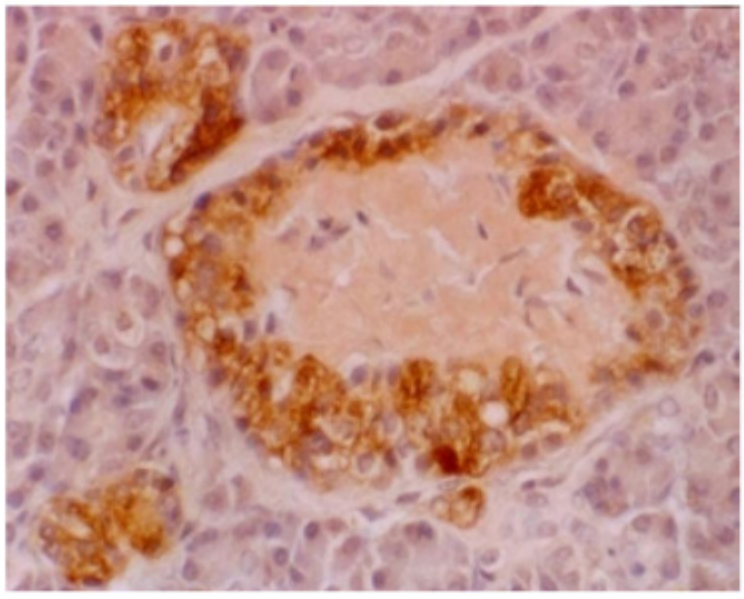

Anne Clark, University of Oxford/Wellcome Images

▲ **Figure 19–6.2A** Insulinoma Histology

Please visit us at www.Groupinsiders.com

© DeVry/Becker Educational Development Corp. All rights reserved.

Please visit us at www.Groupinsiders.com

6.2.2 Zollinger-Ellison Syndrome (Gastrinoma)

- **Characteristics**
  - Malignant (60% to 90%) tumor that secretes excess gastrin, producing hyperacidity.
  - Majority (60%) of the tumors are in the duodenum and smaller percentage (30%) are in the pancreatic islet cells.
- **Occurrence:** Sporadic in two thirds of cases and associated with MEN type I in one third of cases.
- **Clinical Features**
  - Peptic ulcer disease of solitary or multiple ulcers might be present.
  - Secretory type of diarrhea.
  - Increased acidity in various part of the intestine contributes to maldigestion.
  - Lab: Serum gastrin >1000 pg/mL
- **Treatment:** Proton pump inhibitors (-prazole), octreotide (somatostatin analogue), surgery.

6.2.3 Glucagonoma

Glucagonoma is a malignant tumor of α-islet cells with presenting symptoms of hyperglycemia due to glucagon's anti-insulin effects, weight loss, and a rash known as necrolytic migratory erythema. This rash presents as an annular pattern of erythema with central crusting and bullae.

Dr. P. Marazzi/Science Source

▲ **Figure 19–6.2B** Necrolytic Migratory Erythema

6.2.4 VIPoma

- Malignant tumor with excessive secretion of vasoactive intestinal peptide.
- Associated with *WDHA syndrome*:
  - *W*ater *D*iarrhea: Non-anion gap metabolic acidosis due to contraction alkalosis
  - *H*ypokalemia
  - *A*chlorhydia

© DeVry/Becker Educational Development Corp. All rights reserved.

6.3 Diabetes Mellitus

Diabetes mellitus is a chronic systemic disease of carbohydrate, fat, and protein metabolism that results from deficient secretion of insulin or peripheral tissue resistance to insulin. Types of diabetes and related conditions include:

- Diabetes mellitus type I
- Diabetes mellitus type II
- Secondary diabetes mellitus
- Prediabetic mellitus
- Gestational diabetes mellitus
- Maturity onset diabetes of the young
- Metabolic syndrome

6.3.1 Diagnosis

Clinical diagnosis is based on hyperglycemia, including any one of three of the following criteria:

1. Fasting glucose >126 mg/dL or random plasma glucose >200 mg/dL on two separate occasions.
2. Symptoms of diabetes (e.g., polyuria, polydipsia, ketoacidosis) plus a random plasma glucose >200 mg/dL.
3. Plasma glucose >200 mg/dL two hours after 75-gram oral glucose load on two occasions (see impaired glucose tolerance below for description).

Additional diagnostic considerations include:

- *%HbA_{1C}: Goal in therapy of DM is <7%* (mean glucose estimation of 8 to 12 weeks):
  - *Normal range from 4% to 5.6%*
  - *From 5.7% to 6.4% indicates increased risk for diabetes*
  - *HbA_{1c} ≥ 6.5% confirms diagnosis of diabetes*
- Prediabetic patients will show impaired glucose tolerance *(IGT)*:
  - Prediabetic condition with insulin resistance:
    - —30% develop diabetes in 10 years
    - —Patient may have developed macrovascular disease and neuropathy
  - Labs
    - —Fasting glucose: >110 mg/dL, but <126 mg/dL
    - —Oral glucose tolerance test (OGTT): Two-hour glucose is >140 mg/dL, but <200 mg/dL

The procedure for an oral glucose tolerance test (OGTT) is to administer a 75-g dose of oral glucose and then, two hours later, to measure blood glucose levels.

Please visit us at www.Groupinsiders.com

© DeVry/Becker Educational Development Corp. All rights reserved.

Clinical Application

Fed State vs. Fasting State

In the fed state, insulin is always present to conduct the following functions:

- Lipogenesis: Storage of triglycerides in adipocytes.
- Glycogenesis: Storage of glucose as glycogen.

In the fasting state, glucagon/epinephrine/cortisol are key hormones and conduct the following functions:

- Lipolysis: β-oxidation results in breakdown of fat and ketones for fuel.
- Glycogenolysis: Breaks down glycogen to glucose for fuel.

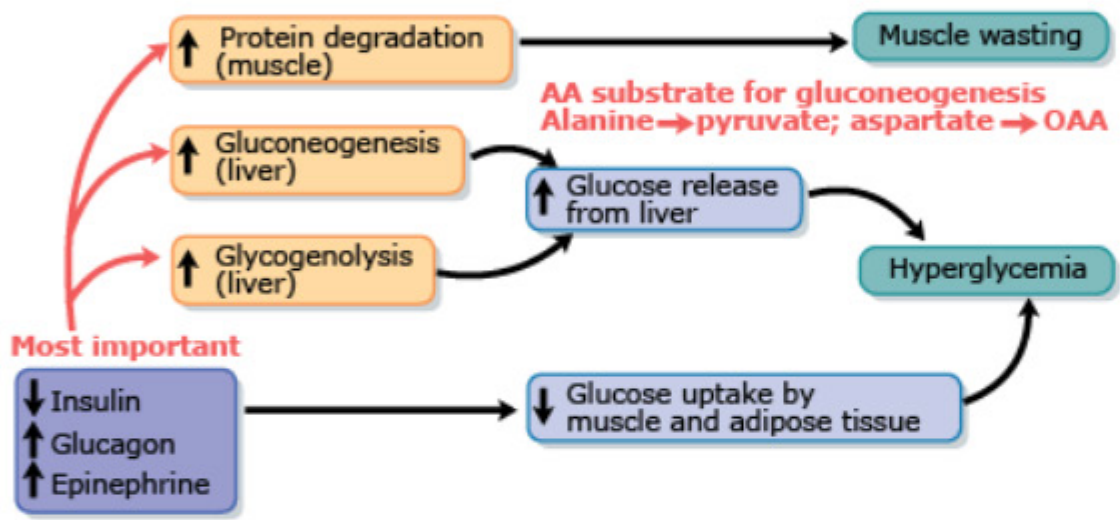

▲ **Figure 19–6.3A** Diabetes Mellitus: Muscle Wasting and Hyperglycemia

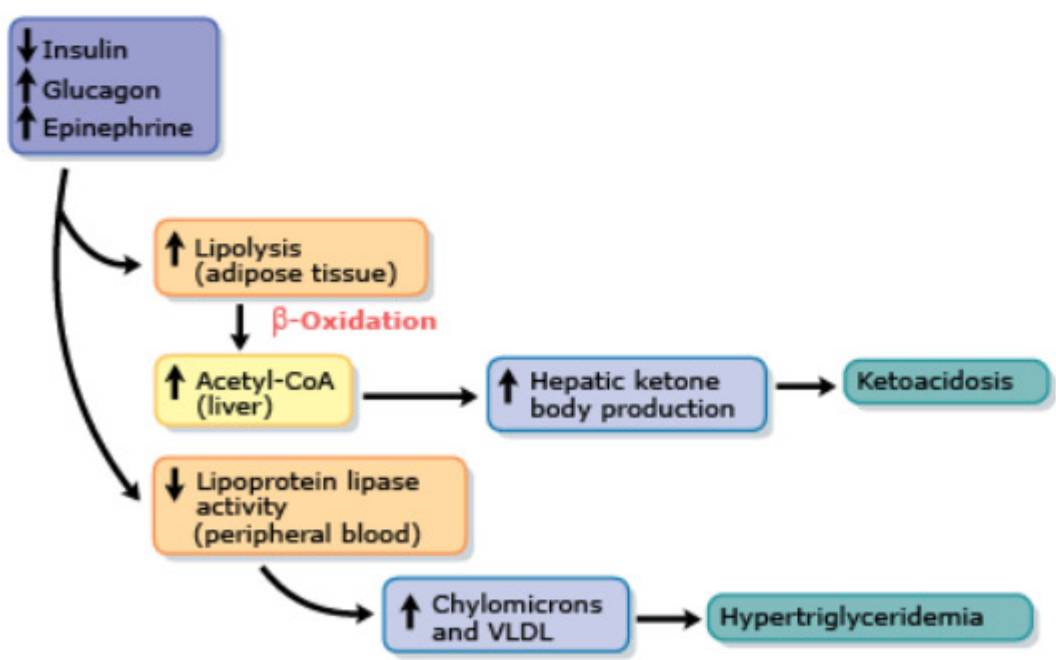

▲ **Figure 19–6.3B** Diabetes Mellitus: Ketoacidosis and Hypertriglyceridemia

Please visit us at www.Groupinsiders.com

© DeVry/Becker Educational Development Corp. All rights reserved.

6.3.2 Type I Diabetes Mellitus (DM)

Basic Characteristics

- **Epidemiology**
  - Early age: Usually under 30 years
  - Weight: Usually thin
  - Genetic predisposition
    - —Family history uncommon
    - —HLA-DQ, but also HLA-DR3 and 4
- **Pathology:** Pancreatic β-islet cell destruction resulting in complete lack of insulin. *Insulitis* can result from two types of autoimmune hypersensitivity reactions.
  - **Type II Hypersensitivity Reaction:** Anti-islet cell antibodies, insulin, *glutamic acid decarboxylase (GAD65)*, and the 40K fragment of tyrosine phosphatase (IA2).
  - **Type IV Hypersensitivity Reaction:** T cell cytokine destruction and autoantibodies.
- **Clinical Features:** Polyuria, polyphagia; acute complication characterized by ketoacidosis.

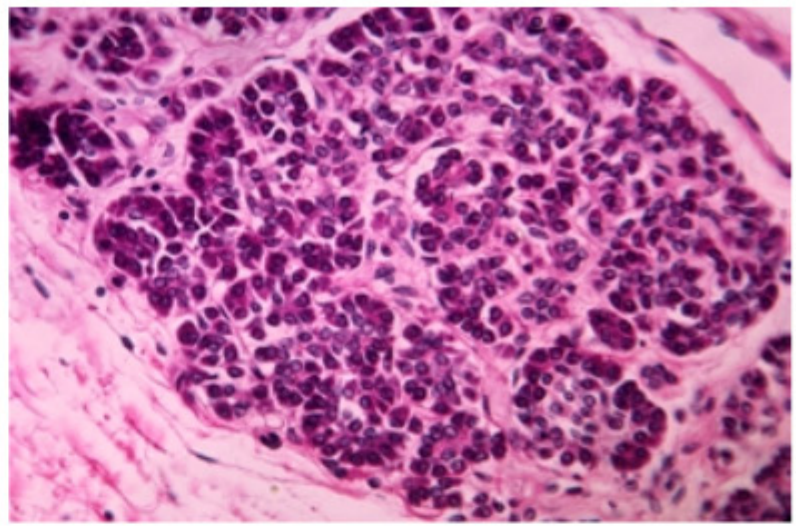

Dr. Arthur Siegelman/Visuals Unlimited, Inc.

▲ **Figure 19–6.3C** Insulitis in Type I Diabetes

Diabetic Ketoacidosis

- More common in type I DM.
- Characterized by hyperglycemia, anion gap acidosis, and ketonemia.
- Signs/symptoms
  - Fatigue, blurred vision, polydipsia, polyuria, weight loss
  - Nausea, vomiting, abdominal pain
  - Kussmaul respirations and fruity breath
- Common precipitants
  - New-onset diabetes
  - Inadequate insulin use
  - Infection
- Treatment
  - *IV fluid resuscitation*
    - —Often 3L to 6L required.
    - —Add dextrose to IVF when glucose <200 mg/dL.
  - Insulin infusion until anion gap acidosis resolves.
  - Close monitoring and repletion as needed of potassium, magnesium, phosphate.

Please visit us at www.Groupinsiders.com

© DeVry/Becker Educational Development Corp. All rights reserved.

Please visit us at www.Groupinsiders.com

6.3.3 Type II Diabetes Mellitus

Basic Characteristics

- **Epidemiology**
  - Later age: Usually older than 40 years.
  - Weight: Usually obese.
  - Genetic predisposition:
    - —Family history common.
    - —No HLA association or autoimmune associations.
    - —Increased in Native Americans and African-Americans.
- **Pathophysiology**
  - Most important, post-receptor defects are associated with tyrosine kinase and GLUT-4 abnormalities.
  - Decreased insulin receptors due to down-regulation as a result of increased adipose tissue.
  - Insulin resistance leads to diminished peripheral glucose uptake and increased hepatic glucose production.
  - Fibrotic β-islet cells contain amyloid and hyalinization.
- Early findings include hyperinsulinemia resulting in reactive hypoglycemia.
- **Complications:** *Ketoacidosis is rare*; *hyperosmolar nonketotic coma (HNKC)* mainly occurs with type II DM, especially when subjected to extreme stress.

▼ **Table 19–6.3A** Osmolarity Changes Found in Diabetes Mellitus

Compartment Alteration	POsm/Na+	ECF Volume	ICF Volume	Conditions
Hyperglycemia	Increased: ↑ glucose ↓ Na^+ (dilutional effect)	Contracted	Contracted	• Diabetic ketoacidosis • Hyperosmolar nonketotic coma (type II diabetes)
Hypotonic loss of Na^+	Increased: ↓ $TBNa^+$/↓↓ TBW	Contracted	Contracted	Osmotic diuresis: • Glucose • Sweating

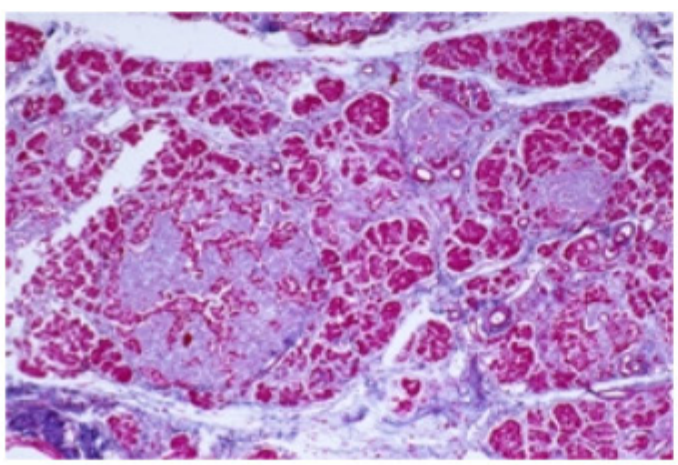

Michael Abbey/Science Source

▲ **Figure 19–6.3D** Hyalinization of Pancreatic β Cells in Type II Diabetes

© DeVry/Becker Educational Development Corp. All rights reserved.

▼ **Table 19–6.3B** Summary of Type I and Type II Diabetes

	Type I	Type II
Weight	Normal or thin. Often lose weight prior to diagnosis.	Overweight or obese.
Age	Typically first to second decade of life but may present at any age (latent autoimmune diabetes of adulthood, LADA).	Typically over age 40 but can present much earlier.
Glycemic patterns	Highly variable	Less variable
Insulin sensitivity	Normal	Reduced
Response to oral agents	Not responsive	Responsive
Antibody status	Usually positive	Negative
C-peptide level	Low or undetectable	Detectable or high
Family history	First-degree relatives uncommonly affected.	Strong family history of first-degree relatives.
Other autoimmune disorders	May have autoimmune thyroid disease, adrenal insufficiency, vitiligo, pernicious anemia.	Absent
Prevalence	5%–10%	90%–95%
Genetics	HLA-DR3, HLA-DR4	Family history common
Pathogenesis	• Lack insulin • Absent β-islet cells • Insulitis (CMI); antibodies against islets and insulin (type II HSR)	• Decreased insulin receptors (↑adipose down-regulates receptor synthesis) • Postreceptor defects: e.g., ↓ tyrosine kinase in receptor, ↓ GLUT-4 transport units • Fibrotic β-islet cells with amyloid
Clinical	DKA + lactic acidosis (hypovolemic shock from osmotic diuresis)	Hyperosmolar nonketotic coma + lactic acidosis (hypovolemic shock from osmotic diuresis)
Treatment	Insulin	Weight loss, oral drugs, insulin

6.3.4 Secondary Diabetes Mellitus

Causes

- Endocrinopathies
  - Cushing syndrome
    - —Increased gluconeogenesis
    - —Impaired peripheral utilization
  - Acromegaly: Anti-insulin-like effect of growth hormone
  - Glucagon hypersecretion: Islet alpha cell tumor
- Hemochromatosis: Reactive fibrosis of heart, liver, and pancreas to iron
- Chronic pancreatitis
- Pancreatic carcinoma: DM can be presenting sign
- Maturity onset of diabetes of the young
- Metabolic syndrome
- Gestational diabetes

Please visit us at www.Groupinsiders.com

© DeVry/Becker Educational Development Corp. All rights reserved.

6.3.5 Maturity Onset Diabetes of the Young (MODY)

- Autosomal dominant inheritance: Mutations of transcription factors genes, such as the glucokinase gene
- Patients<25 years of age are not obese
- Mild to severe hyperglycemia: Impaired glucose-induced secretion of insulin release
- Resistance to ketosis
- May progress to type II DM

6.3.6 Gestational Diabetes Mellitus (GDM)

- Diabetes usually develops after five months of pregnancy:
  - After initial development of GDM in the mother, there is an increased risk of developing GDM in future pregnancies.
  - Mother has >50% chance of developing diabetes at a later date.
- Pathogenesis
  - ↑ glucose in mother due to anti-insulin effects of HPL, progesterone, and cortisol.
  - ↑ maternal glucose causes ↑ in fetal glucose.
  - Fetus responds by ↑ its own production of insulin.
  - Postpartum, the maternal supply of glucose is cut off; however, the newborn has ↑ insulin, resulting in hypoglycemia.
  - Must give newborn glucose to prevent loss of neurons.
  - Produces macrosomia (insulin ↑ AA uptake in muscle [GH effect] and fat in adipose).
  - Also, increased risk for respiratory distress syndrome.
  - Insulin ↓ surfactant synthesis.

6.3.7 Metabolic Syndrome

- Genetic insulin resistance resulting in hyperinsulinemia and hyperglycemia.
- Elevated fasting glucose: ≥100 mg/dL.
- Elevated waist circumference equates to obesity, and thus exacerbates hyperinsulinemia due to down-regulation of peripheral insulin receptor synthesis:
  - Men ≥40 inches (102 cm)
  - Women ≥35 inches (88 cm)
- Insulin ↑ VLDL synthesis (↓ HDL):
  - Elevated triglycerides: ≥150 mg/dL
  - Reduced HDL ("good") cholesterol:
    - Men <40 mg/dL
    - Women <50 mg/dL
- Insulin possesses mineralocorticoid activity causing elevated blood pressure: ≥130/85 mmHg.
- Insulin causes damage to endothelial cells, leading to coronary artery disease.
- Associations: Polycystic ovarian syndrome, acanthosis nigricans, increased risk of Alzheimer disease.

Please visit us at www.Groupinsiders.com

© DeVry/Becker Educational Development Corp. All rights reserved.

6.3.8 Diabetes Mellitus Pathogenesis

- Non-enzymatic glycosylation of proteins (NEG):
  - Glucose combines with amino groups in proteins.
  - Produces advanced glycosylated end products (AGE).
  - Increases vessel permeability to protein.
  - Increases atherogenesis.
- Diabetes mellitus manifestations as a result of NEG:
  - Production of HB_{A1c}
  - Hyaline arteriosclerosis
  - Diabetic glomerunephropathy
  - Vascular disease
- Osmotic damage:
  - Altered carbohydrate metabolism: Aldose reductase converts glucose into *sorbitol*.
  - Sorbitol provides an osmotic gradient to draw water into tissue.
- Diabetes mellitus manifestations as a result of osmotic damage:
  - Nerves, lenses, kidney, and blood vessels do not require insulin for glucose transport and so there is unregulated glucose intake by these tissues.
  - Cataract formation.
  - Peripheral neuropathy:
    - —Osmotic damage of Schwann cell produces demyelination and sensorimotor peripheral neuropathy.
    - —Peripheral neuropathy leads to neuropathic ulcers for which patient cannot feel pain.

6.3.9 Complications of Diabetes

- Acute complications
  - Diabetic ketoacidosis (type I)
  - Hyperosmolar hyperglycemic state (type II)
- Chronic complications
  - Microvascular
    - —Retinopathy
    - —Nephropathy
    - —Neuropathy (stocking-glove)
  - Macrovascular
    - —Coronary artery
    - —Peripheral vascular
    - —Cerebrovascular disease

Please visit us at www.Groupinsiders.com

© DeVry/Becker Educational Development Corp. All rights reserved.

Diabetic Retinopathy

▼ **Table 19–6.3C** Classification of Diabetic Retinopathy

Type	Clinical Features
Nonproliferative	• Microaneurysms • Soft exudates (cotton wool spots/infarcts) • Intraretinal hemorrhage • Occluded, dilated, tortuous vessels
Proliferative	• Neovascularization from the disc and/or retinal vessles • Preretinal and vitreous hemorrhage • Subsequent fibrosis and tractional retinal detachment
Macular edema	• Retinal thickening and edema involving macula • Can occur during nonproliferative or proliferative retinopathy

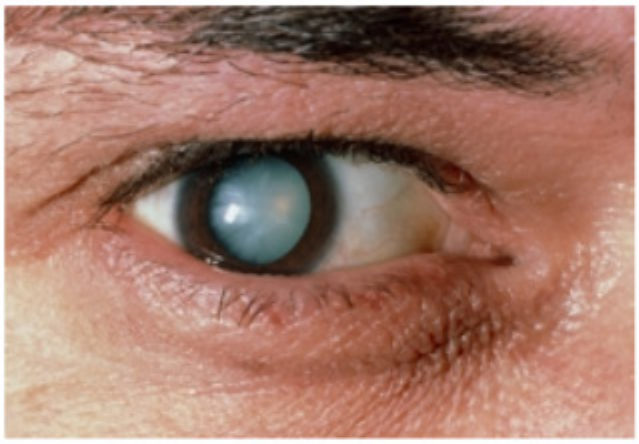

Sue Ford/Science Source

▲ **Figure 19–6.3E** Diabetic Ocular Complication: Cataracts

Sue Ford/Science Source

▲ **Figure 19–6.3F** Diabetic Ocular Complication: Retinal Detachment

Diabetic Nephropathy

- Glomerular lesions
  - Capillary basement membrane thickening *(earliest and most common change).*
  - Glomerulosclerosis *(Kimmelstiel-Wilson nodules).*
- Tubular lesions: *Armanni-Ebstein lesion* result from tubular deposition of glycogen due to hyperglycemia (>500 mg/dL).

Diagnosis

- 20% to 30% of all patients with diabetes develop nephropathy.
- Usually asymptomatic until advanced.
- Screen for microalbuminuria.
- Microalbuminuria may be secondary to fever exercise, infection, CHF, marked hyperglycemia, and marked hypertension.

Treatment

- ACE inhibitor or angiotensin II receptor blocker (ARB) for hypertensive patients and those with microalbuminuria.
- BP goal <130/80 for all patients with DM.

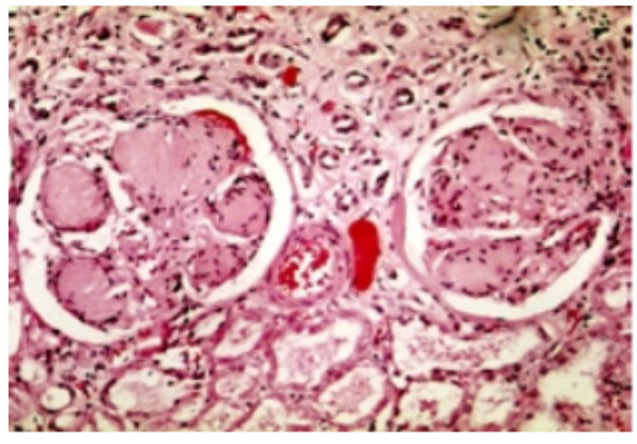

Courtesy of Dr. Edwin P. Ewing, Jr./ CDC Image Library

▲ **Figure 19–6.3G** Kimmelstiel-Wilson Nodule

Please visit us at www.Groupinsiders.com

© DeVry/Becker Educational Development Corp. All rights reserved.

Diabetic Neuropathy

- Can be generalized, focal/multifocal, or autonomic.
- Chronic sensorimotor distal symmetric polyneuropathy
  - Most common
  - Often asymptomatic
  - Increased risk of foot injury/ulcer
- Autonomic neuropathy (AN)
  - *Cardiovascular*
    - —Silent myocardial infarction
    - —Orthostatic hypotension
  - *Gastrointestinal*
    - —Variety of GI symptoms
    - —Gastroparesis treated with small, frequent meals and prokinetic agents (e.g., metoclopramide)
  - *Genitourinary*
    - —Erectile dysfunction
    - —Retrograde ejaculation
    - —Bladder dysfunction

SIU/Visuals Unlimited, Inc.

▲ **Figure 19–6.3H** Neuropathic Pressure Ulcers

Diabetic Skin Manifestations

- Acanthosis nigricans: Dark, velvety plaques in axilla, neck, inguinal crease; associated with insulin resistance; sometimes seen with underlying malignancy.
- Necrobiosis lipoidica: Oval or irregular, indurated with central atrophy and yellow pigmentation and red-brown margins. Mostly seen in patients on the shins with diabetes or prediabetes.

ISM/Phototake, Inc.

▲ **Figure 19–6.3I** Acanthosis Nigricans

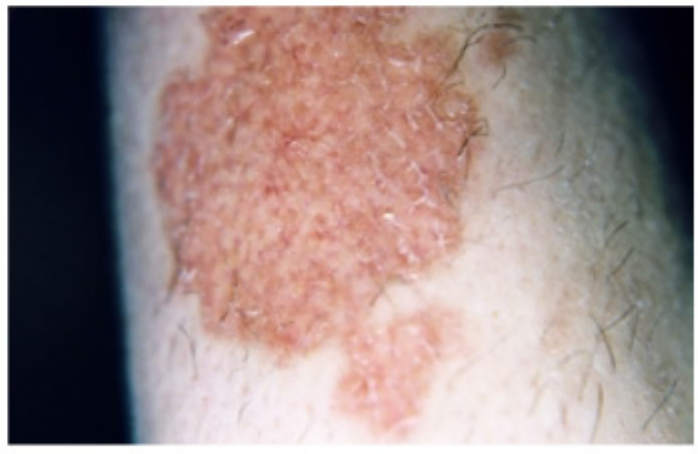
Custom Medical Stock Photo

▲ **Figure 19–6.3J** Necrobiosis Lipoidica

Please visit us at www.Groupinsiders.com

© DeVry/Becker Educational Development Corp. All rights reserved.

7 Calcium Metabolism and Bone

7.1 Hormonal Control of Ca^{++} and PO_4^-

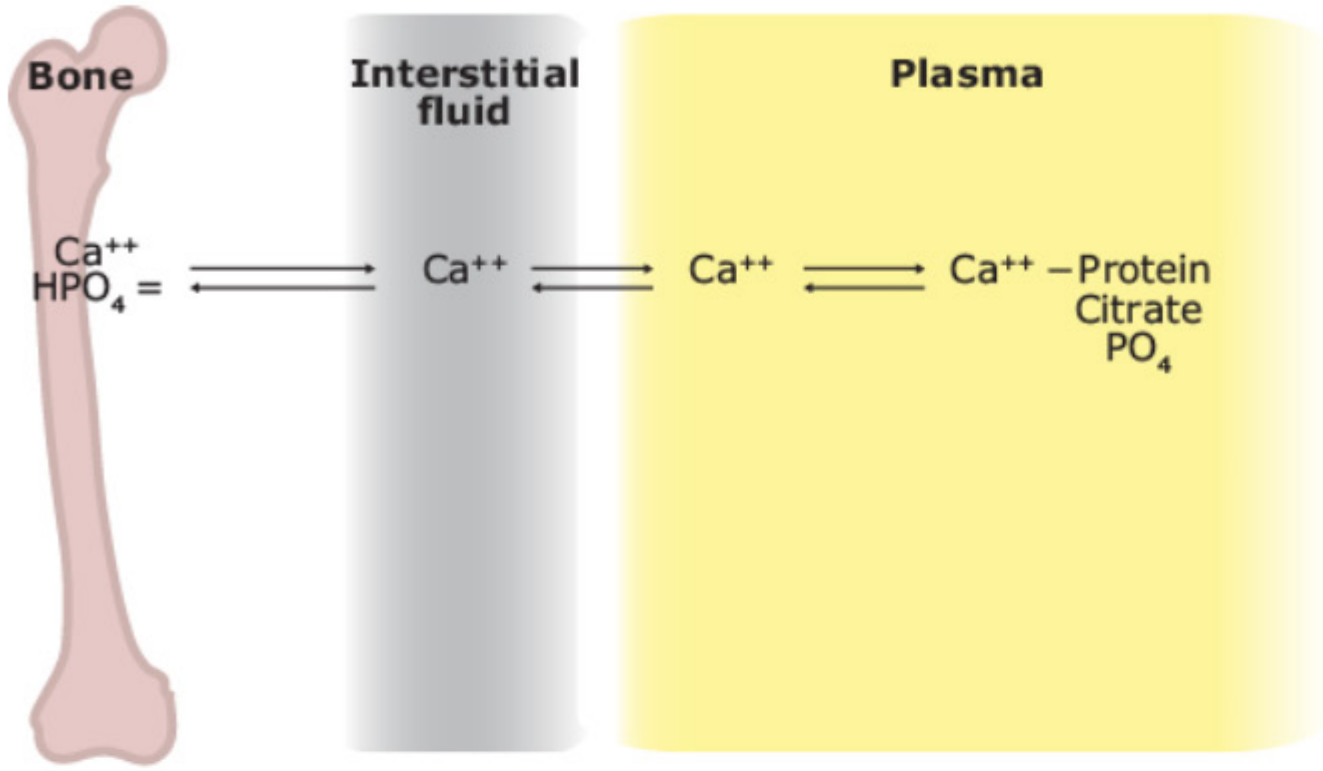

▲ **Figure 19–7.1A** Compartmentalization of Ca^{++} and Free PO_4^-

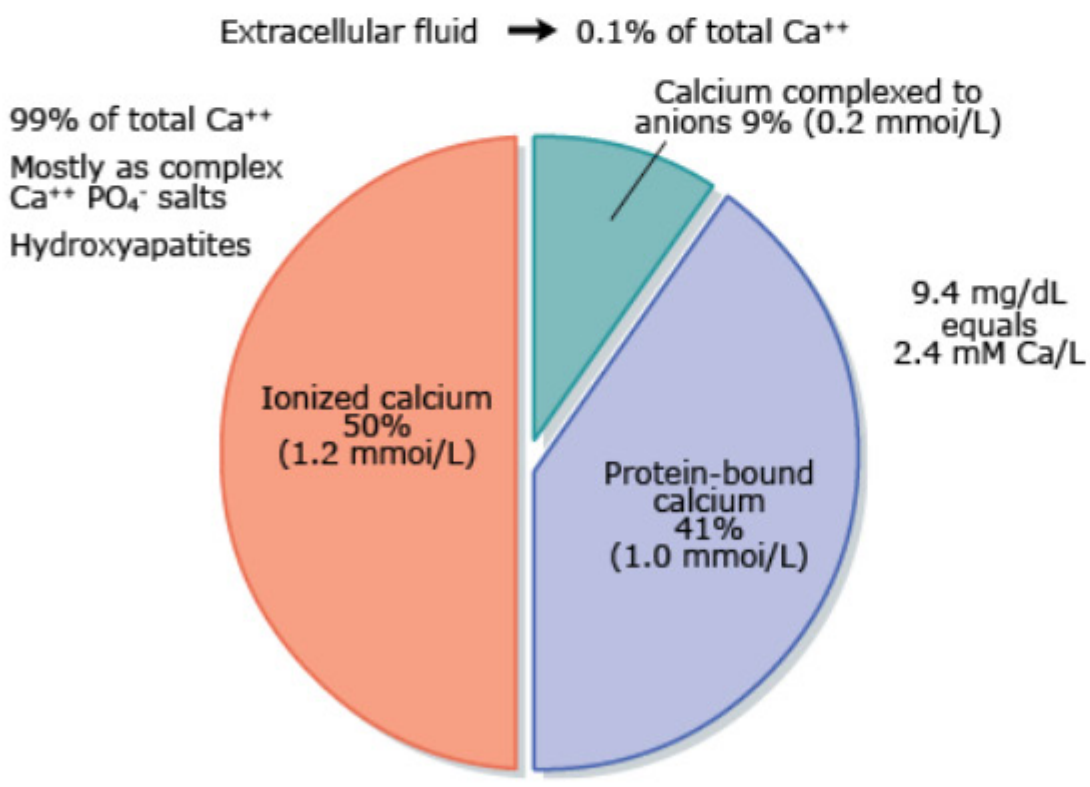

▲ **Figure 19–7.1B** Compartmentalization of Ca++ in the Body

Connection to Physiology

See *Physiology*, chapter 35, topic 7 to review bone physiology.

Connection to Physiology

To review parathyroid hormone (PTH) regulation of calcium and phosphate, see *Physiology*, chapter 35, topic 8.

Please visit us at www.Groupinsiders.com

© DeVry/Becker Educational Development Corp. All rights reserved.

7.2 Primary Pathophysiologic Changes in PTH Secretion

7.2.1 Primary Hyperparathyroidism

Etiology

- Hypersecretion of PTH by parathyroid tumor or an ectopic tumor. Increased plasma Ca^{++} and decreased plasma PO_4^-.
- Even though PO_4^- is mobilized from bone, it decreases due to PTH inhibiting PO_4^- reabsorption in the proximal tubule and producing phosphaturia.

Clinical Features

- Polyuria and calciuria.
- Even though PTH increases Ca^{++} reabsorption by the kidney, the filtered load of Ca^{++} can greatly exceed Tm and Ca^{++} excretion increases.
- *Increased serum alkaline phosphatase and increased excretion of cAMP and hydroxyproline.*

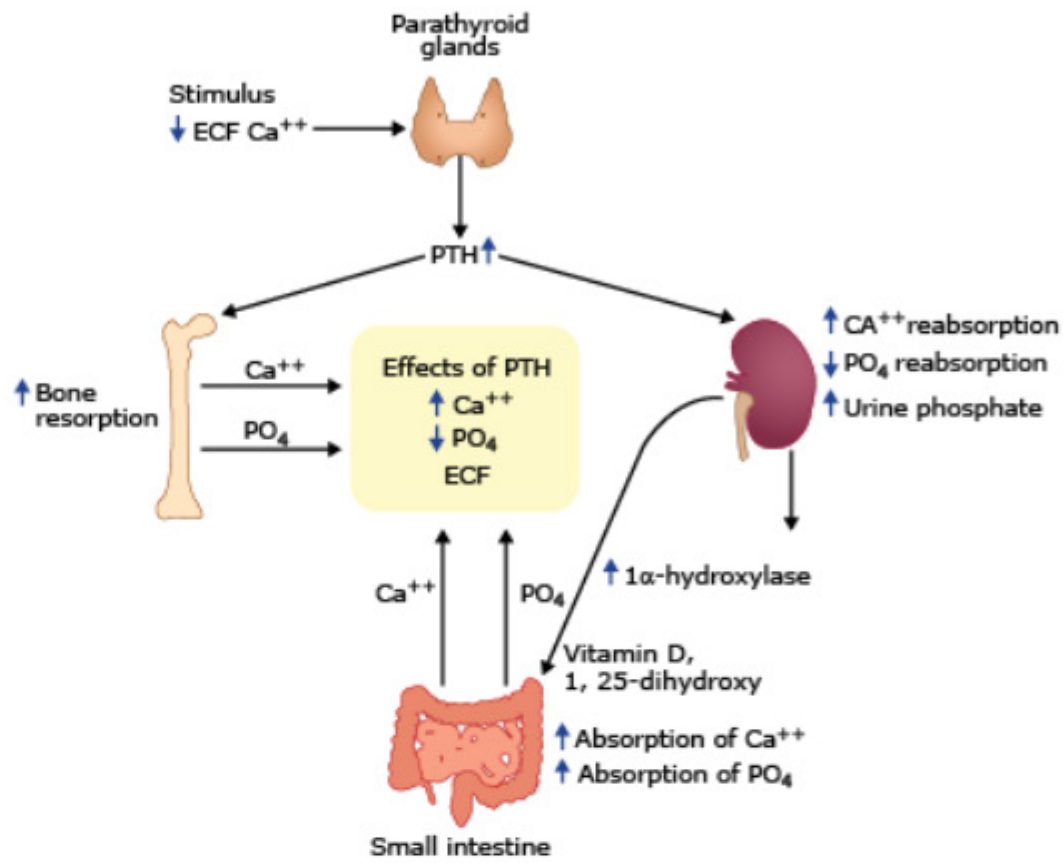

▲ **Figure 19–7.2** Regulation of ECF Calcium and Phosphate

7.2.2 Primary Hypoparathyroidism

Etiology The initiating factor is inadequate secretion of PTH by parathyroids as may be seen with inadvertently resecting the parathyroids during thyroid surgery or congenital deficiencies that are manifested with *DiGeorge syndrome*.

Clinical Features

- Decreased plasma Ca^{++} and increased plasma PO_4^-:
  - Even though less PO_4^- is reabsorbed from bone, plasma PO_4^- increases because the normal action of PTH is to inhibit PO_4^- reabsorption and increase excretion by the kidney.
  - Without PTH, more of the filtered load of PO_4^- is reabsorbed.
- Positive Trousseau and Chvostek signs.
- Occluding the blood flow (BP cuff) to the forearm, resulting in tetany.

Please visit us at www.Groupinsiders.com

© DeVry/Becker Educational Development Corp. All rights reserved.

7.3 Secondary Physiologic and Pathologic Changes in PTH Secretion

The only physiologically significant signal affecting PTH secretions is free Ca^{++}. Changes in PTH can be predicated from expected changes in circulating Ca^{++}.

7.3.1 Secondary Hyperparathyrodism

In all of the following situations, there is a decrease in plasma Ca^{++} and an increase in PTH secretion:

- Vitamin D deficiencies of various causes, including inadequate exposure to sunlight and insufficient quantities in diet.
- Malabsorption syndromes.
- Inability to synthesize 1.25 di-OH D_3 (calcitriol): Renals versus liver.
- Increased demand for Ca^{++}, as in pregnancy or lactation.

All of the above result in 2° hyperparathyroidism characterized by increased plasma PTH.

7.3.2 Pseudohypoparathyroidism

- **Autosomal Recessive:** Result of a defective G protein (GNAS mutation) in kidney and bone causing insensitivity to PTH (i.e., PTH resistance) → hypocalcemia (with serum PTH elevated).
- **Skeletal Abnormalities**
  - Shortened fourth and fifth metacarpals and metatarsals, which produce the classic "knuckle-knuckle-dimple-dimple" sign.
  - Shortened stature.
- Symptoms are *not* improved by the administration of PTH.

7.4 Vitamin D Deficiency: Rickets

- Excess of unmineralized matrix.
- Inadequate provisional calcification (mineralization) of epiphyseal cartilage leading to impaired endochondral ossification. Calcification of the matrix is required for subsequent steps:
  - Invasion of cartilage cells by blood vessels from metaphysis.
  - Destruction of cartilage cells.
    - —This provides space for the ingress of vascular channels and bone-marrow stromal cells.
    - —Formation of bone along remaining walls of calcified cartilage matrix.
- Overgrowth of epiphyseal cartilage. Failure of cartilagenous cells to mature and be resorbed.

Connection to Physiology

For more information about secondary hyperparathyroidism of chronic renal failure, see *Physiology*, chapter 35, topic 9.4.

Looking Ahead

For more about bone pathology, see chapter 25, Table 3–3.1.

Looking Ahead

For more about bone pathology, see chapter 25, topic 3.4.

Please visit us at www.Groupinsiders.com

© DeVry/Becker Educational Development Corp. All rights reserved.

Please visit us at www.Groupinsiders.com

Unit 10

Nervous Pathology

Please visit us at www.Groupinsiders.com

Please visit us at www.Groupinsiders.com

1 Basic Neuroanatomy

1.1 Layers of the Skull

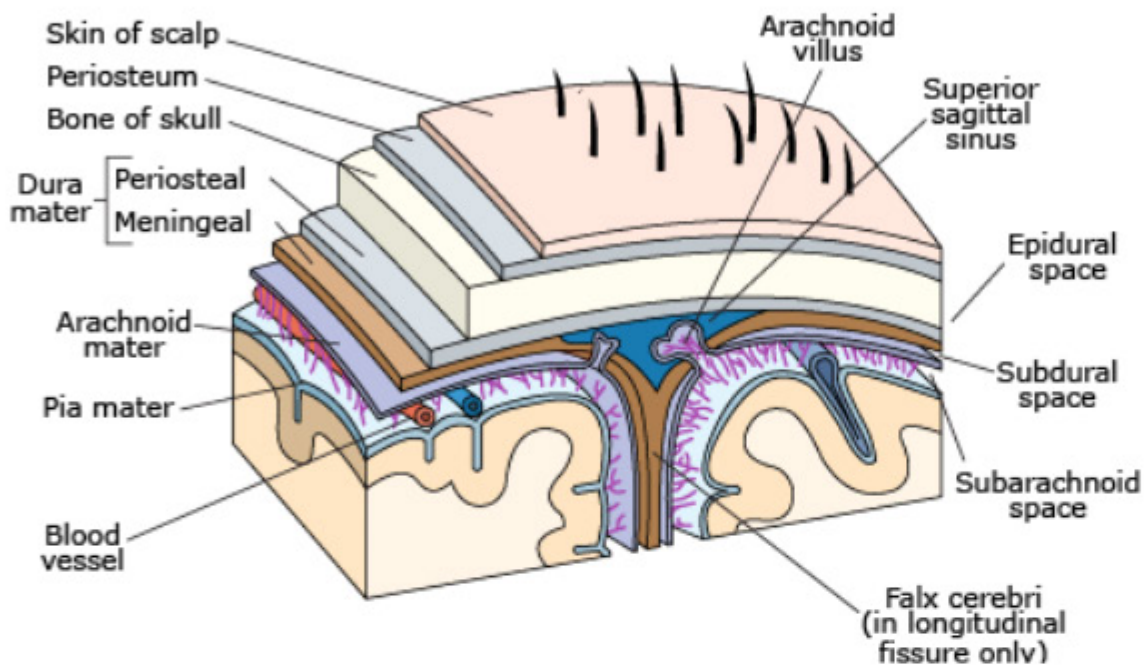

▲ **Figure 20–1.1A** Layers of the Skull

USMLE® Key Concepts

For Step 1, you must be able to:

- Identify central nervous system developmental diseases.
- Describe various types of herniations, traumas, and lesions of the cerebrum and spinal cord.
- Differentiate between various causes of hypoxic ischemic encephalopathy.
- Describe infectious diseases of the central nervous system.
- Identify degenerative diseases of the central nervous system.
- Differentiate between various central nervous system tumors.

Please visit us at www.Groupinsiders.com

© DeVry/Becker Educational Development Corp. All rights reserved.

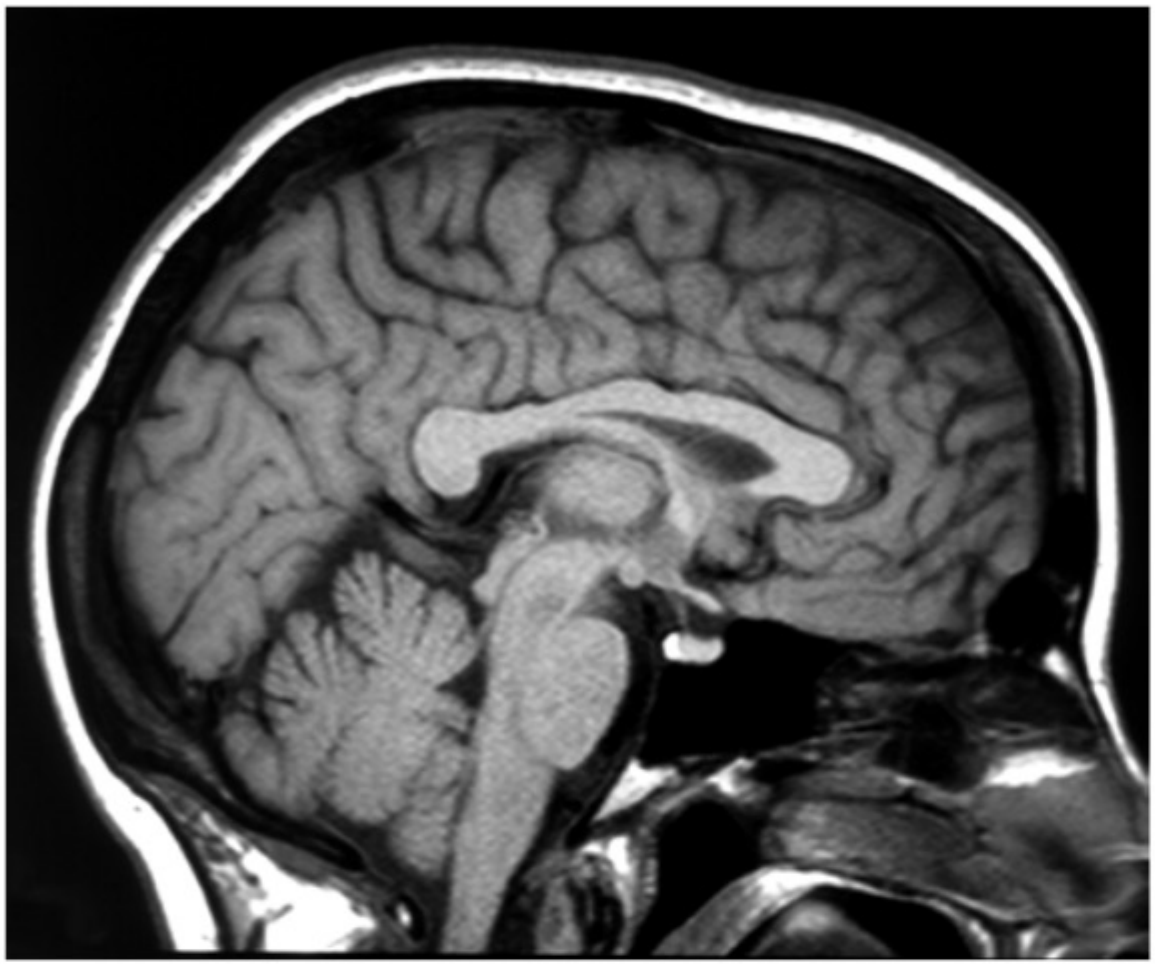

Ted Kinsman/Science Source

▲ **Figure 20–1.1B** MRI Sagittal Section of the Brain

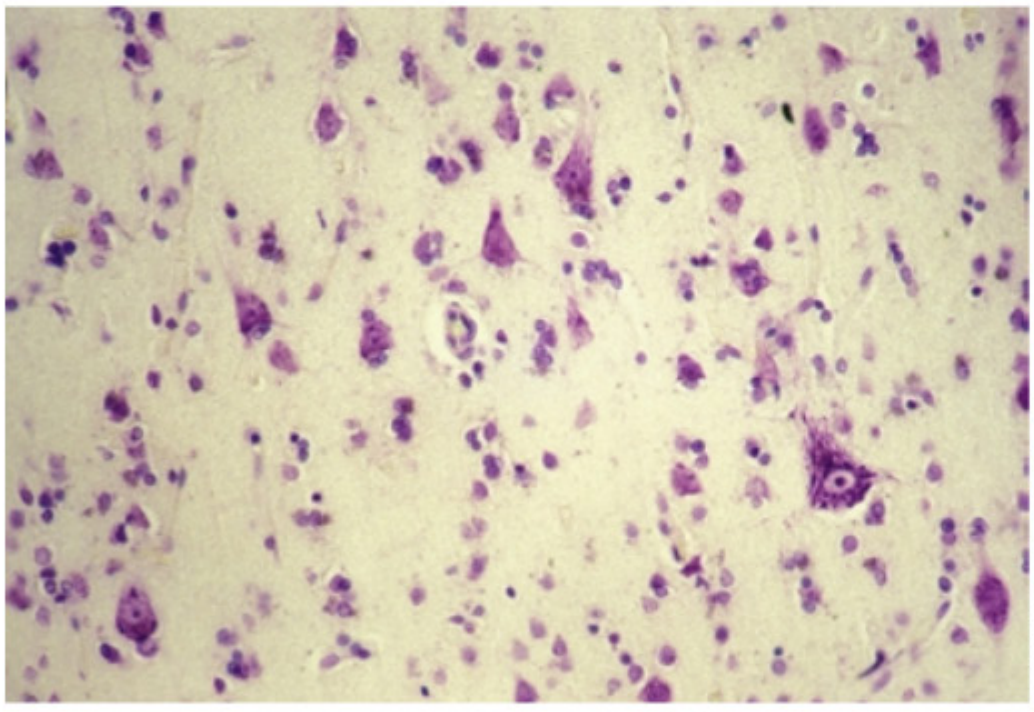

Dr. Fred Hossler/Visuals Unlimited, Inc.

▲ **Figure 20–1.1C** Pyramidal Neurons

Connection to Anatomy

Review the following topics from *Anatomy*, Unit 3, "Neuroscience."

- Parts of the Brain
- Magnetic Reasonance Imaging (MRI)
- Lobes of the Brain
- Homunculus

Please visit us at www.Groupinsiders.com

© DeVry/Becker Educational Development Corp. All rights reserved.

2 Central Nervous System Developmental Diseases

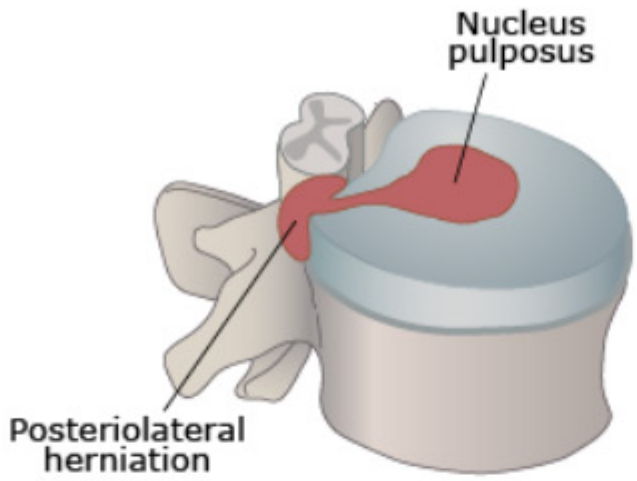

▲ **Figure 20–2.0A** "Bleeding" of the Nucleus Pulposus

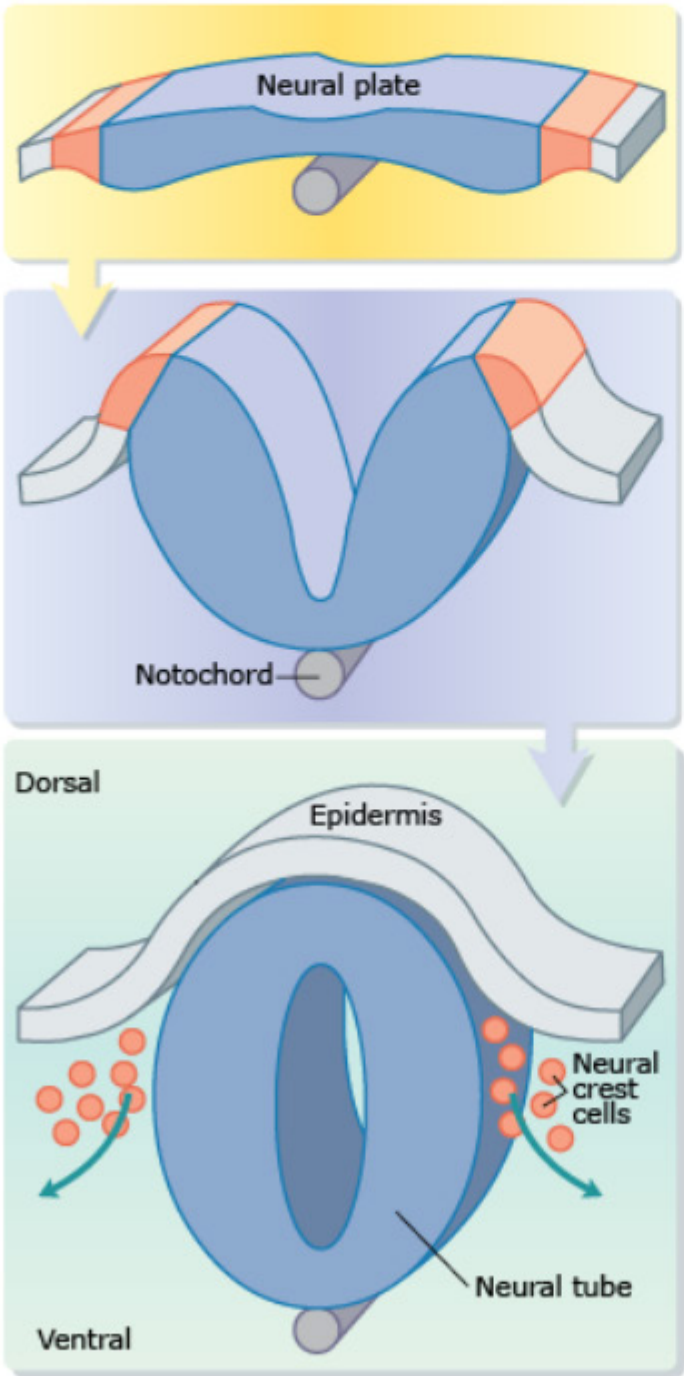

▲ **Figure 20–2.0B** Developmental Diseases

Important Concept

Central Nervous System

- Notochord induces overlying ectoderm to differentiate into neuroectoderm and form the *neural plate*.
- Neural plate gives rise to neural tube and *neural crest cells*.
- Notochord becomes *nucleus pulposus* of the intervertebral disk in adults.

Please visit us at www.Groupinsiders.com

© DeVry/Becker Educational Development Corp. All rights reserved.

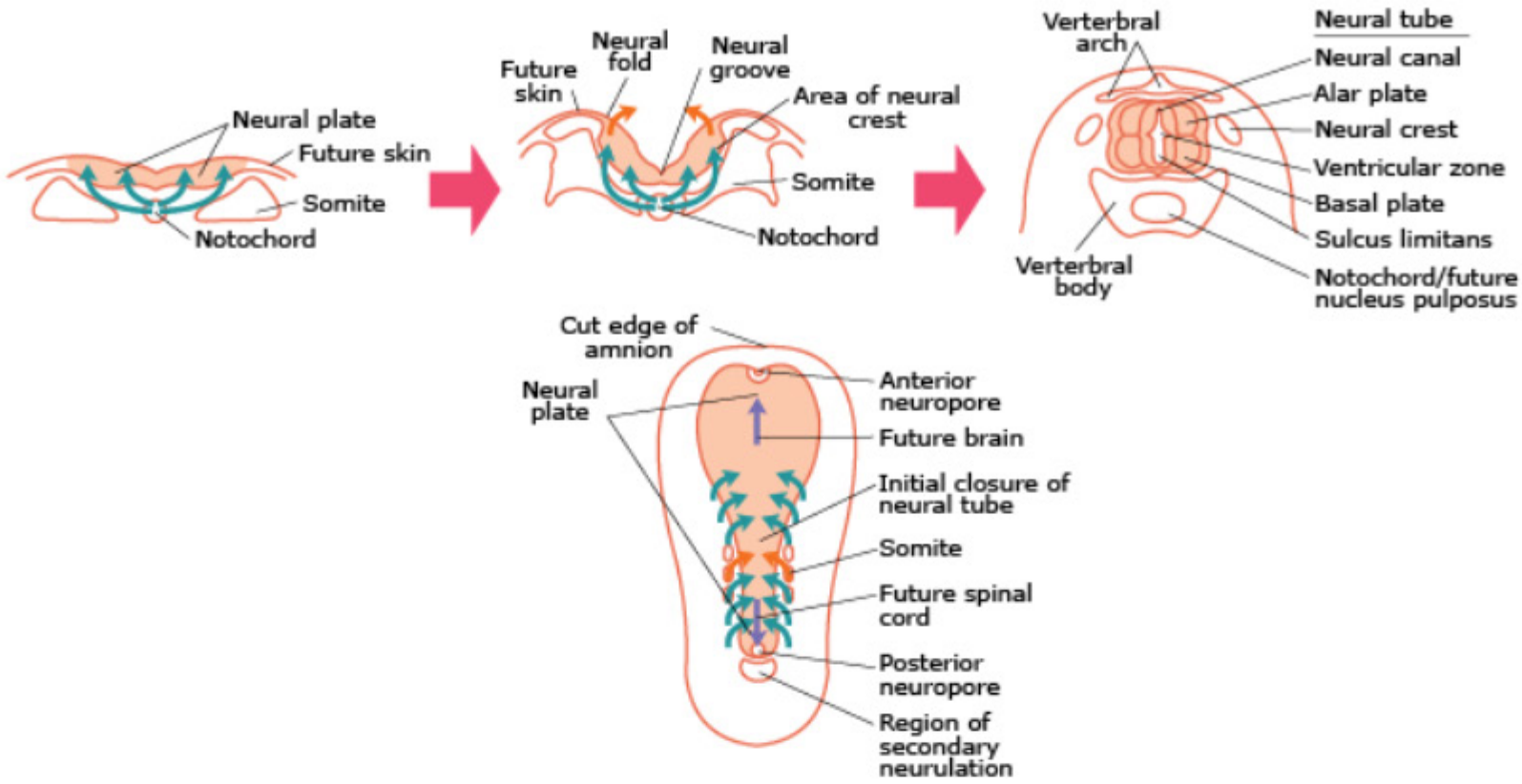

▲ **Figure 20–2.0C** Developmental Diseases of the Central Nervous System

2.1 Neural Tube Defects

2.1.1 Anencephaly

- Malformation of anterior end of neural tube resulting in absence of the brain and calvarium.
- Loss of swallowing center resulting in *polyhydramnios*.
- Incompatible with life.
- One to five occurrences in 1,000 live births.

2.1.2 Encephalocele

- Diverticulum of malformed neural tissue extending through a defect in the cranium.
- Most often occurs in occipital region or in posterior fossa.

Jan Leestma MD/Custom Medical Stock Photo

▲ **Figure 20–2.1A** Anencephaly

Medicimage/Phototake, Inc.

▲ **Figure 20–2.1B** Encephalocele

Please visit us at www.Groupinsiders.com

© DeVry/Becker Educational Development Corp. All rights reserved.

2.1.3 Spina Bifida

- **Occulta:** Asymptomatic failure of bony spinal canal to close with dura intact, but no structural herniation. It is usually seen at lower vertebral levels.
- **Meningocele:** Meningeal extrusion only.
- **Myelocele:** Defective bony arch with complete exposure of spinal cord.
- **Myelomeningocele:** Extension of neural tissue through a defect in the vertebral column causing cystic outpouching of meninges, spinal cord, and spinal roots. *Can cause paraplegia and urinary incontinence.*

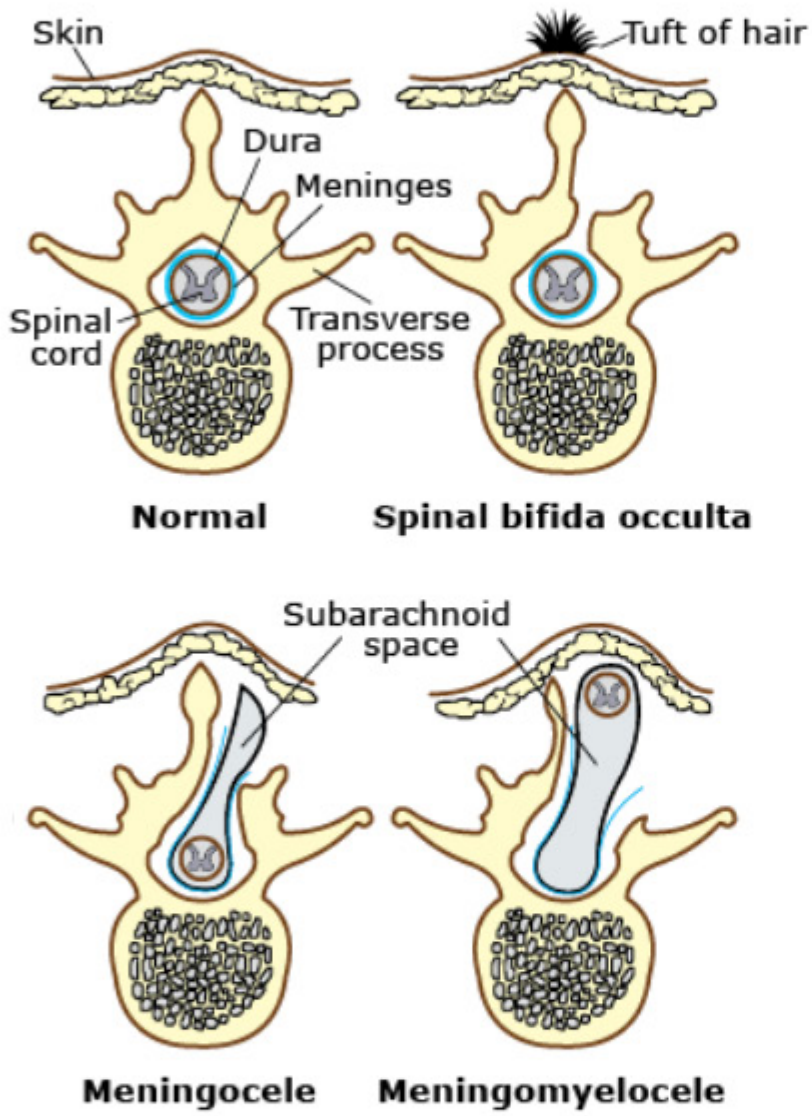

▲ **Figure 20–2.1C** Spina Bifida

Please visit us at www.Groupinsiders.com

© DeVry/Becker Educational Development Corp. All rights reserved.

2.2 Posterior Fossa Abnormalities

2.2.1 Arnold-Chiari Malformations

- **Arnold-Chiari Type I**
  - **Posterior fossa cavity too small** → herniation of *tonsils* into foramen magnum
  - Most are asymptomatic but can lead to obstruction of CSF flow and compression of the medulla, resulting in symptoms of severe headache or cranial nerve deficits
  - Easily decompressed surgically
- **Arnold-Chiari Type II**
  - Small posterior fossa → cerebellum *and* brainstem herniation through foramen magnum
  - *Aqueductal stenosis and hydrocephalus*
  - *Thoracolumbar meningomyelocele*
  - *Syringomyelia*

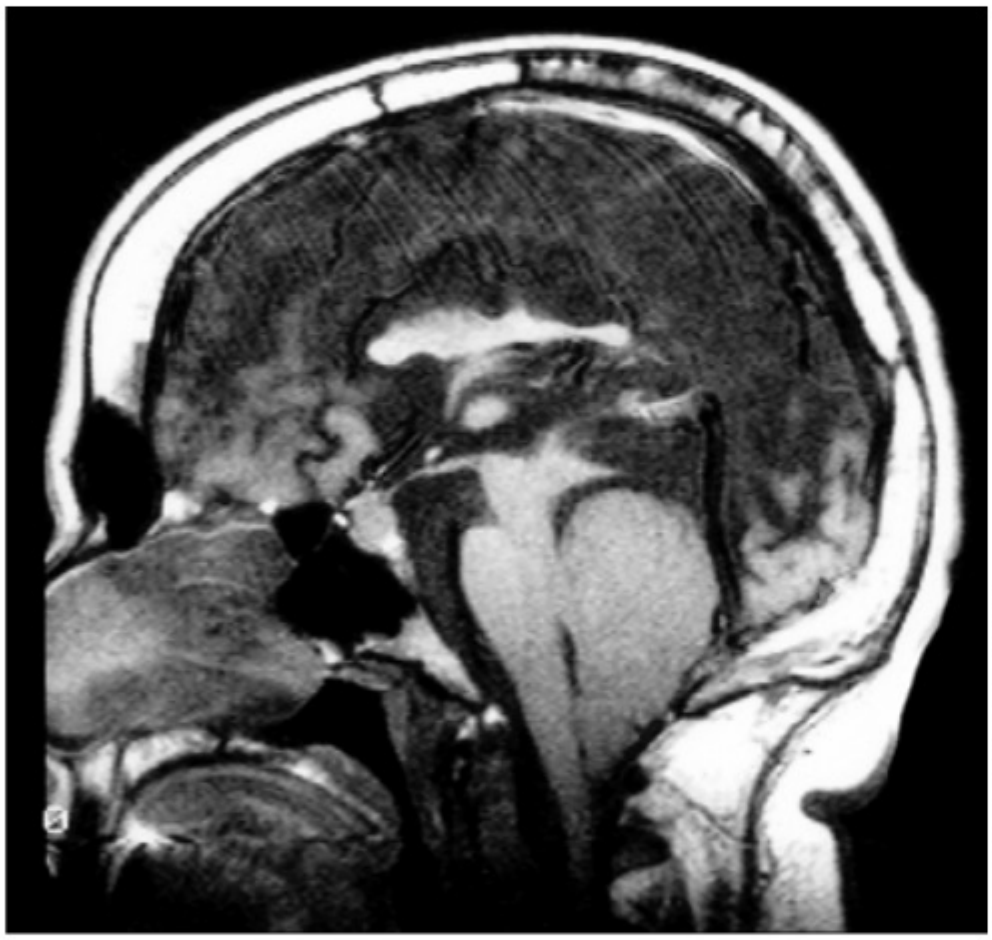

Living Art Enterprises, LLC/Science Source

▲ **Figure 20–2.2A** Arnold-Chiari Type I

Please visit us at www.Groupinsiders.com

© DeVry/Becker Educational Development Corp. All rights reserved.

2.2.2 Dandy-Walker Malformation

- Enlarged posterior fossa
- Partial or complete absence of cerebellar vermis
- Cystic dilation of fourth ventricle with noncommunicating hydrocephalus

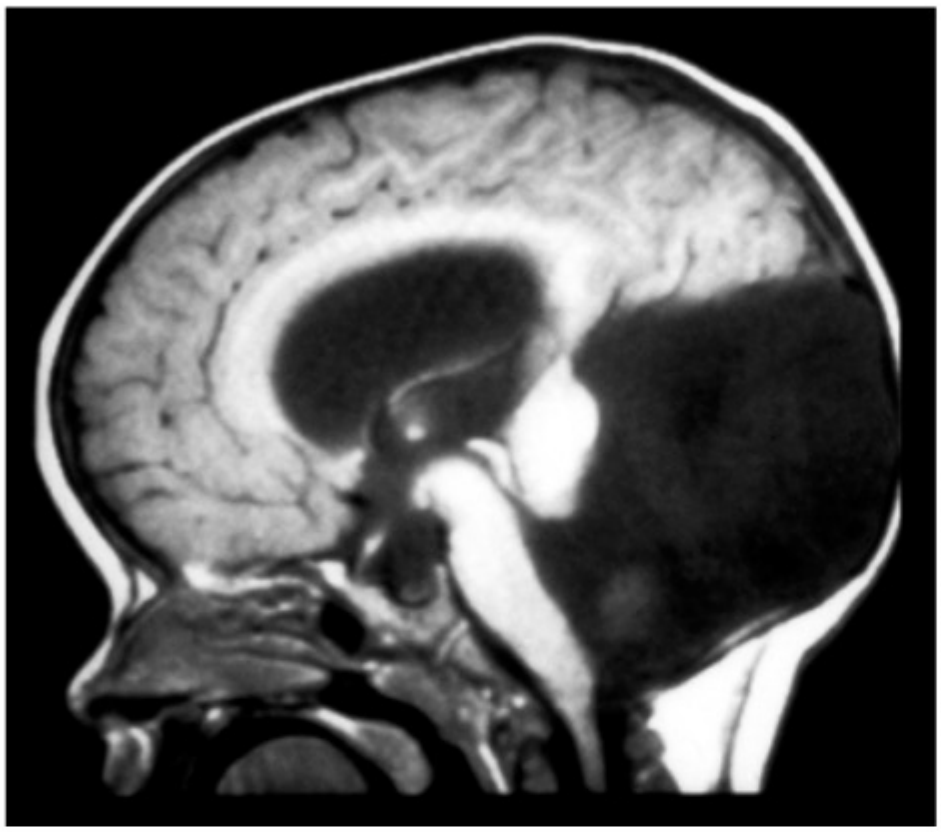

Living Art Enterprises, LLC/Science Source

▲ **Figure 20–2.2B** Dandy-Walker Malformation

2.3 Prenatal/Perinatal Brain Injury

2.3.1 Germinal Matrix Hemorrhage

- Hypoxic/ischemic damage to periventricular *gray* matter (germinal matrix) → *hemorrhage* into ventricular system
- Increased risk in *premature* infants

2.3.2 Periventricular Leukomalacia

- *Infarcts* in periventricular *white* matter
- Increased risk in *premature* infants

2.3.3 Cerebral Palsy

- Nonprogressive neurologic motor deficit
- Symptoms include dystonia, spasticity, athetosis/ataxia
- Frequent in premature babies
- Caused by *periventricular leukomalacia*

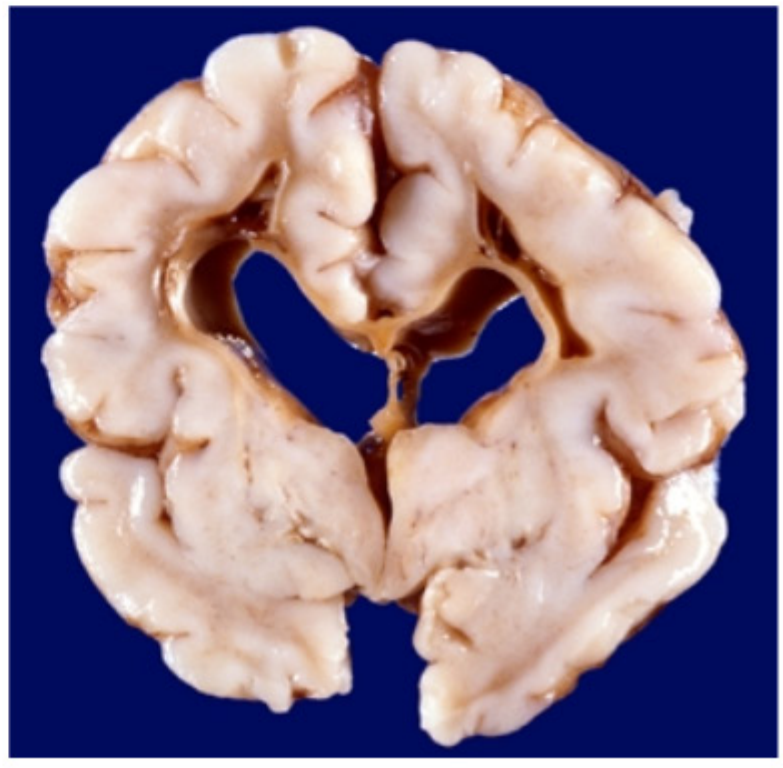

Jan Leestma MD/Custom Medical Stock Photo

▶ **Figure 20–2.3** Periventricular Leukomalacia

Please visit us at www.Groupinsiders.com

© DeVry/Becker Educational Development Corp. All rights reserved.

2.4 Fetal Alcohol Syndrome

- Excessive maternal alcohol intake during pregnancy.
- Characteristics include:
  - Facial abnormalities
  - Microcephaly
  - Atrial septal defect
  - Intellectual disability and growth retardation
  - Epicanthal folds
  - Short palpebral fissures
  - Maxillary hypoplasia
  - Thin upper lip
  - Micrognathia
  - Poorly developed philtrum

Mediscany/Visuals Unlimited, Inc.

▲ **Figure 20–2.4** Fetal Alcohol Syndrome

2.5 Holoprosencephaly

Decreased separation of hemispheres across midline; results in cyclopia; associated with Patau syndrome, severe fetal alcohol syndrome, and cleft lip/palate.

- Results in cyclopia.
- Associated with Patau syndrome, severe fetal alcohol syndrome, and cleft lip/palate.

Ralph C. Eagle, Jr./Science Source

▲ **Figure 20–2.5** Holoprosencephaly

Please visit us at www.Groupinsiders.com

© DeVry/Becker Educational Development Corp. All rights reserved.

3 Cerebral Herniation

Herniation is a protrusion of tissue into a place it does not belong. Caused by diffuse edema or local mass effect (for example, tumor, hemorrhage). The three types of herniation are *subfalcine (cingulate), transtentorial (uncinate),* and *tonsillar.*

3.1 Subfalcine (aka Cingulate)

- Cingulate gyrus displaced underneath falx to opposite side.
- Compression of *anterior cerebral artery* (infarction).

3.2 Tonsillar Herniation

- Displacement of cerebellar tonsils through the foramen magnum.
- *Compression of brainstem* (pons, medulla).

3.3 Transtentorial (Uncal, Medial Temporal) Herniation

- Medial aspect of temporal lobe compressed against the tentorium cerebelli.
- Compresses cranial nerve III *(fixed, dilated pupil; "blown pupil").*
- Also compresses *posterior cerebral artery* leading to primary visual cortex infarction and ultimately *"cortical blindness."*
- Progression of herniation results in compression of opposite cerebral peduncle.
- Stretching of upper brainstem vessels → *Duret hemorrhages* in the pons.

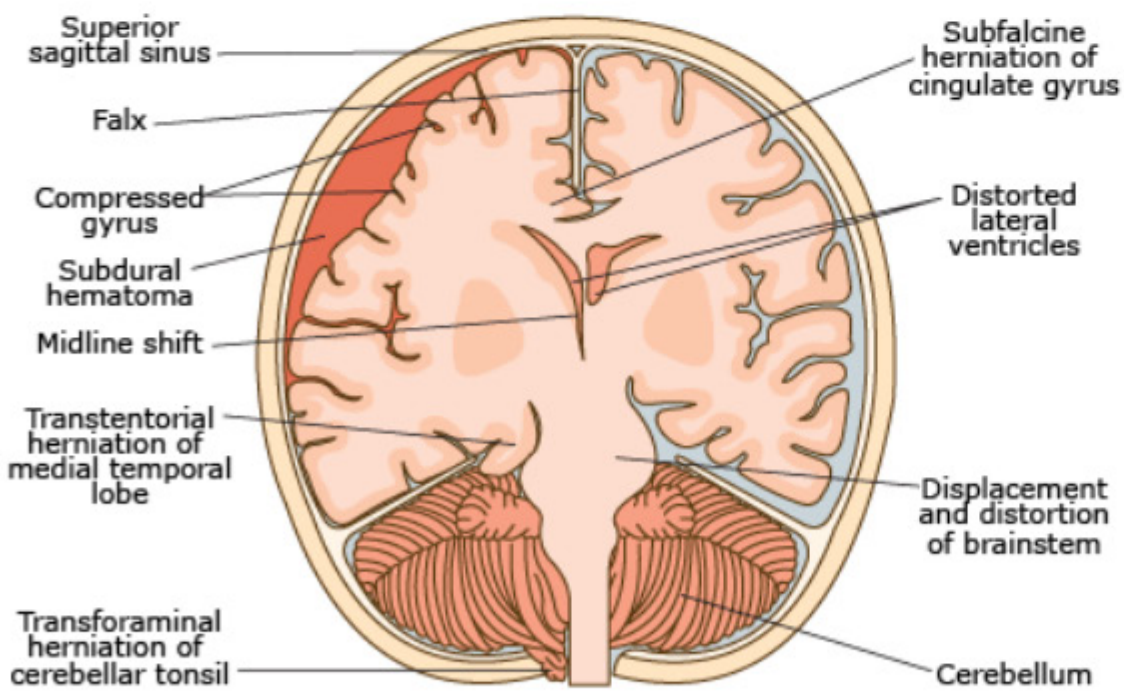

▲ **Figure 20–3.3A** Cerebral Herniation

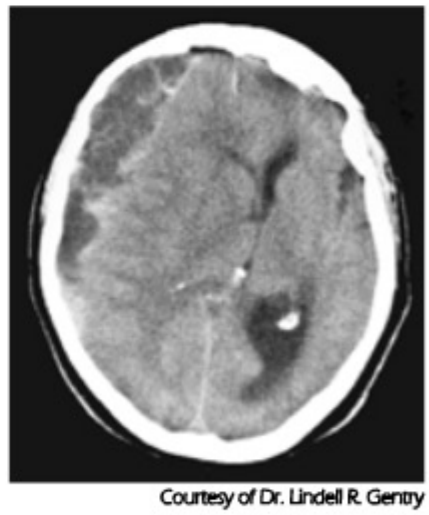

Courtesy of Dr. Lindell R. Gentry

▲ **Figure 20–3.3B** Effects of Uncal and Subfalcine Herniations of the CN III and PCA

Please visit us at www.Groupinsiders.com

© DeVry/Becker Educational Development Corp. All rights reserved.

4 Cranial Pressure Abnormalities

4.1 Hydrocephalus

- Normal pressure hydrocephalus
- Communicating hydrocephalus
- Noncommunicating hydrocephalus
- Hydrocephalus ex vacuo

4.1.1 Normal Pressure Hydrocephalus

- Does not result in increase in subarachnoid space volume.
- Expansion of ventricles distorts the fibers of the corona radiata and leads to the clinical triad of dementia *(reversible cause in the elderly)*, ataxia, and urinary incontinence.

4.1.2 Communicating (Non-obstructive)

Decreased CSF resorption by arachnoid villi (post-meningitis arachnoid scarring) leading to increased ICP.

4.1.3 Noncommunicating

Obstruction anywhere along the CSF flow.

4.1.4 Hydrocephalus Ex Vacuo

- Appearance of increased CSF in atrophy due to loss of brain tissue.
- ICP is normal; triad of normal pressure hydrocephalus is not seen (see topic 4.1.1).
  - Alzheimer disease (see topic 9.1 for more on Alzheimer disease)
  - Advanced HIV
  - Pick disease

Connection to Anatomy

See *Anatomy*, chapter 15, "Meninges and Circulation of Cerebrospinal Fluid."

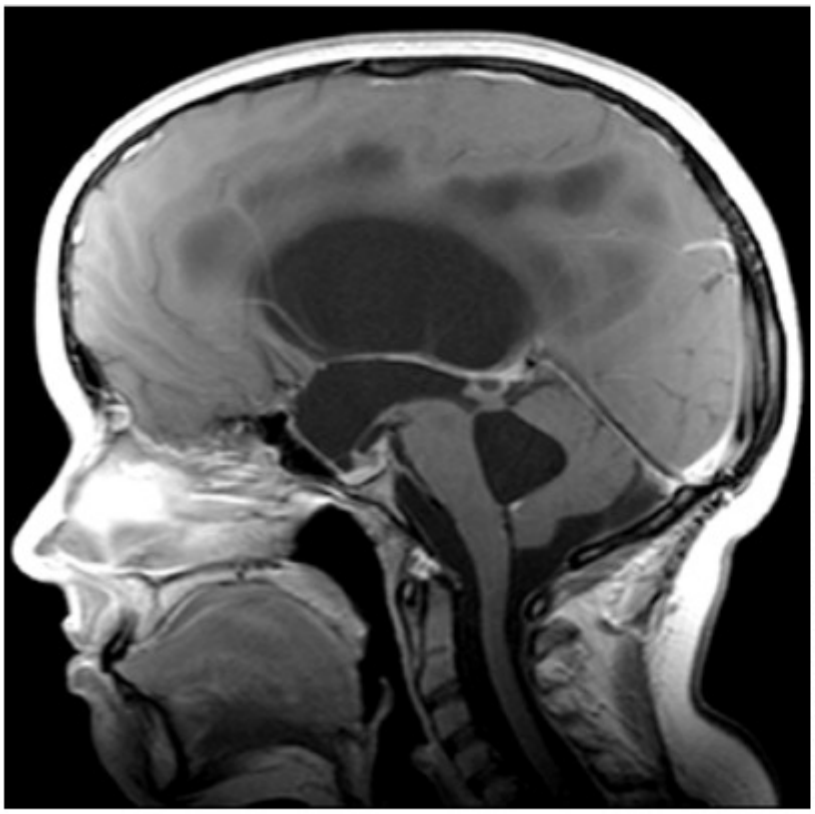

Living Art Enterprises, LLC/Science Source

▲ **Figure 20–3.4A** Holoprosencephaly

Barbara Galati/Pphotolab, Inc.

▲ **Figure 20–3.4B** Hydrocephalus

Please visit us at www.Groupinsiders.com

© DeVry/Becker Educational Development Corp. All rights reserved.

4.2 Pseudotumor Cerebri

Benign increase in intracranial pressure secondary to decreased CSF resorption in arachnoid granulations (non-obstructive).

Clinical Features

- Most commonly seen in overweight females of childbearing age.
- *Papilledema*
- Headache, projectile vomiting
- No evidence of tumor or obstruction
- *No* mental status changes
- *No* focal neurological signs

Please visit us at www.Groupinsiders.com

© DeVry/Becker Educational Development Corp. All rights reserved.

5 Head Trauma

5.1 Parenchymal Injuries

5.1.1 Concussion

- Clinical syndrome of altered mental status secondary to head injury
- Loss of consciousness, temporary respiratory arrest, and loss of reflexes
- *Amnesia present*
- *Neurologic recovery is complete*

5.1.2 Contusion

- Direct parenchymal injury to brain
- *Coup* injury: Cerebral injury *at* point of impact
- *Contrecoup* injury: Cerebral injury *opposite* to point of impact

Biophoto Associates/Science Source

▲ **Figure 20–5.1A** Head Trauma

5.1.3 Diffuse Axonal Injury

Definition

Injury to white matter due to acceleration and deceleration

Locations

- Corpus callosum, periventricular white matter, and hippocampus
- Cerebral and cerebellar peduncles

Pathology

- Axonal swelling of white matter
- Poor prognosis

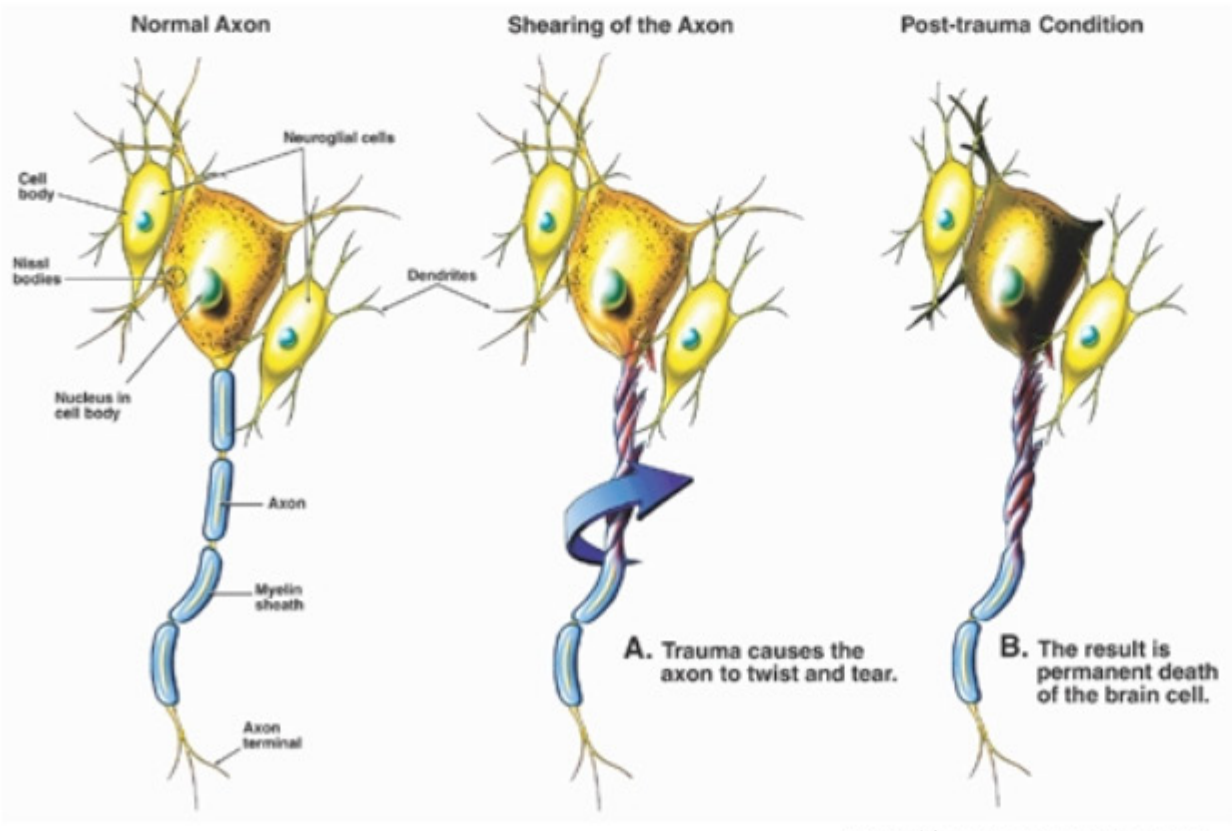

Nucleus Medical Art/Visuals Unlimited, Inc.

◀ **Figure 20–5.1B** Diffuse Axonal Injury

Please visit us at www.Groupinsiders.com

© DeVry/Becker Educational Development Corp. All rights reserved.

5.2 Traumatic Vascular Injury (Hematoma)

- Epidural
- Subdural
- Subarachnoid
- Intraparenchymal

5.2.1 Epidural Hematoma

- Rupture of *middle meningeal artery*, often secondary to temporoparietal fracture, creating a blood-filled space between the bone and dura.
- *Lucid interval* before loss of consciousness; "talk and die syndrome"
- Deficits
  - Contralateral hemiparesis
  - Ipsilateral pupillary dilation
- Head CT (without contrast) scan is the imaging test of choice.
- Treatment consists of creating burr holes to relieve pressure.
- Biconvex-shaped hemorrhage that does not cross suture lines.
- Transtentorial herniation may take place. See topic 3.3, "Cerebral Herniation."

Living Art Enterprises, LLC/Science Source

▲ **Figure 20–5.2A** Epidural Hematoma: Biconvex Bleed

Please visit us at www.Groupinsiders.com

© DeVry/Becker Educational Development Corp. All rights reserved.

5.2.2 Subdural Hematoma

- Tear of *bridging veins* between dura and arachnoid membranes.
- Slow venous bleeding with delayed onset of symptoms.
- Most common intracerebral lesion in traumatic brain injury.
- Risk factors:
  - Brain atrophy (elderly)
  - Anticoagulant therapy (coumadin)
  - Shaking, whiplash
- Present within 48 hours after injury.
- Head CT scan (without contrast) is the imaging test of choice.
- Crescent-shaped hemorrhage that crosses suture lines.
- Gyri are preserved since pressure is distributed equally.
- Cannot cross falx tentorium.

▲ **Figure 20–5.2B** Subdural Hematoma

5.3 Spinal Cord Trauma

- **Pathogenesis:** Associated with displacement of spinal column
- **Paraplegia:** Thoracic segments
- **Quadriplegia**: Cervical segments
- **C3–C5**: Respiratory compromise, C3, 4, and 5 keep you alive (See *Anatomy,* chapter 16, "Spinal Cord.")

5.4 Overview

▼ **Table 20–5.4** Motor Neuron Signs

Sign	UMN Lesion	LMN Lesion
Weakness	Positive	Positive
Atrophy	Negative	Present
Fasciculation	Negative	Present
Reflexes	Increased	Decreased
Tone	Increased	Decreased
Babinski	Positive	Negative
Spastic paralysis	Positive	Negative
Clasp knife spasticity	Positive	Negative

Please visit us at www.Groupinsiders.com

© DeVry/Becker Educational Development Corp. All rights reserved.

6 Spinal Cord Lesions

See *Anatomy,* chapter 16, "Spinal Cord" for the organization and sequencing of the spinal cord tracts.

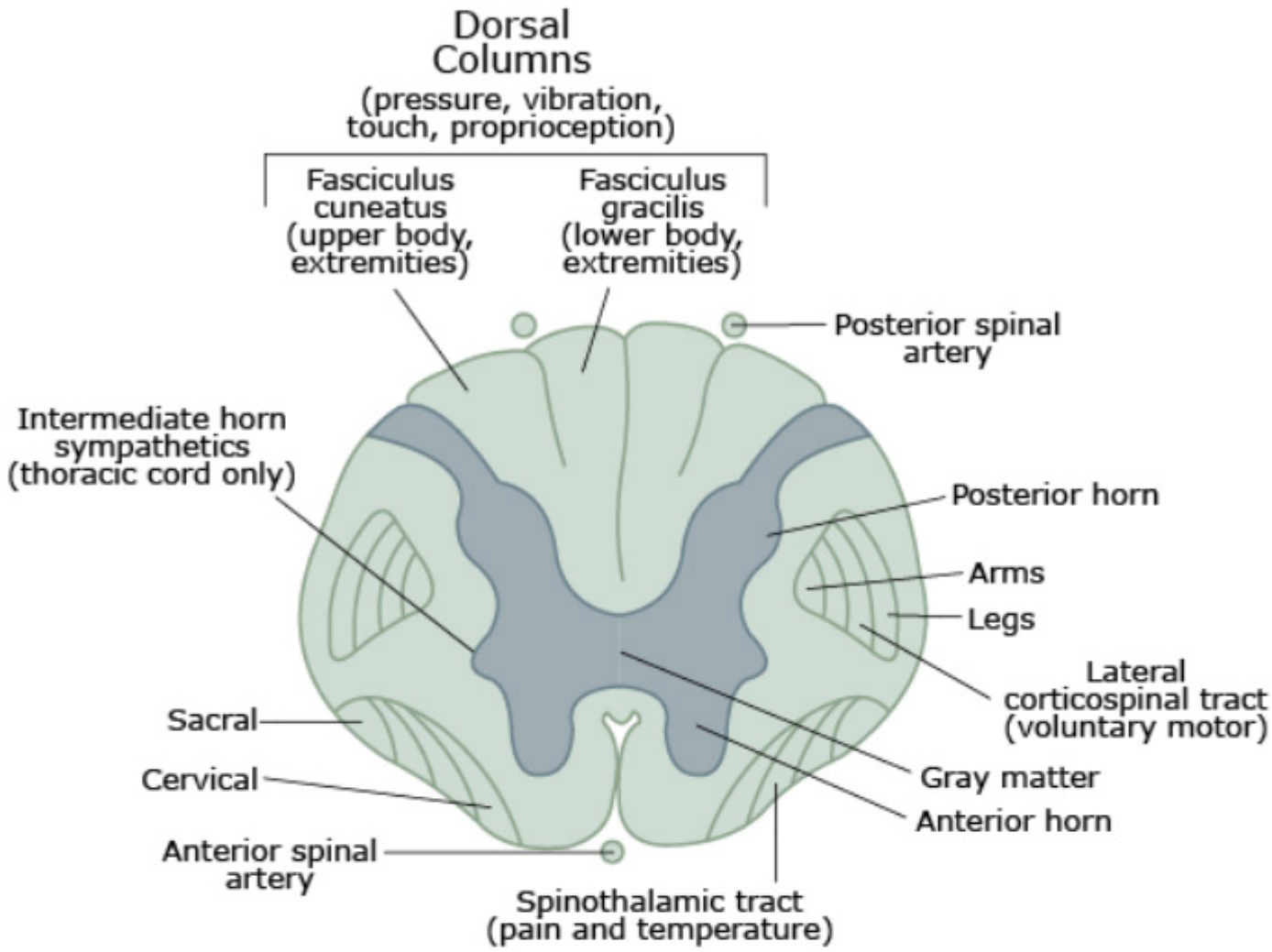

▲ **Figure 20–6.0** Spinal Cord and Associated Tracts

6.1 Poliomyelitis and Werdnig-Hoffmann Disease

- LMN lesions only due to destruction of anterior horns
- Symptoms: Flaccid paralysis

Please visit us at www.Groupinsiders.com

© DeVry/Becker Educational Development Corp. All rights reserved.

6.2 Multiple Sclerosis

- Mostly white matter of *cervical* region
- Random and *a*symmetric lesions, due to demyelination
- Symptoms:
  - Scanning speech
  - Intention tremor
  - Nystagmus

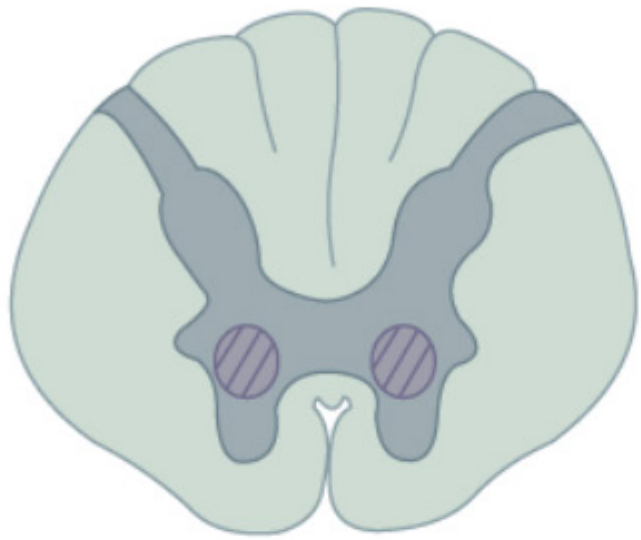

▲ **Figure 20–6.2A** Poliomyelitis: Lesion of the Anterior Horns

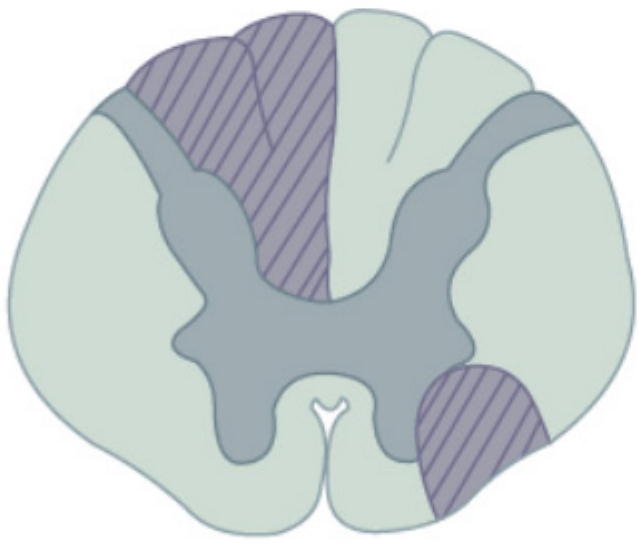

▲ **Figure 20–6.2B** Multiple Sclerosis: Lesion of Anterior Horns

6.3 Amyotrophic Lateral Sclerosis (Lou Gehrig Disease)

- Combined upper and lower motor neuron deficits with accompanying signs.
- No sensory deficit.

Please visit us at www.Groupinsiders.com

© DeVry/Becker Educational Development Corp. All rights reserved.

6.4 Complete Occlusion of Anterior Spinal Artery

- Upper thoracic *anterior spinal artery (ASA)*
  - This territory is a watershed area.
- Artery of Adamkiewicz can be affected when there is an *abdominal aortic aneurysm* (AAA).
  - Normally it supplies ASA below–T8.
  - When damaged, it results in urinary and fecal incontinence.
- Spares dorsal columns and Lissauer tract (or posterolateral tract).

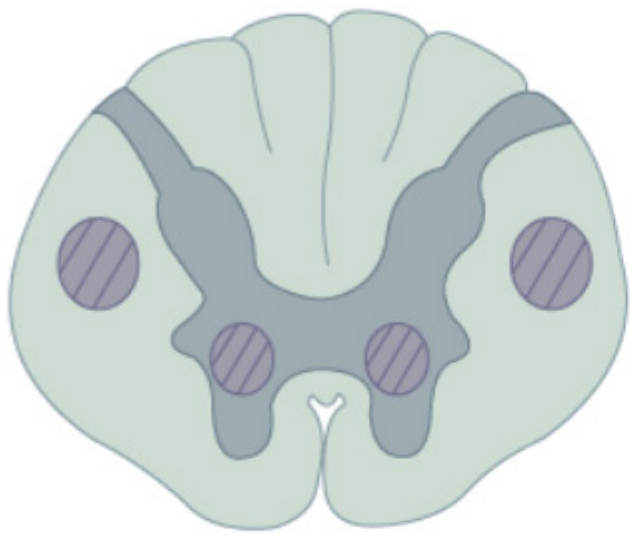

▲ **Figure 20–6.4A** Amyotrophic Lateral Sclerosis

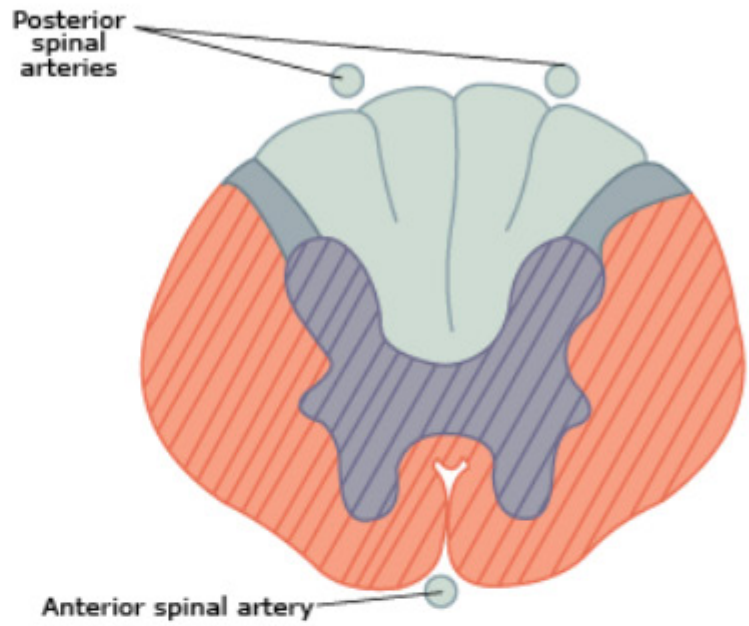

▲ **Figure 20–6.4B** ASA Occlusion Lesions

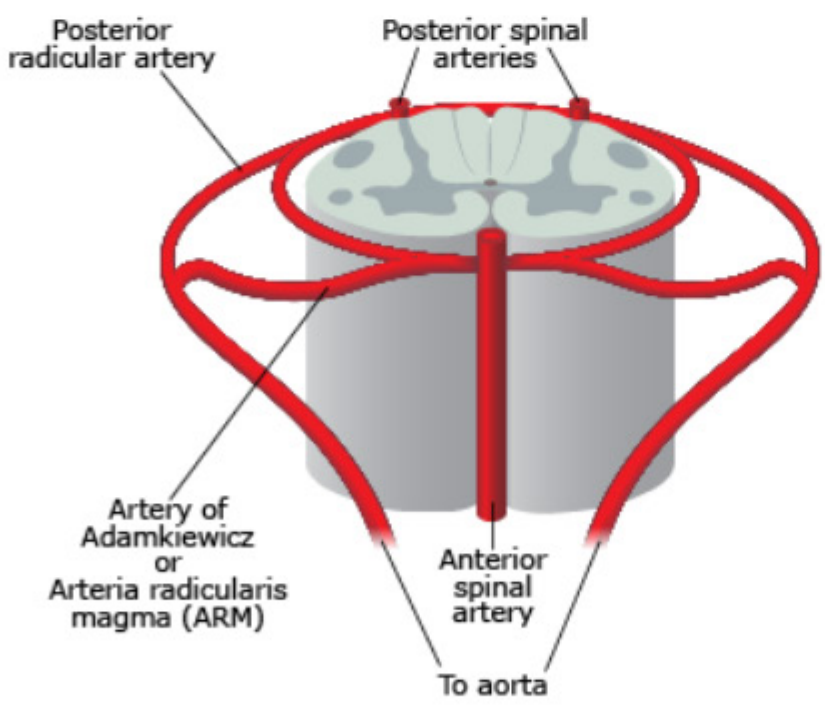

▲ **Figure 20–6.4C** Artery of Adamkiewicz

Please visit us at www.Groupinsiders.com

© DeVry/Becker Educational Development Corp. All rights reserved.

6.5 Tabes Dorsalis (Tertiary Syphilis)

- Degeneration of dorsal roots and dorsal columns
- Symptoms: Impaired proprioception, locomotor ataxia

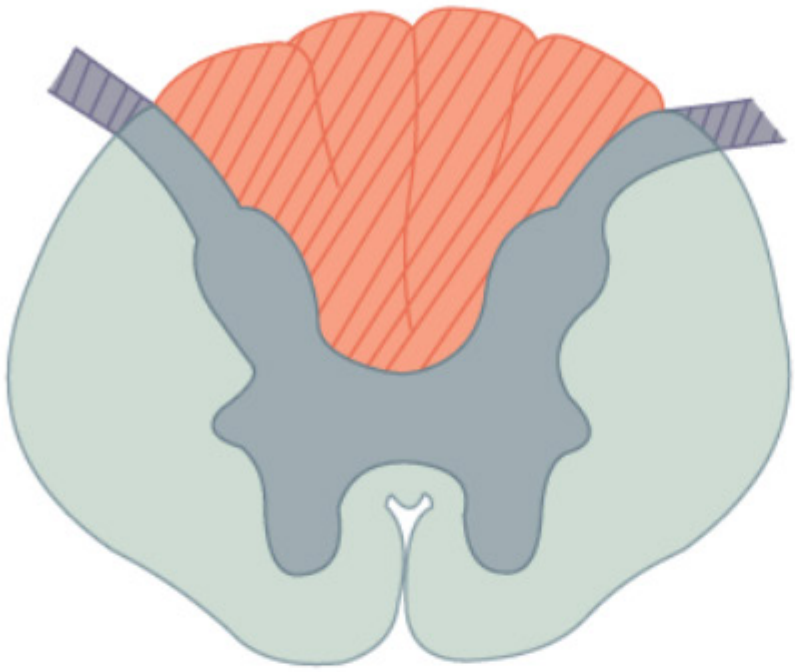

▲ **Figure 20–6.5** Tabes Dorsalis

6.6 Subacute Combined Degeneration (Vitamin B12 Deficiency)

- Vitamin E deficiency
- Friedreich ataxia
  - Demyelination of dorsal columns and spinocerebellar tracts
  - Symptoms: Ataxic gait, hyperreflexia, impaired position and vibration sense

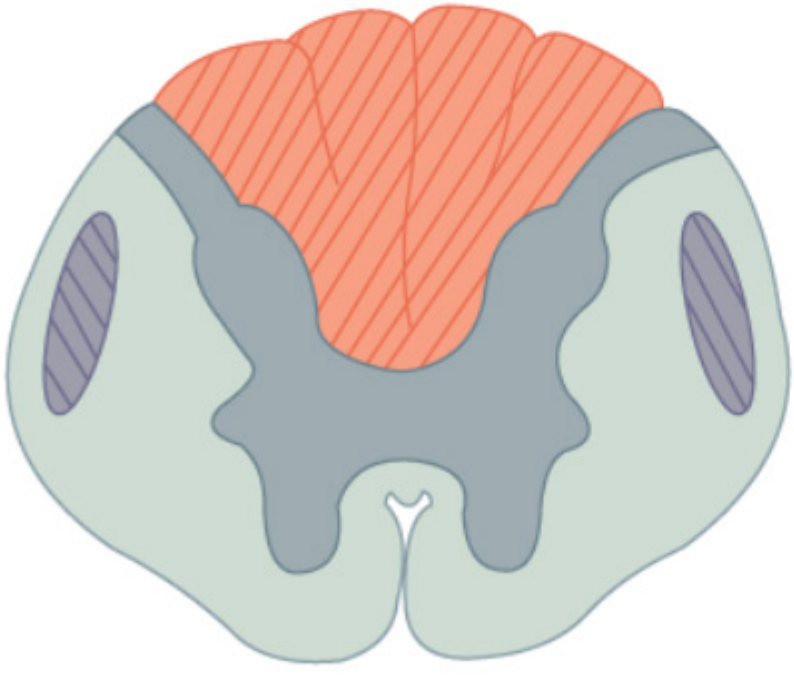

▲ **Figure 20–6.6** Subacute Combined Degeneration

Please visit us at www.Groupinsiders.com

© DeVry/Becker Educational Development Corp. All rights reserved.

6.7 Syringomyelia

- Enlargement of the central canal
- First, damages anterior white commissure of spinothalamic tract (second-order neurons)
- Symptoms:
  - Bilateral "cape-like" loss of pain and temperature sensation (C8-T1) of upper extremity with preservation of sensation
  - Anterior horn involvement results in atrophy of intrinsic muscles of the hand
- Seen with Arnold-Chiari type II
- May affect other tracts

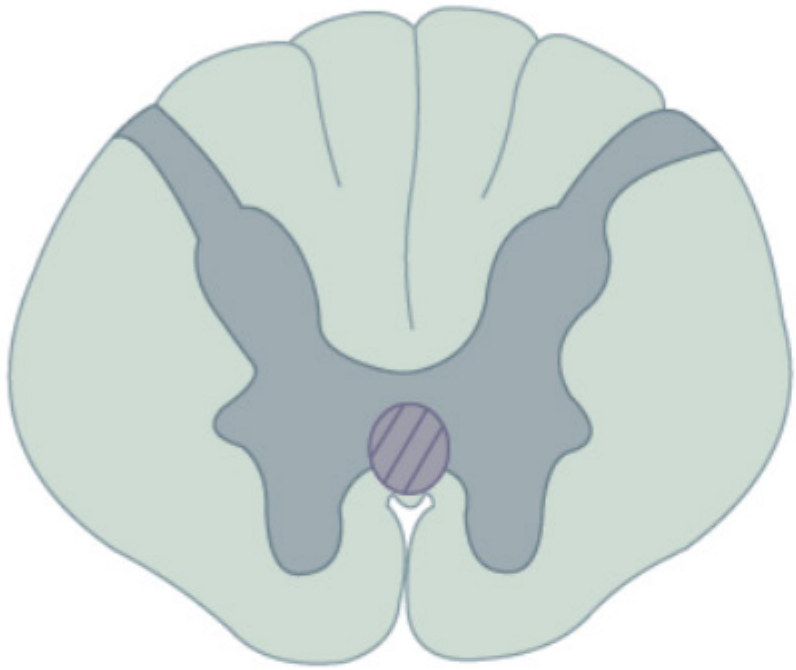

▲ **Figure 20–6.7** Syringomyelia

Please visit us at www.Groupinsiders.com

© DeVry/Becker Educational Development Corp. All rights reserved.

6.8 Brown-Séquard Syndrome

- **Causes:** *Trauma,* rarely cord compression or partial transverse myelitis
- **Symptoms**
  - *Ipsilateral*
    - —*UMN* signs *(corticospinal tract)* below lesion
    - —Loss of tactile, vibration, proprioception sense *(dorsal column)* below lesion
    - —*LMN* signs (such as flaccid paralysis) at level of lesion
  - *Contralateral*
    - —*Loss of* pain and temperature *(spinothalamic tract)* below lesion
  - Loss of *all* sensation at level of lesion
  - Bowel/bladder dysfunction is rare
  - If lesion occurs above T1, *presents* with *Horner syndrome*

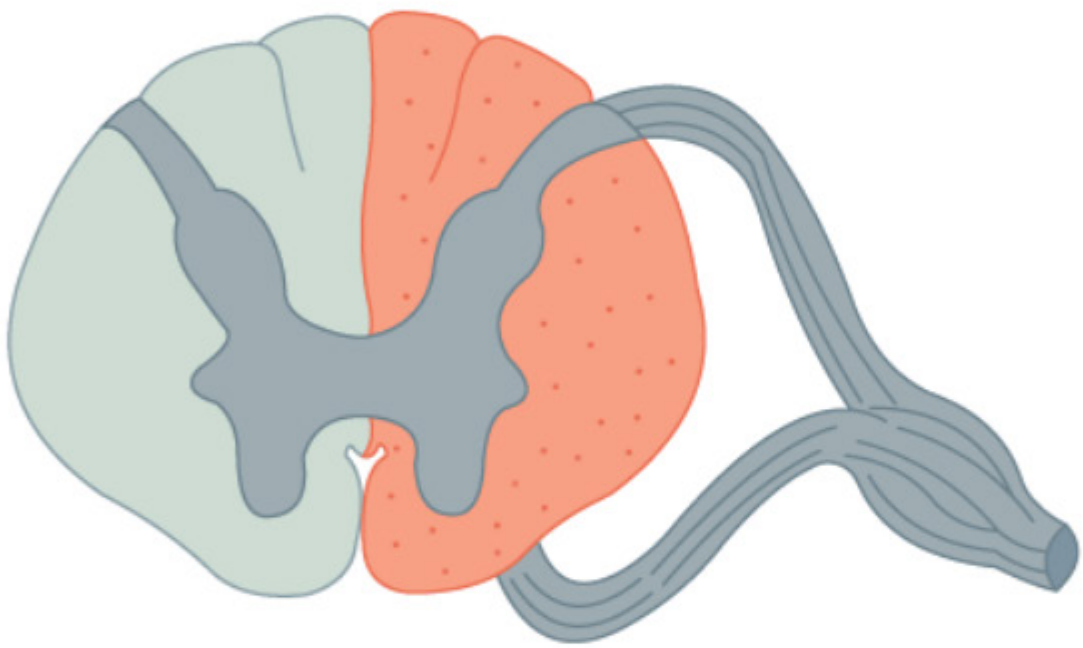

▲ **Figure 20–6.8** Syringomyelia Lesion

Please visit us at www.Groupinsiders.com

© DeVry/Becker Educational Development Corp. All rights reserved.

7 Cerebrovascular Disease

7.1 Hypoxic-Ischemic Encephalopathy (H.I.E.)

- Irreversible damage after five minutes
- One of four basic pathological processes
  - Hypoxia
  - Thrombotic occlusion of vessel
  - Embolic occlusion of vessel
  - Rupture of vessel

7.2 Cerebral Edema

Edema: Accumulation of excess fluid in the brain parenchyma.

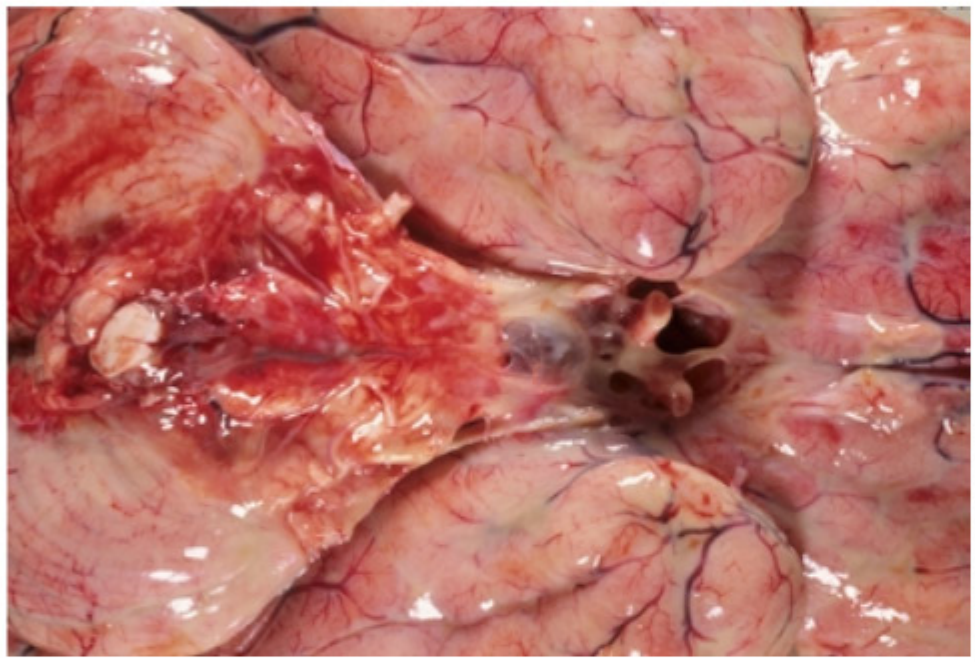

Custom Medical Stock Photo

▲ **Figure 20–7.2** Cerebral Edema

7.2.1 Cytotoxic Edema

Intercellular fluid accumulations secondary to damage to neural cells

7.2.2 Vasogenic Edema

- Secondary to disruption of the blood-brain barrier
- Increased vascular permeability allows vascular fluids to "leak" into intercellular spaces between nerve cells.
- Hypoventilation with respiratory acidosis

7.3 Hypoxia

- *Plenty of blood, but not enough oxygen*
  - CO poisoning
  - Near drowning/suffocation
  - Respiratory arrest
  - Prolonged status epilepticus

Please visit us at www.Groupinsiders.com

© DeVry/Becker Educational Development Corp. All rights reserved.

- *Selective vulnerability*
  - *Hippocampus* (CA1, aka Sommer sector)
  - Neocortical pyramidal neurons
  - Cerebellar Purkinje neurons
  - Thalamus
  - Basal ganglia
  - Brainstem
  - Hypothalamus

7.4 Hypoxia-Ischemia

7.4.1 Gross Changes Found in Ischemia

- 0 to 12 hours: No changes
- 12 to 24 hours: Minimal changes
- *24 to 48 hours: Indistinct gray-white matter junction*
- *2 to 10 days: Friable tissue with marked edema, separation of gray and white matter*
- 2 to 3 weeks: Tissue liquefies
- 3 weeks to 3 months: Fluid-filled cavity demarcated by gliotic scar
- Years: Old cyst surrounded by gliotic scar

7.4.2 Microscopic Changes Found in Ischemia

- 0 to 12 hours: Minimal or no changes
- 12 to 48 hours: *Red neurons* (hypereosinophilic cytoplasm with pyknotic nuclei)
- 24 to 72 hours: Neutrophilic infiltration + Necrosis
- 3 to 5 days: Macrophages
- 1 to 2 weeks: *Reactive gliosis (astrocytosis) + neovascularization*
- More than 2 weeks-months: Glial scar
  - No fibroblasts, so no fibrotic scar, like elsewhere

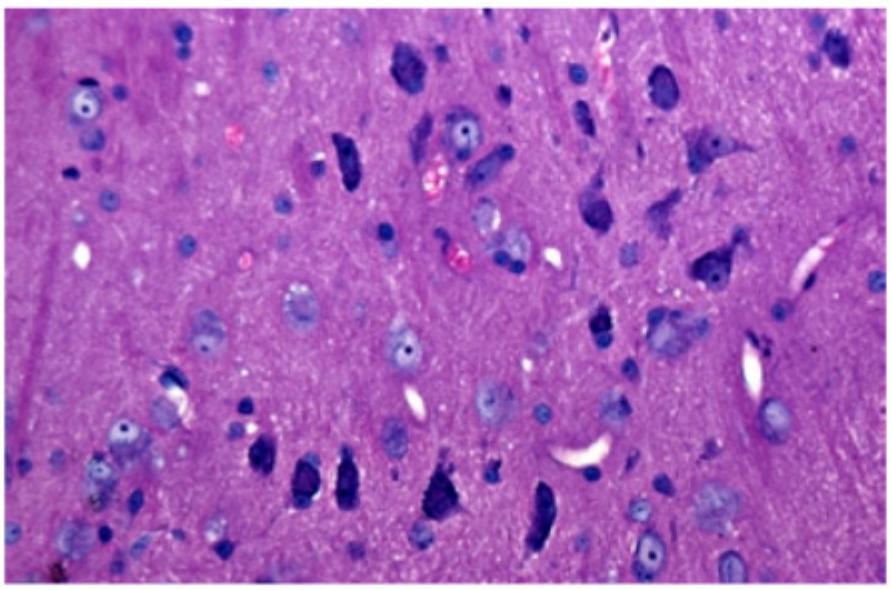

R. Rosemary/Custom Medical Stock Photo

▲ **Figure 20–7.4** 12 to 48 Hours "Dead Reds"

Please visit us at www.Groupinsiders.com

© DeVry/Becker Educational Development Corp. All rights reserved.

7.5 Ischemia Patterns

7.5.1 Global Ischemia

- *Drop in systemic blood pressure (below 40–50mm Hg).*
  Examples: Cardiogenic, septic, and hemorrhagic types of shock
- *Increase in intracranial pressure*
  - This exceeds mean arterial pressure, results in no more cerebral blood flow.
  - Edema, hemorrhage (subdural/subarachnoid)
- *Watershed regions are the most affected in global ischemia.*
  - Most distant fields of arterial perfusion.
  - Normally there are boundaries between major cerebral/cerebellar artery perfusion territories.
  - First areas to feel the pinch when cerebral blood flow drops.

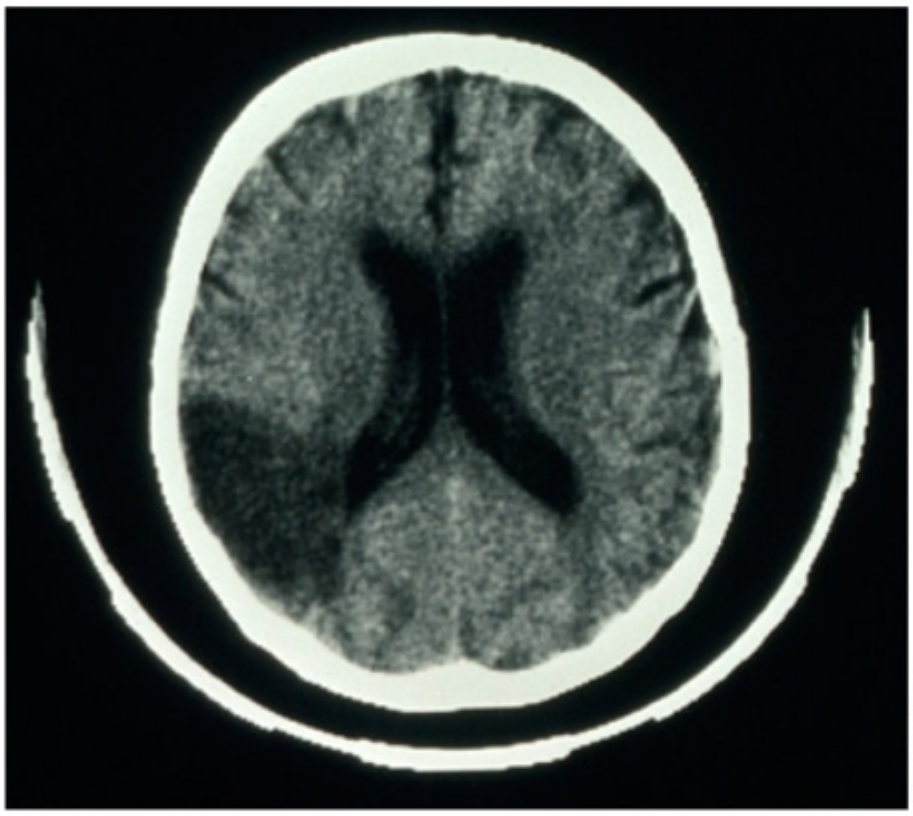
Wellcome Images

▲ **Figure 20–7.5A** Acute Watershed Infarcts

7.5.2 Focal Ischemia

- **Atherosclerotic stroke**
  - Tends to be a pale infarct.
  - Atheromatous plaques within carotid arteries lead to ischemic stroke with subsequent necrosis with red neurons.
  - Form cystic cavity with reactive gliosis.
- **Embolic stroke**
  - Tends to be hemorrhagic type.
  - Atrial fibrillation, carotid dissection, patent foramen ovale, endocarditis

Please visit us at www.Groupinsiders.com

© DeVry/Becker Educational Development Corp. All rights reserved.

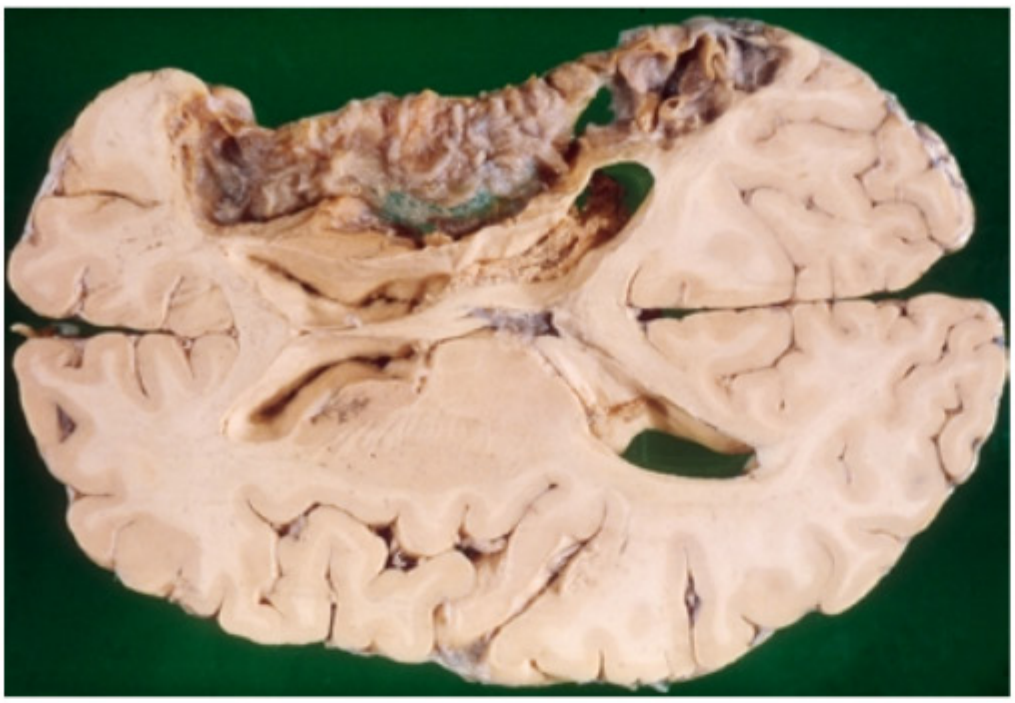

Biophoto Associates/Science Source

◀ **Figure 20–7.5B** Atherosclerotic Stroke

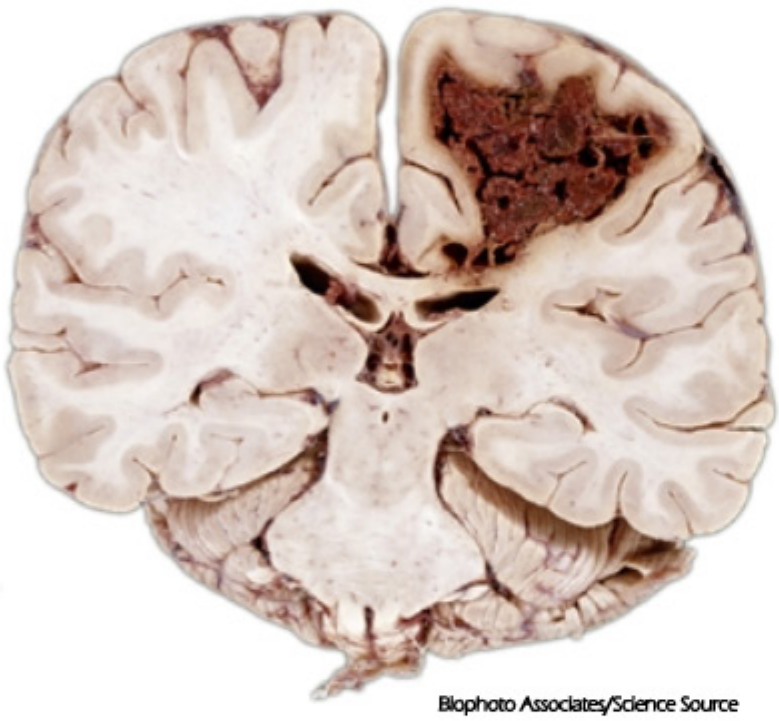

Biophoto Associates/Science Source

◀ **Figure 20–7.5C** Chronic Right MCA Infarct

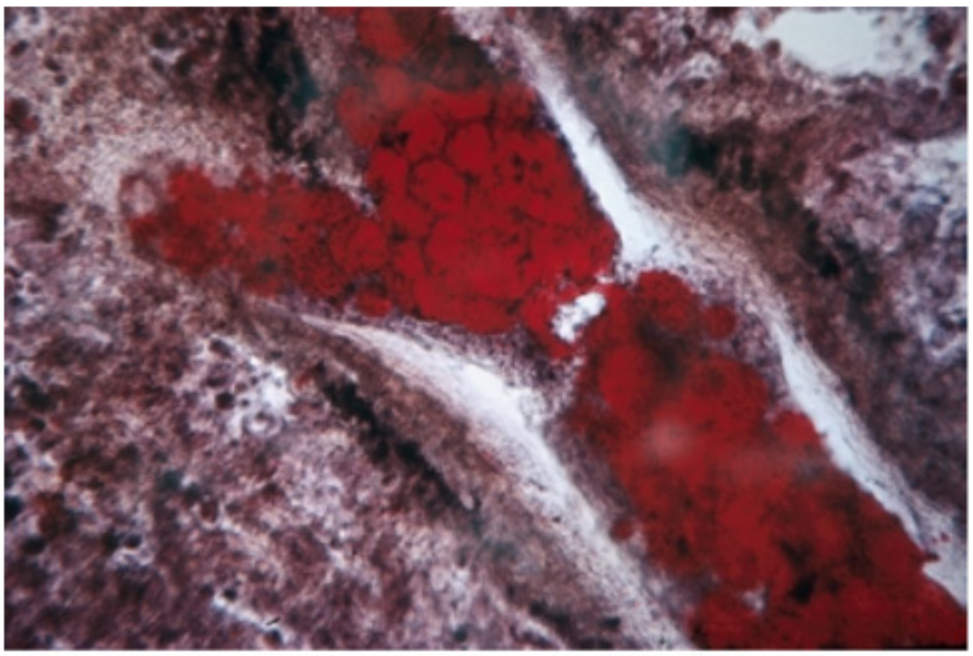

O.J. Staats MD/Custom Medical Stock Photo

◀ **Figure 20–7.5D** Focal Ischemia

Please visit us at www.Groupinsiders.com

© DeVry/Becker Educational Development Corp. All rights reserved.

- **Lacunar infarcts = Small vessel disease**
  - Contralateral subthalamic nucleus lesion
  - Loss of inhibition of thalamus through globus pallidus, resulting in hemiballismus

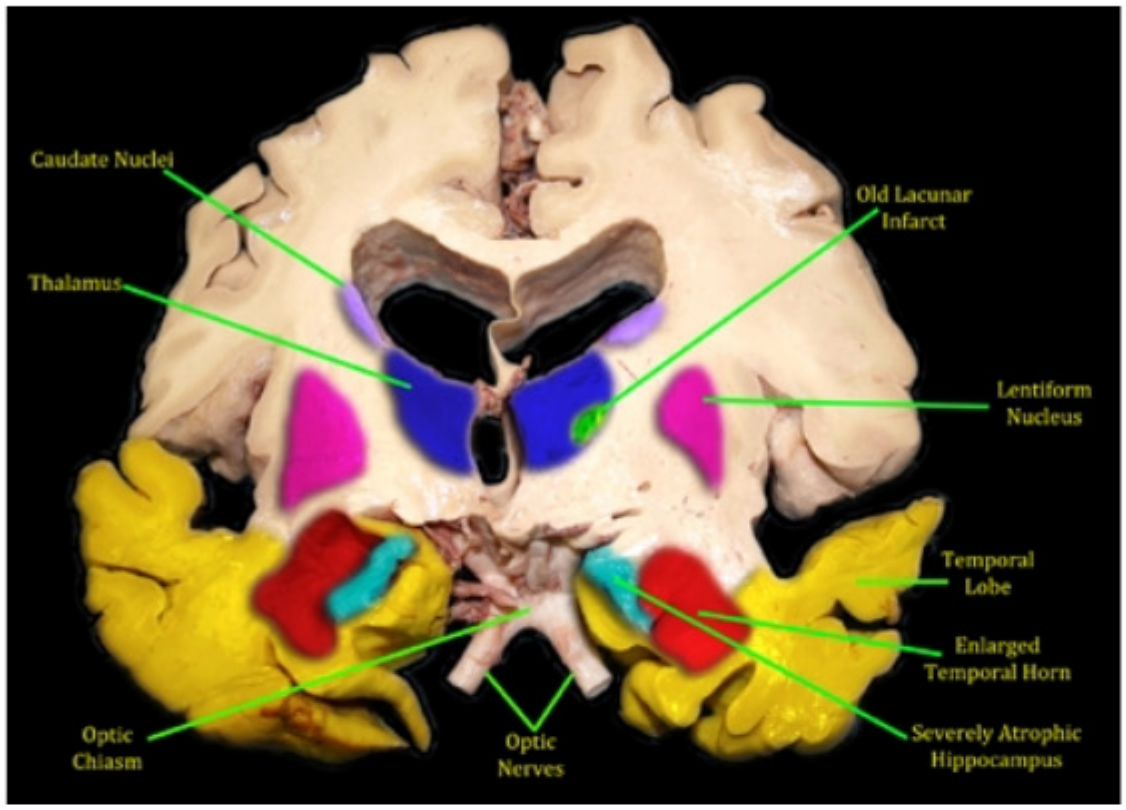

Living Art Enterprises/Science Source

▲ **Figure 20–7.5E** Lacunar Infarcts

- **Ischemic Stroke Imaging**
  - Bright on diffusion-weighted MRI *(gold standard)* or noncontrast CT indicates hemorrhage for which tPA therapy is contraindicated.
  - Bright areas on noncontrast CT indicate hemorrhage
  - Dark on CT in ~24 hours

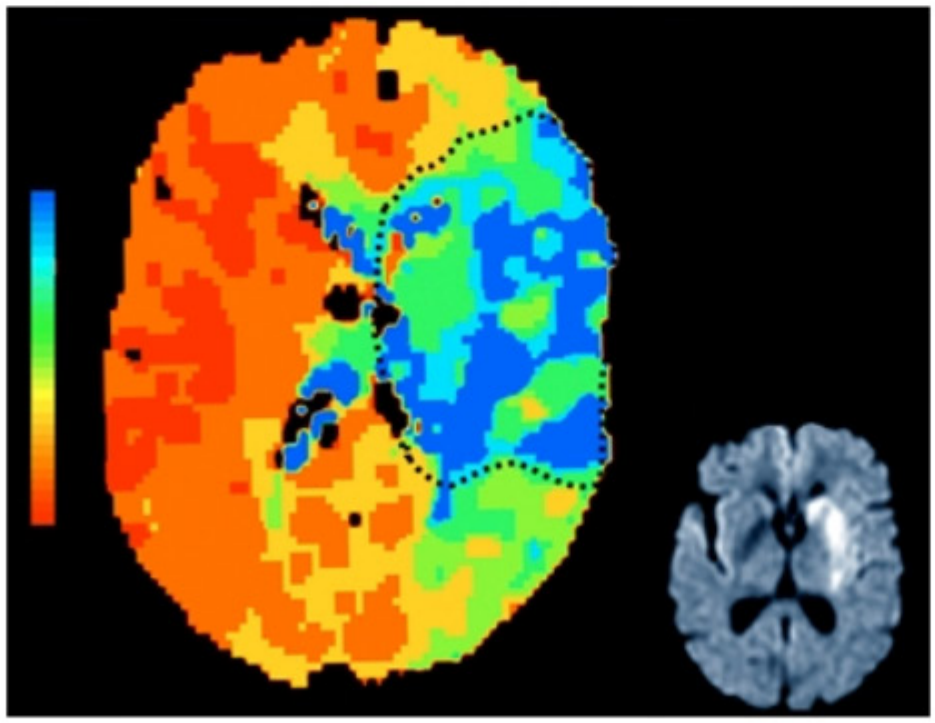

Gilles Podevins/Phototake, Inc.

▲ **Figure 20–7.5F** H.I.E. Stroke Imaging

Please visit us at www.Groupinsiders.com

© DeVry/Becker Educational Development Corp. All rights reserved.

7.6 Locations and Types of Cerebral Strokes

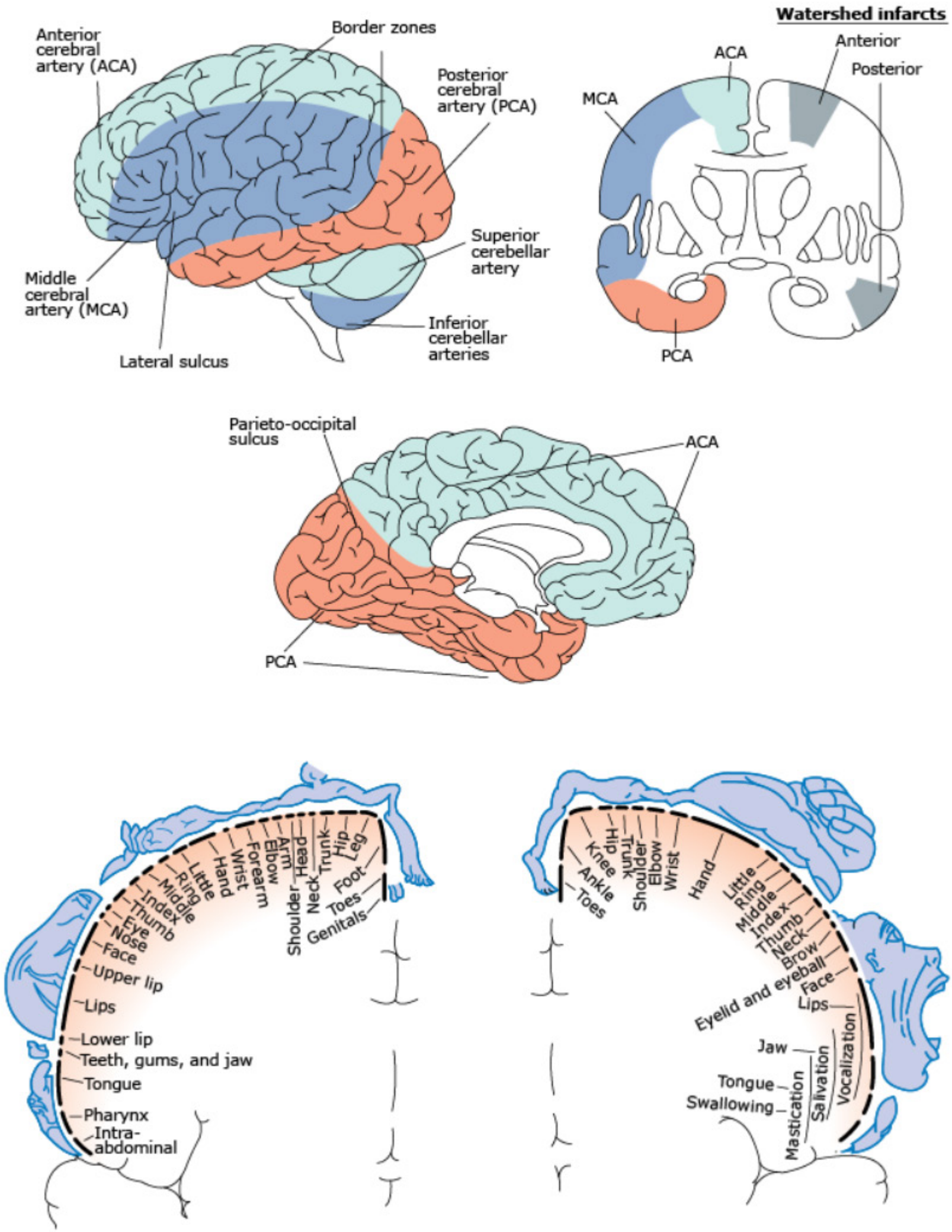

▲ **Figure 20–7.6** Cerebral Distribution

Please visit us at www.Groupinsiders.com

© DeVry/Becker Educational Development Corp. All rights reserved.

7.6.1 Middle Cerebral Artery

Area of lesion

- Motor cortex—upper limb and face
- Sensory cortex—upper limb and face

Symptoms

- *Contralateral*
  - Paralysis—upper limb and face
  - Loss of sensation—upper limb and face
- *Ipsilateral*
  - Hemineglect if lesion affects nondominant side
  - Wernicke area, Broca area are affected on the dominant side
  - Head/eyes to the side of lesion

7.6.2 Anterior Cerebral Artery

Area of lesion

- Motor cortex—lower limb
- Sensory cortex—lower limb

Symptoms

- Contralateral paralysis—lower limb
- Contralateral loss of sensation—lower limb

▼Table 20–7.6A Posterior Circulation Deficits

Communicating Arteries			
AComm	Common site of saccular (berry) aneurysm → impingement on cranial nerves	Visual field defects	Lesions are typically aneurysms, not strokes
PComm	Common site of saccular (berry) aneurysm	CN III palsy—eye is "down and out"	Lesions are typically aneurysms, not strokes
Posterior Circulation			
ASA	Lateral corticospinal tract Medial lemniscus Caudal medulla—hypoglossal nerve	Contralateral hemiparesis—lower limbs ↓ contralateral proprioception Ipsilateral hypoglossal dysfunction (tongue deviates ipsilaterally)	
PICA	Lateral medulla—vestibular nuclei, lateral spinothalamic tract, spinal trigeminal nucleus, nucleus ambiguus, sympathetic fibers Inferior cerebellar peduncle	Vomiting, vertigo, nystagmus Limbs/face—↓ pain, temperature sensation Dysphagia, hoarseness, ↓ gag reflex Ipsilateral Horner's syndrome Ataxia, dysmetria	Lateral medullary (Wallenberg's) syndrome Nucleus ambiguus effects are specific to PICA lesions Don't *pick* a (PICA) *horse* (hoarseness) that *can't eat* (dysphagia)
AICA	Lateral pons—vestibular nuclei, facial nucleus, spinal trigeminal nucleus, cochlear nuclei, sympathetic fibers Middle and inferior cerebellar peduncles	Vomiting, vertigo, nystagmus. Paralysis of face, ↓ lacrimation, salivation, ↓ taste from anterior 2/3 of tongue, ↓ corneal reflex. Face— ↓ pain and temperature sensation. Ipsilateral ↓ hearing. Ipsilateral Horner's syndrome	Lateral pontine syndrome Facial nucleus effects are specific to AICA lesions *Facial droop* means AICA's *pooped*
PCA	Occipital cortex, visual cortex	Contralateral hemianopsia with macular sparing	

Please visit us at www.Groupinsiders.com

© DeVry/Becker Educational Development Corp. All rights reserved.

7.6.3 Lateral Striate Artery

Area of lesion

- Striatum
- Internal capsule

Symptoms

- Contralateral hemiparesis/hemiplagia
- Common location of lacunar infarcts secondary to unmanaged hypertension (see topic 7.5.2, "Focal Ischemia").

7.6.4 Subacute Infarction

The evolution of a cerebral infarct occurs in three phases, which can be defined by the "rule of 1's":

1. *Acute* may occur from *1 day to 1 week*. Injured area is soft and edematous with undefined areas of the brain.
2. *Subacute* may occur from *1 week to 1 month*. Injured area shows obvious tissue destruction and liquefactive necrosis.
3. *Chronic* is greater than *1 month*. Injured tissue is phagocytized and replaced with cavition surrounded by gliosis.

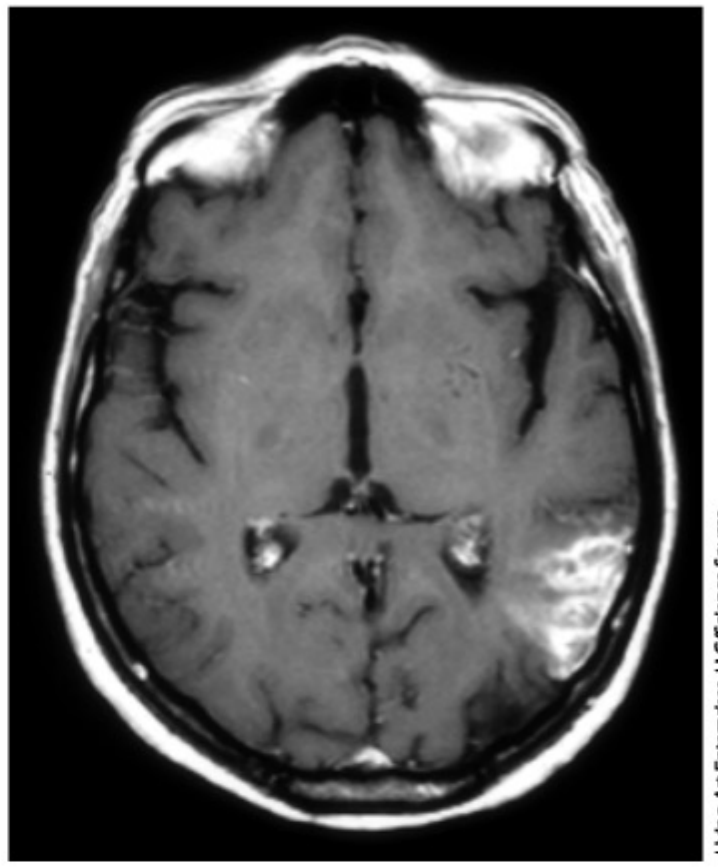

Living Art Enterprises, LLC/Science Source

▲ **Figure 20–7.6B** Subacute Infarction

7.6.5 Transient Ischemic Attacks

- Ischemic episodes secondary to microembolization of plaque material with transient neurologic deficit lasting less than 24 hours.
- Typical neurologic deficits include:
  - Visual loss, paresthesias, loss of speech, hemiparesis
- Precede most cerebrovascular incidents
- Treatment options:
  - Aspirin
  - Clopidogrel
  - Ticlopidine

7.6.6 Multi-infarct Dementia

- Cerebral atherosclerosis
- Presents as a *slow, step-wise*, decrease in mental function
- Important to distinguish from Alzheimer and other causes of dementia

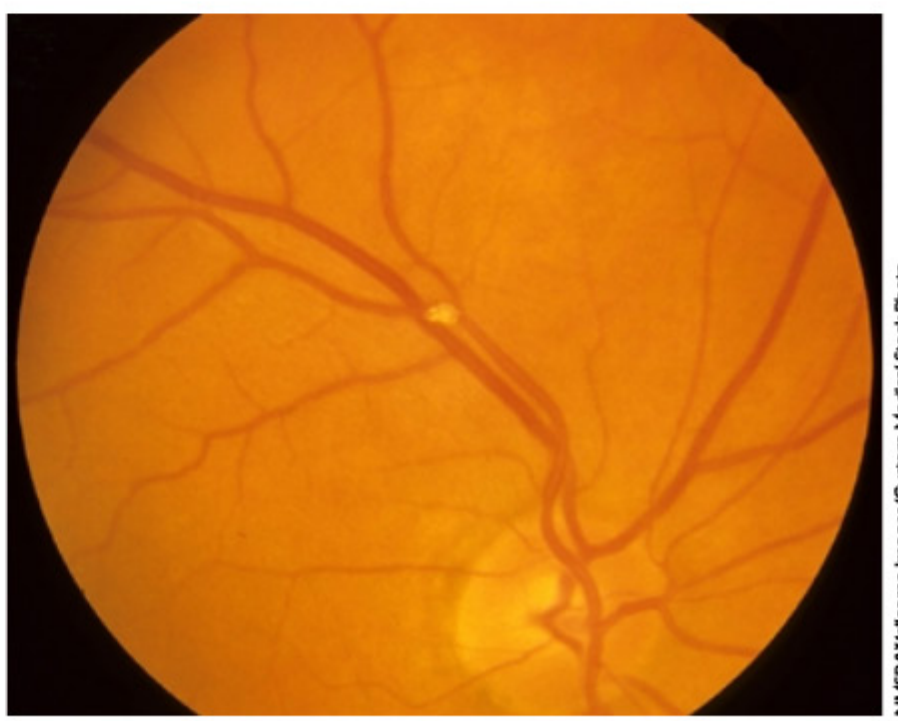

NMSB/Wellcome Images/Custom Medical Stock Photo

▲ **Figure 20–7.6C** Transient Ischemic Attacks

Please visit us at www.Groupinsiders.com

© DeVry/Becker Educational Development Corp. All rights reserved.

7.7 Hemorrhagic Infarcts: Causes

7.7.1 Hypertension

- Most commonly caused by systemic hypertension, but also amyloid angiopathy, vasculitis, and neoplasm.
- Typically occurs in basal ganglia and internal capsule but also can be lobar.

7.7.2 Aneurysms

- **Saccular aneurysms:** Occur in the anterior circulation near major arterial branch points 90% of the time.
- Can rupture at any time, resulting in subarachnoid hemorrhage.
  - Associated with acute increases in intracranial pressure (straining at stool or sexual orgasm).
  - Blood forced into the subarachnoid space causing sudden, excruciating headache ("the worst headache I've ever had"). See *Anatomy*, chapter 17, "Spinal Cord."

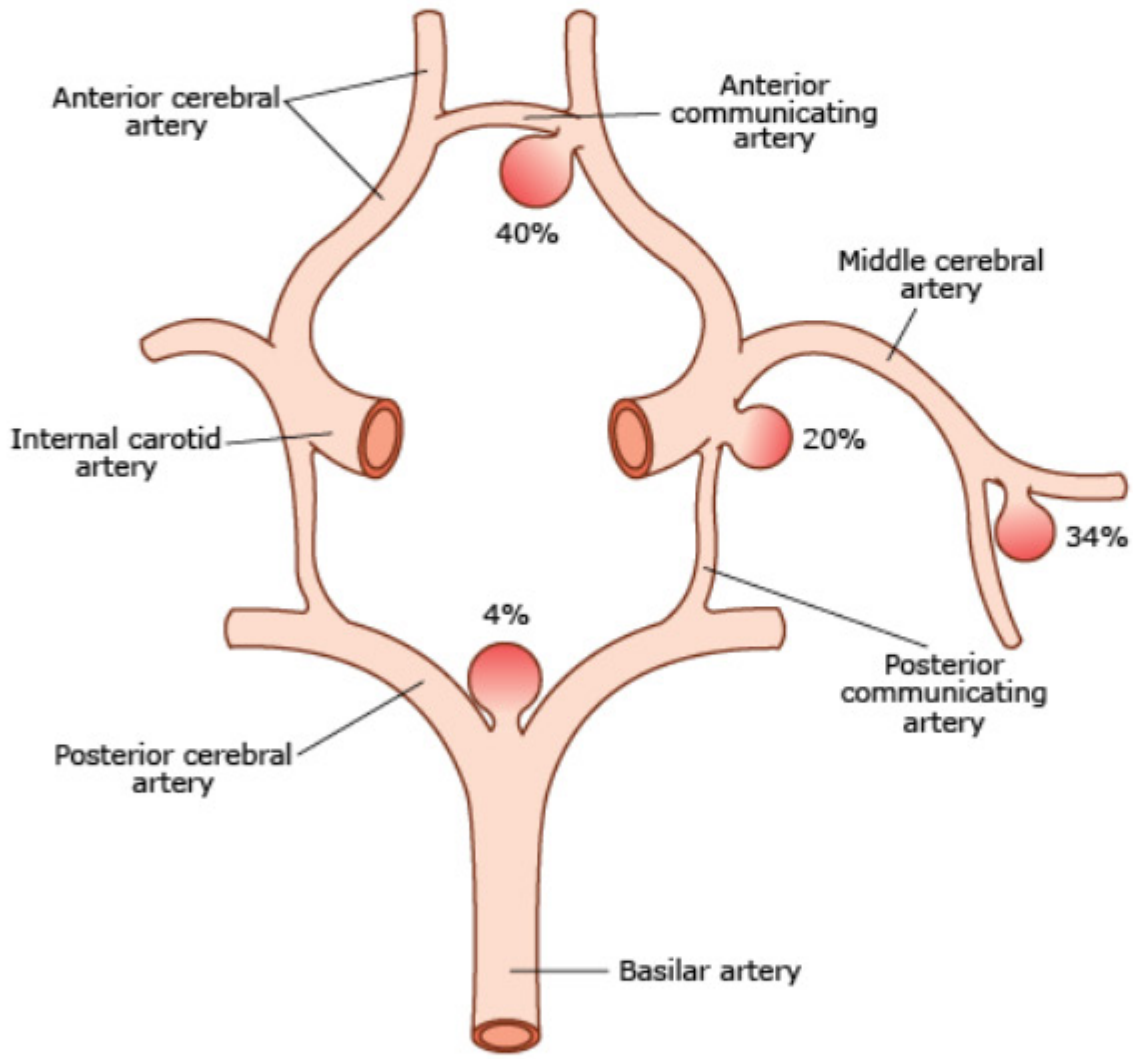

▲ **Figure 20–7.7A** Hemorrhagic Infarcts: Causes

  - Increased risk in the following conditions: *APKD* (autosomal dominant polycystic Kidney disease), EDS (Ehlers-Danlos syndrome), *Marfan*, and *AVM* (arterio-venous malformation)

Please visit us at www.Groupinsiders.com

© DeVry/Becker Educational Development Corp. All rights reserved.

Clinical Features

- Bloody or xanthochromic spinal tap two to three days afterward.
- Risk of vasospasm due to blood breakdown not visible on CT.

Du Cane Medical Imaging Ltd/Science Source

▲ **Figure 20–7.7B** Berry Aneurysms

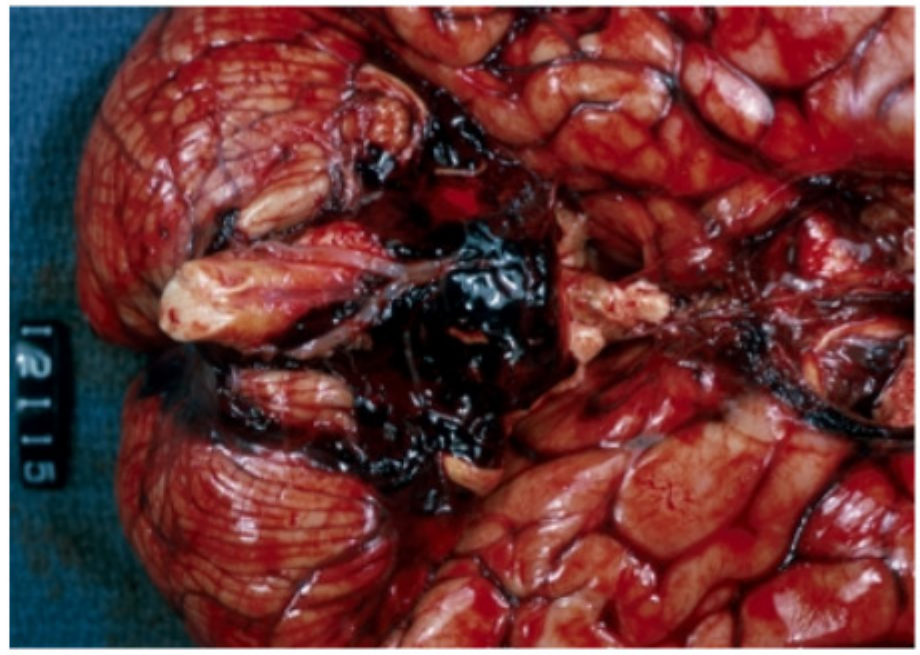

O.J. Staats MD/Custom Medical Stock Photo

▲ **Figure 20–7.7C** Subarachnoid Hemorrhage

7.7.3 Charcot-Bouchard Microaneurysms

- Associated with chronic hypertension
- Affects small vessels commonly in the basal ganglia and thalamus

7.8 Types of CNS Vascular Malformations

(See chapter 11, "Cardiovascular Pathology.")

- Cerebral arteriovenous malformations
  - Can be symptomatic or asypmtomatic
  - When symptomatic, often presents as
    - New onset seizure disorder
    - Intracerebral hemorrhage leading to subarachnoid hemorrhage
- Cavernous hemangiomas
  - Von Hippel-Lindau disease (see chapter 13, "Renal Pathology" and chapter 11, "Cardiovascular Pathology")
  - Sturge-Weber syndrome (see chapter 11, "Vascular Pathology")

Please visit us at www.Groupinsiders.com

© DeVry/Becker Educational Development Corp. All rights reserved.

8 Infectious Diseases

8.1 Meningitis

- Inflammation of meninges and cerebrospinal fluid within subarachnoid space
- Usually caused by infection, but also may be from chemical irritant or malignancy

8.1.1 Bacterial Meningitis

Etiologic agents

- Neonates
  - *E. coli*
  - Group B streptococci
  - *H. influenzae*
- **Infants and children**: *H. influenzae*
- **Adolescents**: *Neisseria meningitis*
- Elderly
  - *S. pneumoniae*
  - *Listeria monocytogenes*

Clinical Features

- Headache, irritability
- Photophobia
- Cranial nerve deficits
- Altered mental status
- Neck stiffness
- **Labs:** Lumbar puncture—CSF analysis
  - *Increased protein level*
  - *Increased WBC (primarily neutrophils)*
  - *Low glucose level*
  - Cloudy or purulent cerebrospinal fluid
  - Increased pressure

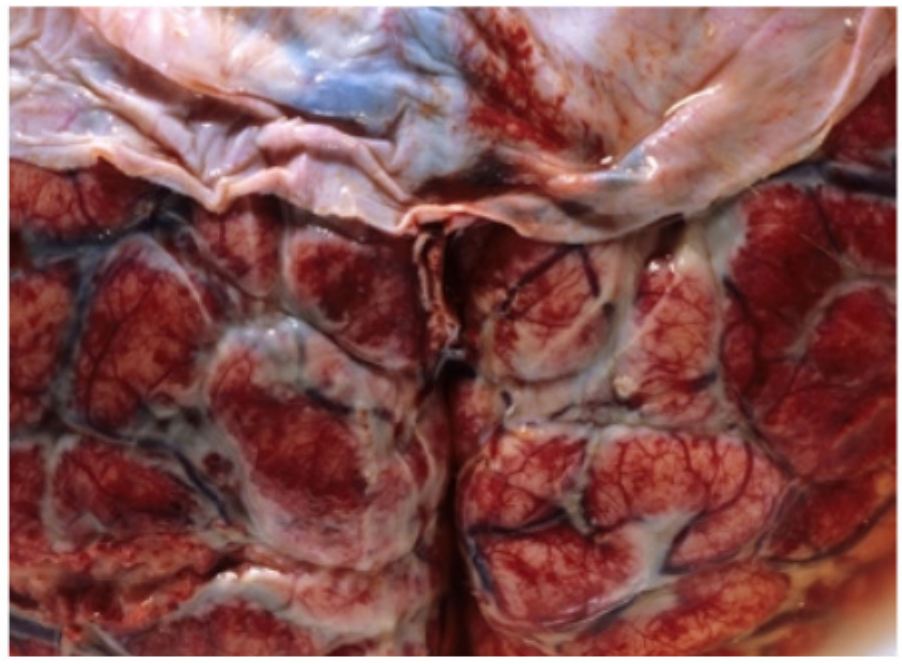

Custom Medical Stock Photo

▲ **Figure 20–8.1A** Bacterial Meningitis

8.1.2 Viral Meningitis

- Characterized by meningismus, fever, and altered mental status

Etiologic agents

- Enteroviruses: Coxsackievirus
- Most common during the summer months
- Arboviruses (more will be discussed in topic on encephalitis)
- HSV → EBV, VZV
- Mumps

Please visit us at www.Groupinsiders.com

© DeVry/Becker Educational Development Corp. All rights reserved.

Lumbar puncture (LP)

- *Lymphocytic pleocytosis:* If you don't see neuts on the CSF, it isn't bacterial!
- *Moderate protein elevation*
- *Normal glucose*

8.1.3 Chronic Bacterial Meningoencephalitis

- Tuberculous meningitis
  - Presents with headache, malaise, altered mental status, and vomiting.
  - Likes to stay around the *brainstem/posterior fossa meninges.*
  - Lumbar puncture (LP)
    —Moderate increase of lymphocytes and neutrophils
    —Elevated protein level
    —Normal or moderately reduced glucose level

8.1.4 Fungal Meningitis

Usually found in immunodeficient patients

Etiologic Agents

- *Candida Albicans:* Frequently found in neonatal period
- *Aspergillus* and *mucor* (rhizopus): Both angioinvasive
- ***Cryptococcus***
  - Oval yeast found in bird excreta
  - Most often community-acquired
  - *India ink on CSF*

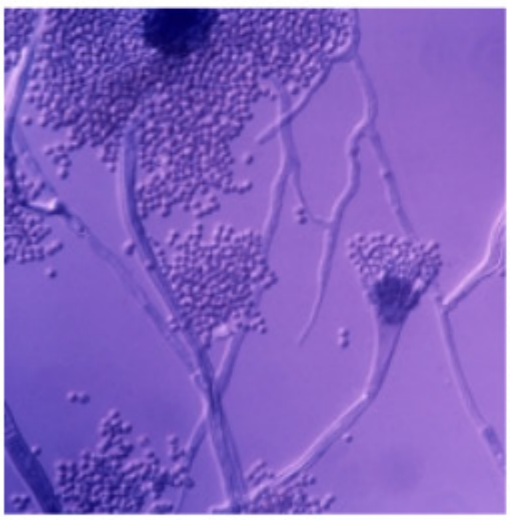

Daniel Snyder/Visuals Unlimited, Inc.

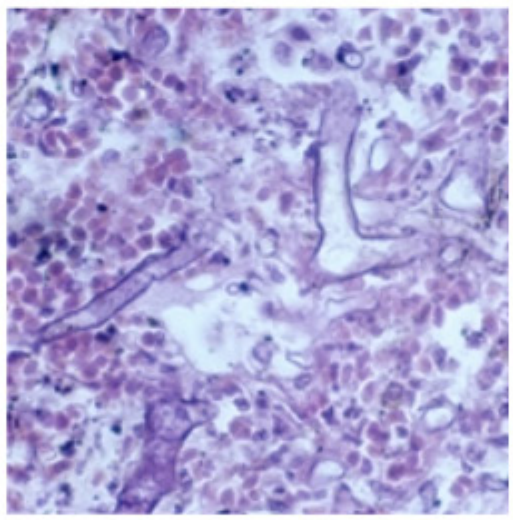

CNRI/Science Source

▲ **Figure 20–8.1B** Fungal Meningitis

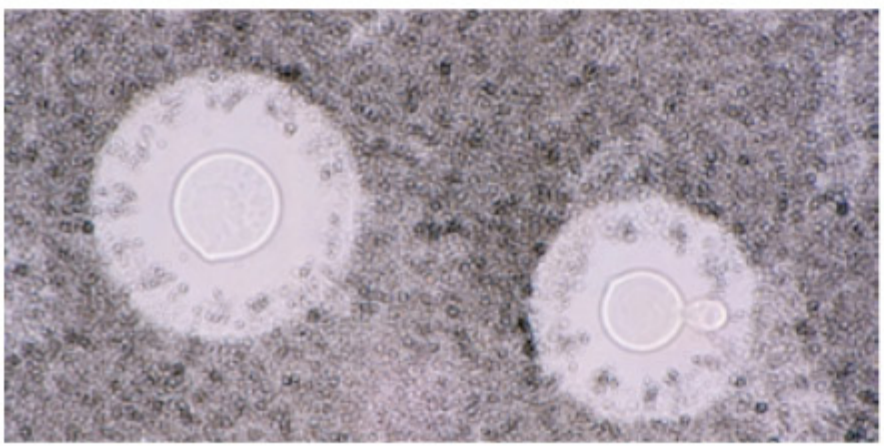

Dr. Gladden Willis/Visuals Unlimited, Inc.

◀ **Figure 20–8.1C** Cryptococci in a Mucinous Background

Please visit us at www.Groupinsiders.com

© DeVry/Becker Educational Development Corp. All rights reserved.

8.2 Neurosyphilis

Etiologic agent: Tertiary stage Treponema pallidum

Clinical Features

- Tabes dorsalis
- Wide-based gait
- LMN lesion → absent deep tendon reflexes
- Argyll Robertson pupil
  - Pupil accommodates
  - Does not react to light

8.3 CNS Parenchymal Infections

- **Brain Abscesses**
- **Encephalopathies**
  - Viral
  - Protozoal
  - Prion

8.3.1 Brain Abcesses

Definition: Acute focal suppurative infection of brain parenchyma.

Clinical Features

- Focal neurologic deficits
- Elevated CSF white cell count
- Elevated CSF protein
- *Ring-enhancing lesions on CT/MRI*

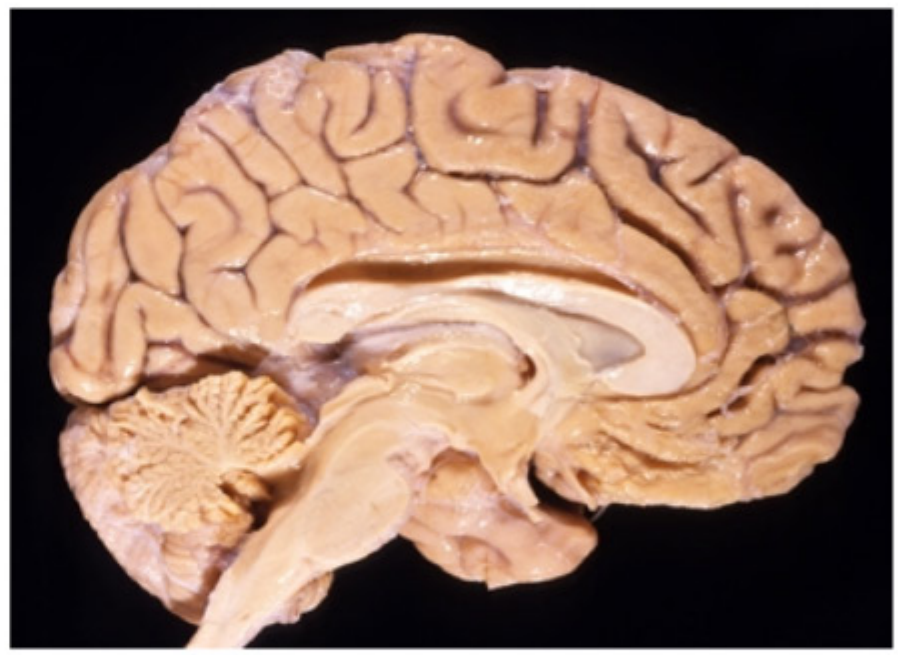

▲ **Figure 20–8.3A** Cytomegalovirus

8.3.2 Viral Encephalitis

- **Arbovirus Viral Encephalitis**
  - Arthropod-borne viruses
    - West Nile virus
    - St. Louis encephalitis
    - Eastern and western equine
  - Altered mental status
  - *Mononuclear cell-rich*
    - Lymphocytes, plasma cells, macrophages
  - Look for history of time spent outdoors, in developing nations, etc.
- **Cytomegalovirus**
  - Prenatal and immunosuppressed
  - In Utero
    - *Periventricular necrosis resulting in dystrophic calcification.*
    - Severe brain destruction followed by microcephaly.
- *Prominent cytomegalic cells with intranuclear and intracytoplasmic inclusions.*

Please visit us at www.Groupinsiders.com

© DeVry/Becker Educational Development Corp. All rights reserved.

Please visit us at www.Groupinsiders.com

- **Poliomyelitis**
  - CNS infection manifests initially with meningeal irritation and aseptic meningitis.
  - Attack of anterior horns with loss of motor neurons.
  - Flaccid paralysis with muscle wasting and hyporeflexia.
  - Death can occur from paralysis of respiratory muscles.
  - Spinal tract lesions can appear with poliomyelitis and Werdnig-Hoffman disease.
- **Rabies**
  - Transmitted by the bite of a rabid animal; most common are raccoons.
  - Causes severe encephalitis.
  - Virus enters central nervous system along peripheral nerves from the wound site.
  - Contracture of pharyngeal musculature on swallowing produces foaming at mouth.
  - Progresses to meningismus and to flaccid paralysis.
  - *Negri bodies:* Inclusions found in neurons.

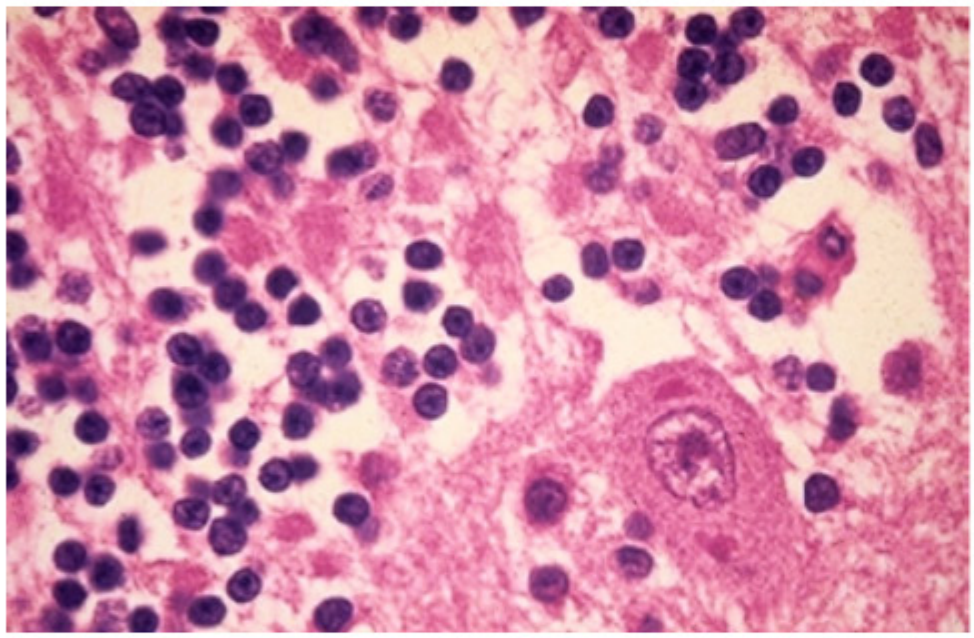

Dr. John D. Cunningham/Visuals Unlimited, Inc.

▲ **Figure 20–8.3B Viral Encephalitis: Rabies**

- **Progressive Multifocal Leukoencephalopathy (PML)**
  - Caused by *JC virus, a papovavirus.*
    —Virus infects oligodendrocytes and astrocytes, resulting in demyelination.
  - Occurs in *immunosuppressed* patients.
    —Transplant
    —HIV
  - Irregular, ill-defined destruction of *white matter*
  - Poor prognosis

© DeVry/Becker Educational Development Corp. All rights reserved.

- **Herpes Simplex Virus (HSV) Encephalitis**
  - **Herpes Simplex Virus type I**
    - —More common in *children and young adults.*
    - —Involves the inferior and medial regions of the *temporal lobes and orbital gyri of the frontal lobes,* causing alterations in mood, memory, and behavior.
  - *Cowdry type A intranuclear* viral inclusion bodies can be found in both neurons and glia.
  - **Herpes Simplex Virus type 2**
    - —Presents as meningitis in *adults.*
    - —Presents as *diffuse encephalitis in neonates* born by vaginal delivery to mothers with active HSV genital infections.

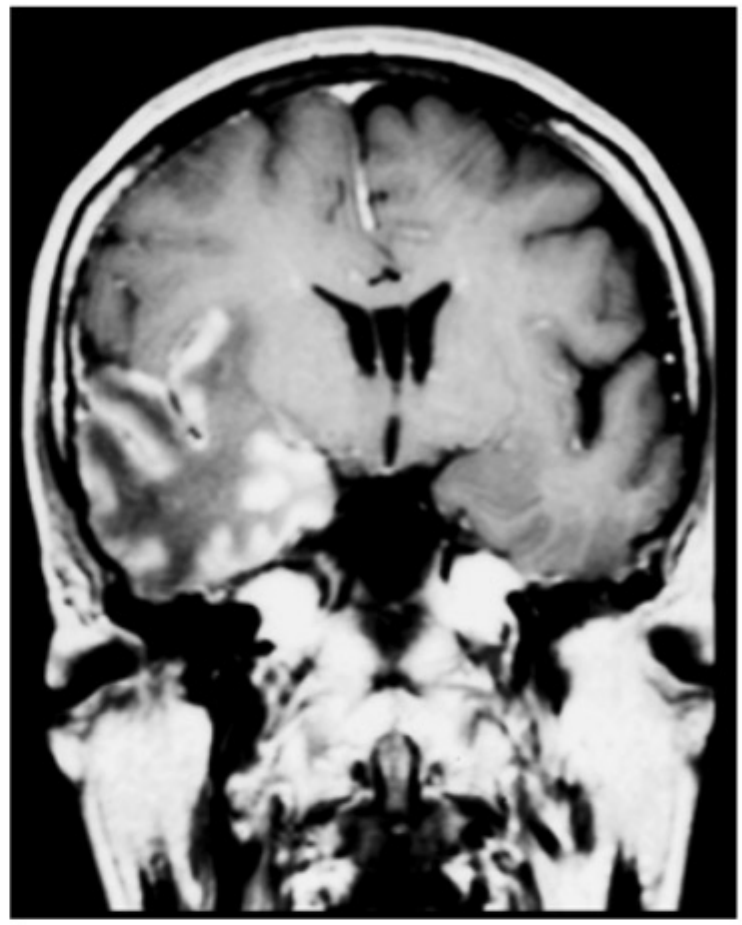

Living Art Enterprises, LLC/Science Source

▲ **Figure 20–8.3C** Type I Viral Encephalitis

8.4 Protozoal Diseases

8.4.1 *Naegleria Fowleri*

- Classic case: Teenager swimming in a pond gets a headache.
- Severe infection, penetrates sinuses into the brain; high mortality.

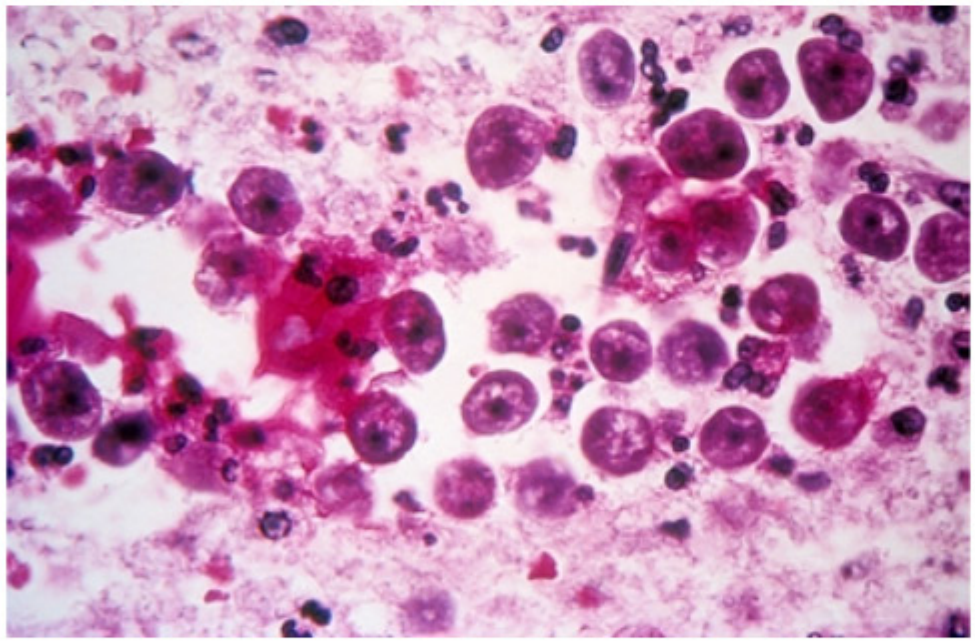

Science VU/Visuals Unlimited, Inc.

▲ **Figure 20–8.4A** *Naegleria Fowleri*

Please visit us at www.Groupinsiders.com

© DeVry/Becker Educational Development Corp. All rights reserved.

8.4.2 Cerebral Toxoplasmosis

- *Toxoplasma gondii* is one of the most common causes of neurologic symptoms and morbidity in patients with AIDS.
- CT and MRI show *multiple ring-enhancing lesions (abscesses).*
- AIDS-defining illness

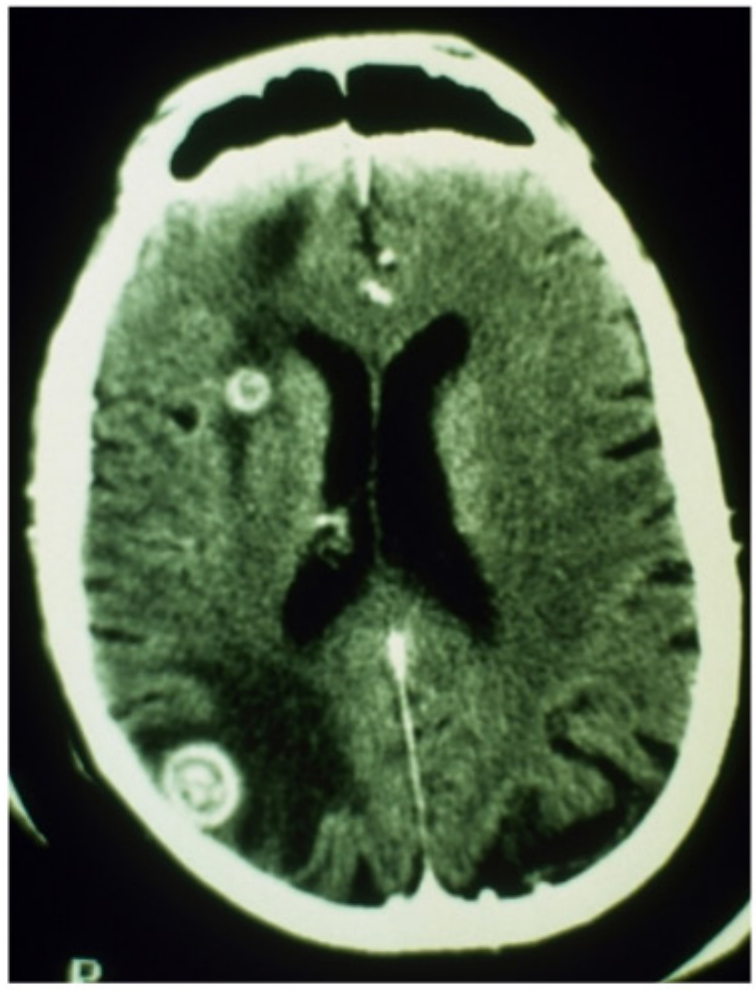

Pr. Bourree/Science Source

▲ **Figure 20–8.4B** Cerebral Toxoplasmosis

8.4.3 Transmissible Spongiform Encephalopathies

Diseases

- Creutzfeldt-Jakob disease
- Kuru
- Bovine spongiform encephalopathy
- Fatal familial insomnia
- All associated with abnormal forms of a specific protein (prion) which is infectious and transmissible.

Pathogenesis

- Misfolding of the normal prion protein (PrP^{C}) converts it to an isoform (PrP^{Sc}), which precipitates as amyloid *from a-helix to β-pleated sheet.*
- Prion protein acquires relative resistance to digestion with proteases.
- *Infectious nature comes from ability to bind and alter conformation of normal prion proteins.*
- **Prion Disease Pathology**
  - Progression of dementia usually *rapid*—for example, less than a year
  - Little macroscopic evidence of brain atrophy
  - 14-3-3 protein is elevated in the CSF

Microscopic

- Pathognomonic finding is spongiform transformation of cerebral cortex
- Microscopic vacuoles in neurons, neuronal loss, reactive gliosis

Creutzfeldt-Jakob Disease

- Rapidly progressive dementia
- Peak incidence in seventh decade
- Most cases (85%) are sporadic
- Subtle changes in memory and behavior followed by *rapidly progressive dementia with involuntary jerking muscle contractions*

Kuru

- Discovered in a cannibalistic tribe in New Guinea that ate the brains of dead relatives.

Important Concept

Ring-Enhanced Lesions:

- Brain abscess
- Toxoplasmosis
- Metastases:
  1. Lung
  2. Breast
  3. Melanoma
  4. Renal
  5. GI
- HIV-associated 1° lymphoma

Heterogenously Enhancing Lesion:

- Glioblastoma multiforme

Uniformly Enhancing Lesion:

- Lymphoma, meningioma, mets (usually ring-enhancing)

Please visit us at www.Groupinsiders.com

© DeVry/Becker Educational Development Corp. All rights reserved.

8.5 Demyelinating Diseases

- Multiple sclerosis
- Central pontine myelinolysis

8.5.1 Multiple Sclerosis

Definition: Demyelinating disorder characterized by distinct episodes of neurological defects, *separated in time*, attributable to white-matter lesions that are *separated in space*.

- Most common of the demyelinating disorders.
- Considered to be a *type IV* hypersensitivity reaction.
- Disease can become clinically apparent at any age.
- Onset in childhood or after age 50 is rare.
  (See topic 6.2, "Multiple Sclerosis.")

Clinical Course

- Relapsing and remitting flare-up episodes during variable intervals of time resulting in steady neurologic deterioration in a subset of patients.
- Environmental, genetic, and immune factors
- Risk is 15-fold higher when disease is present in first-degree relatives.
- White-matter disease
  - *Autoantibodies to myelin basic protein is common.*
- Multiple, well-circumscribed, depressed, glassy, gray-tan, irregularly shaped plaques
- Relative preservation of axons and depletion of oligodendrocytes

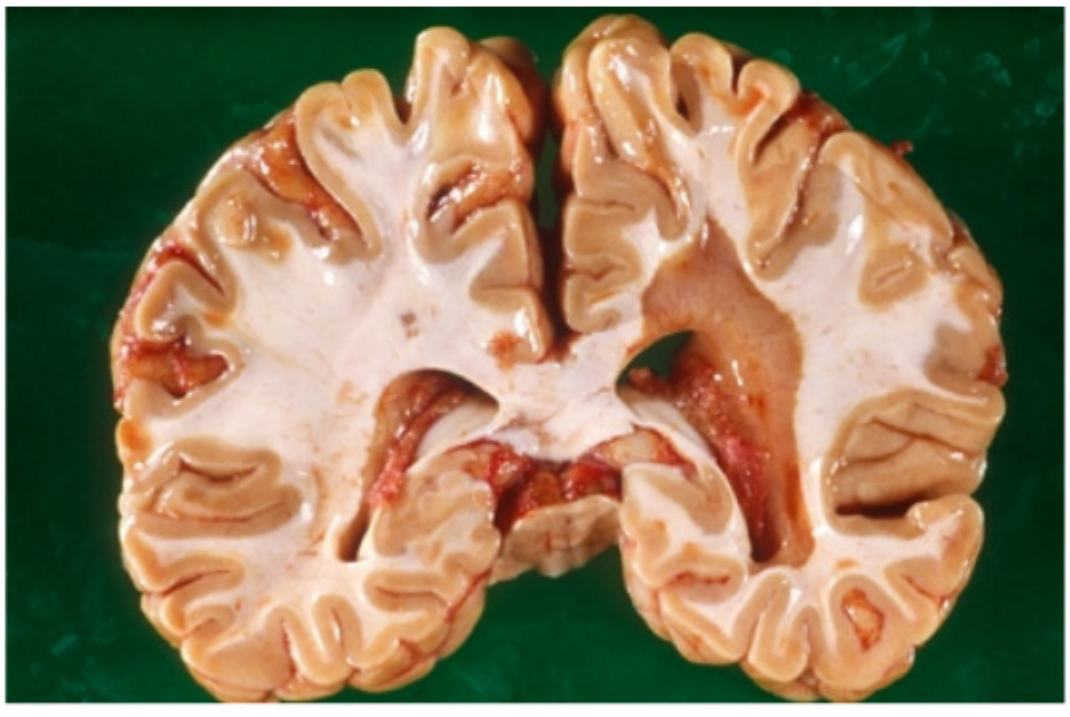

Biophoto Associates/Science Source

▲ **Figure 20–8.5A** Multiple Sclerosis: Demyelination

Please visit us at www.Groupinsiders.com

© DeVry/Becker Educational Development Corp. All rights reserved.

Clinical Features

- Unilateral visual impairment due to *optic neuritis* or retrobulbar neuritis is frequently the initial manifestation.
- Scanning speech, intention tremor, ataxia, nystagmus
- *Internuclear ophthalmoplegia* from interruption of fibers of *medial longitudinal fasciculus*
- Spinal cord lesions: spasticity and urinary incontinence (see topic 6.2, "Multiple Sclerosis.")
- Cerebrospinal fluid
  - Mildly elevated protein level
  - IgG is increased and most show *oligoclonal bands*

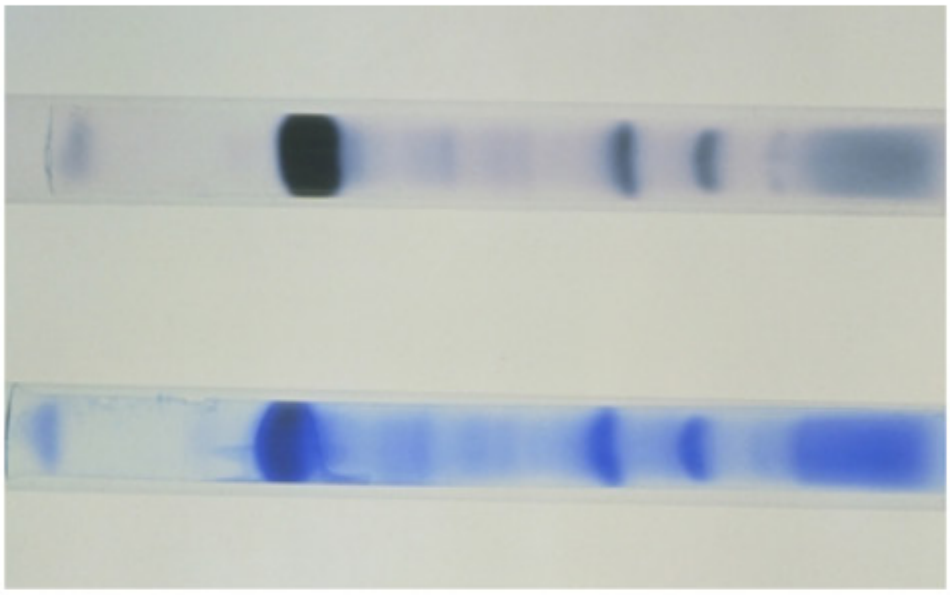

James Stevensory/Science Source

▲ **Figure 20–8.5B** Multiple Sclerosis: Oligoclonal Bands

8.5.2 Central Pontine Myelinolysis

- Loss of myelin in symmetric pattern involving pons
- Presents as rapidly evolving quadriplegia
- Occurs when saline containing IV fluids are too rapidly administered to patients for correction; also seen in patient with severe hyperosmolality without hyponatremia

See *Physiology,* chapter 3, "Membrane Potential."

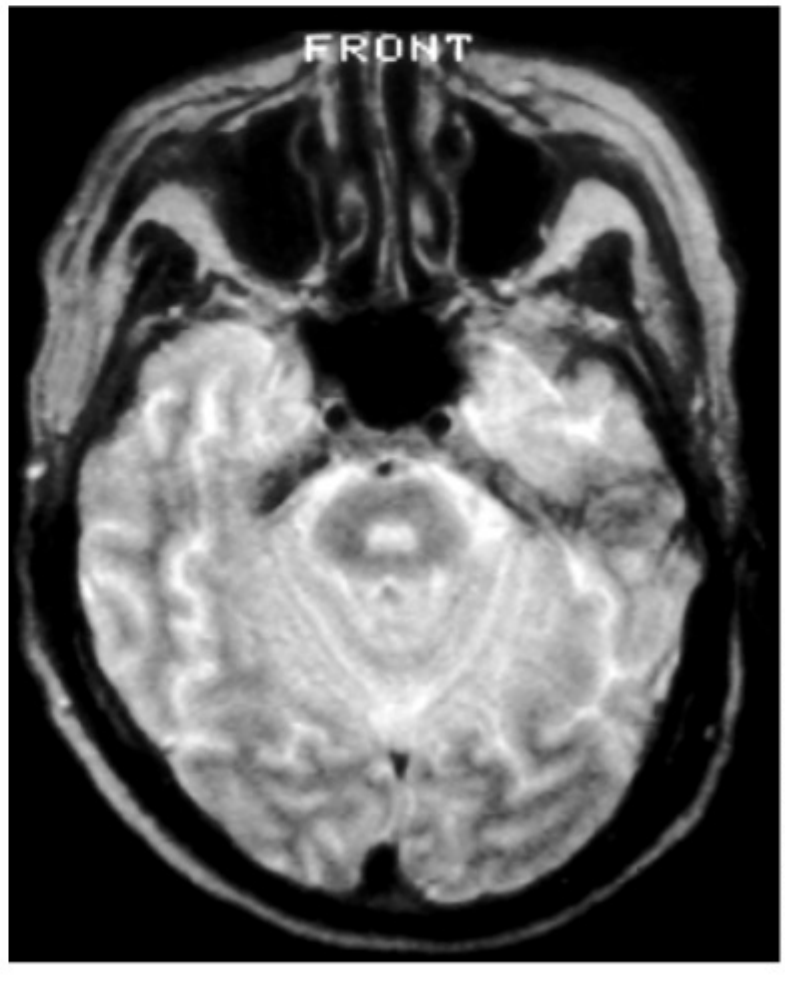

LMng Art Enterprises, LLC/Science Source

▶ **Figure 20–8.5C** Central Pontine Myelinolysis

Please visit us at www.Groupinsiders.com

© DeVry/Becker Educational Development Corp. All rights reserved.

9 Degenerative Diseases

- Alzheimer disease
- Parkinsonism
- Huntington disease
- Amyotrophic lateral sclerosis
- Frontotemporal dementia

General Characteristics

- A decrease in cognitive ability, memory, or function with intact consciousness.
- Diseases characterized by *progressive* loss of neurons associated with secondary changes in white-matter tracts.
- Pattern of neuronal loss is *selective*.
- Diseases arise without any clear inciting event.

Pathology

- Intracellular abnormalities with some degree of specificity (Lewy bodies and neurofibrillary tangles)
- Loss of affected neurons

9.1 Alzheimer Disease

- Most common cause of dementia in the elderly.
- Presents with insidious impairment of higher intellectual function.
- Mood and behavior changes
- Progressive disorientation
- Memory loss
- Aphasia

Pathology

- Gross
  - Cortical atrophy with widening of cerebral sulci
  - Compensatory ventricular enlargement secondary to loss of parenchyma (hydrocephalus ex vacuo)

Microscopic

- **Neurofibrillary Tangles:** Bundles of filaments in cytoplasm of neurons that displace or encircle nucleus.
  - Visible as basophilic fibrillary structures demonstrated by silver staining.
  - Composed of *paired helical filaments* which contain *hyperphosphorylated forms of tau* protein (axonal microtubule associated protein).
  - *Number of tangles correlate with the degree of dementia.*

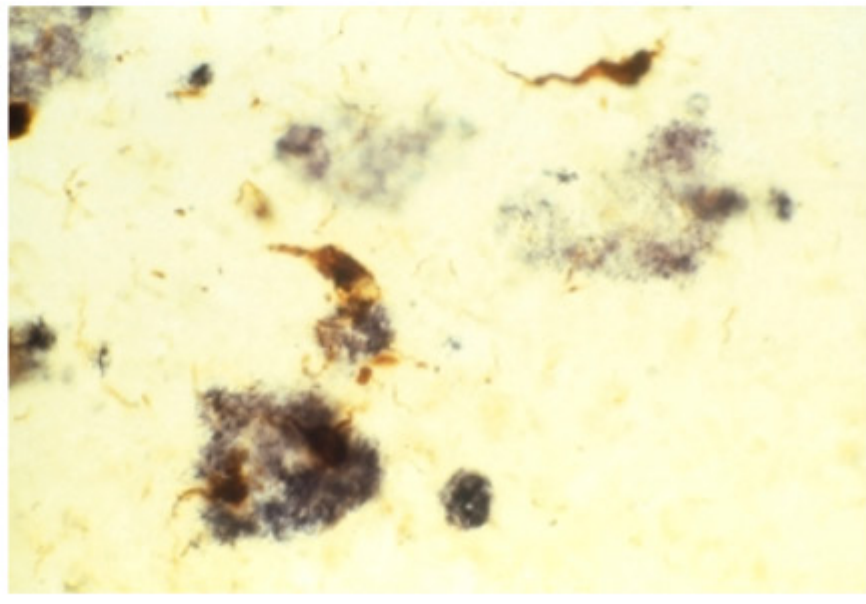

Dr. M. Goedert/Science Source

▲ **Figure 20–9.1** Cortical Neuritic Plaques

Please visit us at www.Groupinsiders.com

© DeVry/Becker Educational Development Corp. All rights reserved.

- **Senile (Neuritic) Plaques:** Extracellular β-amyloid core
  - Dominant component is extracellular β-amyloid, derived from amyloid precursor protein (APP)
  - May lead to *amyloid angiopathy*

Genetics

- Familial form (10%) associated with the following genes:
  - Amyloid precursor protein (APP) coded by chromosome 21; thus increased risk with Down syndrome and with APOE E_4
  - Early onset: APP (21), presenilin-1 (14) presenilin-2 (1)
  - Late onset: $APOE_2$ (19) is protective

Enzymes: α-, β-, γ-Secretases

- α-Secretase degrades APP
- β-, γ-Secretases produce Aβ
- Normally Wnt integrator system exists to maintain proper levels of glycogen synthase kinase (GSK). In Alzheimer disease, this maintenance is mutated, thus resulting in eternal activation of GSK and thus producing the toxic substances that are discovered in Alzheimer disease such as:
  - *Aβ*, which is a neurotoxin giving rise to *senile neuritic plaques*
  - *Hyperphosphorylates tau*, giving rise to neurofibrillary tangles

9.2 Parkinsonism

- Idiopathic Parkinson disease
  - Progressive Parkinsonism in absence of toxic or other known underlying etiology

Pathogenesis

- Degeneration of dopaminergic neurons of *substantia nigra and locus ceruleus*
- Acute Parkinsonian syndrome and destruction of neurons in substantia nigra follow exposure to *MPTP* (1-methyl-4-phenyl-1,2,3,6-tetrahydropyridine).

Pathology

- Gross
  - *Pallor of substantia nigra* and locus ceruleus
  - Not sensitive
- Microscopic
  - Loss of pigmented neurons
  - Lewy bodies: Intracytoplasmic round inclusions of alpha-synuclein

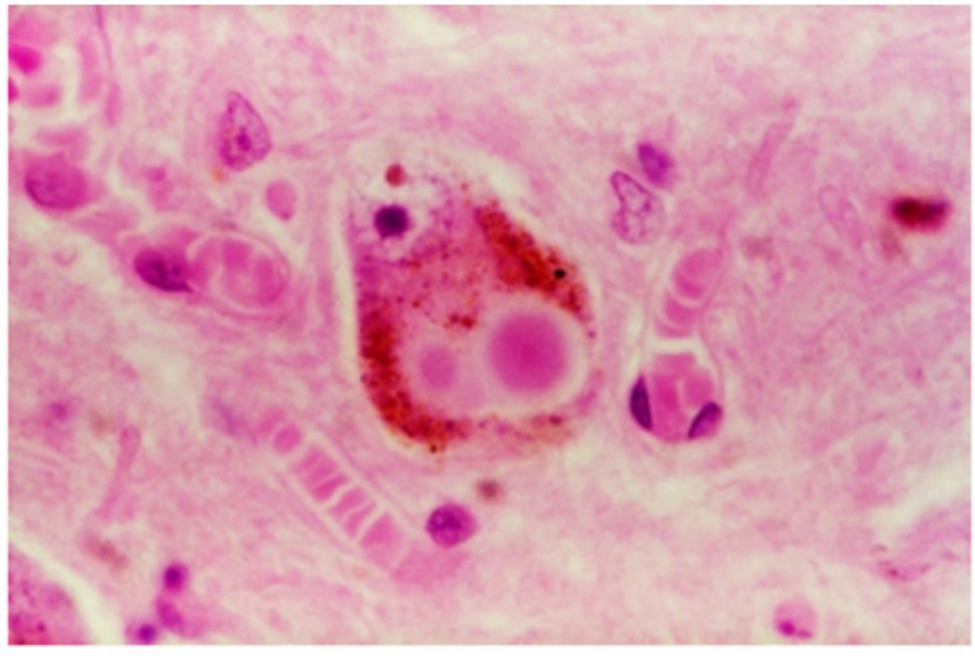

Biophoto Associates/Science Source

▶ **Figure 20–9.2** Idiopathic Parkinson Disease

Please visit us at www.Groupinsiders.com

© DeVry/Becker Educational Development Corp. All rights reserved.

Please visit us at www.Groupinsiders.com

9.3 Huntington Disease

- **Definition**: Autosomal dominant progressive movement disorder with dementia.
- **Movement disorders**:
- Chorea: Jerky movements of extremities
- Athetosis

Pathogenesis

- Huntington disease gene (chromosome 4p)
- *CAG trinucleotide repeat, which encodes polyglutamine*
- Slippage of DNA repair complex
- Protein aggregation and formation of intranuclear inclusions

Pathology

- **Gross:** Small brain with atrophy of *caudate* nucleus and *putamen*
- **Microscopic:** Severe loss of striatal neurons with *ubiquitin-positive inclusions*

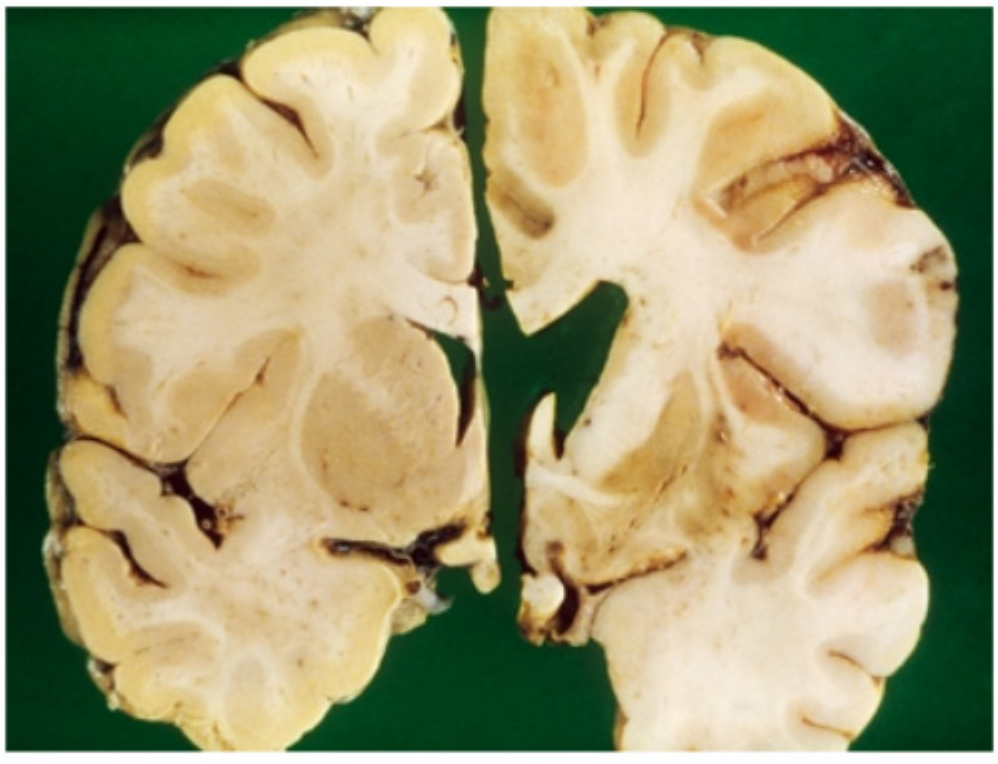

Biophoto Associates/Science Source

▲ **Figure 20–9.3** Huntington Disease

9.4 Amyotrophic Lateral Sclerosis (ALS)

Please refer to topic 6.3 for a visual depiction of ALS.

Pathogenesis

- Idiopathic
- ~5% have hereditary form
- Genetic locus is *SOD1 gene* on chromosome 21 (superoxide dismutase)

© DeVry/Becker Educational Development Corp. All rights reserved.

Clinical Features

- Early: Asymmetric weakness of hands
- Decreased muscle strength and bulk
- Fasciculations: Involuntary contractions of individual motor units
- Progressive muscular atrophy

9.5 Frontotemporal Dementia

Clinical Features

- Dementia, aphasia, Parkinsonian aspects
- Change in personality

Pathogenesis

- Spares parietal lobe and posterior two thirds of superior temporal gyrus.

Histology

- Pick bodies
  - Intracellular, aggregated *tau protein*
  - Frontotemporal atrophy

CNRI/Science Source

▲ **Figure 20–9.5** Pick Disease Frontotemporal Dementia

9.6 Metabolic Disturbances

- **Hypoglycemia**
  - Selective injury to large pyramidal neurons of cerebral cortex
  - Pseudolaminar necrosis of cortex
  - Hippocampus and cerebellum are vulnerable to hypoglycemia
- **Hyperglycemia:** Dehydration, confusion, stupor, and coma
- **Methanol:** Degeneration of retinal ganglion cells causing blindness

Please visit us at www.Groupinsiders.com

© DeVry/Becker Educational Development Corp. All rights reserved.

10 Central Nervous Tumors

10.1 Metastatic Tumors

- More common than primary tumors
  - Lung (35%)
  - Breast (20%)
  - Melanoma (10%)
  - Kidney (10%)
  - GI tract (5%)
- These tumors deposit most commonly in the gray matter-white matter junction.

10.2 Primary Tumors

- Neuroepithelial Tissue
  - Astrocytic
  - Oligodendroglial
  - Ependymal
  - Embryonal: Medulloblastoma
- Cranial/Paraspinal
  - Schwannoma
  - Neurofibroma
  - Neurofibromatoses
- Lymphomas
  - Craniopharyngioma

10.2.1 Neuroepithelial Tissue

Astrocytoma

- **I: Pilocytic astrocytoma**
  - Slow-growing, full resection usually curative
  - *Cerebellar tumors in children*
- **II: Diffuse astrocytoma**
  - Infiltrative, angulated atypical nuclei, no mitoses
  - Six- to eight-year survival
- **III: Anaplastic astrocytoma**
  - Grade II plus mitoses
  - Two-year survival
- **IV: Glioblastoma**
  - Grade III plus necrosis or microvascular proliferation
  - Unfortunately, the most common glioma
  - *Heterogenously-enhancing lesion*
  - Less than one-year survival

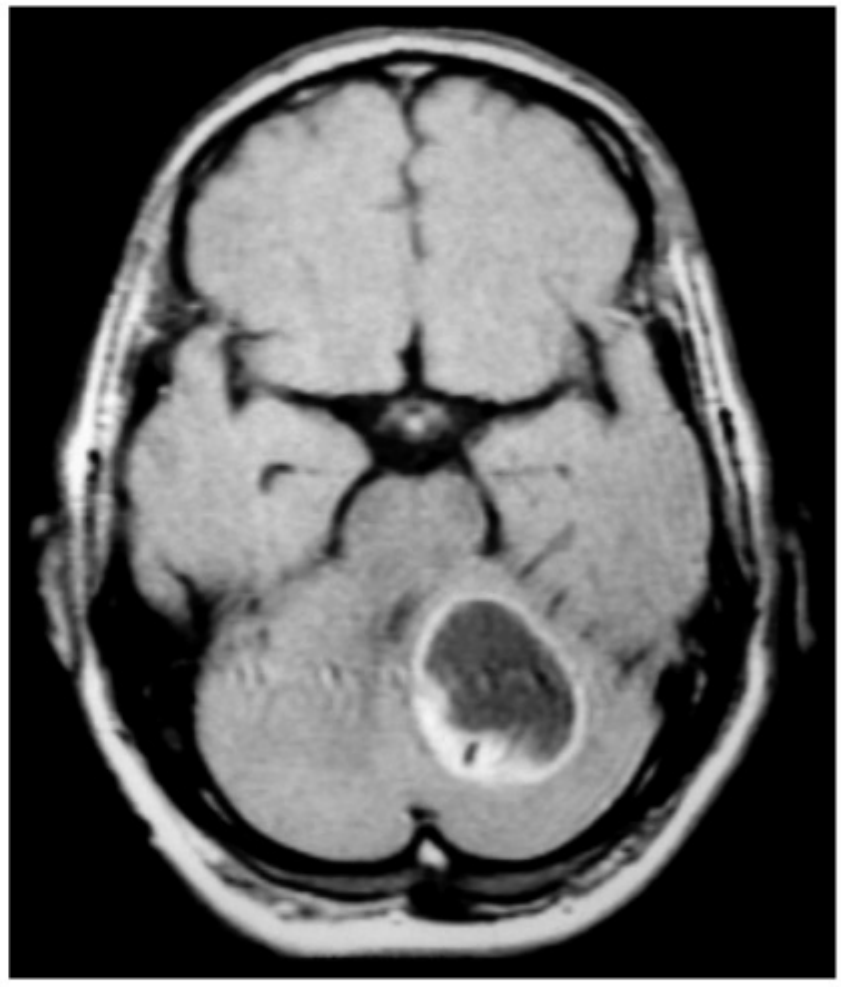

▲ **Figure 20–10.2A** Pilocytic Astrocytoma

Please visit us at www.Groupinsiders.com

© DeVry/Becker Educational Development Corp. All rights reserved.

Oligodendroglioma

- Patients have several years of neurologic complaints, including *seizures.*
- Found in cerebral hemispheres, especially *frontal lobe white matter.*
- Average survival is 10 years
- Classic genetic alteration: *1p/19q codeletion*
  - Improved response to radiation and chemotherapy
- **Oligodendroglioma Grading**
  - I: No such thing
  - **II: Standard oligodendroglioma**
    Round nuclear morphology, short processes, chickenwire vasculature, calcifications, "fried egg"

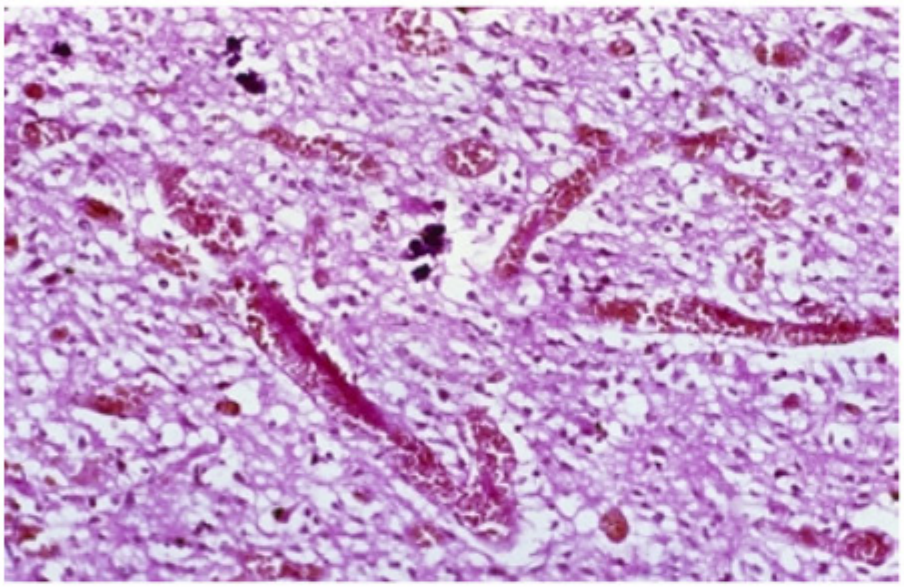

Biophoto Associates/Science Source

▲ **Figure 20–10.2B** Grade II Oligodendroglioma

Important Concept

Differentials of this CT finding:

1. Ependymoma
2. Medulloblastoma
3. Pilocytic astrocytoma

Ependymoma

Arise from ependymal cells which line the ventricles.

Clinical Features

- *Floor of fourth ventricle in children* leading to obstructive hydrocephalus
- *Filum terminale in adults*
- Recur if not completely excised
  - Full excision associated with high morbidity, especially in the fourth ventricle.

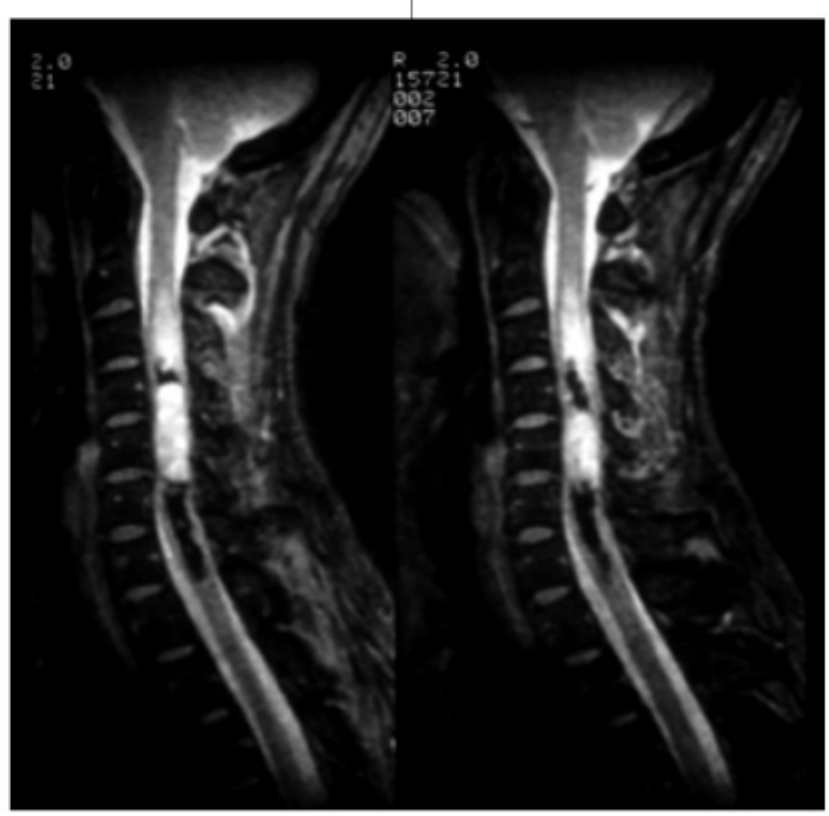

Living Art Enterprises, LLC/Science Source

▶ **Figure 20–10.2C** Ependymoma

Please visit us at www.Groupinsiders.com

© DeVry/Becker Educational Development Corp. All rights reserved.

Medulloblastoma

- 20% of brain tumors in children
- *Located in midline of cerebellum*
- *Next to roof of fourth ventricle*
- Rapid growth may occlude the outflow of cerebrospinal fluid leading to hydrocephalus
- *Dissemination into cerebrospinal fluid is a common complication*

Clinical Features

- Highly malignant tumor, but radiosensitive
- Medulloblastoma found in the midline of the cerebellum and dissemination of small blue cells into the CSF

Biophoto Associates/Science Source

▲ **Figure 20–10.2D** Medulloblastoma

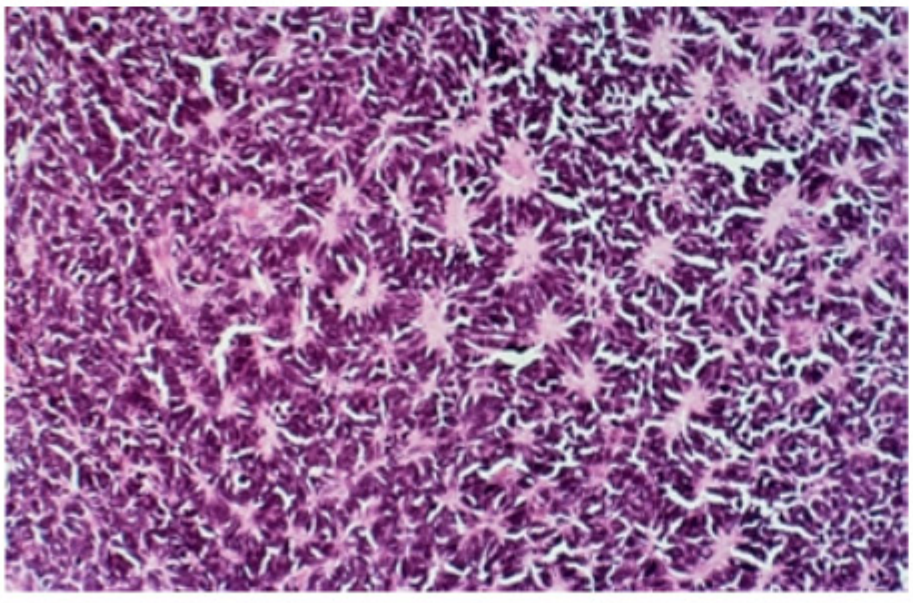

Wellcome Images

▲ **Figure 20–10.2E** Homer-Wright Rosettes

Important Concept

High-yield differentials for "Rosettes" of various types:

1. **Homer-Wright Rosettes**
   A halo of tumor cells surrounding a central region containing neuropil found with medulloblastomas and neuroblastomas.
2. **Flexner-Wintersteiner Rosettes**
   Tumor cells surrounding a central lumen that contains cytoplasmic extensions of photoreceptors from the tumor cells found in retinoblastoma.
3. **Ependymoma Rosettes**
   Found with well-differentiated ependymomas where these rosettes are attempting to create a central ventricle.
4. **Perivascular Pseudorosettes**
   Found with a number of CNS malignancies. "Pseudo" refers to the fact that the central region is not an extension of the tumor.

Please visit us at www.Groupinsiders.com

© DeVry/Becker Educational Development Corp. All rights reserved.

Meningioma

Predominantly a benign tumor that arises from meningothelial cells of the arachnoid

Pathogenesis

- Female dominance
- Rounded masses with *well-defined dural base* that compress underlying brain
- Commonly located in parasagittal and olfactory groove

Clinical Features

Slow-growing, benign tumor usually must become large before producing symptoms of new onset focal seizures.

Important Concept

Meningioma only becomes symptomatic when the tumor is a large enough space-occupying lesion compressing on cerebral structures as shown in Figure 20–10.2G.

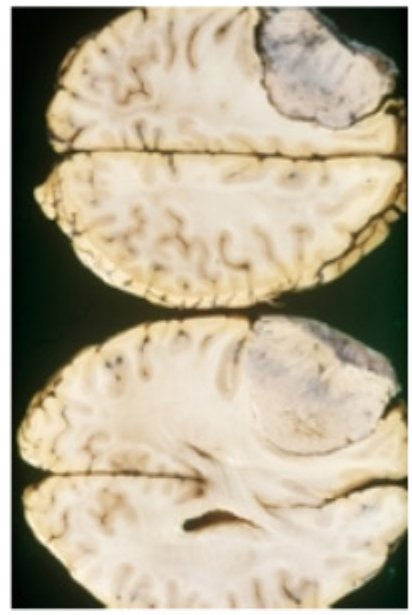

Biophoto Associates/Science Source

▲ **Figure 20–10.2G** Meningioma

10.2.2 Cranial/Paraspinal

Schwannoma

Arise from Schwann cells

- Sporadic
- *If bilateral = neurofibromatosis type 2*
- Most common location is at *cerebellopontine angle at eighth nerve*.
- Often present with tinnitus and hearing loss.

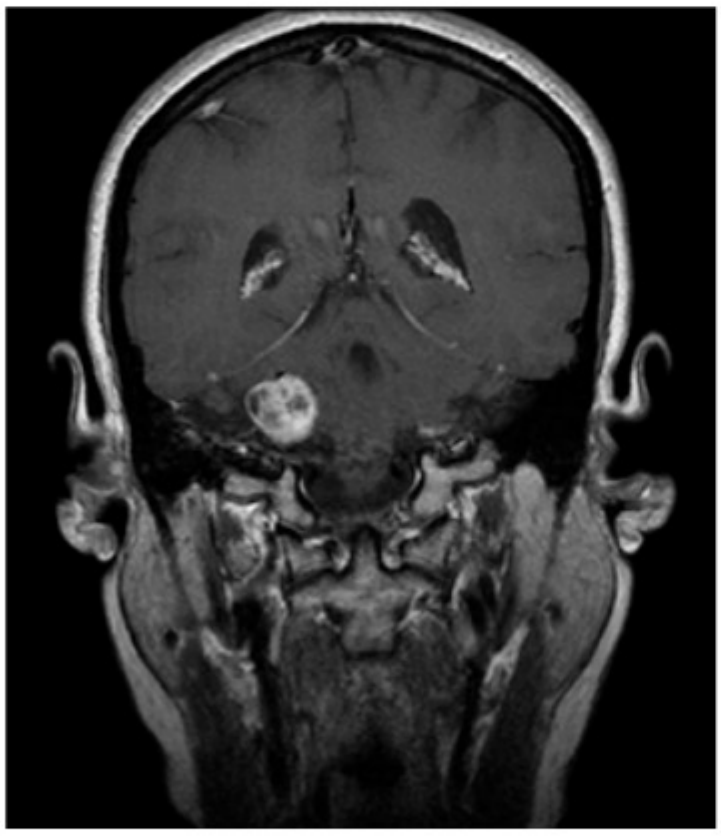

PDSN/Phototake, Inc.

▲ **Figure 20–10.2F** Schwannoma

Neurofibroma

- Common forms
  - Cutaneous neurofibroma
  - Solitary neurofibroma
  - *Plexiform neurofibroma*
- Assocated with progression to MPNST (**m**alignant **p**eripheral **n**erve **s**heath **t**umor)

Please visit us at www.Groupinsiders.com

© DeVry/Becker Educational Development Corp. All rights reserved.

- Arise sporadically or in association with *neurofibromatosis type 1*
- Skin lesions present as nodules with overlying hyperpigmentation
- Well-delineated but unencapsulated masses composed of spindle cells
- Either schwannomas or neurofibromas can progress to a **m**alignant **p**eripheral **n**erve **s**heath **t**umor.

Neurofibromatoses

- **Neurofibromatosis type 1**
  - Autosomal dominant
  - Neurofibromas, pheochromocytoma, Wilms, juvenile CML
  - Pigmented nodules of iris (Lisch nodules)
  - Pigmented plexiform neurofibroma
  - Café au lait spots
  - Chromosome *17q11*—encodes *neurofibromin* protein, which plays a role in signal transduction
  - Mild scoliosis
- **Neurofibromatosis type 2**
  - Autosomal dominant
  - Bilateral acoustic schwannomas and multiple meningiomas
  - Café au lait spots
  - Gliomas (ependymomas of spinal cord)
  - Chromosome *22q12*—encodes *merlin*, which has a structure similar to cytoskeletal proteins

10.2.3 Lymphomas

Craniopharyngioma

- Suprasellar cystic lesion
- Causes visual disturbances
- **"Motor oil"** cyst fluid
- Cholesterol and blood
- Recurs if incompletely excised

ISM/Phototake, Inc.

◀ **Figure 20–10.2H**
Crantopharyngioma

Important Concept

Differentials for the involvement of the iris:

1. Lisch nodules found with neurofibromatosis type I
2. Kayser-Fleischer rings with Wilson disease
3. Brushfield spots with Down syndrome
4. Aniridia with the WAGR syndrome

Please visit us at www.Groupinsiders.com

© DeVry/Becker Educational Development Corp. All rights reserved.

Please visit us at www.Groupinsiders.com

CHAPTER 21 Peripheral Nervous System Pathology

1 Inflammatory Neuropathy

- Any nerve disease characterized by inflammation of peripheral nerves, peripheral nerve roots, or autonomic ganglia.
- Sensory changes with usual segmental demyelination leading to paresthesias, which is often referred to as "glove and stocking" distribution of changes.
- Axon degeneration of the motor pathway leads to muscle fasciculations and atrophy.

1.1 Guillain-Barré Syndrome (*Acute* Inflammatory Demyelinating Polyradiculoneuropathy, or AIDP)

- Incidence: 1–3 per 100,000

Pathogenesis

- *T cell mediated autoimmune response*
- Segmental demyelination of peripheral nerves

Pathology

- Lymphocytic inflammation of peripheral nerve
  - Nearly impossible to see on biopsy
- Remyelination follows

Clinical Features

- Usually preceded by infections such as *mycoplasma pneumonia*, *Campylobacter jejuni* enteritis, influenza, or viral infections.
- Presents with ascending paralysis: Weakness beginning in distal extremities and progressing proximally; usually with loss of deep tendon reflexes.
- Patient runs the risk of respiratory muscle paralysis leading to death.
- CSF albumin-cytologic dissociation (protein highly elevated but cells normal).

USMLE® Key Concepts

For Step 1, you must be able to:

- Identify inflammatory neuropathies such as Guillain-Barré syndrome.
- Identify hereditary neuropathies such as Charcot-Marie-Tooth disease.
- Refer to Microbiology for infectious types of neuropathies.

Connection to Microbiology

See *Microbiology*, chapter 4, "Virology," for infectious neuropathy, including:

- Leprosy.
- Diphtheria, a toxin-mediated peripheral nerve disease.
- Varicella-zoster is a condition of the peripheral nerve caused by reactivation of latent varicella-zoster manifesting as pain in the dermatomes known as shingles or herpes-zoster.

Please visit us at www.Groupinsiders.com

© DeVry/Becker Educational Development Corp. All rights reserved.

2 Hereditary Neuropathy

Definition: Inherited peripheral nerve diseases.

- **Multiple Types**
  - Hereditary Motor and Sensory Neuropathy
    - HMSN I: *Charcot-Marie-Tooth disease*
    - HMSN III: *Dejerine-Sottas disease*
  - Hereditary Sensory and Autonomic Neuropathy
    - HSAN III: *Riley-Day syndrome*

2.1 Charcot-Marie-Tooth Disease

- Most common inherited neuropathy.
  - Autosomal dominant
- Heterogeneous genetic defects, but most cases have a duplicated segment and "segmental trisomy" of chromosome 17p11.2-p12, which encodes for *myelin protein 22.*

Pathology

- Repetitive demyelination and remyelination
- Multiple onion bulbs on distal peripheral nerves

Y. Ali/Wellcome Images

▲ **Figure 21–2.1A** Demyelination/Remyelination

Please visit us at www.Groupinsiders.com

© DeVry/Becker Educational Development Corp. All rights reserved.

Clinical Features

- Peroneal muscular atrophy: *Progressive atrophy of calf*
- *Combined sensory and motor* deficits
- Orthopedic problems: *Pes cavus*

Science Source

▲ **Figure 21–2.1B** Pes Cavus

Please visit us at www.Groupinsiders.com

© DeVry/Becker Educational Development Corp. All rights reserved.

Please visit us at www.Groupinsiders.com

1 Anatomy of the Eye

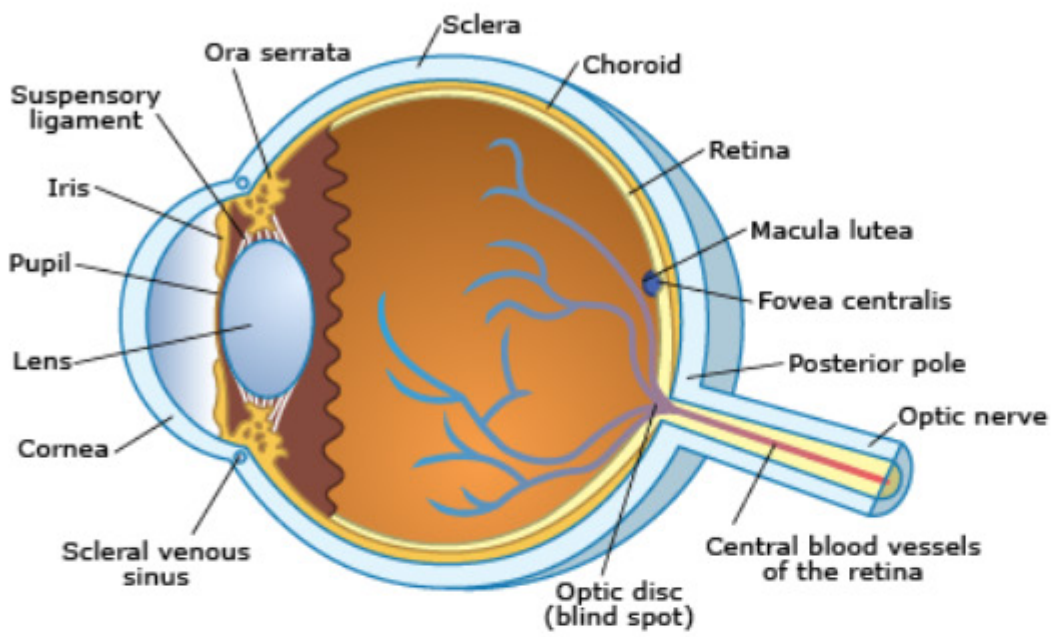

▲ **Figure 22–1.0** Anatomy of the Eye

USMLE® Key Concepts

For Step 1, you must be able to:

- Identify congenital eye disorders.
- Identify eyelid, conjunctival, uveal, and retinal disorders.
- Diagnose ocular melanoma.
- Differentiate between closed-angle and open-angle glaucoma.

Please visit us at www.Groupinsiders.com

© DeVry/Becker Educational Development Corp. All rights reserved.

2 Congenital Abnormalities

2.1 Trisomy 13 (Patau Syndrome)

- *Microphthalmos*: Small eyes

2.2 Trisomy 21 (Down Syndrome)

- *Hypertelorism*: Eyes set abnormally apart
  - *Brushfield spots*
    - —Stromal hyperplasia surrounded by hypoplasia. Normal in children, but frequently found in children with Down syndrome.

Lauren Shear/Science Source

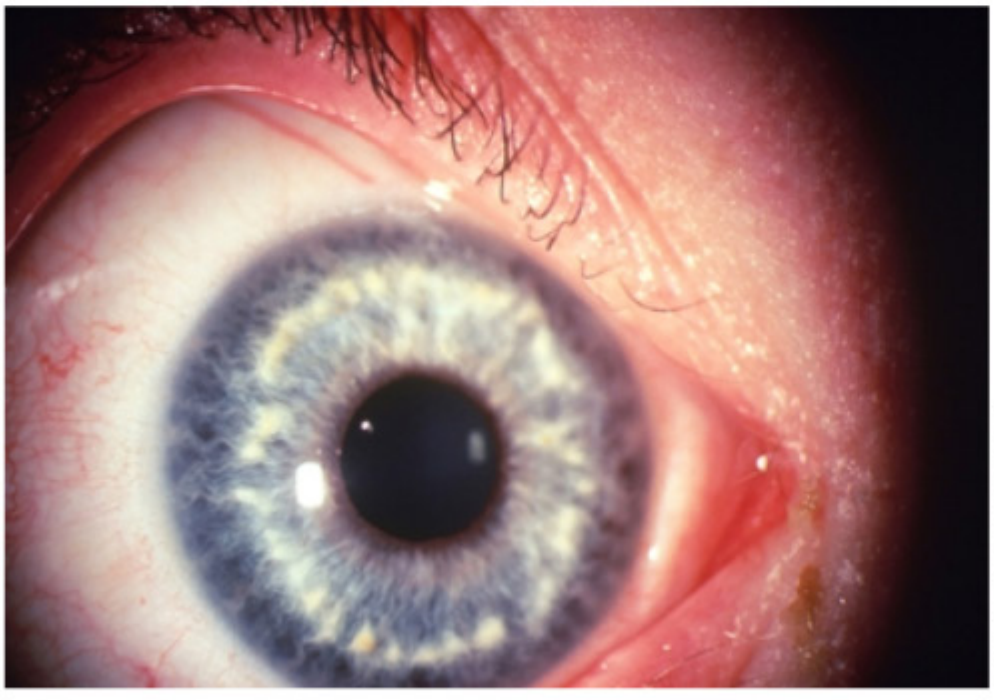

Ralph C. Eagle, Jr./Science Source

▲ **Figure 22–2.2** Congenital Abnormalities

Please visit us at www.Groupinsiders.com

© DeVry/Becker Educational Development Corp. All rights reserved.

3 Eyelid Disorders

3.1 Stye

- Infection of eyelid
- Most commonly due to *S. aureus*

3.2 Chalazion

- Granulomatous inflammation involving the meibomian gland in the eyelid
- Usually disappear on their own within two months

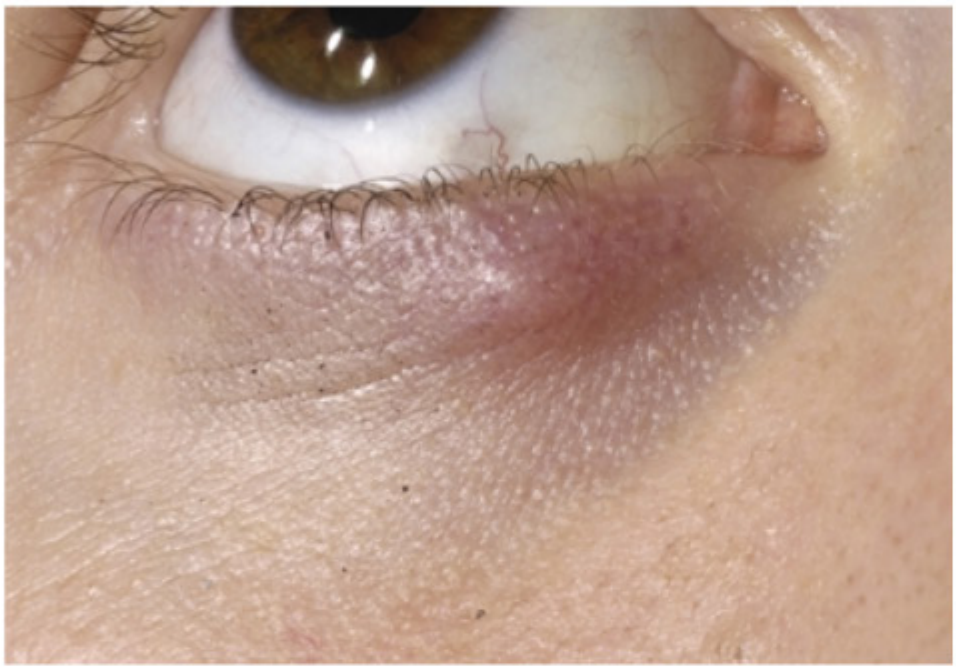

Dr. P. Marazzi/Science Source

▲ **Figure 22–3.2** Chalazion

Please visit us at www.Groupinsiders.com

© DeVry/Becker Educational Development Corp. All rights reserved.

4 Conjunctival Disorders

4.1 Bacterial Conjunctivitis

4.1.1 Purulent Conjunctivitis

- Pain without blurry vision
- Contagious

Pathogens

- *Staphylococcus aureus* (most common)
- *Streptococcus pneumoniae*
- *Haemophilus influenzae* (*H. aegyptius*, pink eye)

4.2 Viral Conjunctivitis

- Adenovirus: Most common
- Herpes simplex
- May include preauricular adenopathy

4.3 Allergic Conjunctivitis

- Intense itching/burning
- Serous (watery) discharge
- *Not* contagious

Biophoto Associates/Science Source

Dr. Allan Harris/Phototake, Inc.

▲ **Figure 22–4.3** Bacterial, Viral, Allergic Conjunctivitis

Please visit us at www.Groupinsiders.com

© DeVry/Becker Educational Development Corp. All rights reserved.

4.4 Pterygium

- Benign superficial growth that usually forms over the perilimbal conjunctiva and extends onto the corneal surface.
- Vary in size from small to large; aggressive, rapidly growing lesions.
- Risk factors for pterygium include: Increased exposure to ultraviolet light, especially living in subtropical and tropical climates.

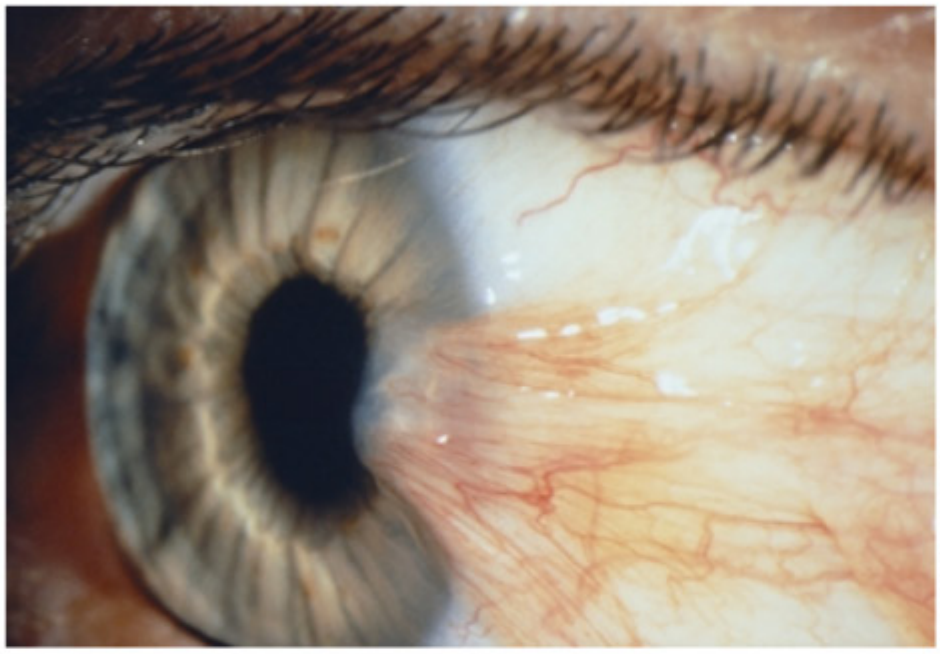

Paul Parker/Science Source

▲ **Figure 22–4.4** Pterygium

Please visit us at www.Groupinsiders.com

© DeVry/Becker Educational Development Corp. All rights reserved.

5 Disorders of the Uvea

- Vascular coat that includes choroid, ciliary body, and iris.
- Inflammation can be *granulomatous* or *nongranulomatous.*

▼ **Table 22–5.0** Granulomatous vs. Nongranulomatous Uveitis

Granulomatous Uveitis	Nongranulomatous Uveitis
Tuberculosis Leprosy Syphilis Tularemia CMV HSV Blastomycosis Cryptococcosis Coccidioidomycosis Aspergillosis Histoplasmosis Toxoplasmosis Sarcoid	Idiopathic causes Diseases associated with HLA-B27: • Ankylosing spondylitis • Reactive arthritis • Inflammatory bowel disease • Psoriasis Infections: • Herpes zoster and/or herpes simplex • Syphilis • Lyme disease • Juvenile idiopathic arthritis • Fuchs heterochromic iridocyclitis

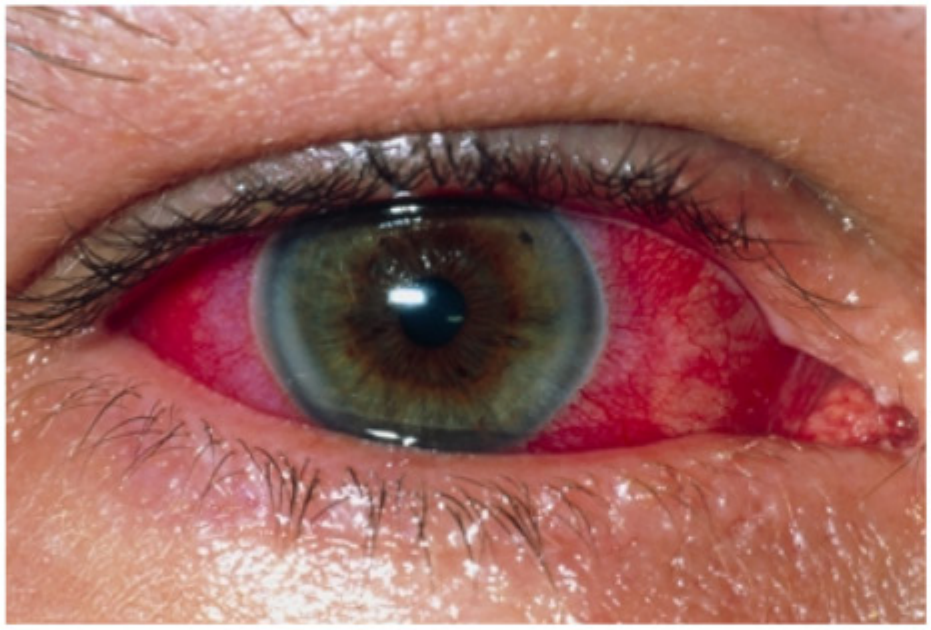

Dr. P. Marazzi/Science Source

▲ **Figure 22–5.0** Uveitis

Please visit us at www.Groupinsiders.com

© DeVry/Becker Educational Development Corp. All rights reserved.

6 Retinal Disorders

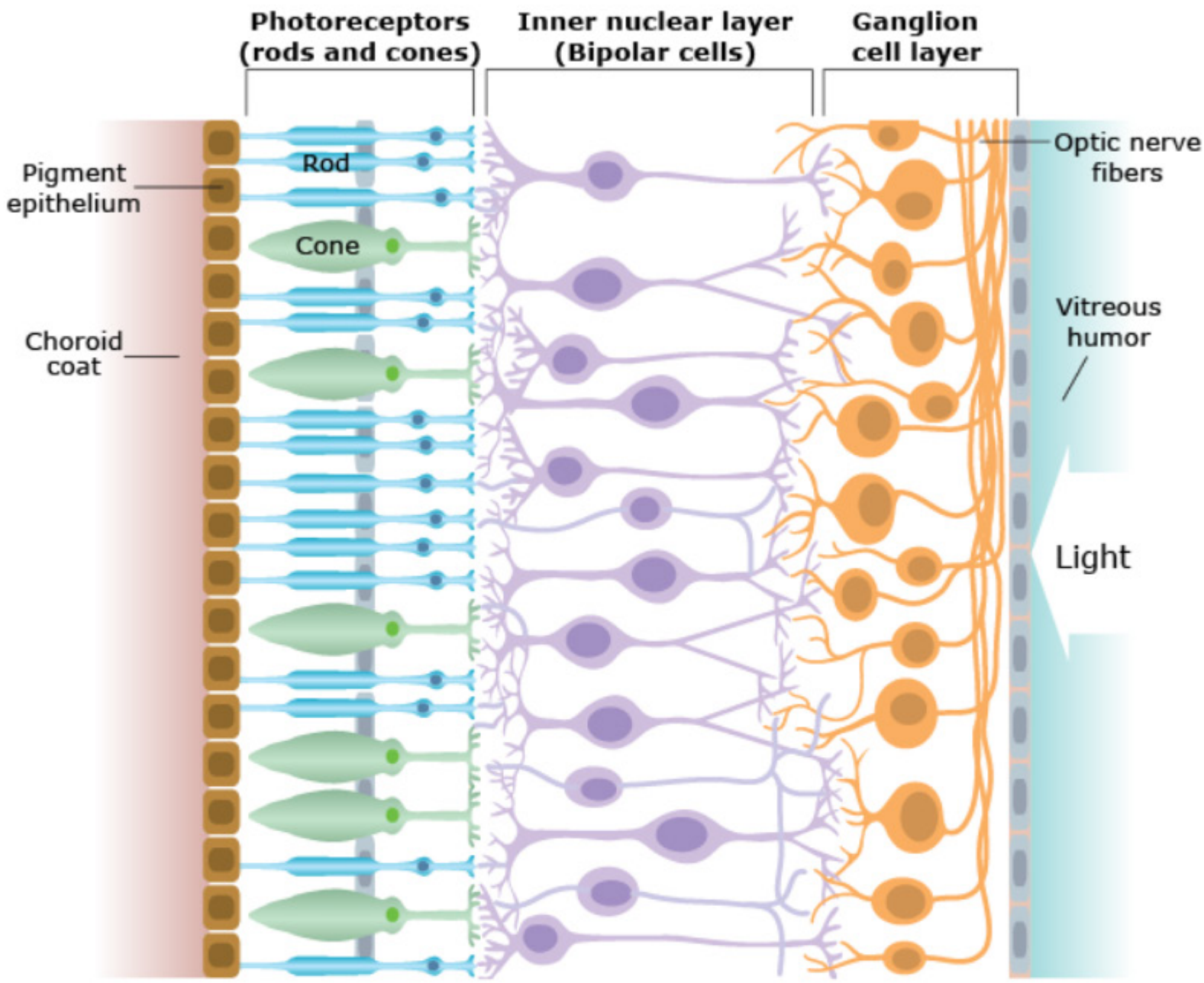

▲ **Figure 22–6.0** Normal Retina

6.1 Retinopathy of Prematurity

- Leading cause of blindness in infants.
- Occurs in premature infants who have been subject to oxygen therapy (51% if <1700 g).

Pathogenesis Vascular proliferation that breaks through the internal limiting membrane and turns into vitreous by VEGF-mediated.

Please visit us at www.Groupinsiders.com

© DeVry/Becker Educational Development Corp. All rights reserved.

6.2 Hypertensive Retinopathy

- Hypertension results in narrowing and decrease in diameter of vessels.
- Histologically, this manifests as hyaline or onion-skin thickening.
- Modified Scheie Grades:
  - Grade 0: No changes
  - Grade 1: Barely detectable arterial narrowing
  - Grade 2: Obvious arterial narrowing with focal irregularities
  - Grade 3: Grade 2 plus retinal hemorrhages and/or exudates
  - Grade 4: Grade 3 plus disc swelling

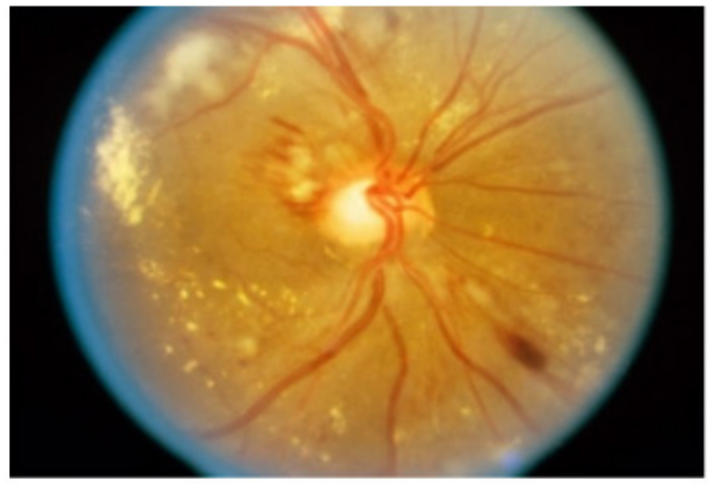

Ralphs C. Eagle, Jr./Science Source

▲ **Figure 22–6.2A** Hypertensive Retinopathy

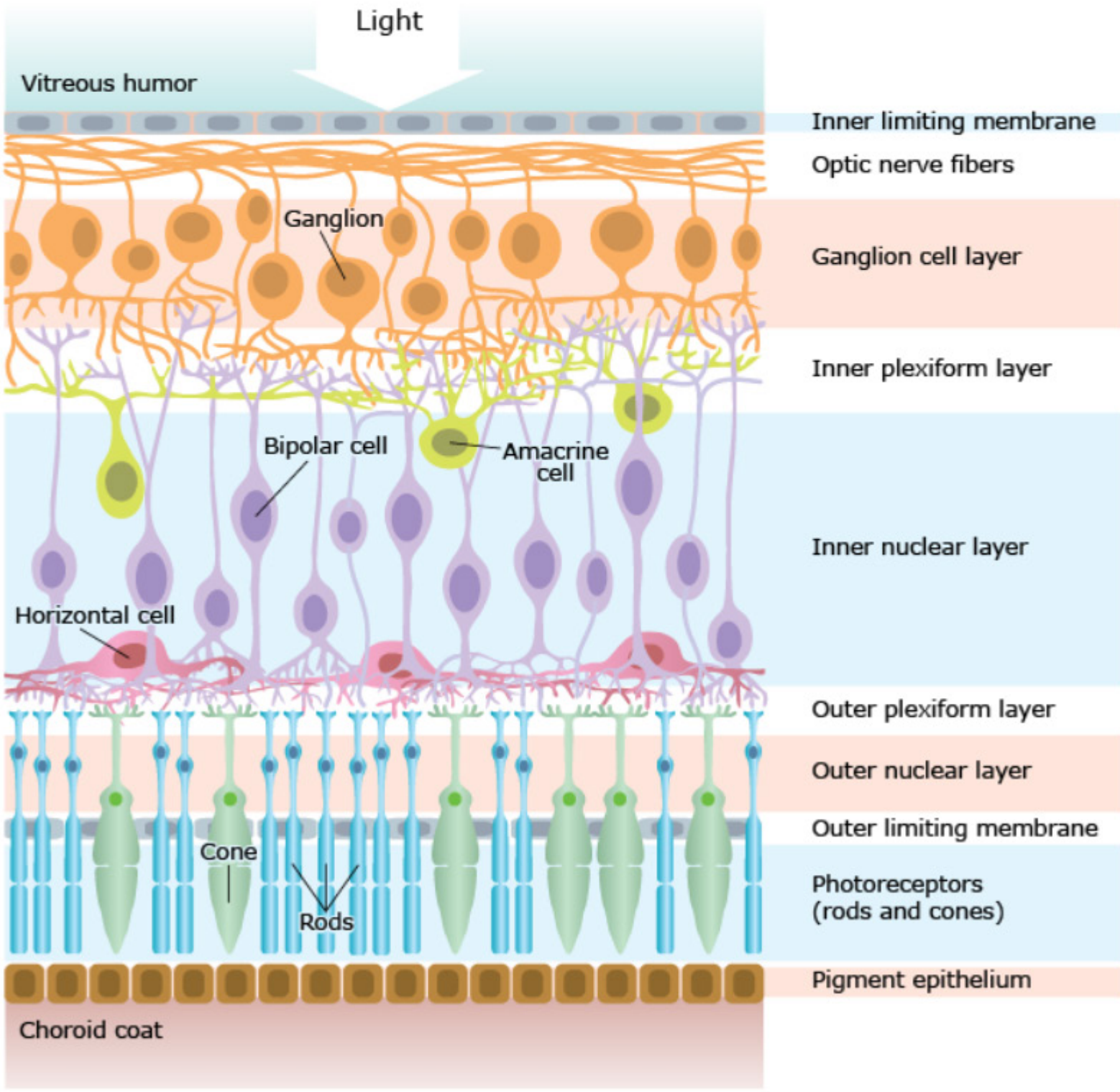

▲ **Figure 22–6.2B** Hypertensive Retinopathy

Please visit us at www.Groupinsiders.com

© DeVry/Becker Educational Development Corp. All rights reserved.

6.2.1 Central Retinal Artery Occlusion

- Sudden, painless, complete loss of vision in one eye
- Pallor of optic disc due to narrowed arteries

Pathogenesis

- Embolization of carotid or ophthalmic artery plaque
- Giant cell temporal arteritis

6.2.2 Central Retinal Vein Occlusion

Sudden, painless, unilateral loss of vision, swelling of optic disc, engorged retinal veins with hemorrhage ("blood and thunder" appearance).

Please visit us at www.Groupinsiders.com

© DeVry/Becker Educational Development Corp. All rights reserved.

7 Macular Degeneration

- Most common cause of irreversible blindness
- **Dry** (aka *nonexudative*) **Macular Degeneration**
  - 90% of all cases
  - Yellow-white deposits (*drusen*) in the retinal pigment epithelium (RPE) tissue beneath the macula
  - Waste products from photoreceptor cells
- **Wet** (*exudative*) **Macular Degeneration**
  - 10% of cases
  - Abnormal blood vessel growth beneath the macula
  - Leak blood and fluid
  - Rapid progression

Please visit us at www.Groupinsiders.com

© DeVry/Becker Educational Development Corp. All rights reserved.

8 Ocular Melanoma

- Can develop on conjunctiva or uvea.
- Most common cause of primary intraocular neoplasm.
  - The most common neoplasm overall is metastasis.
  - Number one melanoma metastatic target: *Liver*.
  - Only hematogenous route exists in eye; no lymphatics.

Dr. M.A. Ansary/Science Source

▲ **Figure 22–8.0** Ocular Melanoma

Memory Aid

Reminder: The most common neoplasm overall is **metastasis** and the No. 1 melanoma metastatic target is the **liver**.

Please visit us at www.Groupinsiders.com

© DeVry/Becker Educational Development Corp. All rights reserved.

9 Glaucoma

- Increased pressure within the eyeball due to lack of drainage of aqueous humor.
- Usually drained by ducts in the vicinity of the iris.
- With thickening of the lens (for example, with age) the canal of Schlemm can be compressed, leading to lack of fluid drainage.
- High pressure damages optic disc.

9.1 Open Angle Glaucoma

Pathogenesis

- Chronic
- Decreased rate of aqueous outflow into the canal of Schlemm
  - Bilateral aching eyes
  - Pathologic cupping of optic discs
  - Night blindness
  - Gradual loss of peripheral vision leading to tunnel vision and blindness

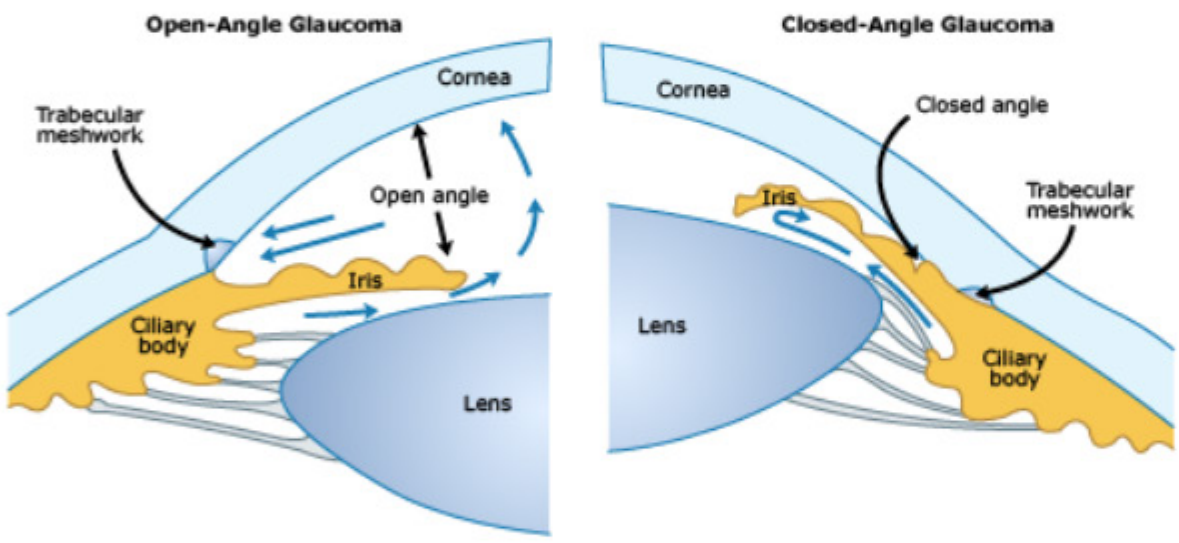

▲ **Figure 22–9.1** Ocular Glaucoma

9.2 Closed-Angle Glaucoma

Pathogenesis

- Acute loss of vision—medical emergency!
- Narrowing of anterior chamber angle

Clinical

- Severe pain
- Photophobia
- Blurry vision
- Red eye with a steamy cornea
  - Pupil fixed and nonreactive to light

Connection to Pharmacology

See *Pharmacology*, chapter 2, "Autonomic Pharmacology," for more on treatment for glaucoma.

Please visit us at www.Groupinsiders.com

© DeVry/Becker Educational Development Corp. All rights reserved.

Unit 11

Musculoskeleton and Connective Tissue Disorders

Please visit us at www.Groupinsiders.com

Please visit us at www.Groupinsiders.com

1 Types of Connective Tissue Disorders

1.1 Genetic Disorders of Collagen Synthesis

1.1.1 Ehlers-Danlos Syndrome

- Defect in fibrillar *collagen synthesis (commonly type I or type III)* or *collagen structure.*
- Ten variants with different modes of inheritance.
- Clinical manifestations:
  - Skin is hyperextensible, fragile, and vulnerable to trauma
  - Joints are hypermobile
  - Aortic dissection is the most common cause of death
  - Ecchymoses
  - Poor wound healing

Dr. Ken Greer/Visuals Unlimited, Inc.

▲ **Figure 23–1.1** Ehlers-Danlos Syndrome

- **Vascular Type (Most Common)**:
  - Defect in type III collagen (COL3A gene).
  - Hyperextensible skin, hypermobile joints; associated with berry aneurysms.
- **Classical Type:** Defect in type V collagen (COL5A gene).
- **Kyphoscoliosis**: Lack of lysyl hydroxylase.
- **Arthrochalasia and Dermatosparaxis Types**: Defect in conversion of type I procollagen to collagen (COL1A gene).

USMLE® Key Concepts

For Step 1, you must be able to:

- Explain the molecular basis of disease for Ehlers-Danlos syndrome, Alport syndrome, and benign familial hematuria.
- Explain the mechanism of disease and mode of inheritance of Marfan syndrome.
- Identify keloid formation and explain its mechanism.

Please visit us at www.Groupinsiders.com

© DeVry/Becker Educational Development Corp. All rights reserved.

1.1.2 Alport Syndrome

- *X-linked* mutation in the α5 chain *of type IV collagen* (COL4A5).
- Results in thinning and *splitting of the basement membranes*.
- Clinically presents with isolated hematuria that progresses to *renal failure, nerve deafness, and eye disorders*.

1.1.3 Benign Familial Hematuria

- Defective *type IV collagen* formation results in familial asymptomatic hematuria.
- EM shows diffuse *thinning of the glomerular basement membranes*.

1.2 Defects of Wound Healing

1.2.1 Keloid

- Excess production of type III collagen.
- Genetic predisposition, more common in *African-Americans*.
- Tends to affect earlobes, fat, neck, sternum, and forearms.
- May produce large, tumor-like scars.

JPD/Custom Medical Stock Photo

▲ **Figure 23–1.2** Keloid

Please visit us at www.Groupinsiders.com

© DeVry/Becker Educational Development Corp. All rights reserved.

1.3 Defects of Elastin Synthesis

1.3.1 Marfan Syndrome

- *Autosomal dominant* defect in *fibrillin*-1 gene.
- Results in abnormal *elastic fibers in extracellular matrix*.
  - Skeletal abnormalities
  - *Dislocation of the lens*
  - Cardiovascular lesions
    - — Dilation of ascending aorta due to cystic medial necrosis (increased risk of *aortic dissection*).

Bart's Medical Library/Phototake, Inc.

▲ **Figure 23–1.3A** Marfan Syndrome

Connection to Biochemistry

Ascorbic acid functions in a number of biosynthetic pathways, including the activation of prolyl and lysyl hydroxylases to hydroxylate procollagen. Deficiency of vitamin C, or scurvy, therefore, leads to impaired wound healing, poor blood vessel support with bleeding, and inadequate synthesis of osteoid.

Please visit us at www.Groupinsiders.com

© DeVry/Becker Educational Development Corp. All rights reserved.

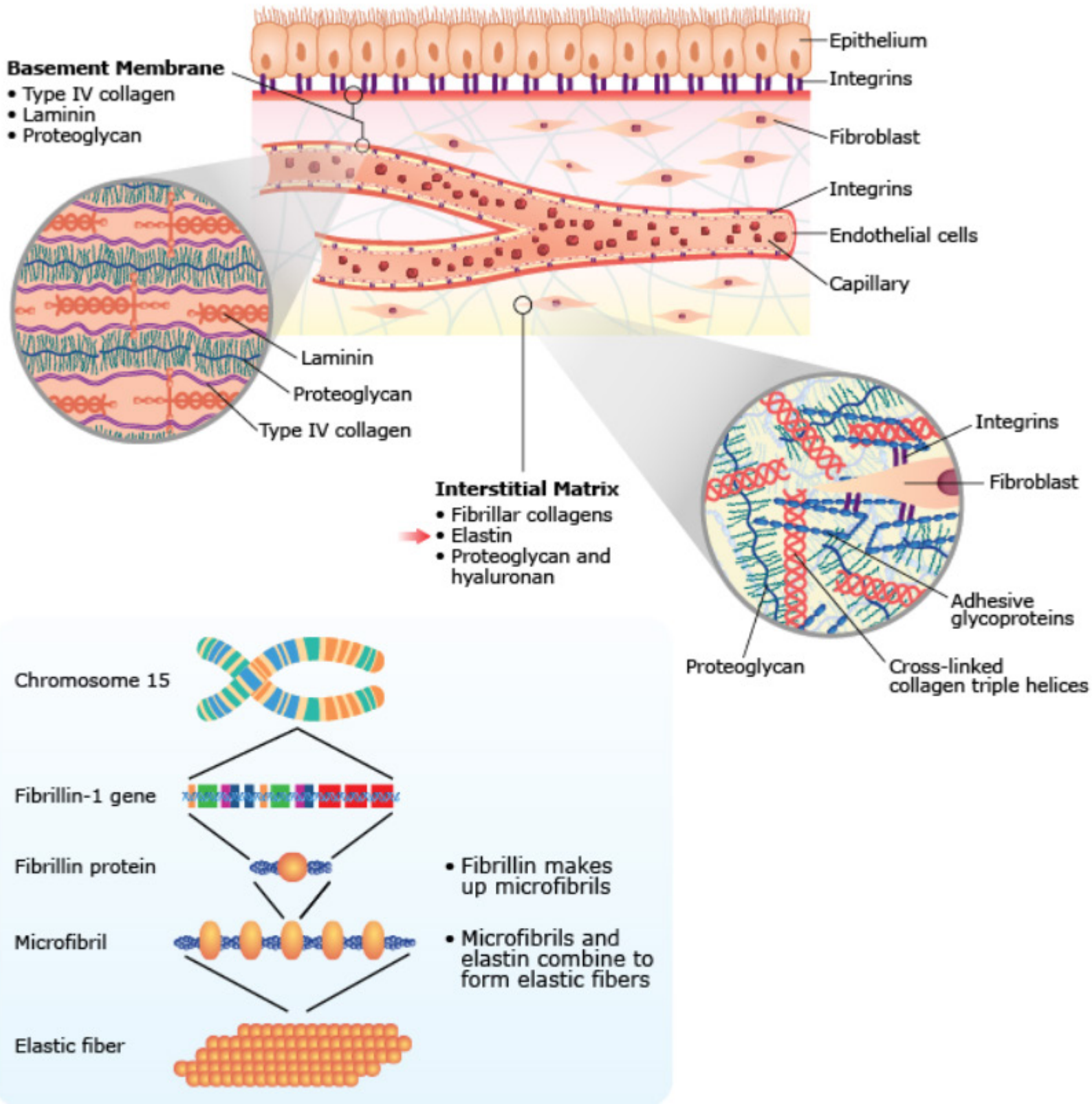

▲ **Figure 23–1.3B** Extracellular Matrix: Elastin

Please visit us at www.Groupinsiders.com

© DeVry/Becker Educational Development Corp. All rights reserved.

1.4 Summary of Collagen Disorders

▼ **Table 23–1.4** Summary of Collagen Disorders

Disease	Collagen Type	Mechanism	Clinical
Scurvy	Vitamin C deficiency	Inhibition of the *hydroxylation* step of collagen synthesis	Bleeding, bruising, impaired wound healing
Keloid	Type III collagen	Excess production	Large, tumor-like scars; common in African-Americans
Ehlers-Danlos Syndrome	Type III collagen (most commonly)	Impaired collagen synthesis or structure	Hyperextensible skin, hypermobile joints; associated with *berry aneurysms*
Osteogenesis Imperfecta	Type 1 collagen	*AD* defect in synthesis of α1 and α2 chains	Brittle bones, *blue sclerae*, hearing loss, dental abnormalities
Alport Syndrome	Type IV collagen	*X-linked* mutation in the α5 chain	Progressive renal failure, deafness, eye disorders
Benign Familial Hematuria	Type IV collagen	Defective formation	Asymptomatic hematuria

1.5 Mixed Connective Tissue Disease

- Autoimmune syndrome with overlapping symptoms of systemic lupus erythematosus (SLE), sclerodoma, and polymyositis.
- Positive *anti-U1 RNP* defines the disease.
- Nephropathy is rare.
- Controversial as to whether this disease exists.

Please visit us at www.Groupinsiders.com

© DeVry/Becker Educational Development Corp. All rights reserved.

Please visit us at www.Groupinsiders.com

1 Classification of Joint Pathologies

- **Group I: Noninflammatory** (osteoarthritis, neuropathic joint)
- **Group II: Inflammatory** (rheumatoid arthritis, gout)
- **Group III: Septic** (Lyme disease, disseminated gonococcemia)
- **Group IV: Hemorrhage** (trauma, hemophilia)

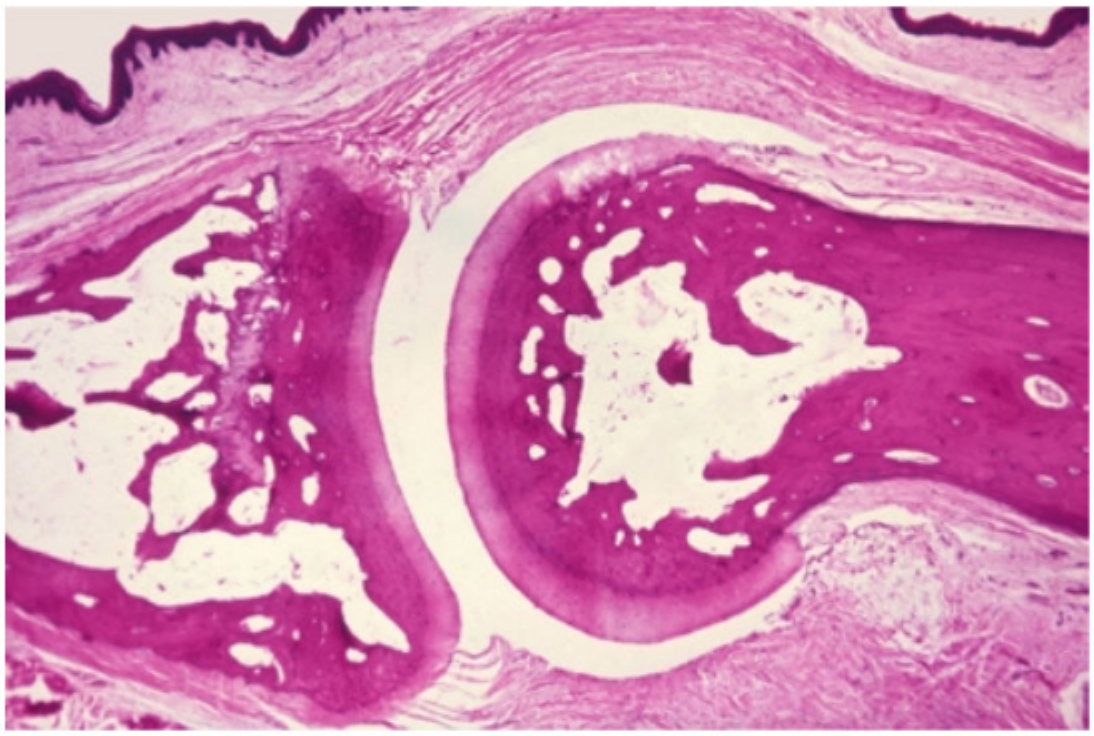

Biophoto Associates/Science Source

▲ **Figure 24–1.0** Joint Histology

1.1 Joint Anatomy and Histology

Divided into two main functional groups: solid joints and synovial joints.

1.1.1 Histology

- Articular surface of each bone is covered by *hyaline cartilage*.
- Articular surfaces are held together by joint capsule.
- Inner aspect of the capsule is lined by *synovium*.
- Synovial cells secrete hyaluronic acid and glycoproteins to make joint fluid, which nourishes and lubricates the hyaline cartilage.

USMLE® Key Concepts

For Step 1, you must be able to:

- Identify the common noninflammatory, inflammatory, and septic arthritides.
- Explain the molecular basis of arthritides' pathogenesis.
- Identify the types of joint tumors.
- Describe the use of synovial fluid analysis in the diagnosis of arthropathies.

Connection to Anatomy

Solid joints provide structure with minimal movement while *synovial joints* provide for a range of movement. The articular surface of each bone is covered by hyaline cartilage and the articular surfaces are held together by a joint capsule. The inner aspect of the capsule is lined by the synovium. Synovial cells secrete hyaluronic acid and glycoproteins to make joint fluid, which nourishes and lubricates the hyaline cartilage.

Please visit us at www.Groupinsiders.com

© DeVry/Becker Educational Development Corp. All rights reserved.

2 Noninflammatory Arthritis

2.1 Osteoarthritis

Osteoarthritis is defined as the *noninflammatory degeneration* of the articular cartilage due to wear and tear. It is the most common form of arthritis.

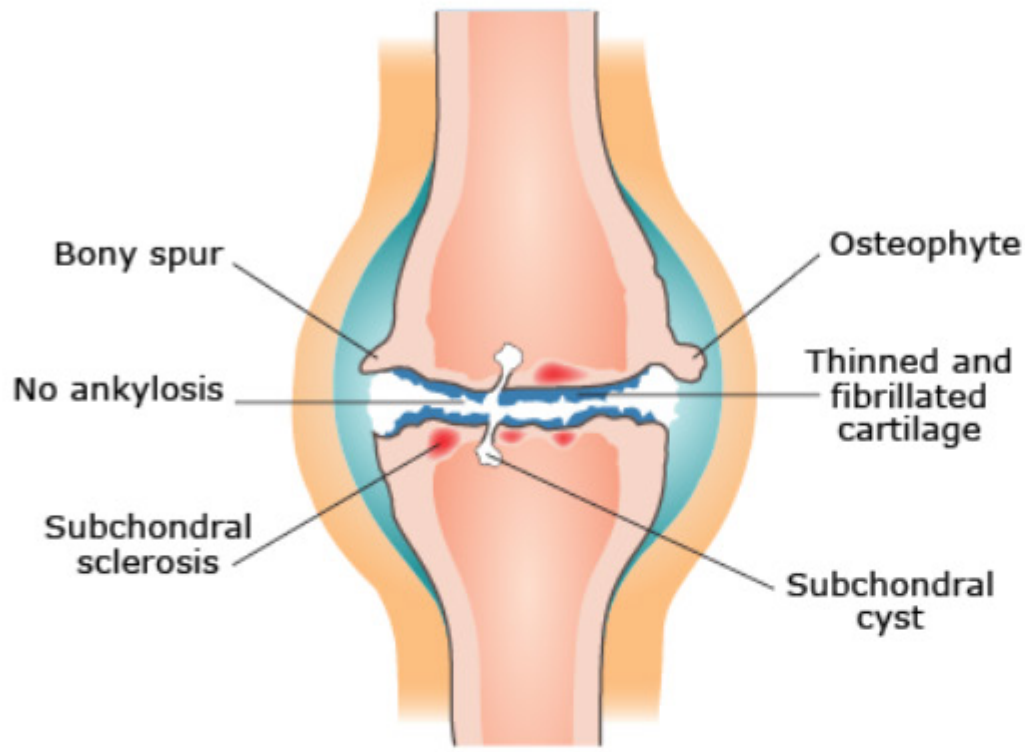

▲ **Figure 24–2.1A** Osteoarthritis

2.1.1 Primary

Due to aging; almost universal after 65 years of age.

Etiology

Excessive pressure on articular cartilage:

- Alters functioning of chondrocytes
- Imbalance between formation and removal of cartilage matrix
- Predisposition to fissuring and flaking of cartilage

2.1.2 Secondary Causes

- Legg-Calvé-Perthes disease
- Osteochondritis dissecans
- Mechanical: Trauma, obesity, meniscus injury, congenital deformity
- Metabolic causes: Diabetes, hemochromatosis

2.1.3 Features

- Insidious onset
- Pain that increases with use
- Morning stiffness typically lasting about 30 minutes
- **Bouchard nodes:** Proximal interphalangeal joint
- **Heberden nodes:** Distal interphalangeal

Please visit us at www.Groupinsiders.com

© DeVry/Becker Educational Development Corp. All rights reserved.

2.1.4 Histopathology

- Granular articular surface
- *Subchondral bone cysts*
- Osteophytes at edge causing 2° synovitis
- *Eburnation*
- *Joint space narrowing*

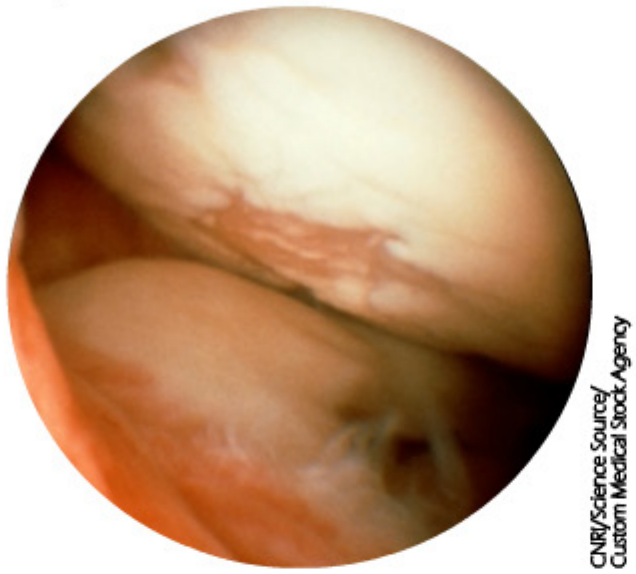

CNRI/Science Source/Custom Medical Stock Agency

▲ **Figure 24–2.1B** Osteoarthritis

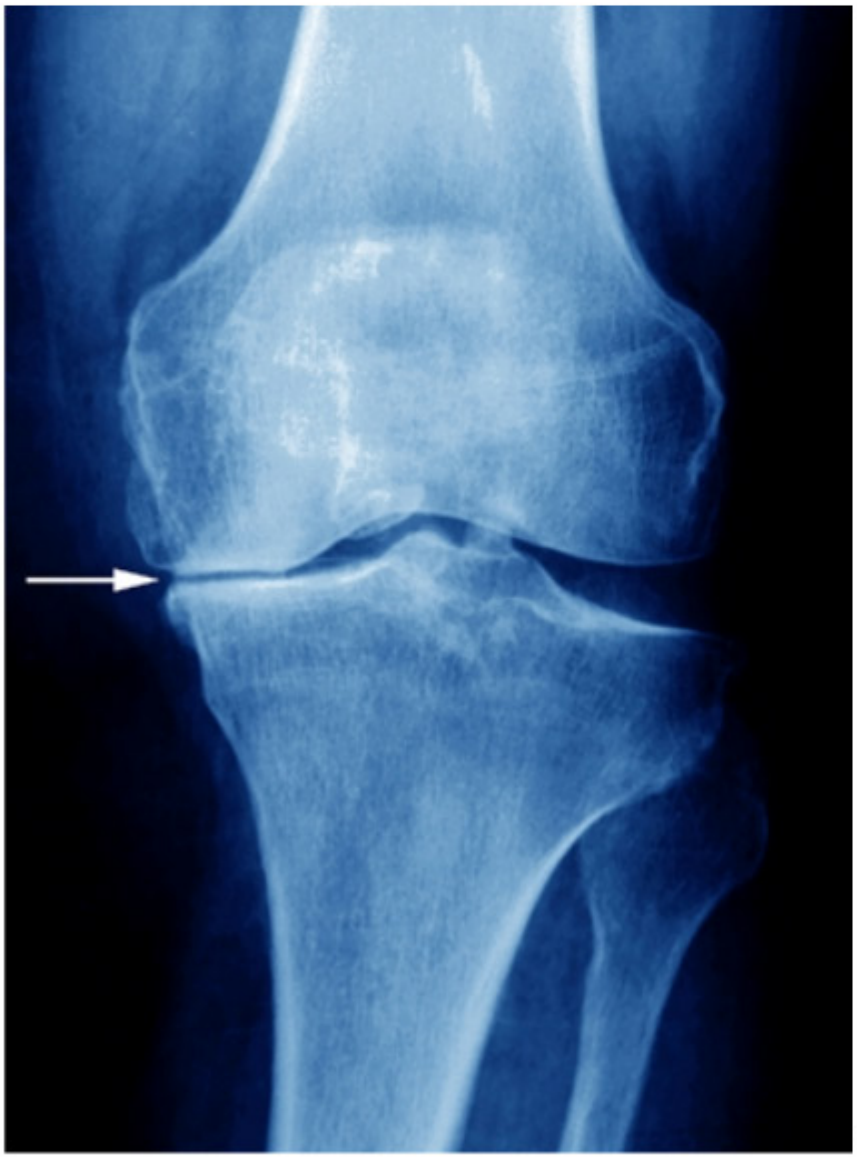

ISM/Phototake, Inc.

▲ **Figure 24–2.1C** Joint Space Narrowing

Dr. P. Marazzi/Science Source

▲ **Figure 24–2.1D** Heberden Nodes in Osteoarthritis

Please visit us at www.Groupinsiders.com

© DeVry/Becker Educational Development Corp. All rights reserved.

2.1.5 Distribution of Primary Osteoarthritis (OA)

- Primary OA typically involves a variable number of joints in characteristic locations, as shown (weight-bearing joints).

2.2 Neuropathic Arthropathy (Charcot Joint)

- Noninflammatory.
- Joint destruction is due to insensitivity to pain (neuropathy).

▼**Table 24–2.2** Diseases Affecting Joints

Disease	Joints Affected
Diabetes mellitus	Tarsometatarsal joint
Syringomyelia	Shoulder, elbow, wrist joints
Syphilis (tabes dorsalis)	Hip, knee, ankle joints

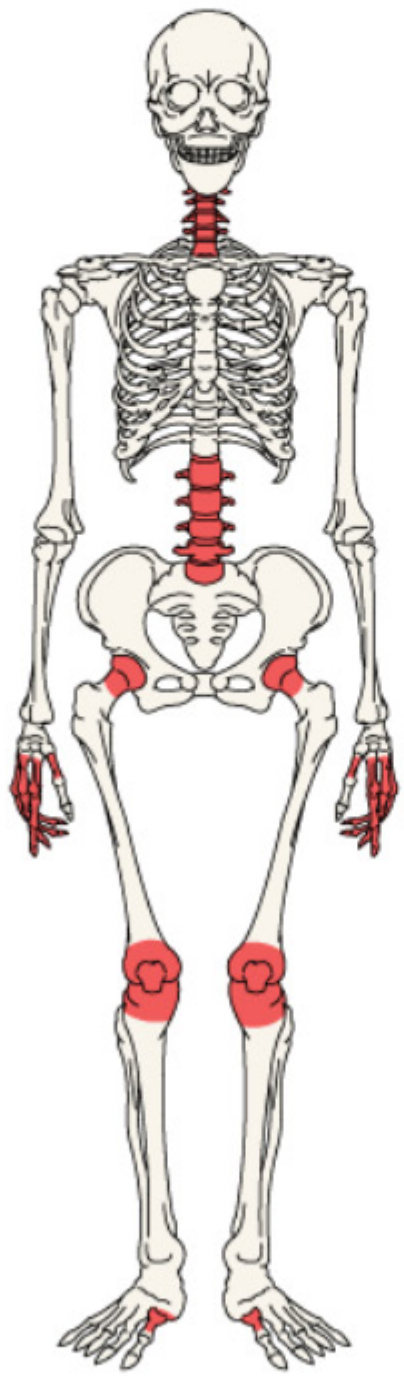

▲**Figure 24–2.2**
Distribution of Primary OA

Connection to Pharmacology

First-line management of osteoarthritis is non-opioid analgesics, acetaminophen or nonsteroidal anti-inflammatory drugs. See *Pharmacology*, chapter 11, "Drugs for Disorders of Connective Tissue and Musculoskeletal System."

Please visit us at www.Groupinsiders.com

© DeVry/Becker Educational Development Corp. All rights reserved.

3 Inflammatory Arthritis

3.1 Rheumatoid Arthritis (RA)

- Chronic systemic autoimmune disease
- Nonsuppurative synovitis
- Onset usually at 20–40 years
- Predominantly in females
- May lead to severe joint deformity

Etiology

- Genetic
  - Increased incidence in family members
  - Monozygotic twins 30% concordance
  - MHC class 2 linkage: HLA–DR4, HLA–DR1
- Autoimmune
  - Rheumatoid factor *(RF)*
    —IgM targeting Fc portion of IgG
  - Antinuclear antigen (ANA) + in 30%
- Other
  - Hormonal
  - Dietary
  - Psychosomatic
  - Biological

Please visit us at www.Groupinsiders.com

© DeVry/Becker Educational Development Corp. All rights reserved.

Pathogenesis

- *Molecular mimicry* between synovial antigen and microbes such as Epstein-Barr virus (EBV) in *HLA-DR4* genetically susceptible individual (*MHC class 2*) results in activation of $CD4^+$ Th1-cells.
- Cytokines (TNF and IL-1) induce inflammation in the synovium.
- RF is made by B cells in response to synovial antigen.
- Damage in joints is *type IV hypersensitivity*.
- RF + IgG in serum activate the complement and cause type III hypersensitivity in the vasculature.
- Th17 produces IL-17, which causes neutrophilic infiltration, and granulation tissue called pannus formation.
  - Pannus formation causes release of cytokines, causing damage to the articular cartilage.
  - There is eventual fusion (ankylosis) of the joint.

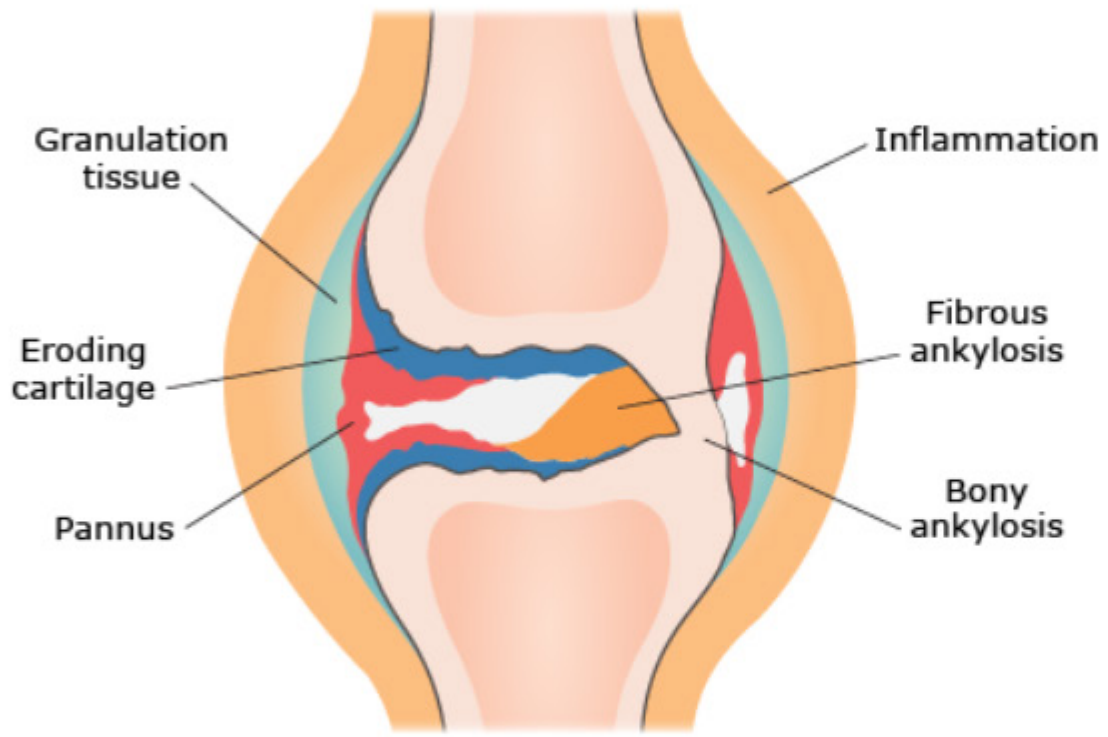

▲ **Figure 24–3.1A** Pannus Formation

Dr. Allan Harris/Phototake, Inc.

◀ **Figure 24–3.1B** Joints Involved in Rheumatoid Arthritis

Please visit us at www.Groupinsiders.com

© DeVry/Becker Educational Development Corp. All rights reserved.

Clinical Findings

- Symptoms of more than six weeks' duration
  - Often last the remainder of the patient's life
- Inflammatory synovitis
  - Palpable synovial swelling
  - Morning stiffness of more than one hour, fatigue
- Symmetrical and polyarticular (more than three joints)
  - Typically involves wrists, MCP, and PIP joints
- Typically spares thoracolumbar spine, DIPs of the fingers, and IPs of the toes
- Rheumatoid factor (RF)
  - 45% positive in first six months
  - 85% positive with established disease
  - Not specific for RA; high titer early is a bad sign
- Marginal erosions and joint space narrowing on x-ray

PIP Swelling

- Swelling is confined to the area of the joint capsule.
- Synovial thickening feels like a *firm sponge*.

Ulnar Deviation and MCP Swelling

- *An across-the-room diagnosis*
- Prominent ulnar deviation in the right hand
- MCP and PIP swelling in both hands
- Synovitis of left wrist

Please visit us at www.Groupinsiders.com

© DeVry/Becker Educational Development Corp. All rights reserved.

Synovitis

- Synovial cell proliferation
- Infiltration with lymphocytes, PMNs, and macrophages
- Lymphoid follicles
- Fibrin on surface

Nodules

Dr. Koshy Johnson/Phototake, Inc.

▲ **Figure 24–3.1C** Nodules

- Skin: Rheumatoid nodules
  - Present in 25% of patients
  - Arise in areas of pressure, such as ulnar aspects of forearm, elbows
    —Can arise in viscera, as in lungs, pericardium, myocardium
    —Firm, non-tender, and subcutaneous

Other Associated Findings

- Sjögren syndrome
- Interstitial fibrosis
- Anemia of chronic disease
- Carpal tunnel (median nerve)
- Subluxation atlantoaxial vertebra
- Pericarditis, aortitis, vasculitis
- Baker cyst behind knee joint
- Caplan syndrome—combination of rheumatoid nodules in the lung and pneumoconiosis
- Rarefaction—adjacent structures affected by osteoclasts

Please visit us at www.Groupinsiders.com

© DeVry/Becker Educational Development Corp. All rights reserved.

Wellcome Images

▲ **Figure 24–3.1D** Arthritis Mutilans

Clinical Course

- *Damage occurs early in most patients.*
  - —50% show joint space narrowing or erosions in the first two years.
  - —By 10 years, 50% of young, working patients are disabled.
- Death comes early.
  - —Multiple causes.
  - —Compared to general population.
  - —Women lose 10 years; men lose 4 years.

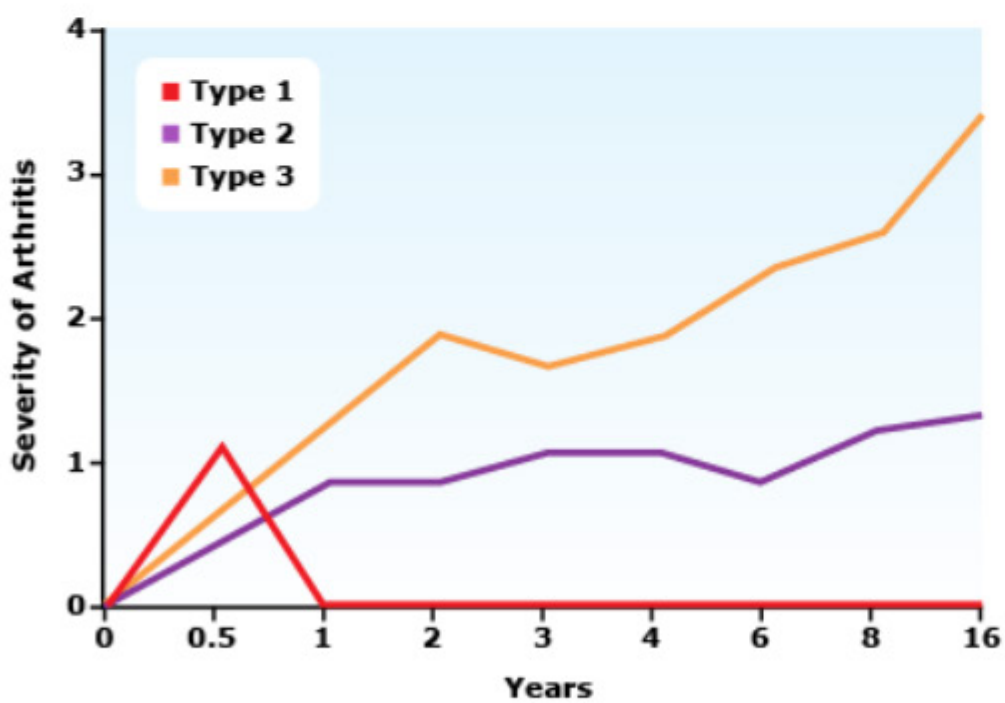

Type 1 = Self-limited—5% to 20%
Type 2 = Minimally progressive—5% to 20%
Type 3 = Progressive—60% to 90%

▲ **Figure 24–3.1E** Clinical Course of RA

Please visit us at www.Groupinsiders.com

© DeVry/Becker Educational Development Corp. All rights reserved.

3.2 Juvenile Rheumatoid Arthritis

- Begins *before age 16* years.
- Females more than males, ratio 2:1.
- **Classification**
  - Polyarticular (40% of cases)
  - Pauciarticular (40%)—uveitis with potential blindness
  - Still disease (20%)—fever, rash polyarthritis
- **Differences from adult rheumatoid arthritis**
  - *Oligoarthritis more common*
  - Systemic onset more frequent
  - Large joints affected more than small joints
  - *Rheumatoid nodules absent*
  - *Rheumatoid factor negative*
  - Anti-nuclear antibody positive
    - —Knees, wrists, elbows, and ankles
    - —Extra-articular manifestations
      - Pericarditis
      - Myocarditis
      - Pulmonary fibrosis
      - Glomerulonephritis

Connection to Pharmacology

Treatment of rheumatoid arthritis depends on immunosuppression. Methotrexate is the gold standard, but new biologics, such as infliximab, inhibit TNF damage. See *Pharmacology*, chapter 11, "Drugs for Disorders of Connective Tissue and Musculoskeletal System."

3.3 Seronegative Spondyloarthropathies

Seronegative spondylarthropathies develop in genetically predisposed individuals when triggered by a variety of environmental stimuli. They include ankylosing spondyloarthritis, Reiter syndrome, enteritis-associated arthritis, and psoriatic arthritis.

Pathogenesis

- T cell response to unknown antigen, often triggered after infection.
- Pain begins in the ligaments.
- Spondylitis (vertebral column) with or without involvement of peripheral or axial arthritis.
  - Sacroiliac joint preferentially affected.
- *HLA-B27*
- Absence of rheumatoid factor—seronegative.
- **Ankylosing Spondyloarthritis**
  - Inflammatory disease of axial joints, especially *sacroiliac* resulting in low-back pain.
  - Starts in adolescent boys but may take years to diagnose.
  - 90% *HLA-B27* positive.
  - Extra-articular manifestations: uveitis, aortitis, and amyloidosis
- **Testing Spinal Mobility Schober Test**

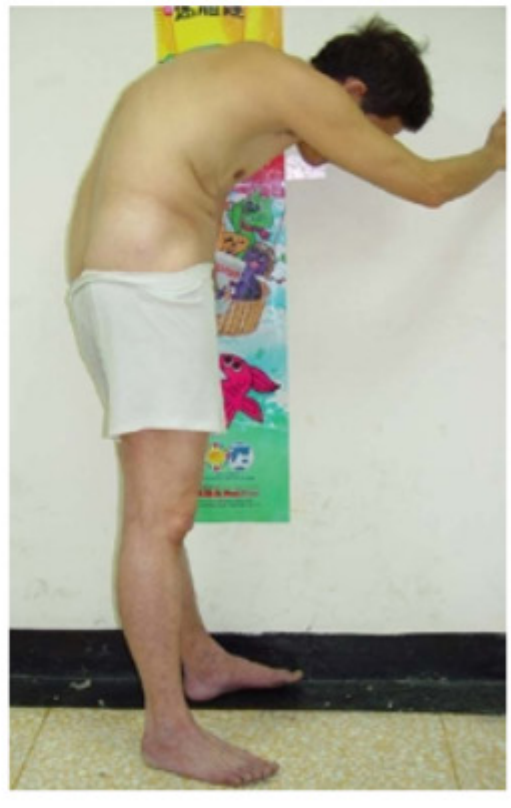

Courtesy of Dr. Eranga Gunawardana/Medical Powerpoint Presentations

▶ **Figure 24–3.3A** Ankylosing Spondyloarthritis

Please visit us at www.Groupinsiders.com

© DeVry/Becker Educational Development Corp. All rights reserved.

3.4 Reactive Arthritis

- *Reiter syndrome* is a triad of arthritis, nongonococcal urethritis, and conjunctivitis.
  - The urethritis is caused most commonly by *chlamydia trachomatis.*
  - The arthritis sets in along with Achilles tendon periostitis.
  - The conjunctivitis is noninfectious.
- Males, ages 20 to 30 years.
- 80% *HLA-B27* positive.

Memory Aid

Reiter syndrome: You can't see, pee, or climb a tree (triad of conjunctivitis, urethritis, and arthritis).

Important Concept

Lover's heel is the inflammation of the Achilles tendon associated with gonococcal urethritis.

3.5 Enteritis-Associated Arthritis

- Associated with gastrointestinal infections with *Yersinia, Salmonella, Shigella, Campylobacter,* and other gram-negatives
- Lipopolysaccharides stimulate immune response
- Primarily involves knees and ankles

3.6 Psoriatic Arthritis

- 10% of patients with psoriasis
- Ages 35 to 45 years
- *Sausage-shaped* distal interphalangeal joints
- Asymmetric
- Ankles, knees, hips, and wrists
- *Radiograph of the hand*—"pencil-in-cup" deformity

Bart's Medical Library/Phototake, Inc.

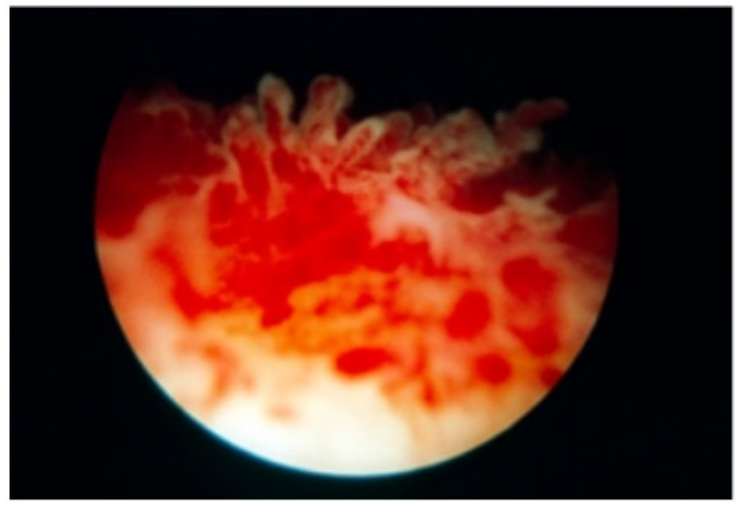

CNRI/Science Source/Custom Medical Stock Photo

National Medical Slide Bank/Custom Medical Stock Photo

▶ **Figure 24–3.6** Psoriatic Arthritis

Please visit us at www.Groupinsiders.com

© DeVry/Becker Educational Development Corp. All rights reserved.

4 Arthritis of Metabolic Origin

4.1 Gout

Gout is characterized by the crystallization of monosodium urate within and around joints, due either to inborn errors of purine metabolism *(primary gout)* or errors of overproduction or underexcretors of uric acid. It occurs 95% of the time in men older than 30 and is uncommon in women prior to menopause.

4.1.1 Primary Gout

Primary gout arises from inborn errors in metabolism involving purine metabolism, for example *hypoxanthine-guanine phosphoribosyltransferase (HPRT, or HGPRT), deficiency*, also known as Lesch-Nyhan syndrome.

- **Lesch–Nyhan Syndrome**
  - X-linked
  - Absence of HPRT (hypoxanthine-guanine phosphoribosyltransferase)
- Accumulation of PRPP (5-phospho-D-ribosyl 1-pyrophosphate) → increased uric acid

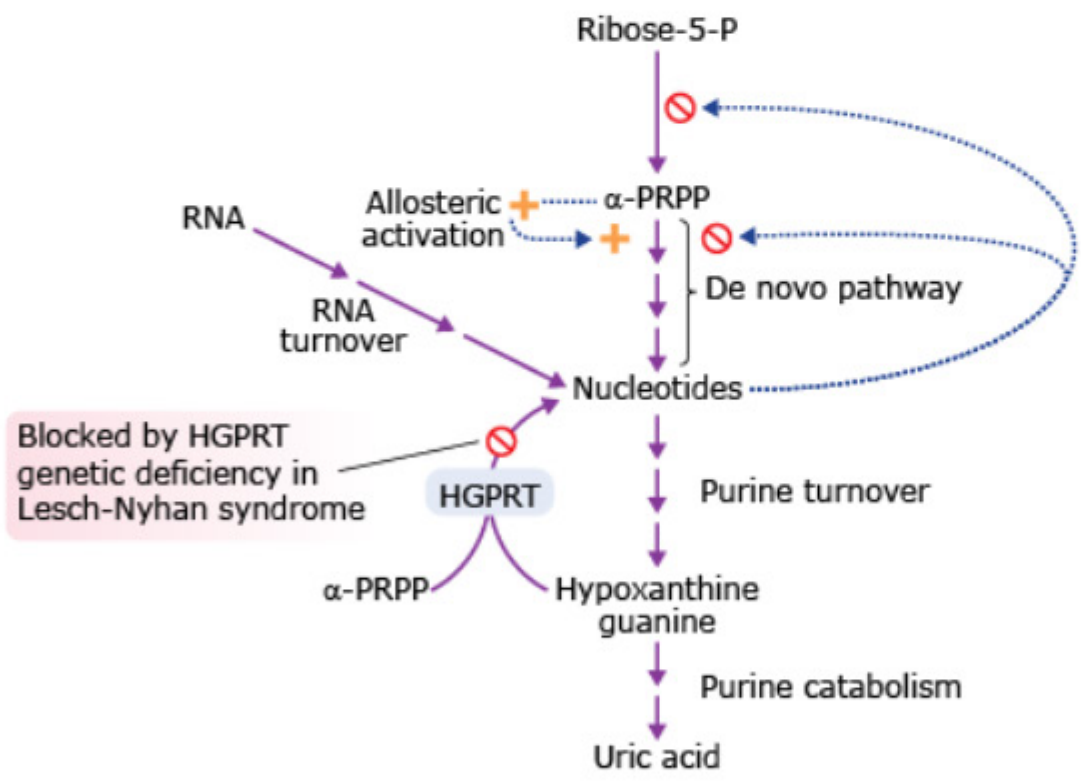

▲ **Figure 24–4.1A** Uric Acid Synthetic Pathways

Connection to Biochemistry

HGPRT is a transferase that catalyzes the conversion of hypoxanthine to inosine monophosphate and guanine to guanosine monophosphate. This reaction transfers the 5-phosphoribosyl group from 5-phosphoribosyl 1-pyrophosphate to the purine. HGPRT plays a central role in the generation of purine nucleotides through the purine salvage pathway. HGPRT deficiency causes a buildup of uric acid in all body fluids. This results in both hyperuricemia and hyperuricosuria, associated with severe gout and kidney problems.

Please visit us at www.Groupinsiders.com

© DeVry/Becker Educational Development Corp. All rights reserved.

4.1.2 Secondary Gout

Secondary gout is more common and presents with two types:

1. **Underexcretors** of uric acid from the kidneys (Urine uric acid **<700 mg/24 h**) account for 80% to 90% of these patients.
   - Renal defect: Reduced GFR, tubular defect
   - Drugs: Cyclosporine, diuretics, nicotinic acid, salicylates (low dose), pyrazinamide, and ethambutol
   - Ethanol
   - Dehydration, acidosis, starvation
   - Lead nephropathy
2. **Overproducers** of uric acid (urine uric acid **>700** to 1,000 mg/24 h) as seen with nucleated cell turnover account for about 10% to 20%.
   - Lymphoproliferative and myeloproliferative disorders, solid tumors (increased cell turnover)
   - Drugs: Cytotoxic agents, pancreatic extracts, vitamin B12 (tumor lysis syndrome)
   - Alcohol consumption (especially beer)
   - Obesity, psoriasis, and tissue necrosis

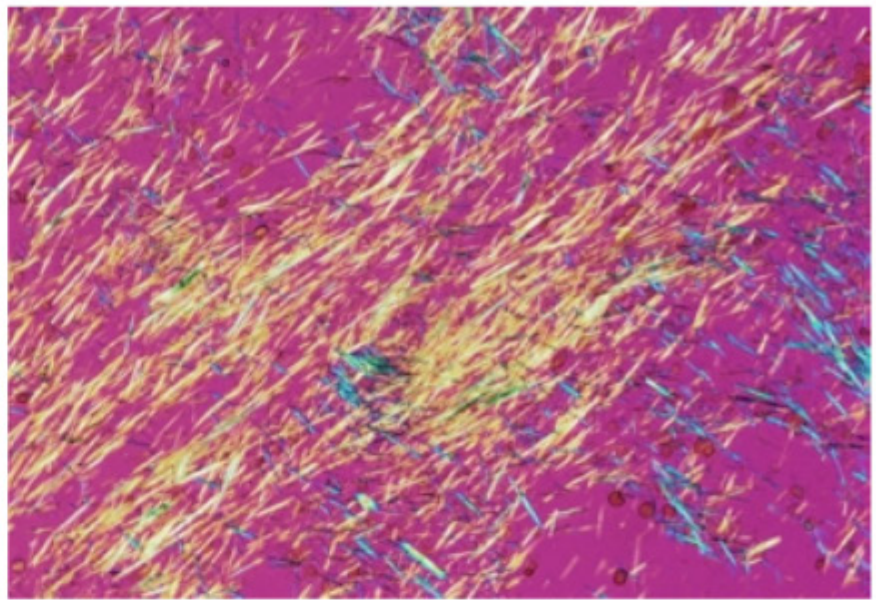

Dr. E. Walker/Science Source

▲ **Figure 24–4.1B** Lab Test for Gout

4.1.3 Other Manifestations of Gout

- **Podagra**
  - Recurrent acute attacks of gout, especially in joints such as the big toe.
  - Sudden onset of severe pain where the joint is hot, red, and swollen.
  - Fever, tachycardia, and other constitutional symptoms are observed.
- **Tophi:** Soft tissue depositions

Mediscary/Visuals Unlimited, Inc.

▲ **Figure 24–4.1C** Tophi

Connection to Pharmacology

Treatment of acute gout involves NSAIDs or corticosteroids. For overproducers, allopurinol; for underexcreters, probenecid. See *Pharmacology*, chapter 11, "Drugs for Disorders of Connective Tissue and Musculoskeletal System."

Please visit us at www.Groupinsiders.com

© DeVry/Becker Educational Development Corp. All rights reserved.

4.1.4 Pseudogout

Pseudogout clinically resembles gout but results from the deposition of *calcium pyrophosphate dihydrate (CPPD)* in tissues, most commonly *the knee*. If it results in linear deposits in articular cartilage, it is referred to as *chondrocalcinosis.*

CNRI/Science Source

▲ **Figure 24–4.1D** Pseudogout

- Typical age is more than 50 years.
- Hereditary type is the most common variant leading to *osteoarthritis* (chromosome 8q).
- Secondary pseudogout, underlying disease associations:
  - Primary hyperparathyroidism
  - Hemochromatosis and hemosiderosis
- Pyrophosphate inhibitor is increased in these conditions, causing an increase in inorganic pyrophosphate concentration.
- Hypothyroidism
- Hypophosphatemia
- *Hypomagnesemia*
- Neuropathic joints
- Trauma
- Aging, hereditary

Bates, MD/Custom Medical Stock Photo

▶ **Figure 24–4.1E** Calcium Pyrophosphate Deposition Positive Birefringence

Please visit us at www.Groupinsiders.com

© DeVry/Becker Educational Development Corp. All rights reserved.

5 Septic Arthritis

When microbes are carried to the synovium via the blood they can set up foci of infection, which ultimately result in joint damage. Most cases will resolve with specific antimicrobials to cure the underlying infection.

Clinical Findings

- Single, warm joint
- Fever
- Leukocytosis
- Elevated ESR
- Purulent synovial fluid

5.1 Gonococcal Arthritis

- The most common form of bacterial arthritis in young, sexually active adults.
- Monoarticular
  - Most frequently knee
- Usually young females present with pauciarticular *migratory arthritis with tenosynovitis.*
- Resolves with appropriate treatment (ceftriaxone).

5.2 *Staphylococcus aureus*

- Most common nongonoccoccal cause of septic arthritis
- Might be seen with intravenous drug abuser (IVDA)

5.3 *Borrelia burgdorferi*

The microbe responsible for Lyme disease.

5.4 *Babesia microti*

The intraerythrocytic parasite responsible for babesiosis, which causes hemolytic anemia.

5.5 *Pasteurella multocida*

Caused by cat or dog bite.

5.6 Tuberculous Arthritis

Classic granulomas (caseating) in synovium.

5.7 Viral Arthritis

Caused by *parvovirus B19*, rubella, and hepatitis C.

Science Source

▲ **Figure 24–5.2** Septic Arthritis

Please visit us at www.Groupinsiders.com

© DeVry/Becker Educational Development Corp. All rights reserved.

6 Joint Tumors

6.1 Ganglion Cyst

- Small cyst located near joint capsule.
- Often arises in wrist.
- Firm, fluctuant, pea-sized translucent nodule.
- Results from cystic or myxoid degeneration of connective tissue, no communication with joint space.

6.2 Pigmented Villonodular Synovitis

- Neoplastic proliferation of synovium, usually involving the knee
- Ages 20 to 40
- Suspect this when you get a bloody arthrocentesis
- Diagnosis by MRI/synovectomy

Please visit us at www.Groupinsiders.com

© DeVry/Becker Educational Development Corp. All rights reserved.

1 The Skeleton

1.1 Function

- Mechanical support
- Body size
- Body shape
- Mineral homeostasis
- Hematopoiesis

1.2 Biochemistry of Bone

Bone is mesenchymal tissue that undergoes mineralization. It is composed of:

1.2.1 Organic Matrix

- Collagen type I (90% by weight)
- Non-collagen proteins including osteocalcin and osteonectin

1.2.2 Inorganic Matrix

- Calcium hydroxyapatite (90%)

1.3 Anatomy of Bone

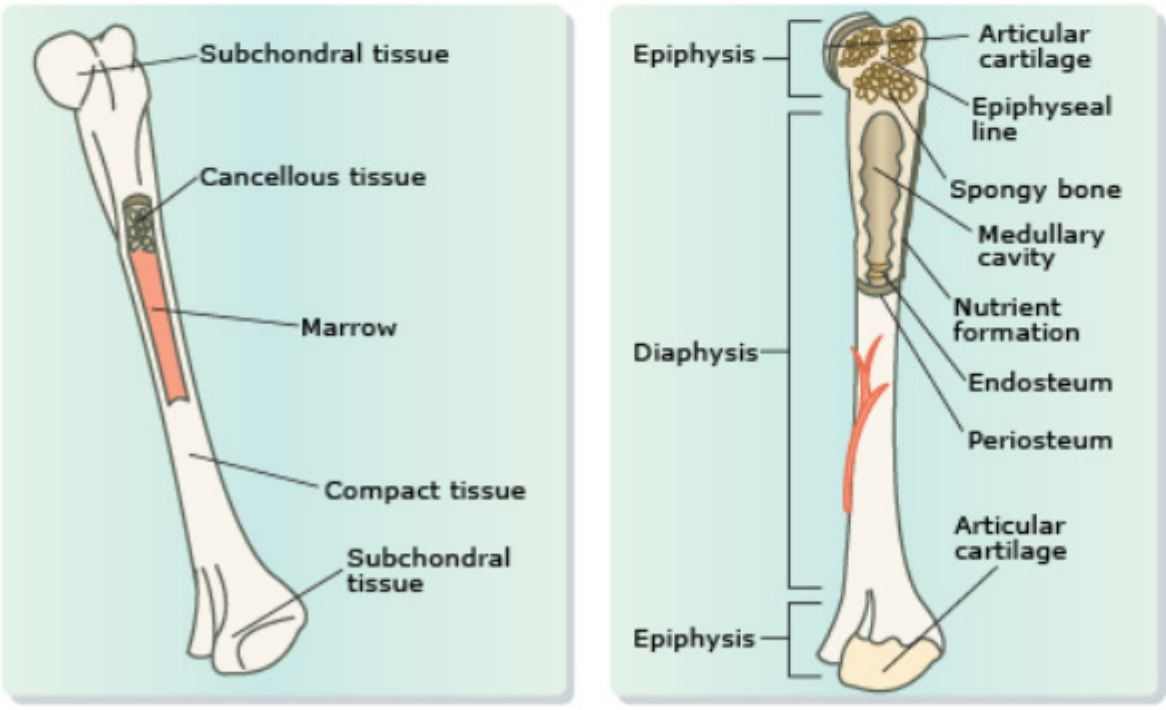

▲ **Figure 25–1.3** Anatomy of a Bone

USMLE® Key Concepts

For Step 1, you must be able to:

- Explain the genetic basis of the important congenital bone diseases.
- Describe the molecular details of bone formation and resorption via osteoprotegerin and receptor activator for NFκB.
- Identify the common causes of osteoporosis, osteitis fibrosa cystica, and osteomalacia.
- Explain the stages and etiologies of Paget disease.
- Identify the common types of bone fractures and describe the molecular basis of fracture repair.
- Differentiate among types of osteomyelitis caused by the most common bacterial agents.
- Distinguish among the common forms of benign and malignant bone neoplasias.

Please visit us at www.Groupinsiders.com

© DeVry/Becker Educational Development Corp. All rights reserved.

1.4 Types of Bone

1.4.1 Compact Bone

Compact bone is the hardened portion of the bone, usually present in the peripheral cortical region, providing structural support to the axial skeleton. Due to its supporting role, the histology will appear homogenously filled with mineralized bone housing various types of bone cells that will be discussed below.

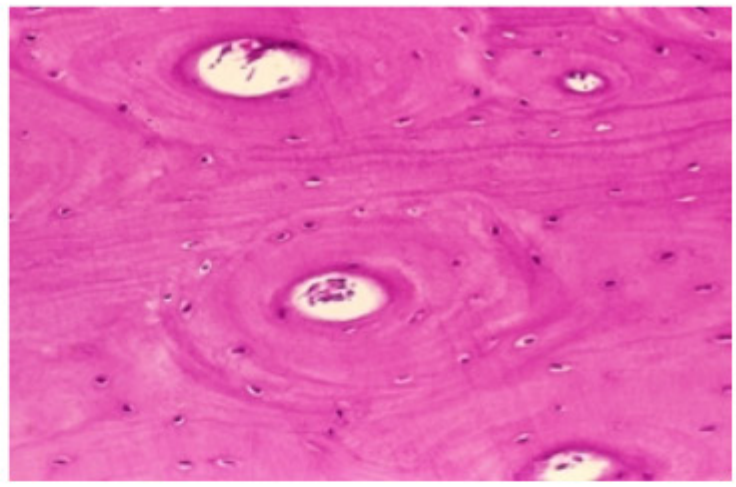

Biophoto Associates/Science Source

▲ **Figure 25–1.4A** Compact Bone

1.4.2 Cancellous/Spongy Bone

- Mature spongy bone also has concentric lamellae with lacunae and canaliculi housing osteocytes. However, the lamellae are *not arranged into osteons*.
- *Bone spicules* form an open network of branching *trabeculae*, with bone marrow found within the spaces.
- Whereas compact bone is vascularized, the bone matrix of the spicules are *not*. Osteocytes must rely on diffusion of nutrients and wastes from the marrow and endostium lining along the penetrating canaliculi.

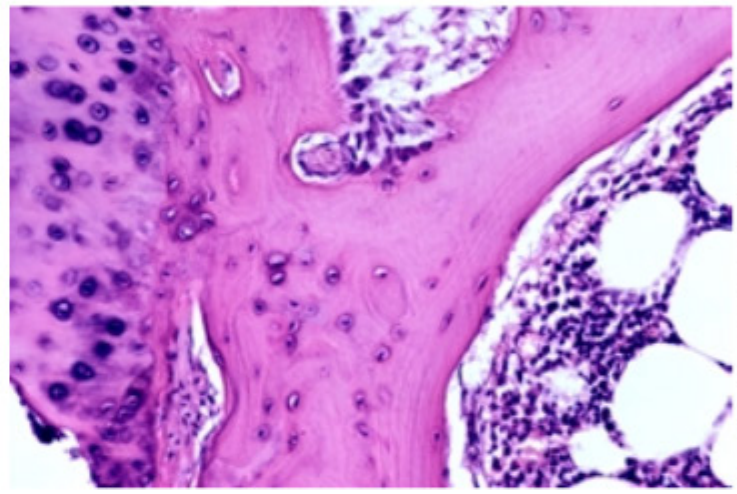

Carolina Biological Supply Co./Visuals Unlimited, Inc.

▲ **Figure 25–1.4B** Cancellous/Spongy Bone

1.4.3 Lamellar Bone

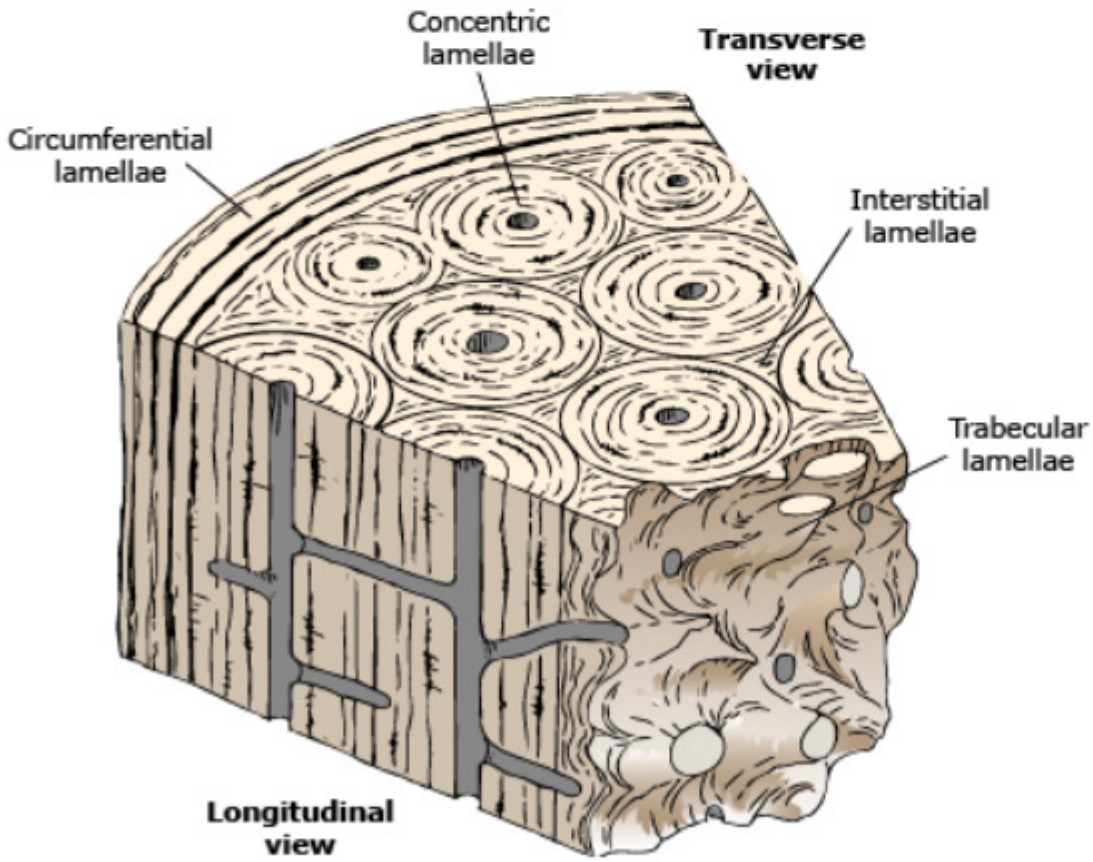

▲ **Figure 25–1.4C** Lamellar Bone

- The only pathological significance of this lamellar bone illustration is the presence of trabecular lamellae, which is addressed when we look at osteoporosis. In osteoporosis, this network is thinned and referred to as *osteopenia*.

Please visit us at www.Groupinsiders.com

© DeVry/Becker Educational Development Corp. All rights reserved.

1.5 Origin of Bone Cells

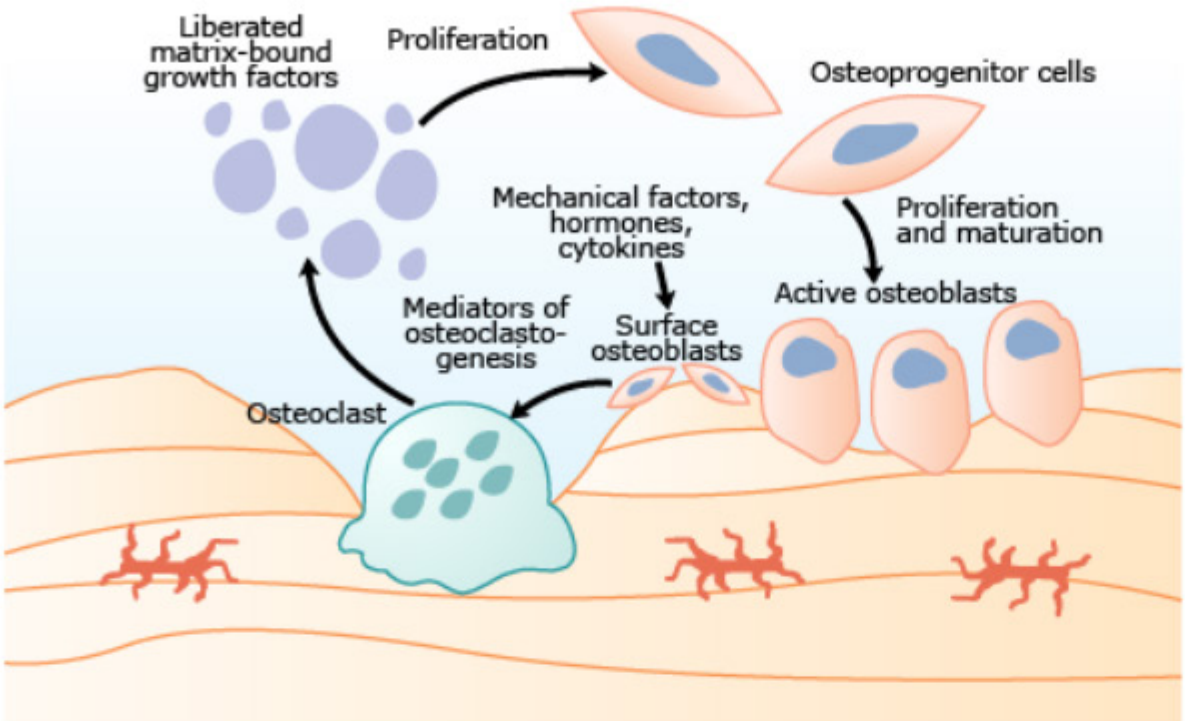

▲ **Figure 25–1.5** Origin of Bone Cells

1.6 Histology of Bone

1.6.1 Osteoblasts

- Located on the surface of bone
- Synthesize and arrange matrix
- If surrounded by bone, become osteocytes

1.6.2 Osteocytes

- Most numerous cells
- Encased by bone, but live in tunnel networks called canaliculi
- Important in maintaining bone and in remodeling

1.6.3 Osteoclasts

- Phagocytic cells responsible for bone resorption
- Important in maintaining bone and in remodeling
- Reside in resorption pits called *Howship lacunae*
- Liberated matrix activates osteoblasts to lay down new bone, keeping bone resorption and formation in balance.

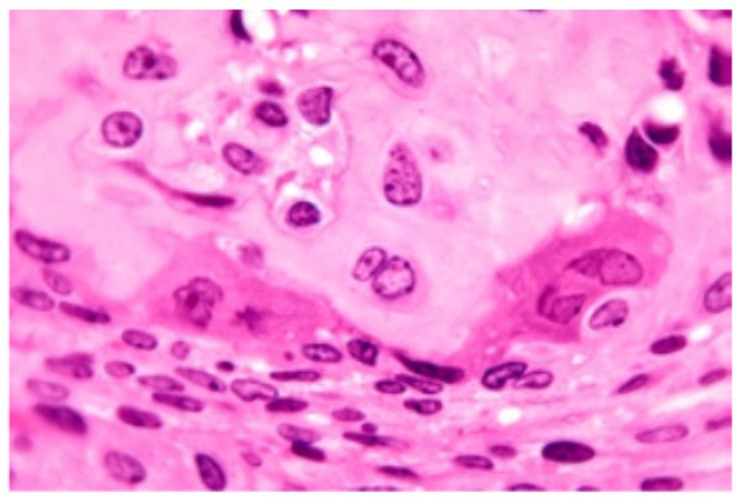

Carolina Biological Supply Co./Visuals Unlimited, Inc.

▲ **Figure 25–1.6** Osteocytes

Please visit us at www.Groupinsiders.com

© DeVry/Becker Educational Development Corp. All rights reserved.

2 Congenital Bone Disease

2.1 Achondroplasia

- Most common disease of growth plate
- Point mutation in *FGF receptor 3*
  - Constant activation of receptor leads to inhibition of cartilage proliferation.
  - Path of growth plate = Narrow zones of proliferation and disorganized clusters of large chondrocytes
- Clinically = *Dwarfism:* Shortened extremities with normal trunk and head
- 80% new mutations

Connection to Genetics

Achondroplasia is inherited as an autosomal dominant condition. Because the homozygous condition is incompatible with life, two affected parents have a two-thirds' chance of having a child with achondroplasia.

Wellcome Images/Custom Medical Stock Photo

	A	a
A	AA	Aa
a	Aa	aa

▲ **Figure 25–2.1** Achondroplasia

2.2 Thanatophoric Dwarfism

- Most common *lethal* form of dwarfism (1 in 20,000 births).
- Disease of growth plate
  - *Missense* or point mutation in *FGF receptor 3* gene results in shortening of limbs and macrocephaly.
  - Poor proliferation of chondrocytes with disorganization.
- Maldevelopment of chest cavity leads to respiratory failure and death.

Please visit us at www.Groupinsiders.com

© DeVry/Becker Educational Development Corp. All rights reserved.

2.3 Osteogenesis Imperfecta ("Brittle Bone" Disease)

- **Autosomal Dominant**
  - Defective synthesis of *type I collagen*
    —α1 α2 chains defects

Dr. Allan Harris/Phototake, Inc.

▲ **Figure 25–2.3** Osteogenesis Imperfecta

- **Types**
  - **Type 1:** Most common
  - **Clinical Findings**
    —Pathologic fractures at birth
    —Blue sclera due to reflection of choroidal vein
    —Misshapen teeth
  - **Type II:** Incompatible with life due to multiple fractures in utero

2.4 Osteopetrosis ("Marble Bone" Disease)

- **Two Forms**
  - Autosomal recessive (severe)
  - Autosomal dominant (less severe)
- **Defect in Osteoclasts (BM Transplant)**
  - Overgrowth and sclerosis of cortical bone ("too much bone")

Clinical Features

- Pathologic fractures
- Anemia secondary to replacement of bone marrow
- Cranial nerve compression with visual and hearing loss

PDSN/Phototake, Inc.

▲ **Figure 25–2.4** "Marble Bone" Disease

Please visit us at www.Groupinsiders.com

© DeVry/Becker Educational Development Corp. All rights reserved.

3 Metabolic and Acquired Bone Disease

3.1 Osteoporosis

- Increased porosity of bone due to *reduced bone mass (osteopenia)*
  - May be localized to a bone or diffuse
- Normal peak bone mass occurs in young adults
  - Polymorphisms in vitamin D receptor account for 75% of peak bone mass achieved
  - Age-related bone loss occurs at 0.7% per year

▼**Table 25–3.1** Osteoclastogenesis

Osteoclastogenesis begins with the induction of hematopoiesis from the bone marrow promoting embryonic stem cells to eventually differentiate into mature osteoclasts. The details of this are still being researched and debated.	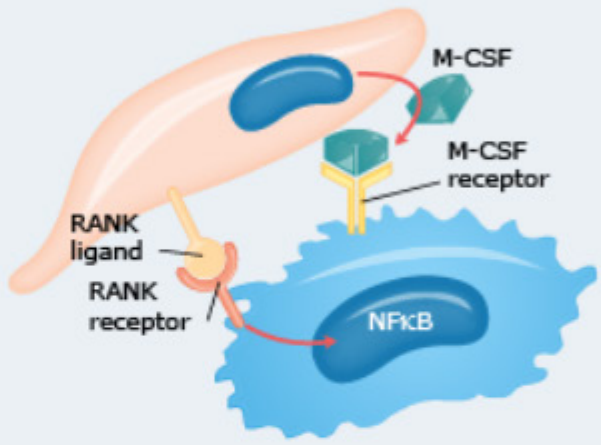
Pathogenesis of impaired synthesis or increased resorption, or both —May be primary or secondary —RANK (receptor activator of nuclear factor kappa β) with M-CSF (macrophage colony-stimulating factor) causes macrophages to convert into osteoclasts.	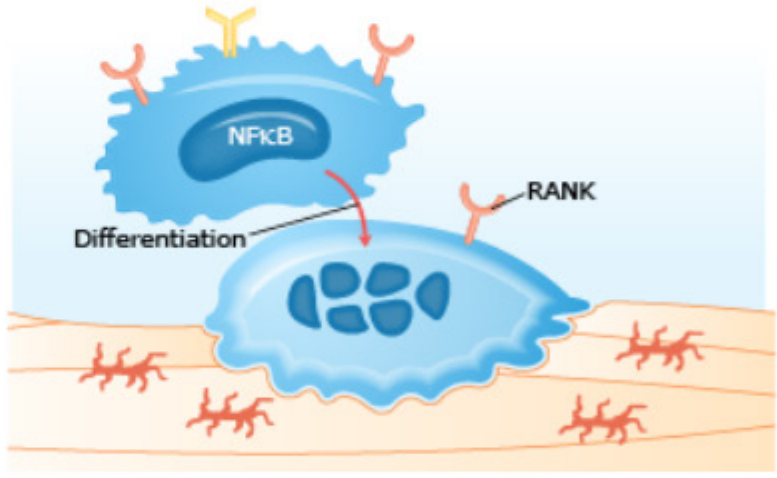
Bone formation and resorption are tightly coupled and controlled by osteoprotegerin (OPG) and receptor activator for NFκB (RANK). Stimulation of RANK causes stimulation of osteoclasts, while osteoprotegerin blocks the binding of RANK ligand and protects bone.	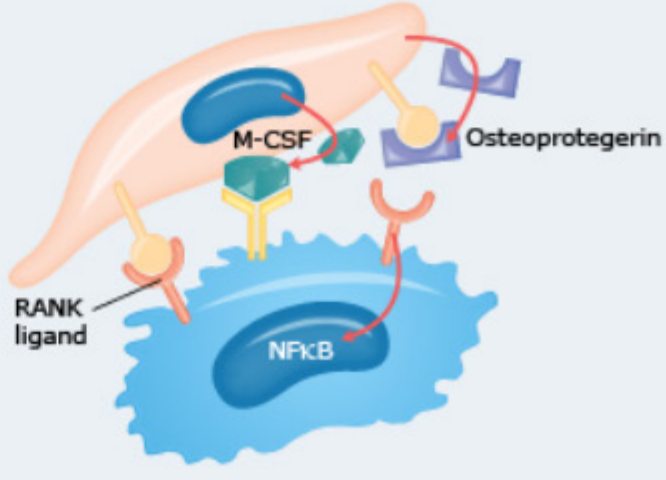

Please visit us at www.Groupinsiders.com

© DeVry/Becker Educational Development Corp. All rights reserved.

3.1.1 Common Forms

- **Senile**
  - Osteoblasts with diminished capacity to make new bone
  - Physical inactivity
- **Postmenopausal**
  - Estrogen deficiency
  - IL-1, IL-6, and TNF-α increased
  - Decreased OPG secretion

3.1.2 Other Secondary Causes

- Corticosteroid therapy
- Endocrine problems
- Poor nutrition
- Neoplasia

3.1.3 Pathology

- Trabeculae are thinned and lose interconnections

3.1.4 Clinical Features

- Vertebral (weight-bearing) fractures that result in spinal deformities (*lumbar lordosis* and *kyphoscoliosis*)
- Femoral neck fractures
- Colles fracture of distal radius

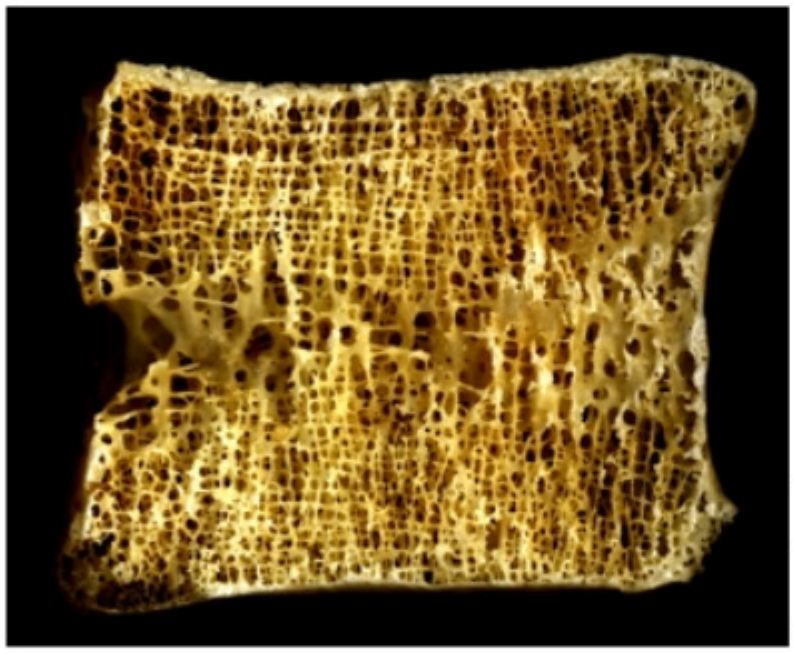

Medimage/Science Source

▲ **Figure 25–3.1B** Osteoporosis/Thinning of Vertebrae

Biophoto Associates/Science Source

▲ **Figure 25–3.1A** Osteoporosis

Please visit us at www.Groupinsiders.com

© DeVry/Becker Educational Development Corp. All rights reserved.

3.2 Osteitis Fibrosa Cystica (Von Recklinghausen Disease of Bone)

- Osteitis fibrosa cystica is a bone degenerative disease due to *any* reason, causing an increased level of parathyroid hormone.
  - Primary hyperparathyroidism due to a functioning adenoma(s) in the parathyroid gland(s).
  - Hyperparathyroidism causing widespread osteolytic lesions.
  - Von Recklinghausen disease of bone may manifest as a *"brown tumor"* of bone with multinucleated osteoclasts forming cystic cavities.
  - Diffuse radiolucency of bone mimicking osteoporosis may sometimes be evident.
  - Primary hyperparathyroidism lab findings:
    - Increased levels of parathyroid hormone
    - High serum calcium
    - Low serum phosphorus
    - High serum alkaline phosphatase

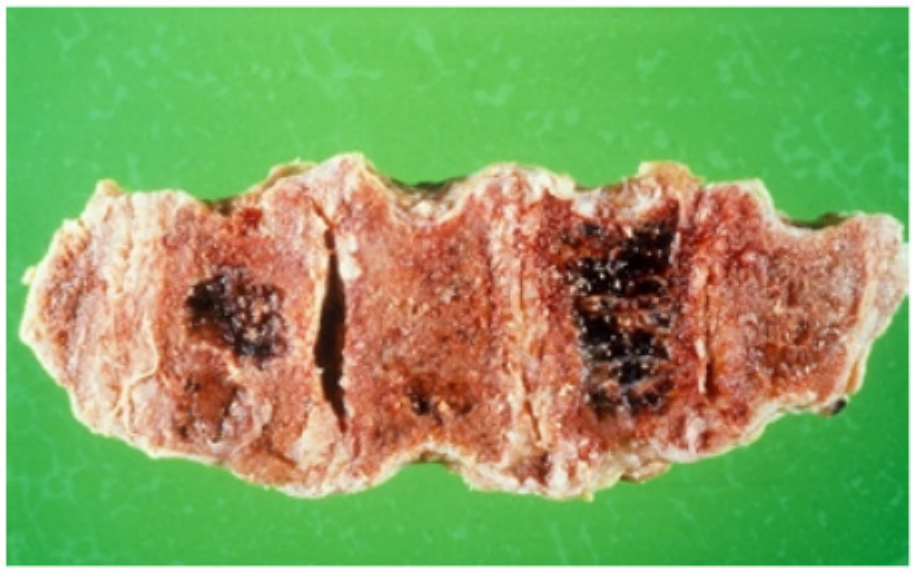
Biophoto Associates/Science Source

▲ **Figure 25–3.2** Osteitis Fibrosa Cystica/ Increased Osteoclastic Activity

3.3 Osteomalacia: Vitamin D Deficiency in Adults

- A softening of bones due to defective calcification of osteoid matrix.
- Diffuse radiolucency, which can mimic osteoporosis, is characteristic radiographically.
- When secondary to renal disease, osteomalacia is called *renal osteodystrophy*.

Please visit us at www.Groupinsiders.com

© DeVry/Becker Educational Development Corp. All rights reserved.

3.3.1 Etiology

▼ **Table 25-3.3** Causes of Vitamin D Deficiency

Vitamin D Deficient	Result
Not made	No sun/pigmentation
Not absorbed	Gastrointestinal disease
Destroyed	Phenytoin, rifampin (p450)
Not activated	Kidney disease, liver
Action resisted	End organ resistance
Phosphate Depletion	**Result**
Not absorbed	Antacids
Excreted in excess	Hyperparathyroidism

3.3.2 Pathology

- Histology shows wide osteoid seams
- **Biochemistry: Secondary to Renal Failure**
  - With elevated PTH:
    - —Calcium level low
    - —Phosphate elevated
    - —Alkaline phosphatase elevated

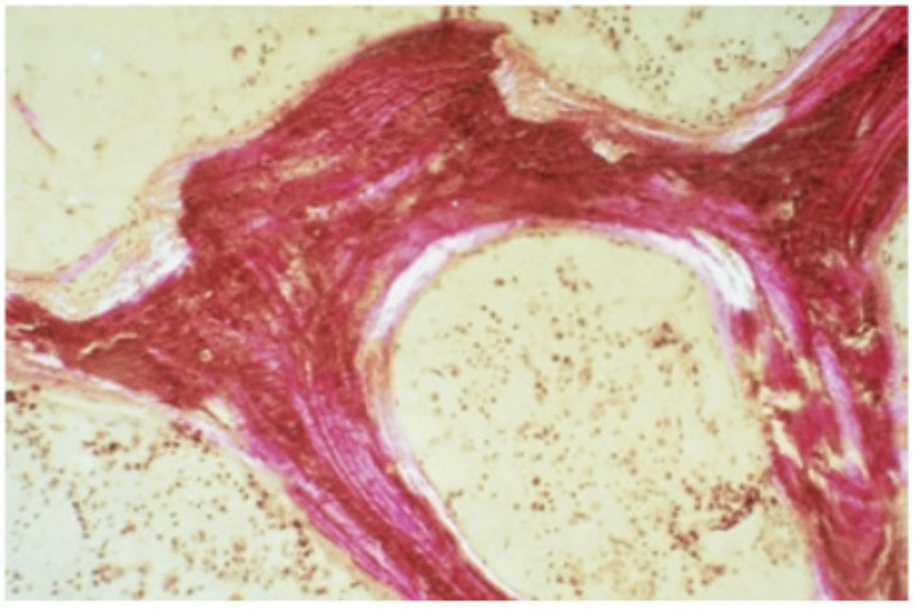

Wellcome Images

▲ **Figure 25–3.3** Osteomalacia

© DeVry/Becker Educational Development Corp. All rights reserved.

3.4 Rickets

- Vitamin D deficiency in children—epiphyseal growth plate *thickness increased* secondary to decreased calcification and excess accumulation of *osteoid matrix*.

Clinical Manifestations

- Rachitic rosary
- Skull: frontal bossing
- Harrison groove
- Pigeon breast
- Lumbar lordosis
- Bowing of legs

Wellcome Images/Custom Medical Stock Photo

▲ **Figure 25–3.4A** Rachitic Rosary

Biophoto Associates/Science Source

▲ **Figure 25–3.4B** Rickets: Bowing of Legs

3.5 Renal Osteodystrophy

- *Osteomalacia* secondary to chronic renal disease
- Decreased renal activation of vitamin D → hypocalcemia
- Phosphate retention > hyperphosphatemia > hypocalcemia
- Hypocalcemia > secondary hyperparathyroidism
- Hyperparathyroidism > osteoclastic activation > bone resorption
- *Entire skeleton affected*
- If left untreated results in von Recklinghausen disease of bone.
  - Mass of brown reactive tissue (due to hemosiderin)

▼ **Table 25–3.5** Osteoporosis and Osteomalacia

	Loss of Organic Matrix	Loss of Mineralized Bone	Pathologic Fractures
Osteoporosis	Yes	Yes	Yes
Osteomalacia (rickets in children)	No, increased	Yes	Yes

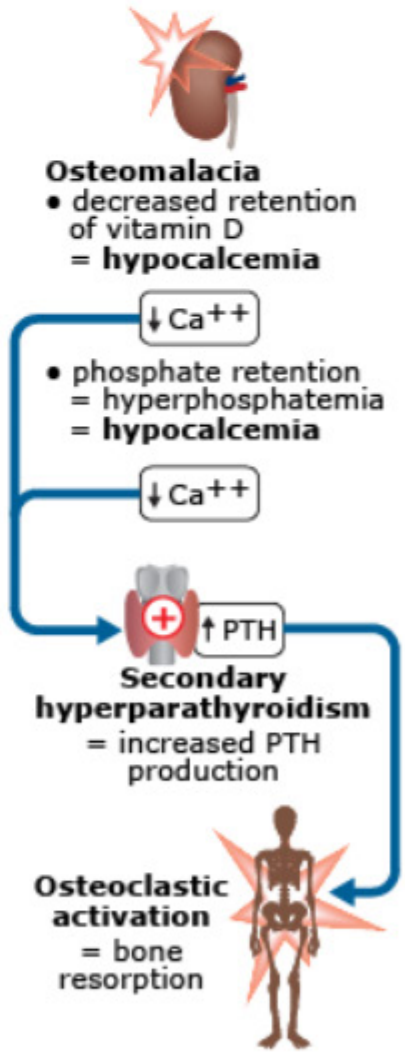

▲ **Figure 25–3.5** Renal Osteodystrophy

© DeVry/Becker Educational Development Corp. All rights reserved.

3.6 Paget Disease of Bone (Osteitis Deformans)

Skeletal disease marked by disordered bone resorption *(osteoclastic)* and bone formation *(osteoblastic)*.

- **Epidemiology:** Primarily occurs in men older than 50.
- **Etiology:** Reported associations with respiratory syncytial virus and paramyxovirus
- **Pathogenesis:** Two types and three stages
  - **Types**
    1. Monostotic
    2. Polyostotic

▼ **Table 25-3.6A** Stages of Paget Disease

Stage 1 **Early osteolytic stage** Causes a shaggy-appearing lytic lesion	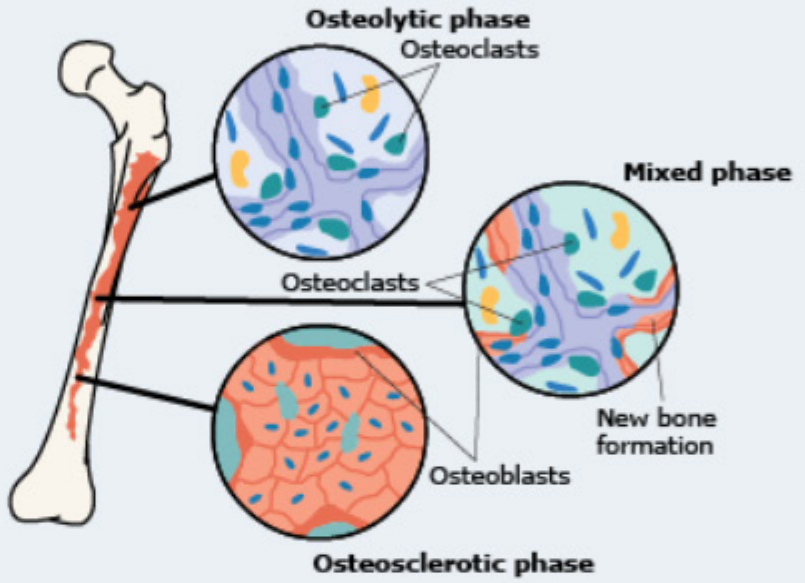 ▲ **Figure 25–3.6A** First Stage
Stage 2 **Mid-mixed osteoclastic-osteoblastic stage** Characteristic *mosaic* pattern	
Stage 3 **Late "burned-out" osteoblastic (osteosclerotic) stage** Lab findings: Marked increase in alkaline phosphatase (ALP)	 ▲ **Figure 25–3.6B** Third Stage

© DeVry/Becker Educational Development Corp. All rights reserved.

Clinical Features

- *Elevated alkaline phosphatase (ALP)*
- *Focal*: Usually affects bones of pelvis, spine, and skull.
- *Pain* due to microfractures and bone overgrowth that compress spinal and cranial nerve roots.
- *Hearing loss* (osteosclerosis)
- *Osteosarcoma* in 1% of cases
- Arteriovenous shunting and *high output heart failure* from hypervascularity of bones.
- Treat with bisphosphonates (inhibits osteoclasts)

▼Table 25-3.6B Expected Lab Findings in Metabolic Bone Disease

Bone Disease	Calcium	Phosphorus	Alkaline Phosphatase
Osteoporosis	Normal	Normal	Normal or decreased
Von Recklinghausen disease of bone	Increased	Decreased	Increased
Osteomalacia and rickets	Decreased or normal	Variable	Normal or mildly increased
Paget disease of bone	Normal	Normal	Significantly increased

© DeVry/Becker Educational Development Corp. All rights reserved.

4 Trauma

4.1 Osteonecrosis or Avascular (or Aseptic) Necrosis (AVN)

4.1.1 Clinical Features

- Disruption of microcirculation causes ischemia of bone
- Common sites of injury:
  - *Femoral head* and condyle
  - Humeral head
  - *Scaphoid* (navicular) and lunate bones of wrist
  - Talus bone located between the calcaneus and the distal tibia and fibula

4.1.2 Etiology

- Most common—fracture or idiopathic
- Second most common—long-term corticosteroid administration
- Alcohol
- Thrombosis (sickle cell disease, caisson disease)
- Legg-Calvé-Perthes disease (osteochondritis)
- Vasculitis
- Radiation injury

4.2 Fractures

4.2.1 Types of Fracture

- **Closed (simple) fractures** are those in which the skin is intact.
- **Open (compound) fractures** involve wounds that communicate with the fracture, or where the fracture hematoma is exposed, and may thus expose the bone to contamination. Open injuries carry a higher risk of infection. If angulation or displacement (fracture gap) is large, reduction (manipulation) of the bone may be required and, in adults, frequently requires surgical care. These injuries may take longer to heal than those without displacement or angulation.
- **Compression fractures** usually occur in the vertebrae, for example, when the front portion of a vertebra collapses due to osteoporosis.
- **Complete fractures** are those in which bone fragments separate completely.
- **Incomplete fractures** are those in which the bone fragments are still partially joined. In such cases, there is a crack in the osseous tissue that does not completely traverse the width of the bone.
- **Comminuted fractures** are those in which the bone has broken into a number of pieces.

© DeVry/Becker Educational Development Corp. All rights reserved.

- **Impacted fractures** occur when bone fragments are driven into each other.
- **Linear fractures** occur parallel to the bone's long axis.
- **Transverse fractures** occur at a right angle to the bone's long axis.
- **Oblique fractures** occur diagonally to a bone's long axis.
- **Spiral fractures** are those where at least one part of the bone has been twisted.

4.2.2 Femoral Head and Condyle

Common fracture in adults 65 and older.

- **Peritrochanteric fracture** is extracapsular and does not compromise blood supply to the femoral head; thus, it does not result in aseptic necrosis.
- **Subcapsular fracture** disrupts the blood supply, including retinacular arteries from medial circumflex femoral arteries; thus, aseptic necrosis does take place.

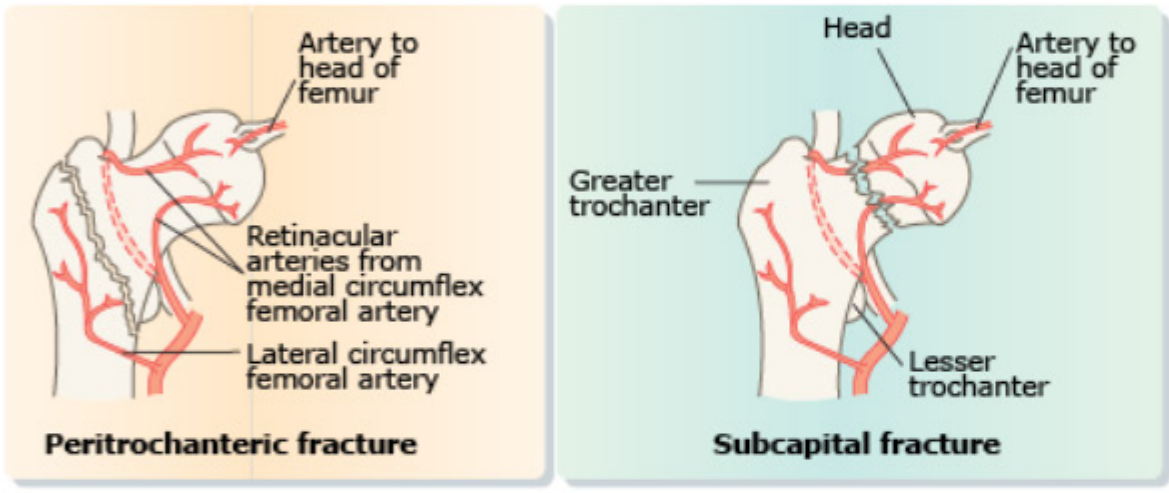

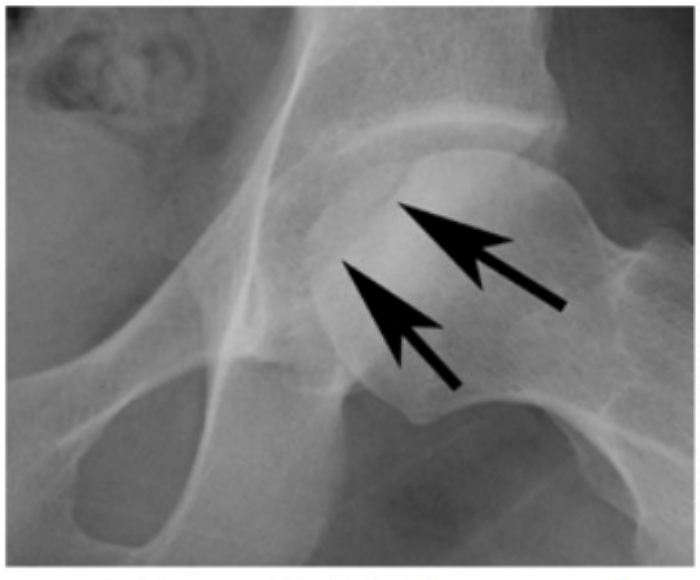

Bates, MD/Custom Medical Stock Photo

▲ **Figure 25–4.2A** Osteonecrosis

© DeVry/Becker Educational Development Corp. All rights reserved.

4.2.3 Fracture Repair

- Bone trauma ruptures blood vessels, releasing platelets, fibroblasts, and other inflammatory mediators.
- The clot forms a soft tissue callus.
- Mesenchymal cells released in the fracture differentiate into *chondroblasts,* synthesizing cartilage in the callus, enabling *endochondral ossification* of the fracture.
- With endochondral ossification, the soft callus develops into a bony callus.

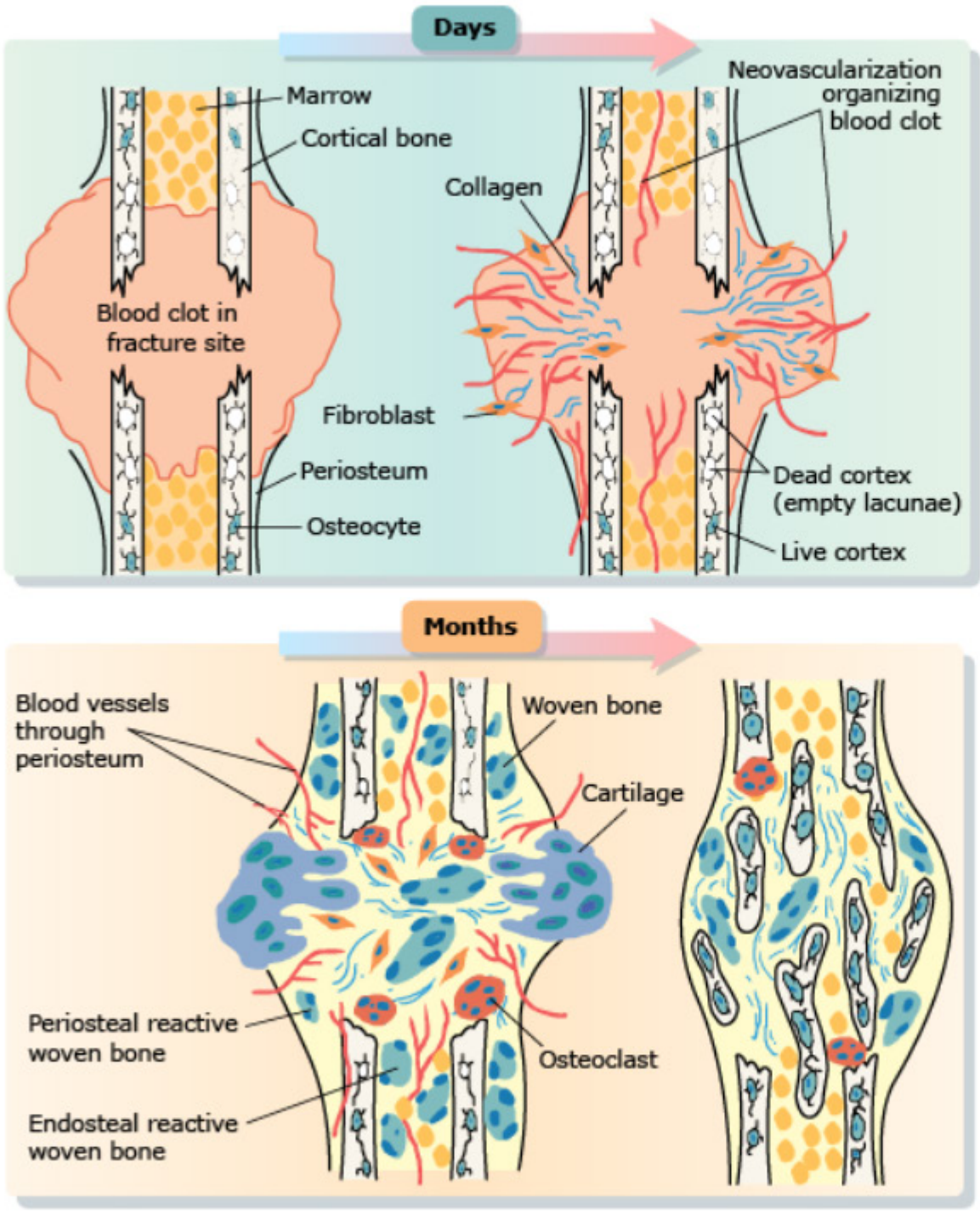

▲ **Figure 25–4.2B** Blood Clot and Fracture Site Over Time

© DeVry/Becker Educational Development Corp. All rights reserved.

5 Infection

5.1 Osteomyelitis

- Infection of bone or bone marrow with subsequent inflammatory response.
- Most commonly due to sepsis with subsequent hematogenous spread to the metaphysis of the bone.
- It may occur in children or adults, and favors the tibia and fibula in children.

Pathogenesis

- Devitalized bone is called *sequestra.*
- Chronic disease produces reactive bone formation in the periosteum called *involucrum.*

St. Mary's Hospital Medical School/Science Source/Custom Medical Stock Photo

▲ **Figure 25–5.1A** Osteomyelitis

5.1.1 Pyogenic Osteomyelitis

Etiology

▼ **Table 25-5.1** Osteomyelitis

Patient Population	Most Common Causal Organism
Adults	*Staphylococcus aureus* (90%)
Neonates	*Haemophilus influenzae,* group B Streptococci
Sickle cell disease	*Salmonella paratyphi*
Direct implant (puncture wounds from nails or syringes)	Most commonly due to *Pseudomonas aeruginosa*
50%	No organism isolated

© DeVry/Becker Educational Development Corp. All rights reserved.

Clinical Features

- Malaise, fever, leukocytosis, pain
- Radiologic—destructive lytic focus, sclerotic rim
- Blood cultures/*bone biopsy*—gold standard
- 25% persist as chronic infections:
  - Delay in diagnosis
  - Extensive bone necrosis
  - Abbreviated antibiotic therapy
  - Inadequate surgical debridement
  - Poor host defenses

Complications

- Chronic osteomyelitis
  - Acute flare-ups
  - Pathologic fracture
- Amyloidosis
- Endocarditis (following sepsis)
- Squamous cell carcinoma in sinus tract
- Osteosarcoma

5.1.2 Tuberculous Osteomyelitis

- Usually solitary lesions.
  - Destruction of the adjacent intervertebral disk is characteristic.
- Spine *(Pott disease)*, knees, and hips are common sites of involvement.

ISM/Phototake, Inc.

▶ **Figure 25–5.1B** Tuberculous Osteomyelitis

© DeVry/Becker Educational Development Corp. All rights reserved.

6 Bone-Forming Tumors

6.1 Osteoma

A benign tumor that projects from the subperiosteal or endosteal surfaces of the cortex.

Clinical Features

- Usually solitary
- Slow-growing
- May obstruct sinus cavity or impinge on brain
- Middle-aged adults
- Associated with *Gardner* syndrome
  - *SOD*: *S*ebaceous cysts, *O*steomas, *D*esmoid tumors
  - *APC* gene dysfunction, *5q21*

Pathology

Woven and lamellar bone deposited on cortical surface, usually of skull or facial bones.

6.2 Other Benign Bone-Forming Tumors

▼**Table 25-6.2** Benign Bone-Forming Tumors

	Osteoid Osteoma	Osteoblastoma
Patient population	Age <25 years; men > women 2:1	80% in people under 30; men > women 2:1 or 3:1
Pathology	Cortex of appendicular bones (femur, *tibia*)	Spinal involvement, well circumscribed • Randomly interconnecting trabeculae of woven bone • Appears radiographically as a variably mineralized small lucency
Clinical picture	Severe nocturnal pain due to excess *prostaglandin* E_2 production, relieved by *aspirin* (classic)	Dull and achy pain, not due to PGE_2 and not relieved by aspirin
Size	Less than 1.5 cm	Osteoblastoma larger (>2 cm)
Prognosis	Excellent with radiofrequency ablation	Excellent with complete excision

© DeVry/Becker Educational Development Corp. All rights reserved.

6.3 Osteosarcoma

- Malignant bone-forming tumor (produces bone matrix called osteoid).
- Most common primary malignant tumor of bone.
- Bimodal age distribution, men > women
  - <20 (75%; arise in metaphysis of long bones, tibia and femur near knee)
  - Elderly (associated with Paget, infarcts, and prior irradiation; equal incidence in flat and long bones)

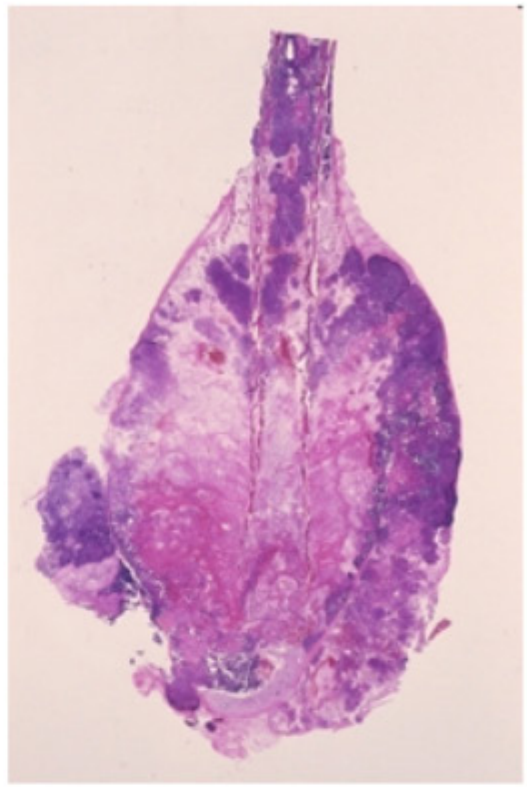
Patricia Barber, RBP/Custom Medical Stock Photo

▲ **Figure 25–6.3A** Osteoid Osteoma

Pathogenesis

- Hereditary retinoblastoma.
- Abnormalities in genes that regulate cell cycling; usually develop in sites of bone growth.
- TP53 mutations in sporadic sarcomas.

Clinical Features

- Painful, enlarging mass.
- Pathologic fracture.
- *Codman triangle* on x-ray: Triangular shadow between cortex and raised ends of periostium.

Prognosis

- Long-term survival is 60%; poor with secondary osteosarcoma.

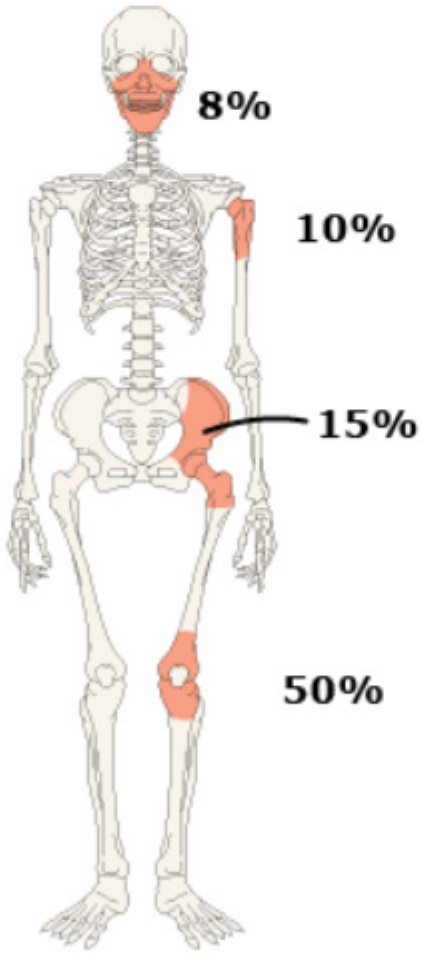

▲ **Figure 25–6.3B** Osteosarcoma

© DeVry/Becker Educational Development Corp. All rights reserved.

7 Cartilage-Forming Tumors

▼ **Table 25-7.0** Cartilage Forming Tumors

Condition	Benign/ Malignant	Description
Osteochondroma	Most common benign tumor of bone	Bony projection from surface of bone covered by a *cap of cartilage.* **Men > women 3:1** 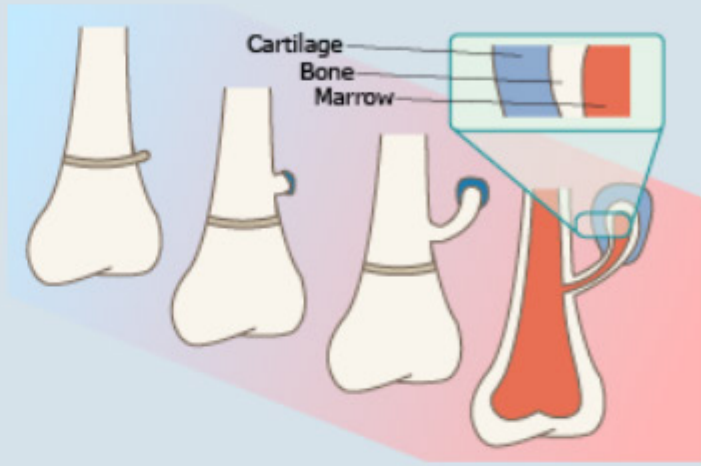 ▲ **Figure 25–7.0A**
Enchondroma	Benign tumor of cartilage	Age 20 to 40 years. Solitary tubular bones of the *extremities.* Multiple enchondromas increase the risk for chondrosarcoma. X-ray: Ring sign (oval lucency surrounded by rim of dense bone). 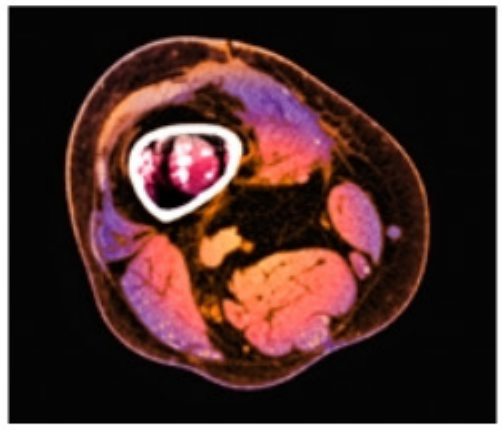 ▲ **Figure 25–7.0B** ▲ **Figure 25–7.0C**
Chondrosarcoma	Malignant cells producing cartilage	May arise from preexisting enchondroma. Age > 40 years Men > women 2:1 Clinical features • Arise in central (axial) portions of skeleton, including pelvis, shoulder, and ribs (versus chondroma in distal extremities). • Present as progressively painful enlarging masses.

Credits (top to bottom): Wellcome Images; Guilloz-Chu Nancy/Phanie/SuperStock

© DeVry/Becker Educational Development Corp. All rights reserved.

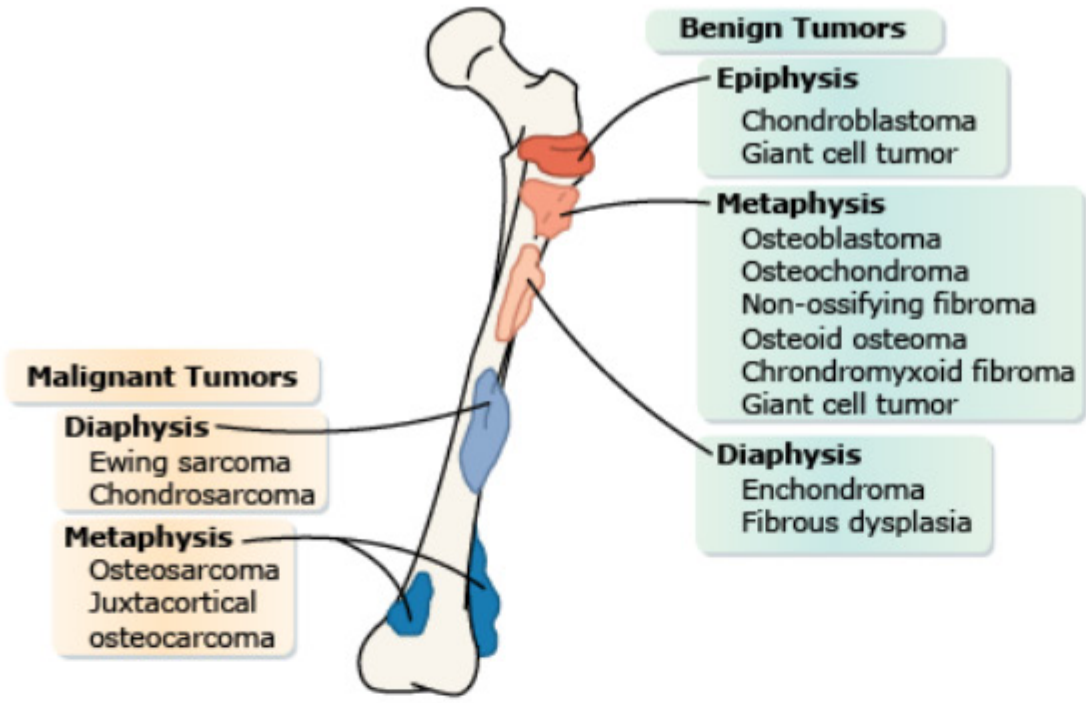

▲ **Figure 25–7.0D** Tumors

8 Fibrous and Other Tumors

8.1 Fibrous Dysplasia

- Benign, tumor-like lesion characterized by replacement of bone with fibrous tissue
- Young patients (adolescents)
- McCune-Albright Syndrome is a condition seen in young girls who present with sporadic hyperpigmented macular patches of the skin (cafe-au-lait spots), polyostitic involvement in the form of fibrous dysplasia, and one if not many types of endocrinopathies listed below:
  - Precocious puberty
  - Hyper-thyroid/parathyroidism
  - Pituitary adenoma
  - Adrenal adenoma

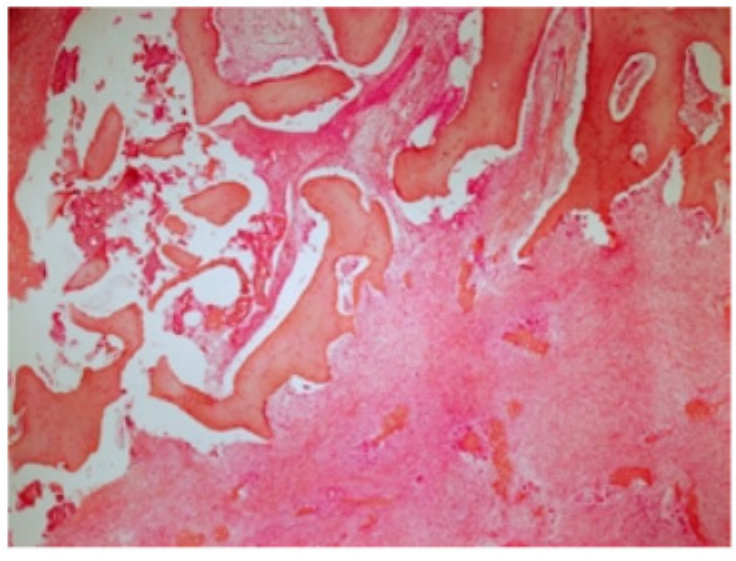

ISM/Phototake, Inc.

▲ **Figure 25–8.1** Fibrous Dysplasia

© DeVry/Becker Educational Development Corp. All rights reserved.

8.2 Primitive Neuroectodermal Tumor/ Ewing Sarcoma

- Malignant *small, round, blue cell bone tumor* (looks like lymphoma)
- Two tumors differing in degree of differentiation

Clinical Features

- Age <20
- Painful, enlarging mass in *diaphysis* of long bone: Femur and flat bones of pelvis
- Painful, enlarging mass
- Early stages mimic acute osteomyelitis
- 11;22 translocation (EWS gene moved adjacent to FLI-1)

Pathology

- Soft tissue mass from invasion through cortex and periosteum
- Sheets of uniform small, round cells that are slightly larger than lymphocytes
  - **Homer-Wright Rosettes**
    - Neural differentiation
    - Presence of 20% indicates PNET

Ewing Tumor

- Differential diagnosis
- Other small cell tumors
  - Neuroblastoma
  - Lymphoma
- Prognosis
  - Five-year survival is 75%

ISM/Phototake, Inc.

▲ **Figure 25–8.2**
Ewing Tumor

8.3 Giant Cell Tumor

- Tumor of multinucleated osteoclast type giant cells
- Age 20 to 40 years
- Arise near the knee
- Appear lytic on x-ray
- Locally aggressive

9 Metastatic Diseases

- Most common form of skeletal malignancy.
- Primary malignancies in adults arise in:
  - **B**reast (mixed)
  - **L**ung (mixed)
  - **T**hyroid (lytic)
  - **K**idney (lytic)
  - **P**rostate (blastic)
- Can involve any location but axial skeleton most common.

Memory Aid

BLT with **K**osher **P**ickles ...
(most common neoplasms which metastasize to bone)

Breast, **L**ung, **T**hyroid, **K**idney, **P**rostate

© DeVry/Becker Educational Development Corp. All rights reserved.

1 Classification of Muscle Fiber Type and Innervation

▼ **Table 26–1.0** Muscle Twitch

Characteristic	Type I: Slow Twitch	Type II: Fast Twitch
Myoglobin, mitochondria, oxidative enzymes	Rich	Poor
ATPase enzymes	Poor	Rich
Speed and duration of contraction	Slow, repetitive	Fast, early fatigue
Fatigue	Slowly	Quickly
Example	Long muscles in back	Extraocular muscles, muscles in hand

- Cardiac
- Smooth
- Skeletal
  - Striated
  - Voluntary

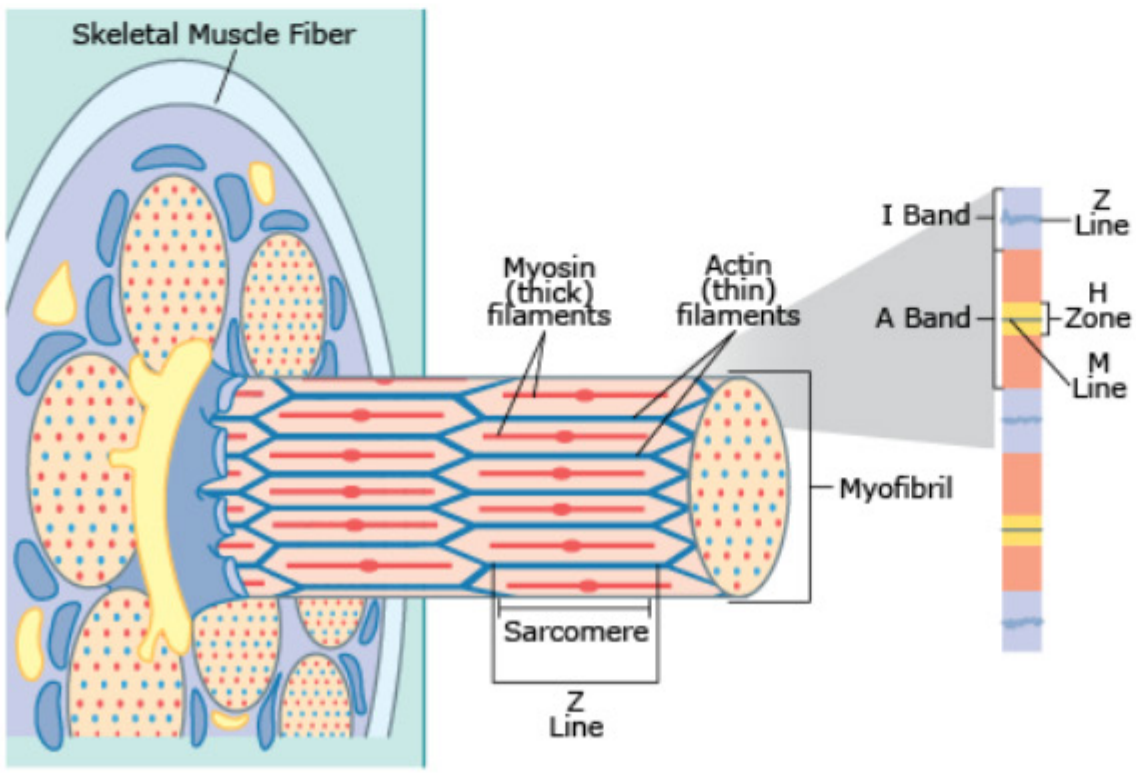

▲ **Figure 26–1.0A** Skeletal Muscle Fiber (part 1)

USMLE® Key Concepts

For Step 1, you must be able to:

- Diagnose and differentiate the common forms of muscular dystrophy (Duchenne, Becker, myotonic) and explain their molecular basis and inheritance.
- Understand the pathogenesis and treatment of myasthenia gravis and Lambert-Eaton myasthenic syndrome.

© DeVry/Becker Educational Development Corp. All rights reserved.

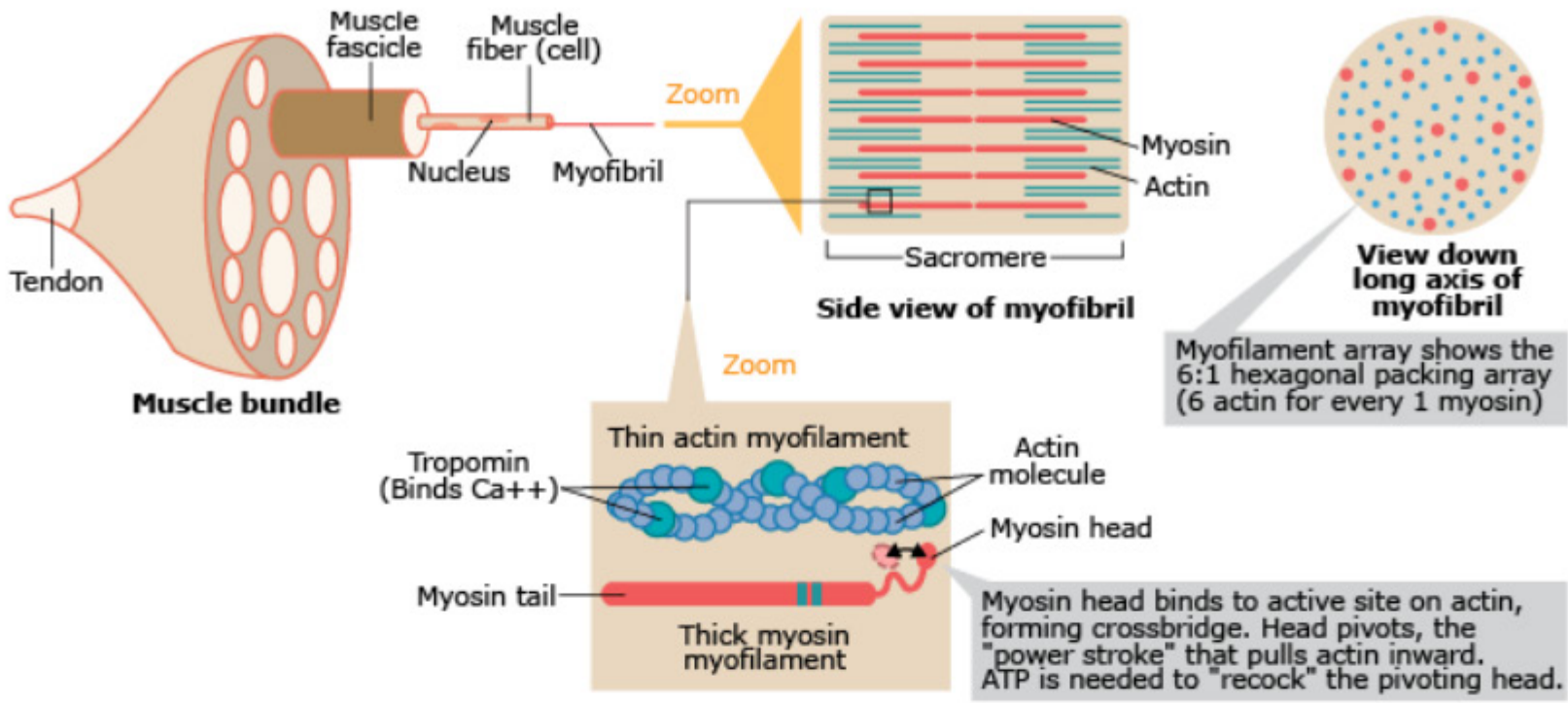

▲ **Figure 26–1.0B** Skeletal Muscle Fiber (part 2)

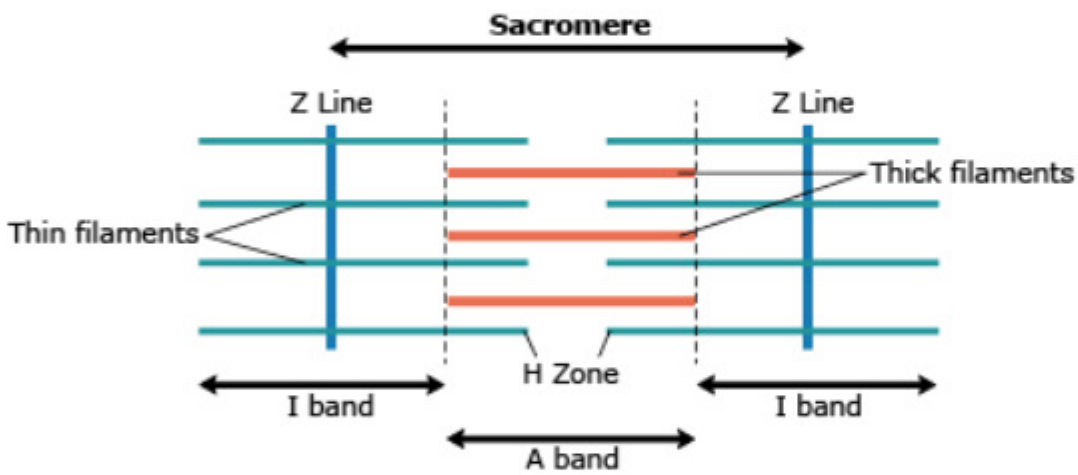

▲ **Figure 26–1.0C** Skeletal Muscle Fiber (part 3)

Connection to Physiology

See *Physiology*, chapter 8, "Exitation-Contraction Coupling."

© DeVry/Becker Educational Development Corp. All rights reserved.

2 Muscular Dystrophies

Muscular dystrophies are a group of genetically determined progressive disorders which are characterized by the degeneration of skeletal muscle with profound wasting and weakness. They cause increased serum creatinine kinase and other muscle enzymes, and are differentiated by age of onset, muscles involved, and mode of inheritance. On biopsy, there are nonspecific degenerative changes, including replacement by fibrofatty tissue.

2.1 Duchenne Muscular Dystrophy (DMD)

- One per 3,500 live male births
- Progressive weakness
- Wheelchair dependence by age 10 to 12 years
- Most common and most severe muscular dystrophy
- Deficiency in *dystrophin* (p arm of chromosome X);
  - X-linked recessive inheritance (majority)
  - One third result from de novo mutations *(frameshift)*
- No dystrophin produced
- Elevated serum creatinine kinase
- Female carriers
- High serum creatinine levels
- Cardiomyopathy risk
  - Also for patients who survive long enough
- Manifests by *age 1 year* with weakness in shoulder and pelvic girdle muscles (proximal).
- Initial compensatory hypertrophy of distal sites (calf) followed by *pseudohypertrophy* (increase in fat and connective tissue).
- Progressive immobilization, death secondary to *pneumonia* in teen years.
- Characterized by random variation in muscle fiber size, necrosis of individual fibers with replacement by fatty tissue.
- *Gowers sign*

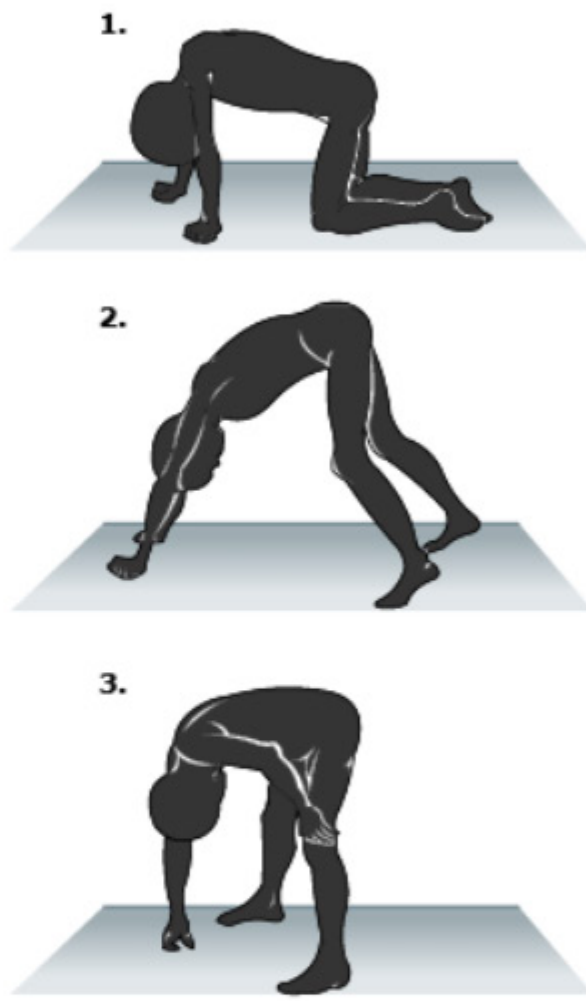

Mode of rising from the ground in pseudohypertrophic muscular paralysis

▲ **Figure 26–2.1A** Duchenne Muscular Dystrophy

© DeVry/Becker Educational Development Corp. All rights reserved.

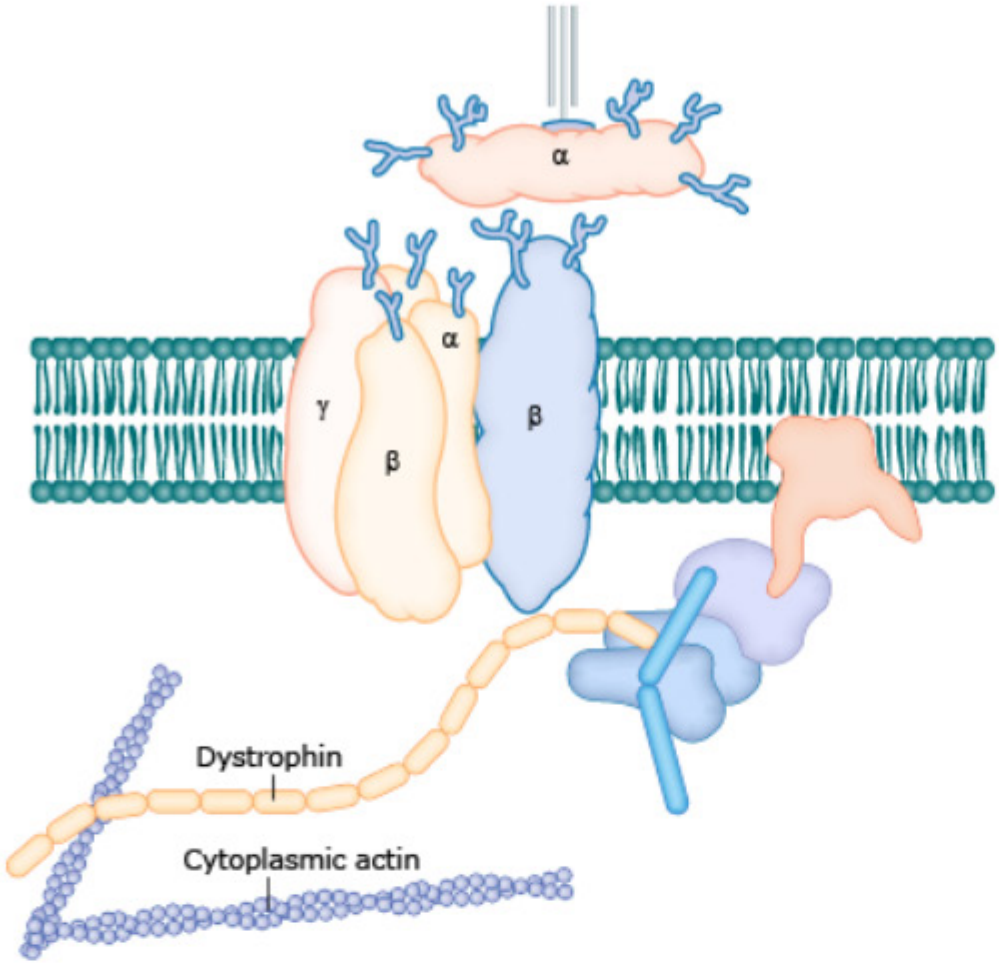

▲ **Figure 26–2.1B** Dystrophin

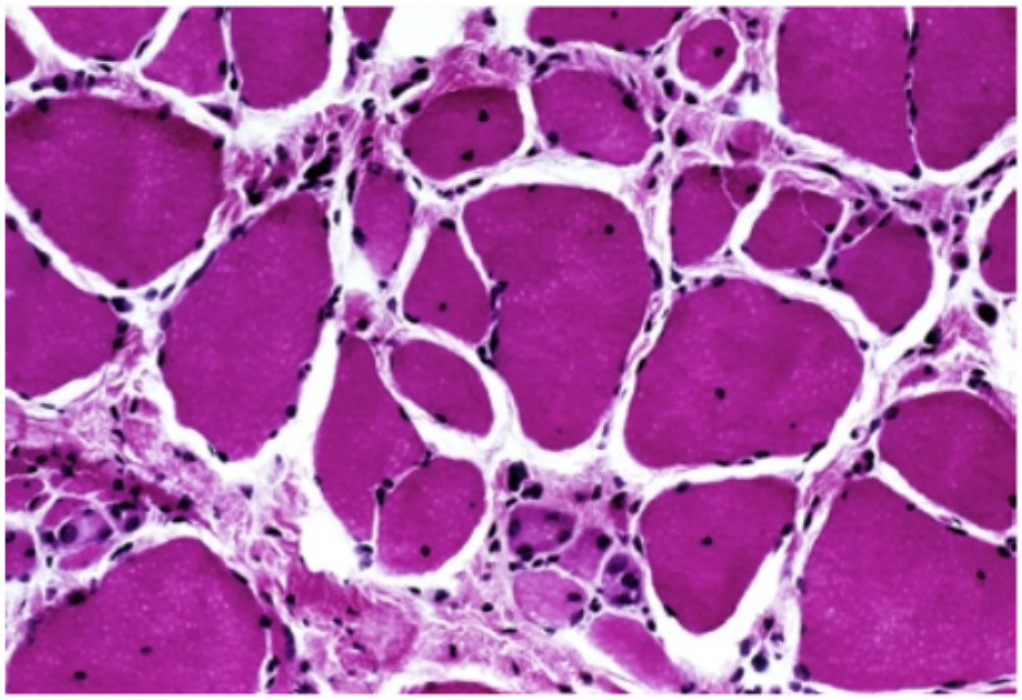

Biophoto Associates/Science Source

▲ **Figure 26–2.1C** Duchenne Muscular Dystrophy/Variation in Muscle Fiber Size

© DeVry/Becker Educational Development Corp. All rights reserved.

2.2 Becker Muscular Dystrophy

- Similar to Duchenne but less severe
- *Deletions* in dystrophin gene (as opposed to frameshift)
- *Some functional dystrophin is produced*, thus clinically less severe
- Age of onset 8 to 25 years old
- Unable to walk by age 25

2.3 Myotonic Dystrophy

- **Definition:** Weakness with sustained involuntary contraction of muscle (myotonia).
  - Atrophy of type I muscle fibers

Pathogenesis

- Autosomal dominant inheritance
- Mutation of gene for myotonin protein kinase on chromosome 19q13.2-13.3
- Increased trinucleotide repeats (CTG >30)
- Shows anticipation

Clinical Features

- Presents in late childhood.
- Gait abnormalities due to weakness of foot dorsiflexors.
- Grip myotonia (sustained grip)
- Percussion myotonia can be elicited by percussion of thenar eminence.
- Cataracts
- *Frontotemporal balding*
- Testicular atrophy
- Cardiomyopathy
- *Hatchet facies*

Welcome Images/Custom Medical Stock Photo

▲ **Figure 26–2.3A** Myotonic Dystrophy

© DeVry/Becker Educational Development Corp. All rights reserved.

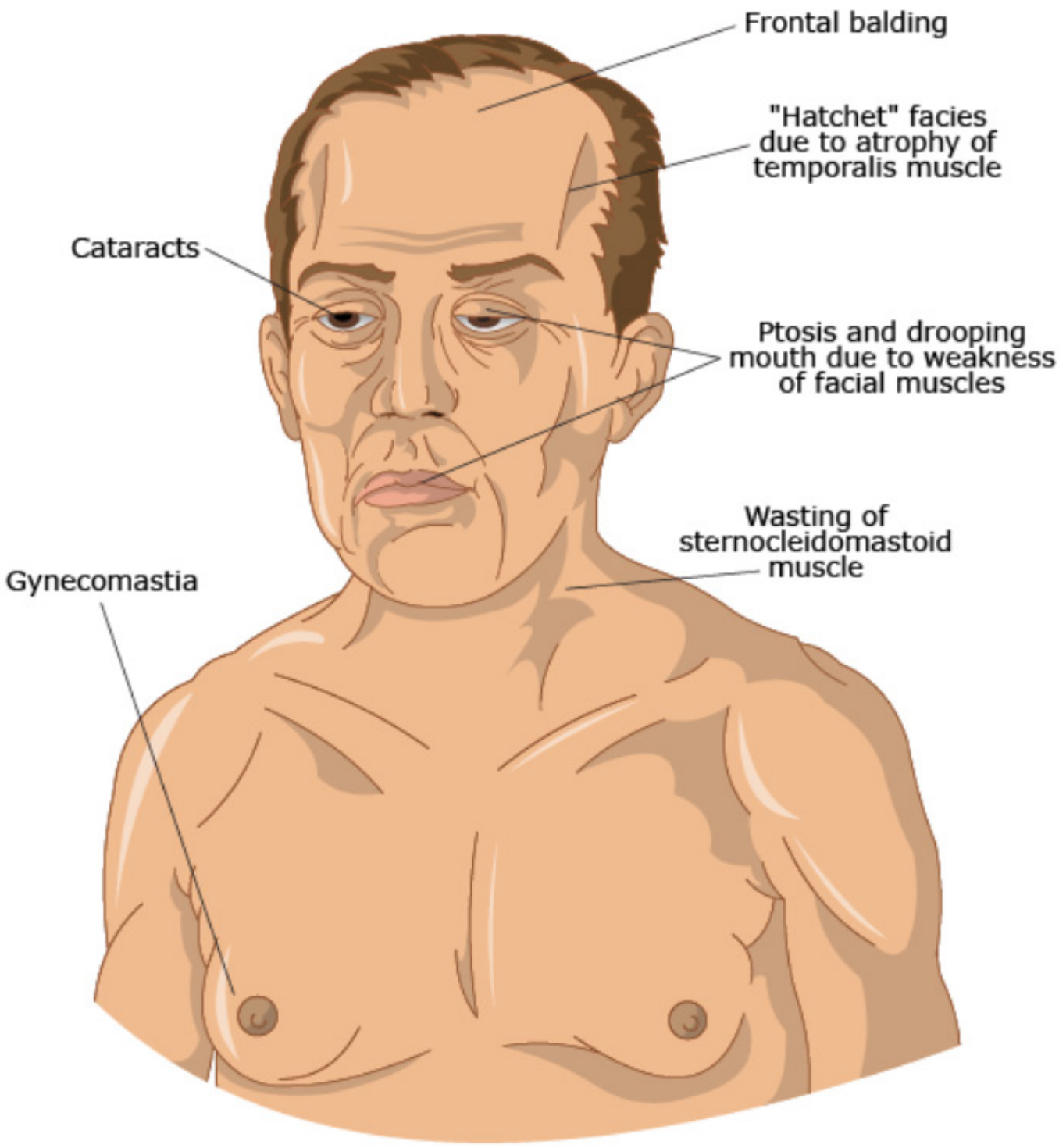

▲ **Figure 26–2.3B** Myotonic Dystrophy

© DeVry/Becker Educational Development Corp. All rights reserved.

3 Diseases of the Neuromuscular Junction

3.1 Myasthenia Gravis

- **Definition:** Muscle disease caused by *antibody-mediated* destruction of *acetylcholine receptors*.
- Weakness *intensified* by use, *recovers* on rest.
- 30 in 100,000
- Prevalence greater in women under 40 years old.
  - Gender-neutral in older age groups.

Pathogenesis Circulating antibodies bind to acetylcholine receptors.

- Considered a Type II non-cytotoxic hypersensitivity reaction
- Associations: *thymic hyperplasia and thymoma*

Pathology

- Type 2 muscle fiber atrophy (nonspecific finding)
- Simplification of motor end plate

Clinical Features

- Weakness of extraocular muscles
- Ptosis—often first symptom
- Diplopia
- Improvement in strength with anticholinesterase agents

Diagnosis

- Tensilon (edrophonium) test: Inhibits acetylcholinesterase; increase in synaptic acetylcholine reverses muscle weakness. Single-fiber electromyography (abnormal in 95% of cases of myasthenia gravis).

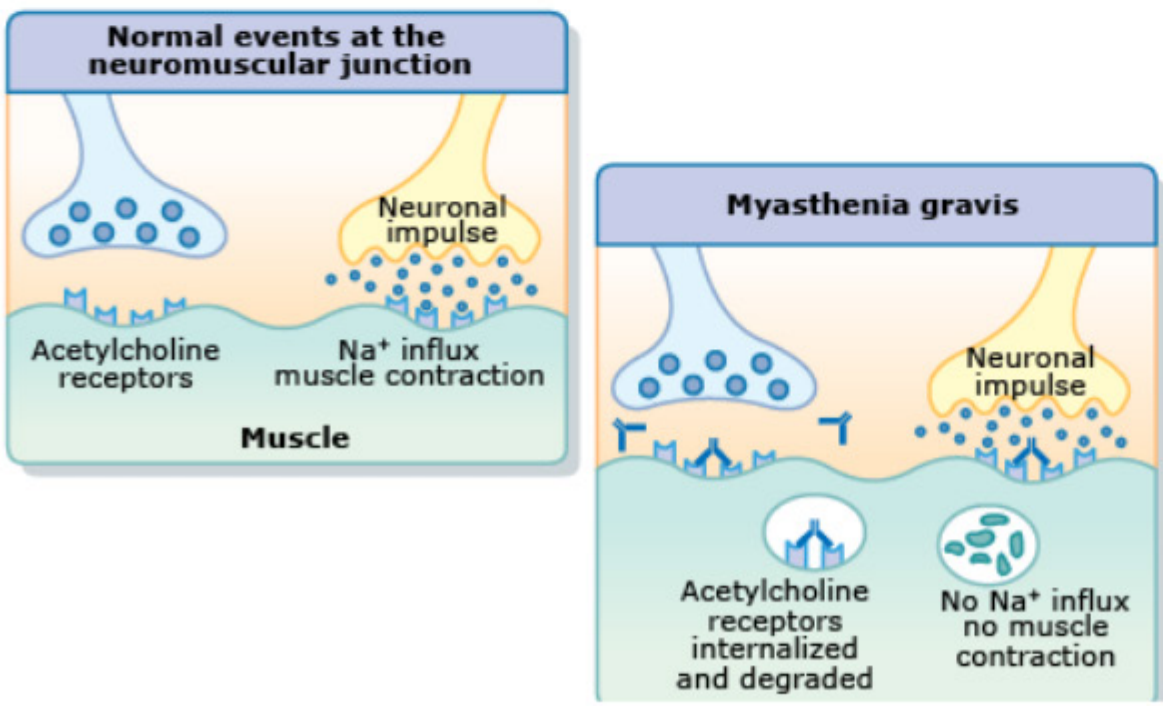

▲ **Figure 26-3.1** Diseases of Neuromuscular Junction

Connection to Pharmacology

Treatment of Myasthenia Gravis

- **Pyridostigmine** (acetylcholinesterase inhibitor)
- **Immunosuppressive drugs** Corticosteroids; azathioprine; cyclosporine
- **Plasmapheresis** (short-term treatment; removes antibodies)
- **Thymectomy**—unknown relationship with disease
- Avoid certain medications: β-blockers; aminoglycosides; quinolone antibiotics; class 1 antiarrhythmics

© DeVry/Becker Educational Development Corp. All rights reserved.

3.2 Lambert-Eaton Myasthenic Syndrome

- Paraneoplastic syndrome: Small cell (oat cell) carcinoma of lung
- Antibodies to *presynaptic (voltage-gated) calcium channels* causing defect in acetylcholine release
- Proximal muscle weakness and symptoms similar to myasthenia gravis
- Autonomic dysfunction
- Differentiation from MG
  - Shows *improvement with repeated use*, as opposed to fatigue in MG
  - *No improvement* with acetylcholinesterase agents

3.3 Dermatomyositis

- Skin plus muscle (skin may be first)
- Heliotrope rash (plus periorbital edema)
  - Grotton lesions (red patches over knuckles)
- Muscle weakness, proximal muscles early
- Slow onset
  - Dysphagia in 30%
  - Extramuscular manifestations

▲ **Figure 26-3.3** Heliotrope Rash

© DeVry/Becker Educational Development Corp. All rights reserved.

1 Overview of Connective Tissue Tumors

▼ **Table 27–1.0** Connective Tissue Tumors

Tissue	Tumor Prefix
Fat	Lipo-
Fibroblasts	Fibro-
Muscle (smooth)	Leiomyo-
Muscle (striated)	Rhabdomyo-
Nerves	Neuro-
Bone	Osteo-
Cartilage	Chondro-

USMLE® Key Concepts

For Step 1, you must be able to:

- Identify the common benign and malignant tumors of fat, fibroblast, and muscle at the clinical and histological level.
- Explain the molecular basis of pathogenesis for each of these diseases.

2 Tumors of Fat Tissue

2.1 Benign

2.1.1 Lipomas

- Benign tumor of mature fat
- Most common soft tissue tumor of adulthood
- Well-encapsulated mass most often in subcutis of proximal extremities or trunk
- Soft, mobile, and painless

2.2 Malignant

2.2.1 Liposarcoma

- Most common sarcoma of adults
- Almost never seen in children
- Ages 40 to 60 years
- Arise in deep tissues of proximal extremities and retroperitoneum
- Have characteristic lipoblasts—lipid vacuoles indent central nucleus

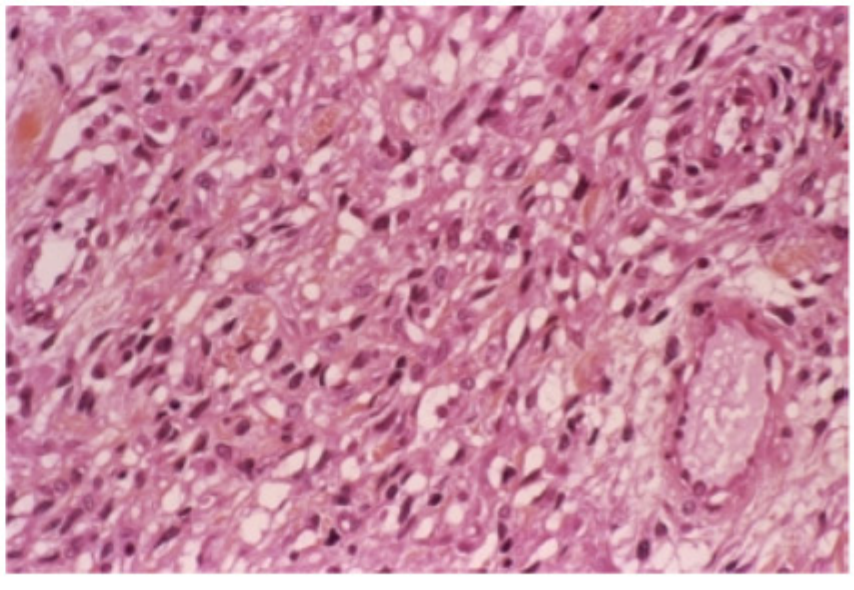

CNRI/Science Source

▲ **Figure 27–2.2** Liposarcoma

© DeVry/Becker Educational Development Corp. All rights reserved.

3 Tumors of Fibroblasts

3.1 Nodular Fasciitis

- Reactive *pseudosarcoma* consisting of plump fibroblasts
- Solitary, *rapidly growing* mass on forearm (patient may give history of trauma)
- Increased mitotic activity
- Myxoid background

3.2 Superficial Fibromatosis

- Poorly defined fascicles of mature-appearing fibroblasts surrounded by abundant dense collagen
  - Dupuytren contractures: palmar
  - Peyronie disease: penile

Ralph Hutchings/Visuals Unlimited, Inc.

▲ **Figure 27–3.2** Superficial Fibromatosis

3.3 Deep-Seated Fibromatosis "Desmoid Tumors"

- Same histologic finding as superficial fibromatosis
- Categories
  - Extra-abdominal
    — Shoulder, chest wall, back, and thigh
  - Intra-abdominal
    — Occur in mesentery or pelvic walls
    — Patient with familial adenomatous polyposis *(Gardner syndrome)*

3.4 Fibrosarcoma

- Malignant tumor composed of fibroblasts and collagen
- Middle-aged and elderly
- Deep soft tissues
- Fleshy mass of malignant fibroblasts arranged in "herringbone" pattern

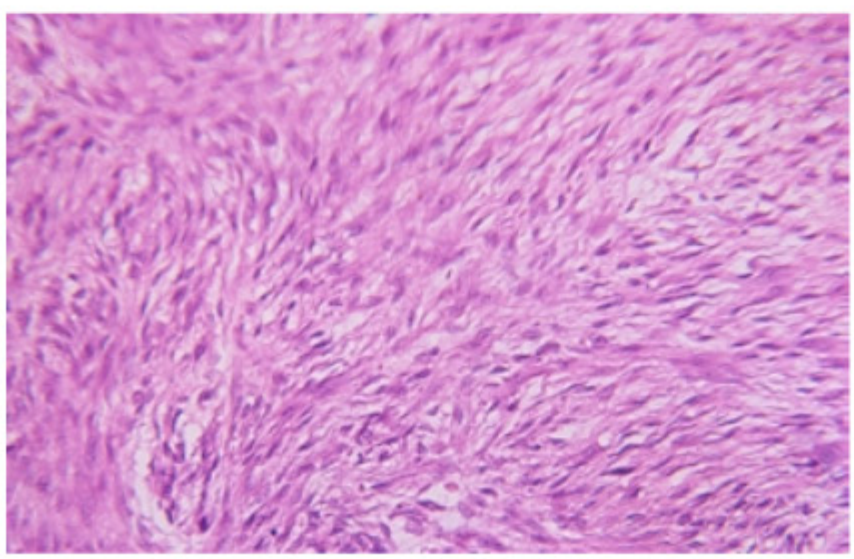
Biodisc/Visuals Unlimited, Inc.

▲ **Figure 27–3.4** Fibrosarcoma

© DeVry/Becker Educational Development Corp. All rights reserved.

4 Tumors of Muscle

4.1 Leiomyoma

- *Benign* smooth muscle tumor
- Often arises in uterus, can arise in deep soft tissues
- *Should have fewer than 10 mitoses per 10 high-power fields.*

CNRI/Science Source

▲ **Figure 27–4.1** Benign Smooth Muscle Tumor

4.2 Leiomyosarcoma

- *Malignant* smooth muscle tumor
- Develops in skin and deep soft tissues of extremities and retroperitoneum
- Painless, firm mass
  - Malignant spindle cells with cigar-shaped nuclei
  - Arranged in interweaving fascicles

© DeVry/Becker Educational Development Corp. All rights reserved.

4.3 Rhabdomyosarcoma

- *Malignant* tumor of skeletal muscle
- Most common soft-tissue sarcoma of childhood
- Patients less than 20 years old
- Usually occurs in head and neck or GU tract
- Identify classic rhabdomyoblast

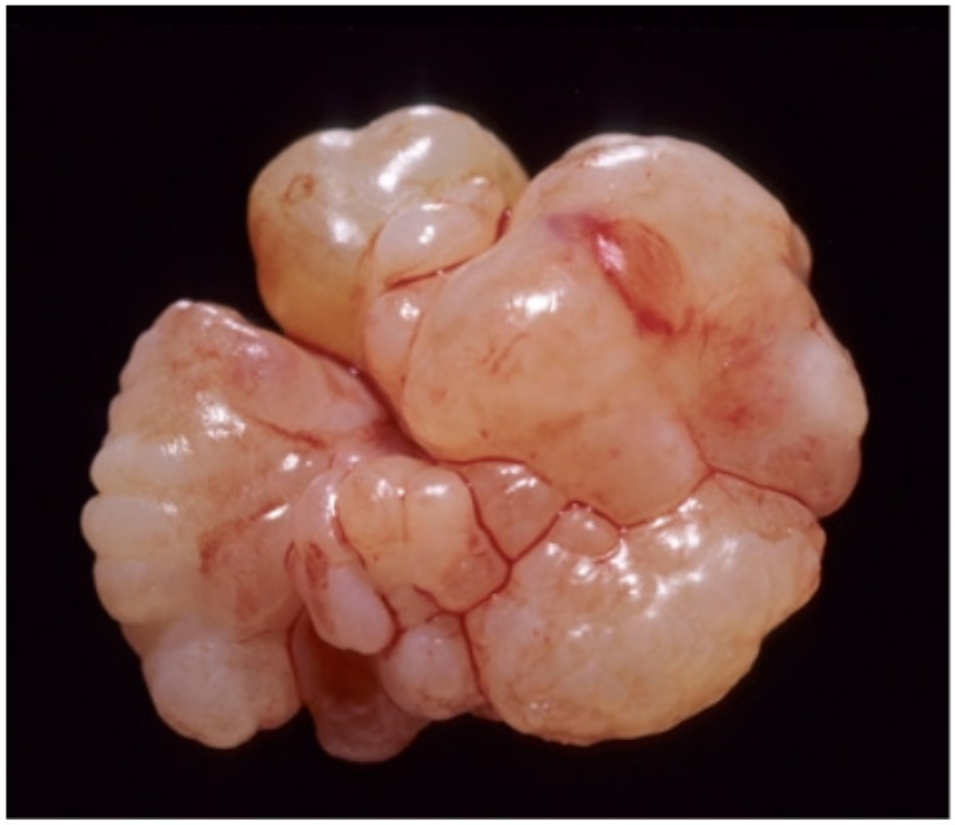

▲ **Figure 27–4.3** Rhabdomyosarcoma

© DeVry/Becker Educational Development Corp. All rights reserved.

Unit 12

Dermatology

1 Overview and Terminology

In dermatology, a diagnosis depends on macroscopic and microscopic *morphology* and the need to be accurate and consistent with descriptive terms.

1.1 Dermatologic Findings: Macroscopic Descriptors

- **Macule:** Flat, circumscribed discoloration
- **Papule:** Elevated area ≤1 cm
- **Nodule:** Raised solid lesion >1 cm
- **Plaque:** Raised lesion with flat top >1 cm
- **Vesicle:** Clear fluid-filled lesion <1 cm
- **Pustule:** Raised lesion with purulent contents
- **Bulla:** Clear fluid-filled lesion >1 cm
- **Wheal (Hives):** Pruritic raised lesion without scale but with surrounding blanching and erythema

Dr. P. Marazzi/Science Source

Pustule

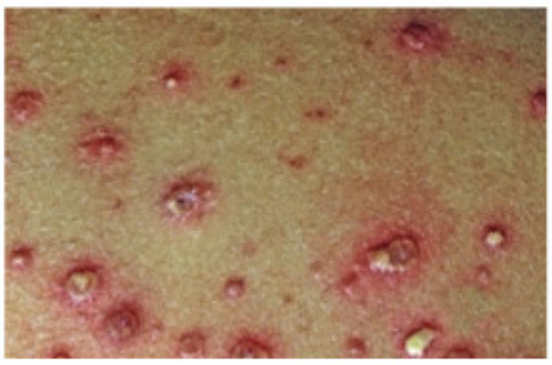
James Cavalini/Science Source

Vesicle

Dr. P. Marazzi/Science Source

Nodule

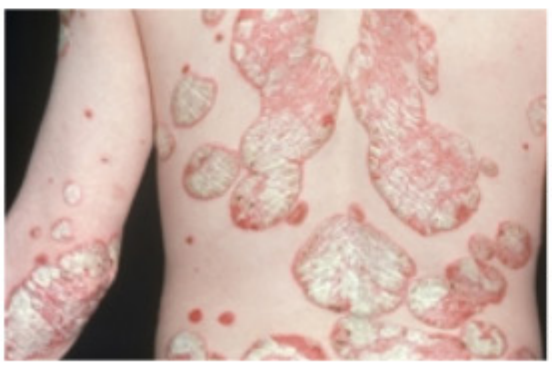
Biophoto Associates/Science Source

Plaque

Dr. P. Marazzi/Science Source

Wheal

▲ **Figure 28–1.1A** Macroscopic Dermatologic Findings

USMLE® Key Concepts

For Step 1, you must be able to:

- Describe dermatologic findings of both micro- and macroscopic nature.
- Recognize infectious diseases of the skin, including viral, bacterial, and fungal.
- Identify inflammatory diseases.
- Identify neoplasms ("growths").

Memory Aid

If you close your eyes and feel it, it is *not* **macule**.

Important Concept

Macule and **papule** are often put together and referred to as **maculopapular** rash.

© DeVry/Becker Educational Development Corp. All rights reserved.

1.2 Dermatologic Findings: Microscopic Descriptors

- **Hyperkeratosis:** Increased stratum corneum (SC)
- **Orthokeratosis:** Increased basket-like pattern of SC
- **Parakeratosis:** Retention of nuclei in SC
- **Acanthosis:** Hyperplasia of keratinocytes in epidermis
- **Acantholysis:** Loss of desmosomal connections between keratinocytes

© DeVry/Becker Educational Development Corp. All rights reserved.

2 Infectious Diseases

2.1 Viral

2.1.1 Verruca (Warts)

Etiology Human Papillomavirus

Morphology

- **Macroscopic Features:** Typical papular/nodular lesions referred to as verrucous. Condyloma acuminatum are warts found in the genital and anal region.
- **Microscopic Features:** Include epidermal hyperplasia with cytoplasmic vacuolization with an atypical hyperchromatic nuclei collectively called *koilocyte*.

Biophoto Associates/Science Source

▲ **Figure 28–2.1A** Verruca

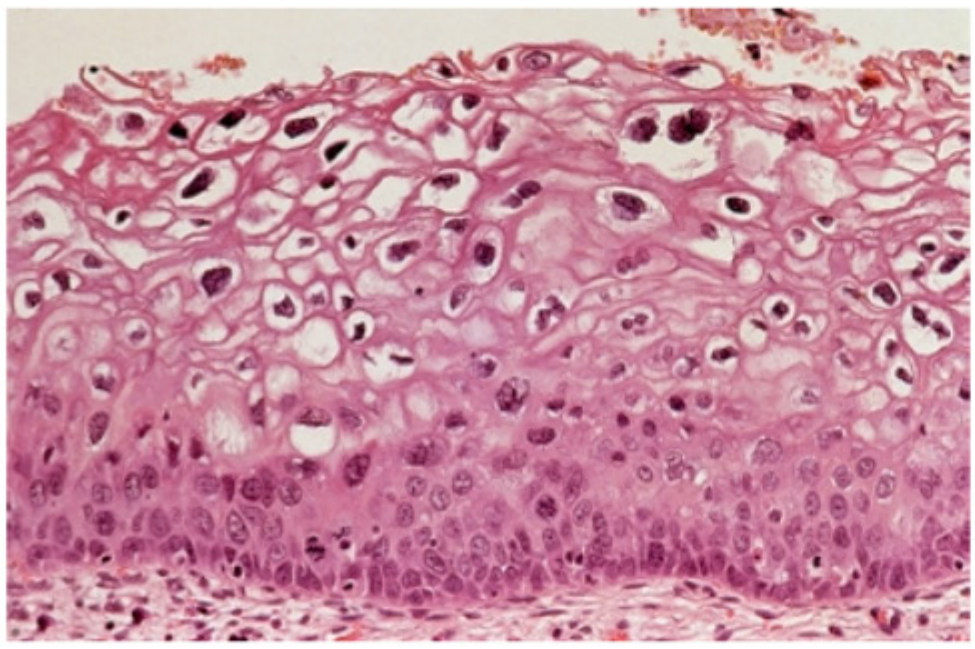

Wellcome Images

▲ **Figure 28–2.1B** Koilocytes

© DeVry/Becker Educational Development Corp. All rights reserved.

2.1.2 Molluscum Contagiosum

Etiology/Pathogenesis Caused by poxvirus. Self-inoculation by scratching infective viral particles from the crater into the periphery.

Morphology

Papular lesions with central *umbilication*.

Eosinophilic viral particles (molluscum bodies).

Dr. P. Marazzi/Science Source

▲ **Figure 28–2.1C** Molluscum Contagiosum

2.2 Bacterial

2.2.1 Impetigo

Etiology *Streptococcus pyogenes*

Morphology Papules that rupture, leading to honey-colored crusted lesions.

Clinical Findings Usually on the central face; can also be caused by *S. aureus* (bullous variant).

National Medical Slide Bank/Wellcome Images/Custom Medical Stock Photo

▲ **Figure 28–2.2A** Impetigo Caused by *S. Pyogenes*

© DeVry/Becker Educational Development Corp. All rights reserved.

2.2.2 Acne Vulgaris

- Chronic inflammation of the pilosebaceous unit.
- Most common disease seen by dermatologists.
- Begins at an early age, from 9 to 11 years.
- Increases in severity in the teenage years.
- Clinical lesions include the entire gamut of papules, pustules, nodules, and cysts.

Inflammatory Type

- Abnormal keratinization of the follicular epithelium.
- Sebaceous glands have androgen receptors that, during pubertal adolescence, increase sebum production.
- *Propionibacterium acnes* produce bacterial lipases, which break down sebum into fatty acids and cause an inflammatory reaction.

2.2.3 Acne Rosacea

- An inflammatory reaction of the pilosebaceous units of facial skin.
- There is a causal relationship with a mite known as *Demodex folliculorum.*
- Pustules and flushing of the cheeks is exacerbated by drinking alcohol, stress, and eating spicy food.
- Sebaceous gland hyperplasia produces enlargement of the nose, referred to as rhinophyma.
- A bulbous nose does not necessarily mean that the individual is an alcoholic.

Dr. Harout Tanielian/Science Source

▲ **Figure 28–2.2B** Acne Rosacea

Important Concept

Pathogenesis of Acne

1. Noninflamed comdones: Plugging of the outlet of a hair follicle by keratin debris.
2. An open comdone is called a "blackhead" due to oxidized central keratin plug.
3. A closed comedone is called a "whitehead" with follicular papules that do not contain an oxidized central plug, but with potential for follicular rupture and inflammation.

© DeVry/Becker Educational Development Corp. All rights reserved.

2.3 Fungal Infections

2.3.1 Dermatophytoses (Superficial Mycoses)

Epidemiology

- Fungi confined to the stratum corneum or its adnexal structures.
- Incidence increases in warm, humid climates.
- Most infections present with a scaling rash.
- The most common infections, in order of highest occurring to lowest occurring, are:
  - Tinea pedis: foot
  - Tinea unguium: nail
  - Tinea versicolor: variation in the color of the skin
  - Tinea cruris: groin

Tinea Capitis

- Superficial fungal infection of the scalp.
- Most often (>95%) caused by *trichophyton tonsurans*.

Clinical Findings

- Infects the inner hair shaft.
- Negative Wood lamp.
- Predominantly found in the African-American population.
- Circular or ring-shaped patches of hair loss, known as alopecia.
- Presence of a black dot where the hair breaks off.

Important Concept

Microsporum canis and *Microsporum audouinii* are most commonly found in Caucasians and test positive under a Wood lamp, whereas *Trichophyton tonsurans* tests negative.

Dr. Ken Greer/Visuals Unlimited, Inc.

▲ **Figure 28-2.3A** Tinea Capitis

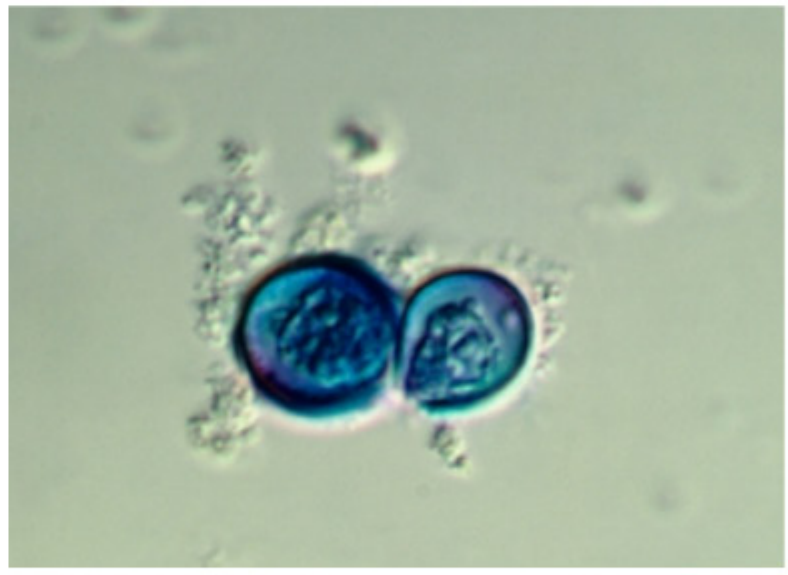

Dr. Gladden Willis/Visuals Unlimited, Inc.

▲ **Figure 28–2.3B** KOH Preparation for Wood Lamp

© DeVry/Becker Educational Development Corp. All rights reserved.

Trichophyton Rubrum

Causes all other "tineas" listed below, except for *versicolor.*

- **Tinea corporis** (body surface)—sometimes called ringworm.
  - May have a history of house pets (for example, dogs or cats).
  - It presents as an annular, outer border that is raised or scaly, with a central clearing.

Dr. Ken Greer/Visuals Unlimited, Inc.

▲ **Figure 28–2.3C** Tinea Corporis

- **Tinea pedis** ("athlete's foot") is the No. 1 cause of fungal infection in humans.
- **Tinea cruris** ("jock itch"), with involvement of the scrotum, frequently coexists with tinea pedis when both are areas for excessive sweating.
- **Tinea unguium** involves a nail that is raised, with a white nail plate, thick and crumbly.

Important Concept

Pityriasis rosea

- Pityriasis rosea initially presents as a single, large, oval, scaly, rose-colored plaque on the trunk referred to as "herald patch."
- It is all too often misdiagnosed as tinea corporis ("ringworm").
- Days or weeks after onset, a papular eruption develops on the trunk which follows the lines of cleavage often referred to as "Christmas tree" distribution.
- Lesions tend to be pruritic.
- More common during the winter.
- Rash remits spontaneously in 2–10 weeks.

© DeVry/Becker Educational Development Corp. All rights reserved.

Tinea Versicolor

- There is alteration of the skin pigmentation with regions of hypo- and hyperpigmentation.
- A Wood lamp accentuates the color variation of the skin. It is caused by *Malassezia furfur*. In a hypopigmented region, the fungus-derived acids inhibit tyrosinase in melanocytes from synthesizing melanin. In a hyperpigmented region, the fungus causes enlargement of the melanosomes in melanocytes.
- KOH preparation will locate the organisms in the hypo- and hyperpigmented regions, for reasons explained above.
  - Short hyphae have the appearance of noodles of "spaghetti."
  - The yeasts have the appearance of "meatballs."

Dr. P. Marazzi/Science Source/Custom Medical Stock Photo

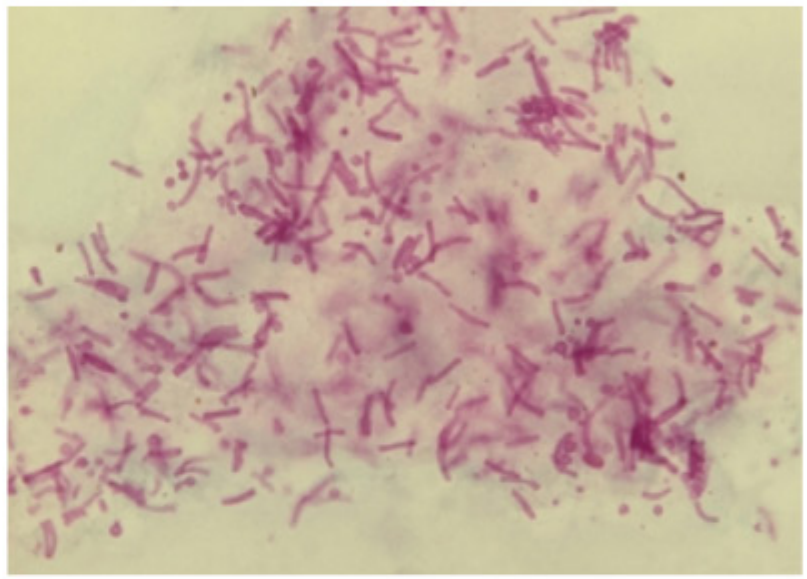

Courtesy of CDC/Dr. Lucille K. Georg

▲ **Figure 28–2.3D** Tinea Versicolor

© DeVry/Becker Educational Development Corp. All rights reserved.

2.3.2 Sporotrichosis

Etiology *Sporothrix schenckii*

- Subcutaneous mycotic infection.
- Dimorphic fungus, which is mold in soil, and yeast in tissue.

Pathogenesis

- Traumatic implantation of the fungus
- Rose gardening
- Sphagnum peat moss for packing material
- Splinters from wood carpentry
- Landscapers or field berry-pickers

Lymphocutaneous Disease Chain of suppurating lymphocutaneous nodules

Custom Medical Stock Photo

▲ **Figure 28–2.3E** Sporotrichosis

© DeVry/Becker Educational Development Corp. All rights reserved.

3 Inflammatory Dermatopathology

3.1 Perivascular Dermatitis: Urticaria

Perivascular inflammation in dermis without epidermal involvement.

Definition Pruritic, caused by mast cell histamine release.

Etiology/Pathogenesis

- Hypersensitivity process
  - Food, insect, drugs (peanuts, fire ants bites, penicillin)
  - Type I hypersensitivity (immediate and acute)
- Serum sickness
  - Type III (immune complex-mediated)
  - Slower onset and resolution

Clinical Pathology

- Raised, pruritic lesions (wheals)
- May cause angioedema
  - Subcutaneous swelling (lips, periorbital area, etc.)
- Treat with antihistamines (H_1 receptor blockers)

3.2 Spongiotic Dermatitis: Eczema

Inflammation and epidermal edema (spongiosis)

Definition Pruritic inflammatory dermatitis

Etiology/Pathophysiology

- **Atopic Dermatitis**
  - Type I IgE-mediated hypersensitivity reaction
    - Dermatitis in children: Dry skin and eczema on cheeks and extensor and flexure surfaces.
    - Dermatitis in adults: Dry skin and eczema on hands, eyelids, elbows, and knees.
- **Contact Dermatitis**
  - Allergic contact dermatitis: Type IV hypersensitivity, as seen with nickel or poison ivy.
  - Photosensitive dermatitis: Exposure to ultraviolet rays, often in association with drugs.
  - Irritant contact dermatitis: Exposure to laundry detergent.

Morphology

- Erythematous rash
- When severe, often with vesicles that weep
- Chronic scratching leads to lichenification

Important Concept

Erythema multiforme (EM)

- Immunologic reaction of skin, often confused for urticaria, triggered by infections such as *Mycoplasma*, Herpes simplex virus (recurrent EM), and drugs such as sulfonamides, penicillin, barbiturates, and phenytoin.
- Vesicles and bullae have a target lesions type of appearance.
- The rash is located on the palms, soles, and extensor surfaces.
- Stevens-Johnson syndrome involves skin and mucous membranes and has potential to be fatal.

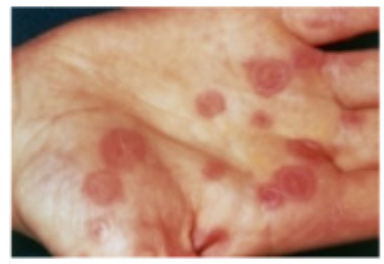

CNRI/Science Source

▲ **Figure 28–3.1A** Erythema Multiforme

Dr. P. Marazzi/Science Source

▲ **Figure 28–3.1B** Urticaria (Hives)

© DeVry/Becker Educational Development Corp. All rights reserved.

3.3 Psoriasiform Dermatitis: Psoriasis

Etiology

- Genetic susceptibility with environmental trigger.
- One third are associated with a positive family history.
- Associated with certain HLA alleles (HLA-CW6).
- Possible triggers:
  - Scratching or trauma to the skin (Koebnerization)
  - Infections (streptococcal pharyngitis)
  - Medications (lithium, antimalarials, β blockers)

Morphology/Clinical Presentation

- Sharply demarcated, white-silver, scaly plaques with salmon-colored erythema.
- Acanthosis (thickened epidermis) with elongated rete ridges.
- Thinned or absent granular layer.
- Parakeratosis with neutrophil microabscesses.
- Occurs in areas of trauma (i.e. elbows, knees); also pitting of nails.
- Pitted, thickened nails are common.

Variations

- Pustular psoriasis: Sterile pustules within plaques.
- Psoriatic arthritis: Asymmetrical sero-negative arthritis involving small and large joints, particularly associated with HLA-B27.

Treatment

- Ultraviolet A rays plus psoralen.
- Ultraviolet B rays plus coal tar.

Dr. P. Marazzi/Science Source

▲ **Figure 28–3.3A** Psoriasis: Pitting of Nails

Biophoto Associates/Science Sources

▲ **Figure 28–3.3B** Psoriasis

© DeVry/Becker Educational Development Corp. All rights reserved.

3.4 Interface Dermatitis Lichen Planus

Band-like inflammation and destruction at the dermoepidermal junction:

Etiology

- Most commonly idiopathic.
- Lichen planus has an association with hepatitis C.
- Sometimes associated with drugs
  - "Lichenoid drug eruption" (antibiotics, antimalarials, etc.)

Pathogenesis

- T cell mediated attack of keratinocytes.
- Increased risk of squamous cell carcinoma.

Morphology

- **P**ruritic, **P**urple, **P**olygonal **P**apules
- May coalesce to form **P**laques

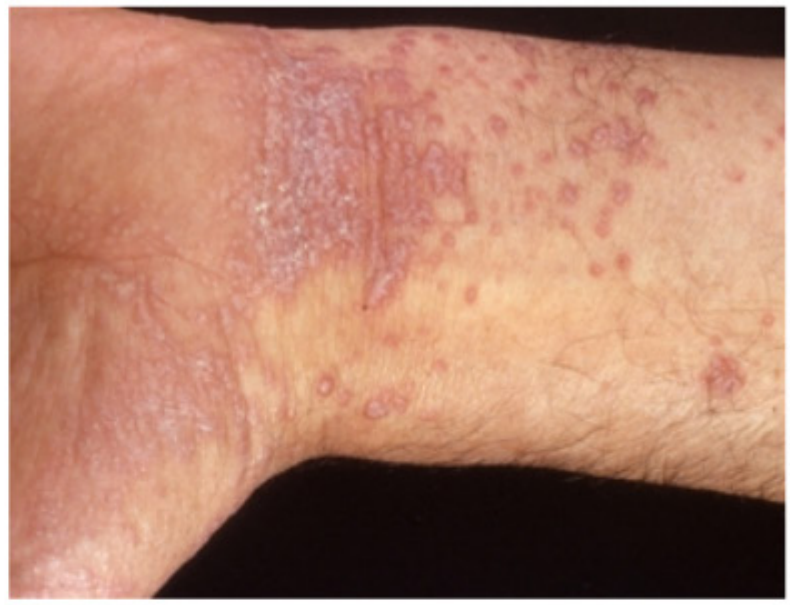

NMSB/Custom Medical Stock Photo

▲ **Figure 28–3.4** A Lichen Planus

3.5 Vesiculobullous Dermatitis

Loss of attachment between either keratinocytes (intraepidermal) or keratinocytes and basement membrane (subepidermal).

3.5.1 Pemphigus Vulgaris

- Type II hypersensitivity of IgG antibodies against intercellular attachment sites, the desmosomes, and between keratinocytes.
- Vesicles and bullae develop on skin and oral mucosa.
- Intraepithelial vesicles are located suprabasal.
  - Basal cells resemble a row of tombstones.
  - Acantholysis of keratinocytes in the vesicle fluid.
  - Pemphigus vulgaris demonstrates a positive Nikolsky sign.
    - Outer epidermis separates from the basal layer with minimal pressure.

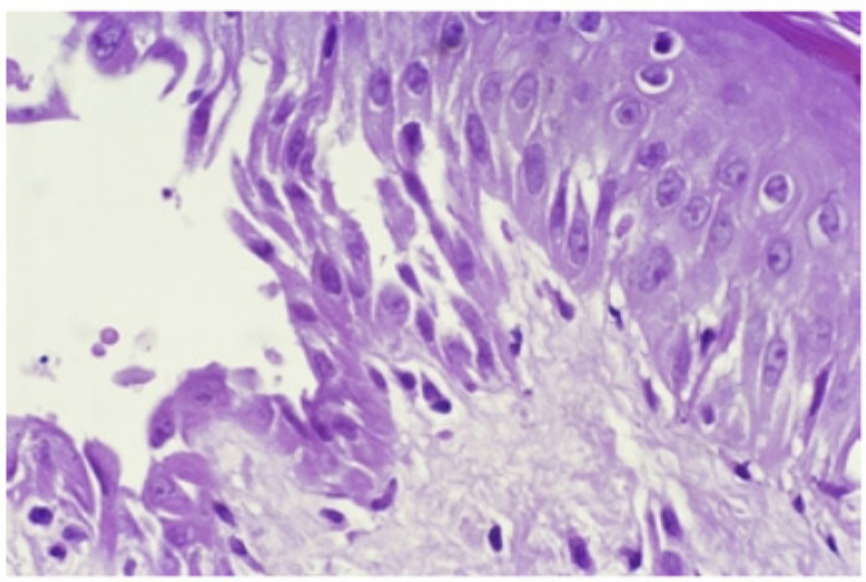

Biophoto Associates/Science Source

▲ **Figure 28–3.5A** Pemphigus Vulgaris

© DeVry/Becker Educational Development Corp. All rights reserved.

3.5.2 Bullous Pemphigoid

- Type II hypersensitivity reaction against basement membrane, against intercellular attachment sites, the hemidesmosomes, and between dermoepidermal junction.
- Vesicles are subepidermal:
  - Develop on the skin and oral mucosa
  - No acantholysis of keratinocytes in vesicle fluid
  - Negative Nikolsky sign

Dr. P. Marazzi/Science Source

▲ **Figure 28–3.5B** Bullous Pemphigoid

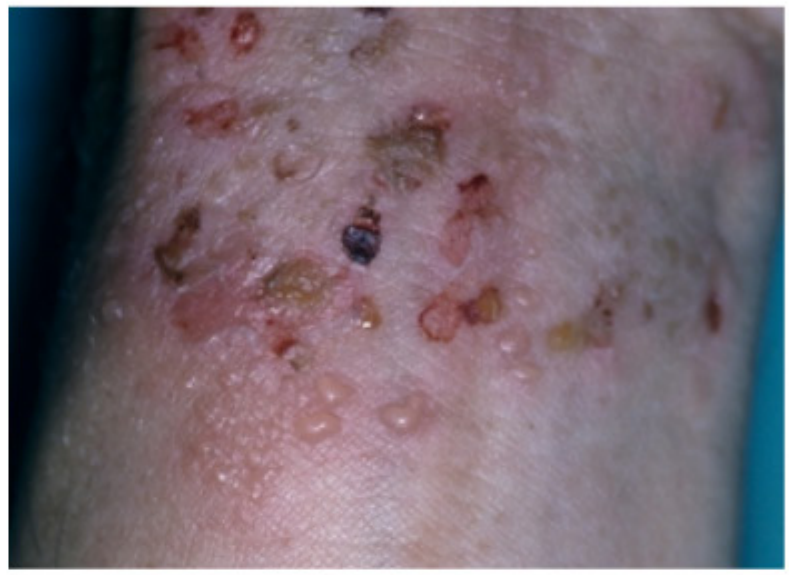

Dr. Ken Greer/Visuals Unlimited, Inc.

▲ **Figure 28–3.5C** Vesiculobullous Dermatitis

3.6 Panniculitis Erythema Nodosum

Definition Inflammatory lesion of subcutaneous fat.

- More common in women than men.
- Seen more in association with the following:
  - Systemic fungi such as coccidioidomycosis, histoplasmosis
  - Sarcoidosis
    - — Oral contraceptive pills/pregnancy
    - — Leprosy/tuberculosis
    - — Streptococcal pharyngitis

Morphology Raised, erythematous, painful nodules on the anterior shins.

Mediscan/Visuals Unlimited, Inc.

▶ **Figure 28–3.6** Erythema Nodosum

© DeVry/Becker Educational Development Corp. All rights reserved.

4 Neoplastic Diseases

4.1 Benign Tumors of the Skin

The two categories of nevi are:

- **Common Nevus:** Symmetric and uniform without atypia; without increased concern.
- **Dysplastic Nevus:** Irregular shape and pigmentation with atypical cytology; possibly "preneoplastic" with increased risk of melanoma.
  - Follows the rule of ABCDE of melanocyte disorders.

4.1.1 Common Nevus: Nevocellular Nevus

Pathophysiology

- **Junctional nevus:** Macular lesions composed of nested melanocytes at the dermoepidermal junction.

Memory Aid

Rule of **ABCDE**

A= Asymmetry

B = Irregular borders

C = Variation in color

D = Increase in diameter of the lesion

E = Elevation of the lesion

Memory Aid

The *Leser-Trélat sign* is a phenotypic marker for gastric adenocarcinoma.

Biophoto Associates/Science Source

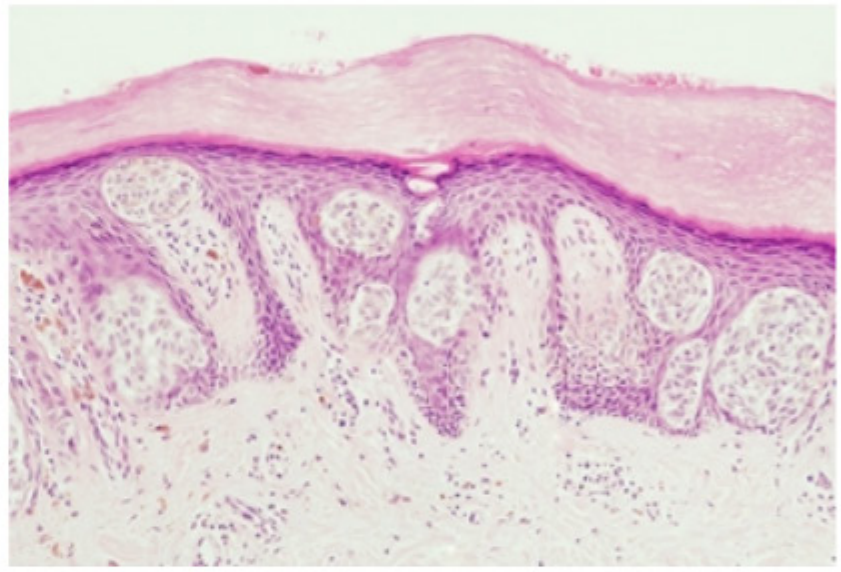

Biophoto Associates/Science Source

▲ **Figure 28–4.1A** Junctional Nevus

- **Compound nevus:** A papular lesion caused by extension of the nested melanocytes into dermis.

SLP/Science Source

▲ **Figure 28–4.1B** Compound Nevus

© DeVry/Becker Educational Development Corp. All rights reserved.

- **Intradermal nevus:** A papular, usually minimally pigmented lesion with nested melanocytes only in the dermis.

Wellcome Images/Custom Medical Stock Photo

▲ **Figure 28–4.1C** Intradermal Nevus

4.1.2 Seborrheic Keratosis

Most common of the benign epidermal neoplasms that arise spontaneously in older individuals.

Morphology Round, coin-like, tan-to-brown thin papules and small plaques with "stuck-on" appearance. Consist of acanthotic epidermis and overlying hyperkeratosis without cytological atypia.

DermPics/Science Source

▲ **Figure 28–4.1D** Seborrheic Keratosis

© DeVry/Becker Educational Development Corp. All rights reserved.

4.2 Premalignant Conditions of the Skin

4.2.1 Actinic (Solar) Keratosis

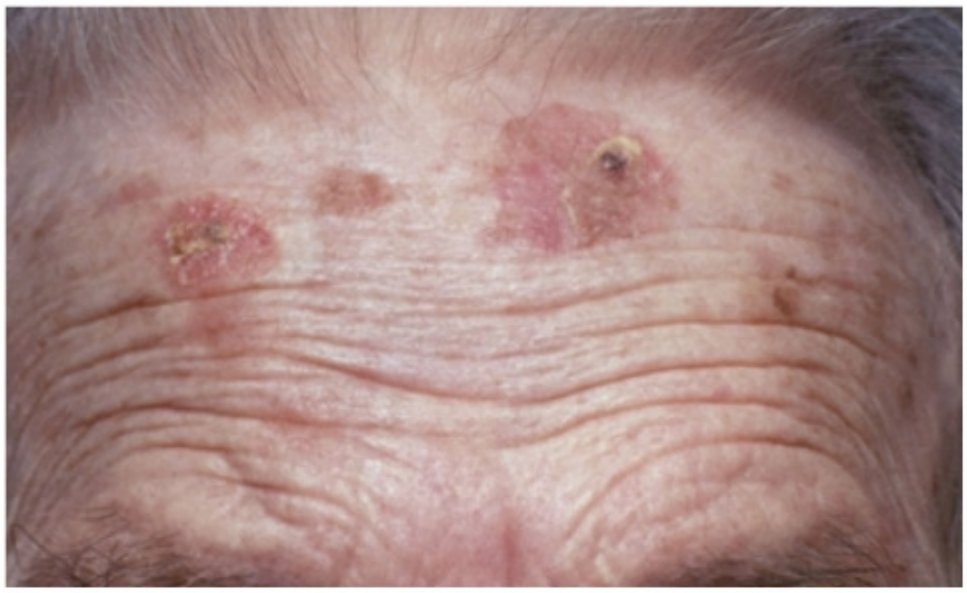

Wellcome Images/Custom Medical Stock Photo

▲ **Figure 28–4.2** Actinic Keratosis

Etiology Associated with UV exposure.

Morphology Scaly lesion with surrounding erythema. Hyperkeratosis, with pearly gray-white appearance which recurs after being scraped off.

Clinical Pathology Precursor of SCC (~ 2%–5% progress but slowly).

4.3 Malignant Conditions of the Skin

4.3.1 Basal Cell Carcinoma of the Skin (BCC)

Etiology Chronic but intermittent UV exposure.

Morphology Pearly papule or nodule, often with central ulceration on sun-exposed skin.

Clinical

- Most common cancer in humans.
- Locally aggressive, although slow-growing.
- May become disfiguring with extensive growth.
- Only very rarely metastasizes (<0.05%).

Morphology Proliferation of basophilic cells, arising from the basal epidermis infiltrating the dermis. Cells resemble the stratum basale of normal skin.

Dr. P. Marazzi/Science Source/Custom Medical Stock Photo

▶ **Figure 28–4.3A** Basal Cell Carcinoma

© DeVry/Becker Educational Development Corp. All rights reserved.

4.3.2 Squamous Cell Carcinoma of the Skin (SCC)

Etiology

- The most common cause is chronic UV exposure.
- Other causes—arsenic exposure, chronic burns or ulcers, chronic inflammation, immunosuppression.
- Locally aggressive, but does not usually metastasize (but does so more often than basal cell carcinoma).
- BCC is more common than SCC everywhere except the hands and the mucosa.

Morphology

- Nodular and scaly lesions on sun-exposed skin.
- Often ulcerated.
- Typically, squamous cells invading dermis.
- Keratin "pearls" on histology.

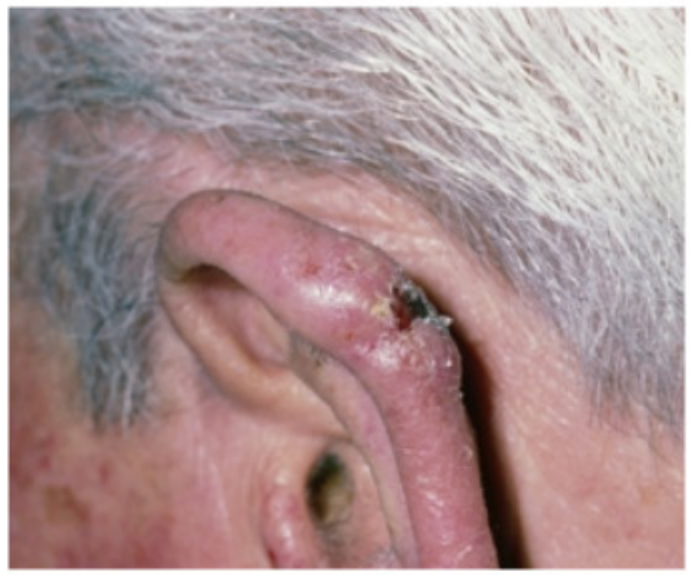

Dr. P. Marazzi/Science Source

▲ **Figure 28–4.3B**
Squamous Cell Carcinoma

4.4 Malignant Melanoma

Epidemiology

Most rapidly increasing cancer worldwide. The risk in the United States is about 1:65.

- Prognosis is best determined by the *depth* of invasion.
  - A reason to avoid transection during biopsy.
- Metastasis (= Harbinger of poor outcome)
  - Lymph nodes, lungs, nervous system, and liver are the most commonly affected.
  - No effective chemotherapy at present.

Etiology

- Excessive sun exposure, especially at an early age.
- Intermittent sun exposure is also associated.
- Melanoma in a first-degree relative increases risk.
- Associated with some syndromes (*for example, dysplastic nevus syndrome*, *xeroderma pigmentosum*).

Pathophysiology

- Radial growth phase
  - Malignant melanocytes proliferate laterally along the dermoepidermal junction.
  - Typically does not metastasize at this stage.
- Vertical growth phase
  - Malignant cells penetrate into dermis and beyond.
  - Metastasis occurs at this stage.

Morphology

- ABCDE criteria found with dysplastic nevus.
- Proliferating atypical nest of melanocytes.
- Often with pagetoid extent.

© DeVry/Becker Educational Development Corp. All rights reserved.

4.4.1 Types of Malignant Melanoma

Superficial spreading melanoma is the most common type of malignant melanoma and occurs on lower extremities, arms, and the upper back.

Lentigo maligna melanoma is most commonly found in the elderly with an extension of the lesion into the dermis, but is the least likely to have a vertical phase.

Nodular melanoma can be found in UV-exposed areas and has no radial growth phase, with only the vertical phase demonstrated at presentation.

Acral lentiginous melanoma is not related to sun exposure and is more commonly found in the African-American and Asian populations. This subtype is found in the palms, soles, and beneath the nails, and has a poor prognosis.

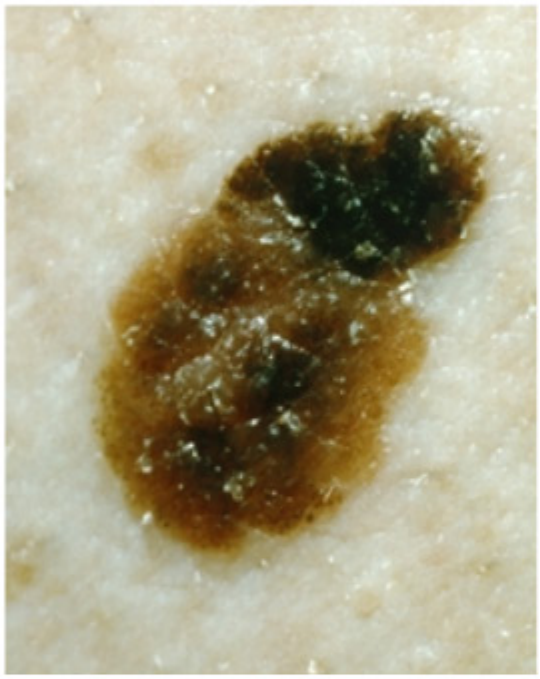

Biophoto Associates/Science Source

▲ **Figure 28–4.4A**
Superficial Spreading Melanoma

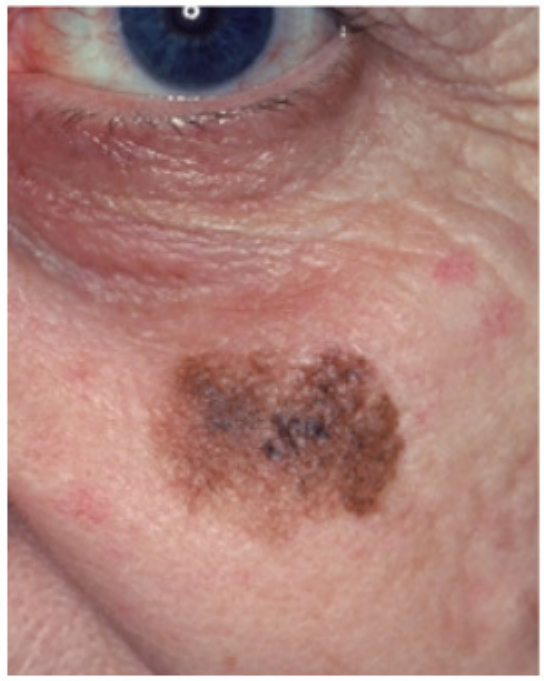

John Watney/Science Source

▲ **Figure 28–4.4B**
Lentigo Maligna Melanoma

Biophoto Associates/Science Source

▲ **Figure 28–4.4C**
Nodular Melanoma

Courtesy of CDC/Carl Washington, MD, Emory University School of Medicine/Mona Saraiya, MD, MPH

▲ **Figure 28–4.4D**
Acral Lentiginous Melanoma

© DeVry/Becker Educational Development Corp. All rights reserved.

BECKER
PROFESSIONAL EDUCATION®

becker.com
ACCOUNTING | PROJECT MANAGEMENT | HEALTHCARE

USMLE® is a joint program of the Federation of State Medical Boards and the National Board of Medical Examiners®.

© 2013 DeVry/Becker Educational Development Corp. All rights reserved.

2 370000 111715